

# 4D-Flow MRI: Technique and Applications

## 4D-MR-Flussmessung: Technik und Anwendungen

### Authors

Alexandra Sträter<sup>1</sup>, Armin Huber<sup>2</sup>, Jan Rudolph<sup>1</sup>, Maria Berndt<sup>3</sup>, Michael Rasper<sup>1</sup>, Ernst J. Rummeny<sup>3</sup>, Jonathan Nadjiri<sup>1</sup>

### Affiliations

- 1 Department of Diagnostic and Interventional Radiology, University Hospital Technical University of Munich
- 2 Department of Radiology, Hospital Fürstentfeldbruck
- 3 Department of Neurology, University Hospital Technical University of Munich

### Key words

MR-angiography, angiocardiology, cardiac, vascular, MR-imaging

received 08.03.2017

accepted 07.05.2018

### Bibliography

DOI <https://doi.org/10.1055/a-0647-2021>

Published online: 13.8.2018

Fortschr Röntgenstr 2018; 190: 1025–1035

© Georg Thieme Verlag KG, Stuttgart · New York

ISSN 1438-9029

### Correspondence

Dr. Alexandra Sträter

Institute of Diagnostic and Interventional Radiology,  
Klinikum rechts der Isar, Technische Universität München,  
Ismaninger Straße 22, 81675 Munich, Germany  
Tel.: ++49/89/41 40 56 02  
[alexandra.straeter@gmail.com](mailto:alexandra.straeter@gmail.com)

### ABSTRACT

**Background** Blood flow through the cavities of the heart and great vessels is pulsatile and is subject to time and multidirectional variations. To date, the recording of blood flow in multiple directions and phases has been limited. 4D-flow MRI offers advantages for the recording, visualization and analysis of blood flow.

**Method** The status quo of the method was summarized through analysis with the PubMed database using the keywords “4D-flow MRI, phase-contrast magnetic resonance imaging, MR flow imaging/visualization, MR flow quantification, 3 D cine (time-resolved) phase-contrast CMR, three-directional velocity-encoding MRI”.

**Results/Conclusion** This review summarizes the current status of the technical development of 4D-flow MRI, discusses

its advantages and disadvantages and describes clinical applications. Finally, the most important principles and parameters are explained to give the reader relevant information about clinical indications, postprocessing methods and limitations of the method.

### Key Points:

- 4D-Fluss-MRT
- 3-dimensionale zeitaufgelöste Phasenkontrast-MRT
- Flussanalyse-MRT (Wall-Shear-Stress/Druckgradienten-Messung/Vortex-Fluss/turbulente kinetische Energie/Flussgeschwindigkeit/Flussrate)

### Citation Format

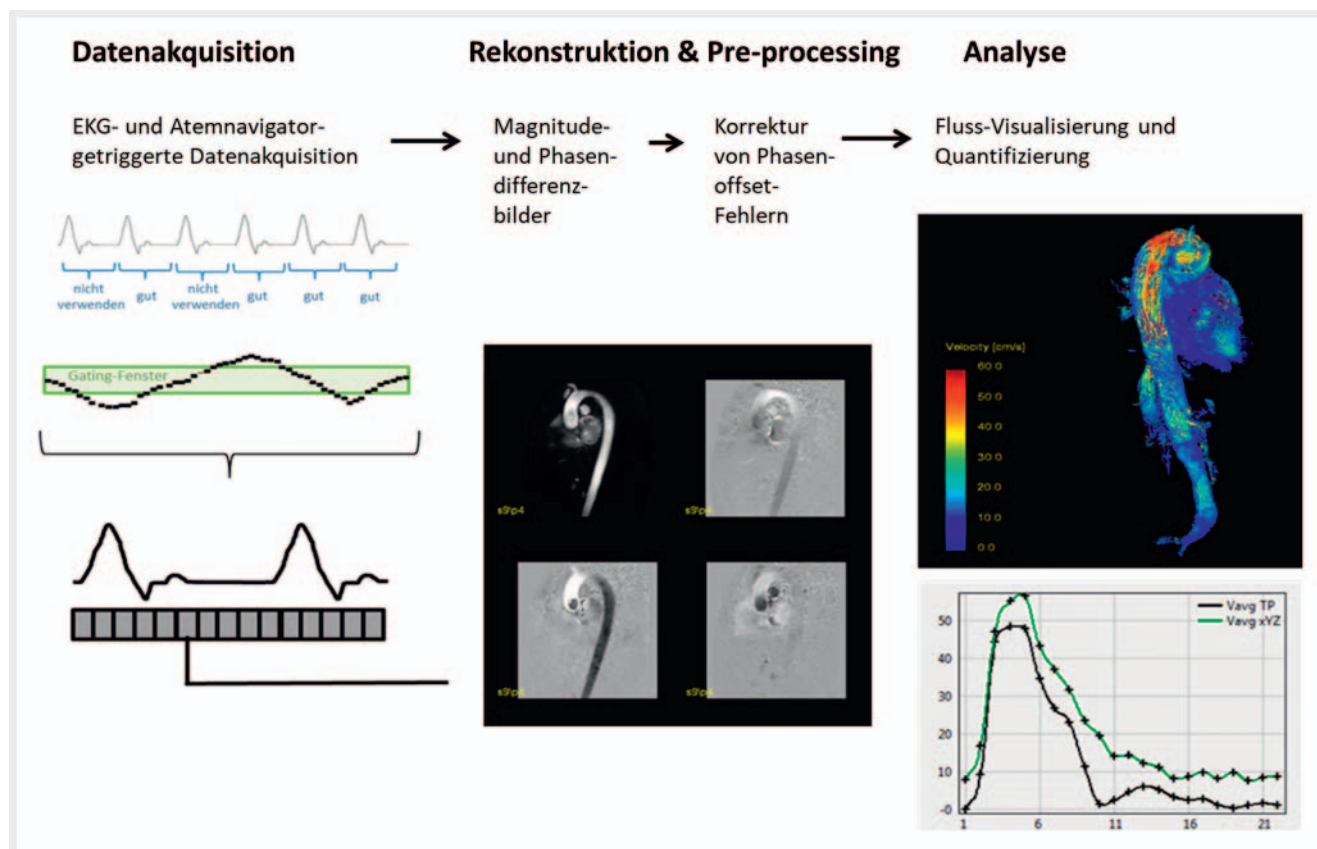
- Sträter A, Huber A, Rudolph J et al. 4D-Flow MRI: Technique and Applications. Fortschr Röntgenstr 2018; 190: 1025–1035

### ZUSAMMENFASSUNG

**Hintergrund** Der Blutfluss durch das Herz und die großen Gefäße erfolgt pulsatil und unterliegt zeitlichen wie auch multidirektionalen Schwankungen. Bisher ist die Erfassung des Blutflusses in alle Richtungen und Phasen deutlich limitiert. Die MRT-gestützte 4D-Flussmessung ist eine fortschrittliche Methode zur Erfassung, Darstellung und Analyse von Flussverhältnissen in den Gefäßen.

**Methode** Basierend auf einer Literaturrecherche in der PubMed-Datenbank mit den Begriffen „4D-Flow-MRI, Phase-contrast magnetic-resonance-imaging, MR-flow-imaging/-visualization, MR-Flow-quantification, 3D-cine (time-resolved) phase-contrast CMR, three-directional velocity-encoding MR“ wurde der aktuelle Stand der Methode in dieser Übersichtsarbeit zusammengefasst.

**Ergebnisse/Schlussfolgerung** Diese Übersichtsarbeit fasst den aktuellen Stand der technischen Entwicklung der 4D-Flussmessung zusammen, diskutiert ihre Vor- und Nachteile und zeigt Anwendungsmöglichkeiten auf. Schließlich werden die wichtigsten Prinzipien und Parameter erklärt, sodass der Leser über die Anwendung der Methode, die möglichen klinischen Indikationen, die Auswertung verschiedener Parameter durch Post-processing-Methoden und die Limitationen des Verfahrens relevante Informationen erhält.



► **Fig. 1** Workflow in a 4D-flow measurement: The initial step is ECG-triggered (left column, top) and breath-triggered (left column, middle) data acquisition. During reconstruction several magnitude pictures (black background, middle bottom) will be taken through different reconstruction processes (e. g. parallel imaging) and pictures in all space axes (gray background, middle bottom) will be calculated. Phase-offset errors will be corrected during preprocessing. During the analysis phase the datasets will be checked for quality first for subsequent visualization (right column, top) and quantitative analysis (right column, bottom).

## Introduction

In light of the globally increasing number of cardiovascular diseases, a detailed analysis of blood flow in the heart and vessels is needed in order to acquire a thorough understanding of the underlying pathomechanisms. 4D-flow measurement seems to be a promising tool that provides functional information in addition to the morphological visualization of vessels. Different parameters are examined with the goal of detecting and treating the causes of cardiovascular diseases prior to the onset of clinically relevant pathologies. 4D-flow measurement allows a qualitative and quantitative analysis of flow velocity, flow volume, flow direction, wall shear stress, pressure gradients, and complex flow patterns. It is currently possible to visualize flow in the heart, aorta, liver vessels, kidney arteries, large intraabdominal vessels, carotids, and large intracranial vessels. Research regarding further improvement of the technique, primarily in regard to further shortening of the measurement time as well as better spatial and temporal resolution, is currently being performed. In particular, parallel imaging and compressed sensing are to be mentioned here. The 4D-flow measurement procedure includes data acquisition, reconstruction, and preprocessing as well as analysis as shown in ► **Fig. 1**.

To date, 4D-flow measurement is used in only a few hospitals in Germany to support clinical decision-making.

## Technique

### Field of view, spatial and temporal resolution, VENC

Due to the relatively long scan times of 4D-flow measurement, the field of view should be limited to the most important region. A high spatial resolution is required for accurate determination of flow parameters and to be able to record even small flow phenomena. However, the smaller the voxel size, the longer the scan time and the lower the signal-to-noise ratio [SNR]. Therefore, a compromise must be made on an individual basis for each patient. A voxel size with an isotropic edge length of 2.5–3.0 mm for the heart and thoracic/abdominal vessels and 0.7–1.5 mm for intracranial vessels has become established [1]. The highest possible temporal resolution of approximately 40 ms per 3D dataset is needed to be able to record even brief flow phenomena [2]. ► **Table 1** summarizes useful benchmarks for spatial and temporal resolution as well as the field of view.

► **Table 1** Benchmarks for the technical parameters of 4D-flow measurement.

parameter	benchmark
field of view (FOV)	as large as necessary and as small as possible
spatial resolution	isotropic voxel size: 2.5 – 3.0 mm for heart/aorta/pulmonary arteries isotropic voxel size: 1.5 – 2.0 mm for large abdominal vessels (renal arteries/celiac trunk/superior mesenteric artery) isotropic voxel size: 0.7 – 1.5 mm for intracranial vessels
temporal resolution	approx. 40 ms

The flow velocity range to be visualized must be defined by the user prior to measurement by setting the VENC (velocity encoding sensitivity). The VENC determines the maximum flow velocity that can be recorded in the subsequent measurement. With a phase shift of  $-\pi$  to  $+\pi$  or an angle difference of the phase of  $-180$  degrees to  $+180$  degrees, the VENC represents a minimum and maximum velocity. This defines the visualizable velocity encoding range. The flow velocities are encoded in grayscale. If the previously selected VENC is exceeded in a region during measurement, the flow velocity in this region cannot be properly recorded. This results in an abrupt transition on the image from a light area to a black area, known as aliasing. Quantification is not possible in the region of the aliasing artifact. The selected VENC correlates with the signal-to-noise ratio so that a VENC that is selected too high results in noisy images. To prevent such an artifact, the VENC of the expected flow velocity must be adapted as exactly as possible. The following rule of thumb applies: the VENC is to be selected to be approximately 10% greater than the expected maximum velocity. A common dilemma results from the fact that both high and low flow velocities must be shown, such as in aortic stenosis with high flow velocity in the jet and slower flow velocities in the heart and in more distal arterial vessels. Multi-VENC approaches represent an attempt to overcome this problem [3]. ► **Table 2** summarizes the benchmarks for the VENC in various vessels.

## Sequence

Spoiled gradient echo sequences are used for 4D flow measurement. After the readout gradient the remaining transverse magnetization is deleted by a spoiler gradient in the layer-selecting X-axis. Thus only the Z-magnetization remains during the subsequent excitation. As a result, short echo (TE) and repetition (TR)

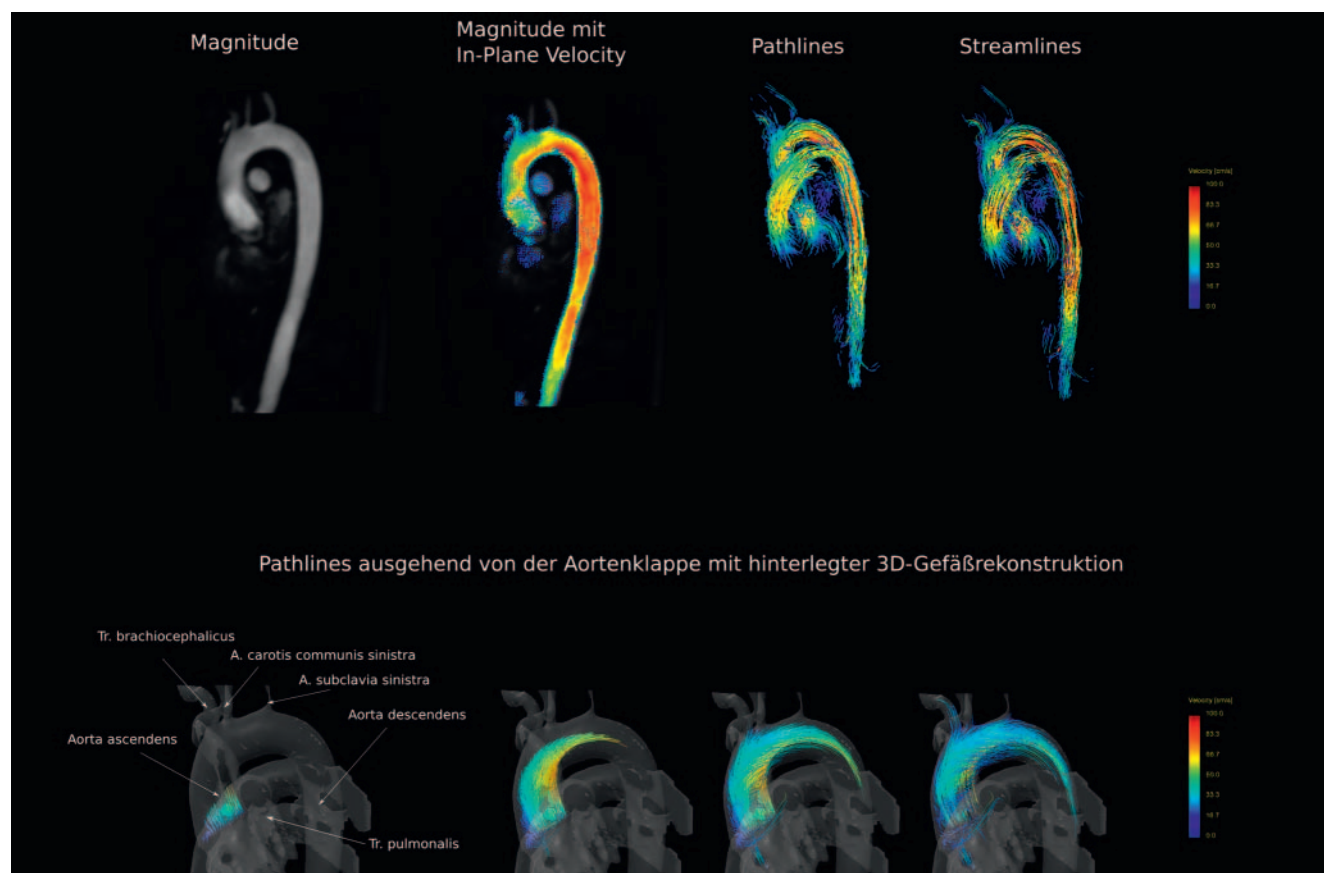
► **Table 2** Benchmarks for the choice of VENC (= velocity encoding sensitivity) in various blood vessels.

examined region	VENC
aorta	100 – 200 cm/s stenosis: 250 – 400 cm/s aneurysm: 0 – 100 cm/s
ventricle	150 cm/s
heart valves/heart cavities	insufficiency: 150 cm/s stenosis: 250 – 500 cm/s
carotids	150 – 450 cm/s
venous vessels	50 – 80 cm/s

times of TE 2 – 4 ms and TR 5 – 7 ms are possible. Due to the short TR, the signal maximum of the blood is weighted inversely with respect to the T1 relaxation time. Therefore, 4D-flow measurement does not require contrast agent administration. Performing 4D-flow measurement after administration of a gadolinium contrast agent results in a better signal-to-noise ratio associated with an improved velocity-to-noise ratio. Of course, the contrast agent improves the contrast between blood and surrounding tissue. However, care must be taken since the washout of the contrast agent changes the T1 time of the blood and it is not yet fully understood how this affects measurement results [1].

## Gating

To compensate for movement of the heart and chest excursion and to be independent of the precise participation of the patient, breath triggering is often used in the navigator technique. Data defined by the diaphragm position determined by the navigator measurement are recorded only during a defined time window. A bar-shaped HF pulse is emitted prior to the measurement to determine the diaphragm position in the direction of movement. If the diaphragm is located within the acceptance window, the data acquired to that point are included in the image reconstruction. Otherwise, they are discarded. Acceptance windows of 3 – 6 mm are typically set. Navigator position measurement takes time. If the navigator efficiency is low, prolonged measurement times can occur [4]. In the case of the real-time slice tracking method, the diaphragm position is measured immediately prior to every data acquisition and then the gradients are modified in real time so that the measured layer corresponds to the current heart position. This makes it possible to define a larger navigator window, typically 5 – 8 mm, thereby shortening the acquisition time [1]. Gating in relation to the cardiac cycle is performed in an analogous manner. Instead of the diaphragm navigator, ECG registration is used for synchronization of the cardiac phases.



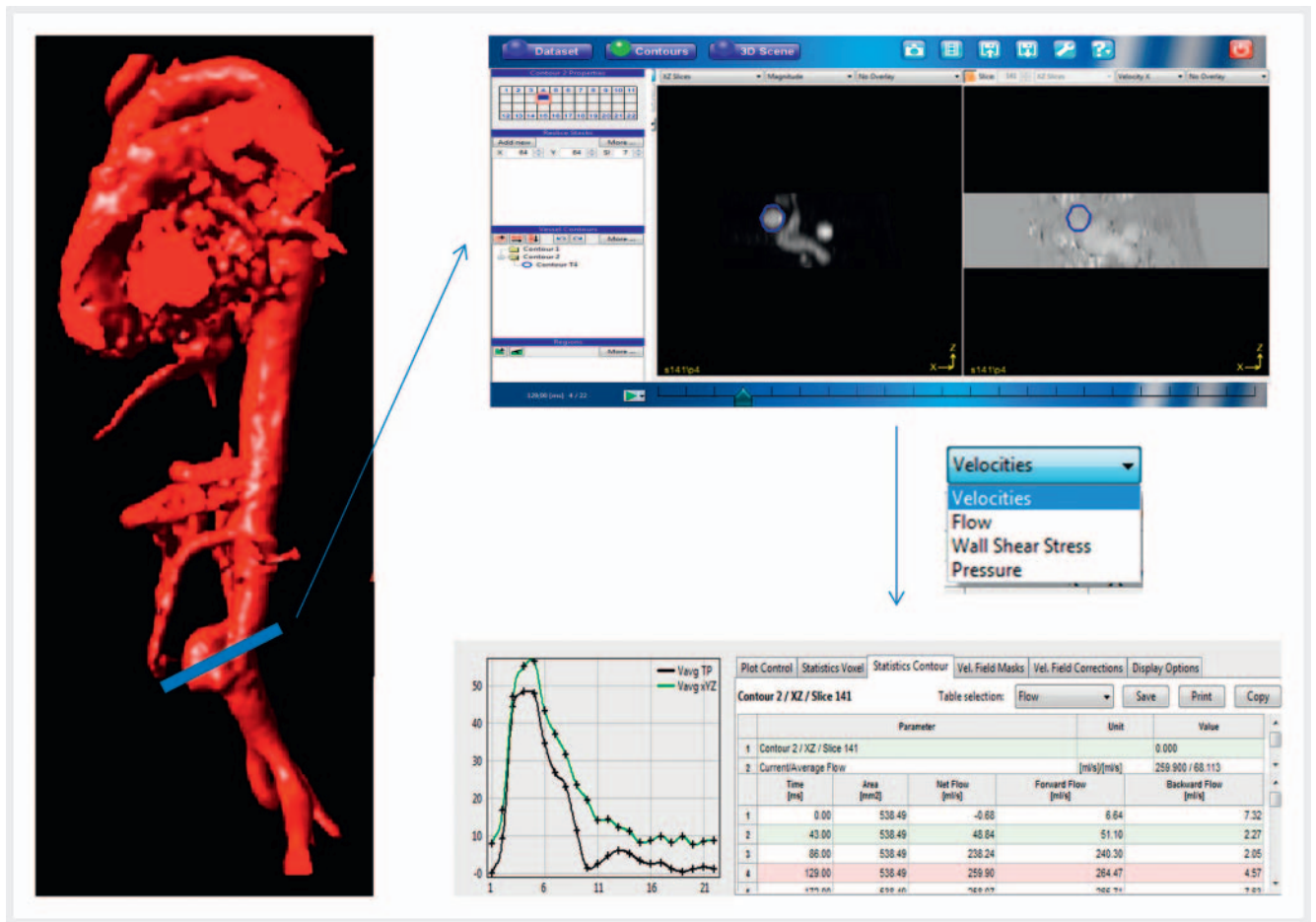
► **Fig. 2** The datasets for 4D-flow measurement provide several options for visualization: magnitude pictures (row 1, left picture) are suited for analyzing anatomical conditions. Color-coded speed visualization (row 1, second picture from the left) on one level on magnitude pictures allows for quick overview of flow velocity inside the vessels. Path lines (row 1, third picture from the left) lay out the route of liquid particles during a heart cycle; they are especially useful for displaying liquids in relation to time (row 2). The lower part of the picture gives an example of the systolic flow coming from the aortic valve. Streamlines (row 1, right picture) show the direction of flow of liquid particles for a given time and are capable of providing three-dimensional conditions at a defined point of time.

## Shortening of the acquisition time

The absolute measurement time is determined on the one hand by technical parameters, such as spatial and temporal resolution and coverage, and on the other hand by patient-dependent parameters, such as heart rate, ECG signal, and respiratory amplitude. Various k-space strategies have been developed to accelerate data acquisition in 4D-flow measurement. In the case of k-t-undersampling, the entire k-space is not read out so that the scan time can be shortened by the reduction factor 4–5 at the expense of the SNR. In the case of segmented k-space filling, multiple connected k-space rows (= segments) are read out with a single excitation. The segments can be recorded in a different sequence. The central rows should be read out first to ensure good image contrast. A decrease in resolution must be accepted since a reduction in the signal occurs by the time the peripheral segments are read out. A segmentation factor of 2 is recommended [1]. The use of non-Cartesian k-space readout makes it possi-

ble to shorten the scan time with a resulting advantage for the resolution and SNR. A centric, elliptical readout in which the outer rows are not read out or are replaced by zeros is useful for 4D-flow measurement. The principle of parallel imaging is based on reduced k-space acquisition: using a coil with multiple elements, various coil elements can simultaneously record information about the origin of the MRI signal according to their sensitivity for the magnetic field. This concept has been realized by various methods and providers, e. g. SENSE (SENSitivity Encoding), SMASH (simultaneous acquisition of spatial harmonics) and GRAPPA (GeneRalized Autocalibrating Partial Parallel Acquisition). The image acquisition time can be lowered by a reduction factor of 2 to 4 depending on the number of coil elements and the field strength [1]. A combination of the described acceleration methods is particularly effective for reducing the scan time of a 4D-flow measurement. Visualization of the entire heart takes approximately 10 min and the aorta takes between 5 and 15 min (depending on coverage).





► **Fig. 3** 4D-flow measurement enables retrospective analysis of flows in any location of the dataset. A layer is drawn in a specific location in the vessel for which corresponding 2 D images are checked and the desired analysis parameters are set.

## Preprocessing

4D-flow measurement provides an enormous amount of data. This raw data contains various errors so that preprocessing is necessary. The main errors are Maxwell terms, eddy currents and phase wraps. In Maxwell terms, concomitant gradient fields cause spatially varying phase offsets. Maxwell terms occur in all phase-contrast acquisitions. The correction factors can be derived directly from the waveforms of the gradients used for data acquisition [5]. Phase wraps refer to wrapping in the phase encoding direction. An automatic correction system is available as an inline function in every MRI scanner. The quick switching on and off of magnetic field gradients results in changes in the magnetic flow, causing eddy currents in conductive materials. These change the strength and duration of the desired gradients so that temporal and spatial phase offsets occur. Most MR scanners have a correction system that adapts the waveforms of the gradients by predicting eddy currents. However, it is not possible to completely eliminate eddy currents [5]. A further error occurs when the flow velocity exceeds the selected VENC during data acquisition,

resulting in aliasing artifacts. If it is not possible to adapt the VENC, an attempt can be made to determine the flow velocities within the areas with aliasing using a phase unwrapping algorithm. Since no mathematical solution for an exact algorithm has been found to date, various errors occur when using the currently available correction software [6] so that its use currently cannot be recommended.

After error correction, the image data must be segmented. Magnitude images (images from the sum of vector differences) allow the best differentiation between static tissue and flowing blood in the vascular lumen. Therefore, the vessel walls should be drawn on the basis of these images. ► **Fig. 1** shows phase-contrast images and magnitude images. ► **Fig. 3** shows the procedure for drawing the vessel wall. In the event that even magnitude images do not provide sufficient contrast to differentiate between the vessel and the surrounding tissue, contrast agent administration or an additional MR angiography scan can be considered [7]. Various software solutions offer different options for vessel wall identification. Depending on the manufacturer, the options range from manual drawing to fully automatic vessel wall detection.

## Visualization

There are various software solutions for evaluation and flow visualization. The most widely available options are 4D Flow (Siemens, Germany Erlangen), cmr 42 (Circle Cardiovascular Imaging Inc., Calgary Canada), GT-Flow (Gyrotool LLC, Switzerland Winterthur), and Arterys (Arterys USA San Francisco). In addition, some hospitals and institutes are using their own inhouse software solutions since the commercially available products offer a limited spectrum of evaluation options. These products all use vector fields, streamlines, or path lines to visualize flow. Some also offer the option of generating wall-shear-stress maps, flow velocity maps or pressure maps.

The flow velocity vectors within a volume are available as vector fields. The velocity of each vector is encoded using color coding and can be interpreted on the basis of a velocity key. The velocity and the flow direction can be represented by vector fields. Streamlines are curves that represent the direction of flow of a liquid particle at a certain point in time. Path lines represent the path taken by a fluid particle during a cardiac cycle. ► **Fig. 2** shows the different visualization options.

## Quantitative evaluation

Since 4D-flow measurement is capable of covering larger areas and records the entire flow information within these areas, the desired flow parameters can be subsequently evaluated in every region of interest. A region of interest (ROI) is drawn at any location in the visualized vessel as shown in ► **Fig. 3** and is evaluated with respect to the desired parameters.

### Flow velocity and flow rate

The flow velocity and flow rate are the simplest parameters, but they are also highly significant. If the local flow rate is reduced, it must be assumed that there is distal ischemia of the tissue to be supplied [8]. Local acceleration of the flow velocity indicates stenosis [9].

### Wall shear stress (WSS)

The WSS is the shear force caused by the blood stream acting on a region of the vessel wall. This parameter is becoming increasingly important since it was able to be shown that the WSS level correlates with different vessel pathologies, primarily atherosclerosis and pathological vessel dilatation [10]. The vessel wall must be drawn as precisely as possible for the WSS calculation. The flow velocity directly beneath the vessel wall can then be determined by interpolating the adjacent velocity data and the flow gradient can be calculated. Under the assumption that the blood viscosity is constant (and is approximately 4 centipoises (cP)), the WSS can be calculated from the flow gradient. The WSS can be displayed

via surface rendering color maps in which regions with a high and low WSS are indicated by color coding. For the aorta it was able to be shown that regions with a high WSS correlate with the dysregulation of the extracellular matrix and the degeneration of elastic fibers of the ascending aorta [11]. Thus the WSS can serve not only as a marker for increased stress and thus a vessel wall location that is particularly at risk but also as a disease course parameter in known vessel pathology [12, 13]. A relationship between WSS and the occurrence/rupture of intracranial aneurysms is presumed [14, 15].

### Turbulent kinetic energy (TKE)

TKE describes the energy that must be additionally applied to keep blood flow constant over turbulent areas. Increased fluctuation of the flow in turbulent areas results in a greater pressure loss in this area so that more energy is needed to maintain blood flow. A TKE that is greater than baseline with a similar flow rate means a reduced luminal diameter of the vessel [16]. TKE quantification is a parameter for determining blood flow efficiency. The higher the TKE, the harder the heart has to work. There is an association between an increased TKE and cardiac disease. It could be shown that patients with dilatative cardiomyopathy have a greater TKE than healthy subjects [17].

### Vortex flows

Vortex flows describe circular flows in a fluid. Vortex flows occur at many locations within the cardiovascular system. These are physiological at some locations such as within the left ventricle, the ascending aorta, and the pulmonary vessels. However, it was able to be shown that vortex flows can occur at non-physiological sites in various diseases. Aneurysms, pulmonary hypertension, and various heart diseases correlate with the occurrence and the intensity of vortex flows [18, 19]. In addition, various valve pathologies and the use of artificial heart valves result in different vortex flows [20]. The significance of the vortex flow is the subject of current research. Various parameters of vortex flow analysis were introduced for this purpose, the most important being vorticity, the  $\lambda_2$  criterion (for visualizing the turbulent flow via scalar fields in combination with isosurfaces) and critical point analysis (transition point of the flow from a laminar to a turbulent flow).

### Pressure gradient

A loss of pressure in the vascular system means that there is a loss of energy generated by the heart. The greater the loss in pressure, the harder the heart has to work. The parameter has become established as a biomarker for evaluating stenosis (e.g. the aortic valve or in an aortic isthmus stenosis) [21, 22]. Invasive measurement via pressure catheter is the gold standard of pressure gradient measurement. The disadvantage is the invasiveness of the

► **Table 3** Clinical use of 4D-flow MRI.

aortic valve stenosis, pulmonary valve stenosis	maximum flow velocity	Hsian A et al. J Mag Res Im 2015; 41: 376 – 385
congenital heart diseases	maximum flow velocity, velocity, changes over time or postoperative vs. preoperative	Riesenkampff E et al. JACC Cardiovasc Ima 2014; 7: 920 – 926
aortic aneurysm	flow characteristics, maximum flow velocity, wall shear stress	Mahadevia R et al. Circulation 2014; 129: 673 – 682
aortic dissection	extent, location of the fenestration, true and false lumen, flow in the arterial branches	Francois CJ et al. J Thora Cardiovasc Surg 2013; 145: 1359 – 1366
pulmonary hypertension	anatomical correlation, changed flow characteristics, pressure calculation	Banc O et al. Mag Res Im 2015; 33: 1224 – 1235
stenosis of pulmonary vessels	peak velocity, flow conditions (primarily poststenotic)	Chen SS et al. Int J Cardiol 2013; 168: 3698.3703

method with corresponding possible postinterventional complications. Echocardiographic determination of the pressure gradient is highly user-dependent and entails a low temporal and spatial resolution and a lack of ability to evaluate flow characteristics. The 2D-flow measurement currently most commonly used clinically can be performed more quickly and provides higher temporal resolution with better temporal averaging but requires exact planning of the measurement plane in advance and measures the flow only in one plane. 4D-flow measurement provides a non-invasive alternative. The advantage in comparison to pressure wire measurement is that not only vessel segments with an elevated pressure can be identified but the wall segment affected by the elevated pressure can also be visualized [23, 24]. It must be taken into consideration that the absolute pressure at a certain location in the vessel cannot be specified with 4D-flow measurement but pressure gradients and their change over time can be measured. A limitation is that the exact peak flow cannot be measured (for example due to blurring during acquisition in free breathing with or without a navigator).

### Pulse wave velocity

The pulse wave velocity is the most useful parameter for describing vessel wall elasticity. In addition, the progression of atherosclerosis can be documented. The field of view must be placed over the entire aorta to determine the pulse wave velocity. The velocity of the pulse wave can be determined in this way [25]. The pulse wave velocity in the aorta should be measured with a temporal resolution of 40 ms.

## 4D-flow measurement applications:

There are a plurality of application options and a detailed description thereof would exceed the limits of this overview. Therefore, the relevant literature is referenced as applicable.

### Aorta, pulmonary vessels, and heart valves:

4D-flow measurement offers the advantage that an anatomical representation as well as a functional characterization of the entire aorta can be performed noninvasively in a single examination. As a result, a broad range of pathologies can be identified. This includes aortic stenoses, pulmonary valve stenoses, aortic aneurysms, aortic dissections, congenital heart diseases, pulmonary hypertension, and stenoses of the pulmonary vessels. ► **Table 3** shows some examples and diseases whose pathological changes can be further clarified via 4D-flow measurement to determine the relevant parameters for the particular diagnosis and treatment.

The hope is that 4D-flow measurement can help to identify previously unknown pathomechanisms. A good example of this is the discovery that plaques in the descending aorta can cause a stroke. Therefore, 4D-flow measurement was able to show that a reverse flow within the thoracic aorta can occur during diastole in patients with atherosclerosis. In this way aortic plaques, particularly those with a thickness of >4 mm, became a previously unidentified source of embolism in cases of stroke [26, 27]. The WSS has become a topic of interest of various research groups. It stimulates arterial mechanotransduction. The changed mechani-

cal stress in the case of an elevated WSS modifies endothelial function [28], thereby inducing vascular remodeling [29]. A non-physiologically high stress on the vessel wall can result in inflammatory reactions and the formation of atherosclerotic plaques [30, 31]. A changed flow pattern can have a pronounced effect on the vascular system. Therefore, a focal change in the stress on the vessel wall can promote the formation of aneurysms [32, 33]. A connection between pulmonary hypertension and a change in flow characteristics as well as the WSS can also be shown [34]. A correlation between the duration of a vortex beneath the right pulmonary artery and the degree of excess pulmonary pressure is assumed [34].

### Congenital heart defects

Congenital heart defects have very different consequences for each person. Some patients remain asymptomatic for their entire lives, while others develop pronounced cyanosis soon after birth. 4D-flow measurement can help to identify these patients. It shows pathophysiological conditions. The physiological consequences of congenital heart defects expressed as abnormal flows and abnormal functioning of the ventricles and heart valves can also be detected [35]. Patients often require lifelong monitoring. Therefore, MRI is advantageous with respect to radiation hygiene. The long acquisition time must be taken into consideration as a limiting factor, but the alternatives also have significant disadvantages: catheter angiography is invasive, CT provides only anatomical information with relevant radiation exposure, and echocardiography provides only flow information and is highly user-dependent.

### Atrial fibrillation

The most common and most feared complication of atrial fibrillation is stroke. The currently used scores for predicting stroke risk are of limited value and are based on clinical parameters (age, sex, diabetes, smoker, etc.). A patient's individual risk for thrombus formation cannot be determined in this way. Patients with atrial fibrillation have slower flow in the left atrium or the left atrial appendage which are the most common thrombus formation locations [36, 37]. These predisposing flow conditions can be analyzed with 4D-flow measurement [38]. It must be mentioned as a limitation that 4D-flow measurement shows only a single cardiac cycle. Differences between two heartbeats, e. g. in arrhythmia, are not recorded with this method but can cause artifacts during image acquisition. Transesophageal echocardiography, which is used as a clinical reference method, requires sedation and subsequent monitoring.

### Coronary arteries

Visualizing coronary arteries and their flows with MRI presents a major challenge. Some working groups have managed to successfully visualize coronary arteries on MRI despite their small size, partially looped course and pronounced movement due to respiration and heartbeat [39, 40]. However, it is doubtful that this experimental success will be able to be applied to the clinical routine in the near future.

### Carotids

4D-flow measurement can be used to correlate the anatomy with the resulting flow characteristics in order to evaluate the relevance of atherosclerotic changes of the carotids regarding the risk of stroke. In this way complex helix flows can be visualized, and absolute velocities and the local wall shear stress can be calculated, with a correlation with the atherogenesis being assumed in each case [41].

### Intracranial vessels

With 4D-flow measurement it is possible to visualize the intracranial vessels, examine the arterial vessels in relation to aneurysms, atherosclerosis, and arteriovenous malformations and to visualize the veins. At present the most established method is 3D-TOF (time of flight) MR angiography. The advantage of this method is that it does not require the use of contrast agent, while the disadvantages include a high susceptibility to motion artifacts and overestimation of the degree of stenosis due to turbulent flows. Contrast-enhanced MR angiography does not have these disadvantages but requires the administration of contrast agent. Transcranial Doppler examination as an alternative is limited by its significant user dependence and spatially limited applicability. 4D-flow measurement is capable of visualizing the flows in the intracranial vessels as well as providing additional functional parameters without the administration of contrast agent in a user-independent manner. WSS changes at an aneurysm wall can cause an increase in size and rupture [14, 42]. Information regarding intra-aneurysmal flow and the current WSS acquired via 4D-flow measurement can be used for preinterventional classification [43, 44]. The particular difficulty regarding 4D-flow measurement of intracranial vessels is the need for an extremely high spatial resolution and the significant fluctuations in flow velocity [45].

### Liver vessels

The development of liver cirrhosis results in dramatic, multi-stage changes in blood flows in the arterial, venous, and portal systems and in the collateral circulation. With 4D-flow measurement, the flows in all of these vessels can be visualized in a single measurement [46].



## Renal vessels

The relevance of renal artery stenosis cannot be evaluated simply by measuring diameter. Using 4D-flow measurement, the renal arteries can be evaluated with an accuracy that correlates well with invasive measurement via pressure wires [46]. 4D-flow measurement is also a suitable method for examining patients before and after kidney transplantation.

## Intraabdominal vessels

4D flow measurement can help with the diagnosis of the causes of a (chronic) mesenteric ischemia since anatomical flow obstructions can be detected and their relevance can be analyzed. If 4D-flow measurement is performed before and after a meal, the changing flow conditions can be compared directly, and possible pathologies can be identified [46].

## Discussion

4D-flow measurement has some advantages compared to the already established methods for visualizing the cardiovascular system. The method allows anatomical and functional visualization of cardiovascular structures in a single measurement, thus making it possible to evaluate more than just vessel morphology. Based on amplitude images, the flow velocity and direction can be displayed visually and in a time-resolved manner. Qualitative and quantitative analysis can be retrospectively performed for every volume element. The method is noninvasive and does not involve the use of ionizing radiation. It is problematic to a certain extent that the user must possess detailed knowledge of the examination technique to generate high-quality images. Corresponding knowledge is also necessary for post-processing with dedicated software. A further disadvantage is that 4D-flow measurement has previously been limited to the visualization of large vessels. Anatomical vessel visualization is inferior to CT angiography and contrast-enhanced MR angiography with respect to spatial resolution. A comparably high spatial resolution would reduce the signal output per voxel too greatly in 4D-flow measurement to be able to obtain usable datasets. Depending on the issue, combining 4D-flow measurement without additional radiation exposure with high-resolution contrast-enhanced MR angiography can be considered. Of course, the usual contraindications for MRI examination must be taken into consideration.

The fast technical progress in the development of new MRI technologies in recent years has made it possible to reduce scan times so that the technique has become clinically applicable and has even been incorporated into the clinical routine for some medical issues. 4D-flow measurement has become well established primarily for visualizing anatomical conditions and flow characteristics in congenital heart diseases. When examining the aorta, the technique is clinically indicated for the clarification of flow conditions in aortic

dissection for the various lumina and the large branches, while the determination of complex parameters, such as wall shear stress, is used for scientific approaches for evaluating prognosis. Some additional possible clinical applications are described in the article. The time-resolved 3D datasets of 4D-flow measurement provide extensive information that can be used to determine a number of parameters for analyzing flow velocity, flow volume, flow characteristics, and even relative pressure conditions. Since the calculation and analysis of all parameters is very time-consuming and is not necessary for every clinical and scientific issue, the parameters that are most helpful for answering the clinical or scientific question are to be determined in as targeted a manner as possible. The value of various complex parameters should be examined in larger studies regarding clinical usability. This results in challenges for the clinical and scientific user: Since there are no standardized evaluation methods, a detailed examination of the available software or the modification thereof is necessary.

MRI-guided 4D-flow measurement has the potential to help clarify the underlying pathomechanisms of cardiovascular diseases before they become clinically relevant. This requires additional clinical studies on healthy subjects and patient populations. Two highly relevant issues include the prediction of the development of problematic plaques at the carotid bifurcation prior to stroke and the prediction of the progression of an aortic aneurysm prior to rupture.

The availability of the technique is currently still limited. While pulse sequences allowing the implementation of 4D-flow measurement are available for many MR scanners, powerful acceleration techniques such as compressed sensing and an efficient undersampling method for data acquisition of the k-space are only available in a small percentage of the latest MRI units. Further development of post-processing software which is currently only offered by a couple of highly specialized companies or developed inhouse at various research institutes can be expected in the near future. Post-processing is often very time-consuming and can only be used clinically for certain complex parameters. In contrast, simple parameters such as flow velocity and flow volume can be determined very quickly. MRI manufacturers currently do not offer any 4D-flow measurement software for broad clinical application. Further development of post-processing in a form allowing use in a uniform workflow would be desirable. It is also necessary to establish standardized analysis methods with limit values for various parameters allowing a differentiation between pathological and healthy in order to obtain reproducible and comparable results.

In summary, as a result of technical advancements, 4D-flow measurement has developed the potential in recent years to be used in the clinical routine for certain medical issues. However, the method can be further developed by improving spatial resolution, increasing the signal output, and shortening the measurement time. While numerous applications and the determination

of various sometimes complex parameters are currently still limited to scientific issues, clinical studies with larger patient populations will result in additional clinical indications and increased use of MRI-supported 4D-flow measurement for clinical purposes can be expected in the future. Additional research is needed to evaluate newly established parameters. The hope is that 4D-flow measurement can be used to understand the underlying pathomechanisms of cardiovascular diseases, to detect consecutive pathologies prior to clinical manifestation, and to provide a prognostic evaluation.

### Conflict of Interest

The authors declare that they have no conflict of interest.

### References

- [1] Dyverfeldt P et al. 4D flow cardiovascular magnetic resonance consensus statement. *J Cardiovasc Mag Res* 2015; 17: 72
- [2] François CJ, Markl M, Schiebler ML et al. Four-dimensional, flow-sensitive magnetic resonance imaging of blood flow patterns in thoracic aortic dissections. *Eur Radiol* 2012; 22:1122–30
- [3] Johnson KM, Markl M. Improved SNR in phase contrast velocimetry with five-point balanced flow encoding. *Mag Res MEd* 2010; 63: 349–355
- [4] Uribe S, Beerbaum P, Sorensen TS et al. Four-dimensional (4D) flow of the whole heart and great vessels using real-time respiratory self-gating. *Magn Reson Med* 2009; 62: 984–992
- [5] Bernstein MA, Zhou XJ, Polzin JA et al. Concomitant gradient terms in phase contrast MR: analysis and correction. *Mag Res Med* 1998; 39: 300–308
- [6] Abdul-Rahman HS et al. Fast and robust three-dimensional best path phase unwrapping algorithm. *Appl Opt* 2007; 46: 6623–6635
- [7] Ha H et al. Hemodynamic Measurement Using Four-Dimensional Phase-Contrast MRI: Quantification of Hemodynamic Parameters and Clinical Applications. *Korean Journal of Radiology* 2016; 17: 445–462
- [8] Bagan P et al. Cerebral ischemia during carotid artery cross-clamping: predictive value of phase-contrast magnetic resonance imaging. *Ann Vasc Surg* 2006; 20: 747–752
- [9] Hope T et al. Evaluation of intracranial stenoses and aneurysms with accelerated 4D flow. *Mag Res Imag* 2010; 28: 41–46
- [10] Ku DN, Giddens DP, Zarins CK et al. Pulsatile flow and atherosclerosis in the human carotid bifurcation. Positive correlation between plaque location and low oscillating shear stress. *Arteriosclerosis* 1985; 5: 293–302
- [11] Guzzardi DG et al. Valve-Related Hemodynamics Mediate Human Bicuspid Aortopathy: Insights From Wall Shear Stress Mapping. *J Am Col Cardiol* 2015; 66: 892–900
- [12] Barker AJ et al. Bicuspid aortic valve is associated with altered wall shear stress in the ascending aorta. *Circ Cardiovasc Imag* 2012; 5: 457–466
- [13] Bissel MM et al. Concomitant gradient terms in phase contrast MR: analysis and correction. *Circ Cardiovasc Imag* 2013; 6: 499–507
- [14] van Ooij P, Potters WV, Guédon A et al. Wall shear stress estimated with phase contrast MRI in an in vitro and in vivo intracranial aneurysm. *J Magn Res Imag* 2013; 38: 876–884
- [15] Isoda H, Ohkura Y, Kosugi T et al. In vivo hemodynamic analysis of intracranial aneurysms obtained by magnetic resonance fluid dynamics (MRFD) based on time-resolved three-dimensional phase-contrast MRI. *Neuroradiology* 2010; 52: 921–928
- [16] Dyverfeldt P, Gårdhagen R, Sigfridsson A et al. On MRI turbulence quantification. *Mag Res Imag* 2009; 27: 913–922
- [17] Zajac J, Eriksson J, Dyverfeldt P et al. Turbulent kinetic energy in normal and myopathic left ventricles. *J Mag Res Imag* 2015; 41: 1021–1029
- [18] Wong KK, Kelso RM, Worthley SG et al. Cardiac flow analysis applied to phase contrast magnetic resonance imaging of the heart. *Ann Biomed Eng* 2009; 37: 1495–1515
- [19] Elbaz MS et al. Vortex flow during early and late left ventricular filling in normal subjects: quantitative characterization using retrospectively-gated 4D flow cardiovascular magnetic resonance and three-dimensional vortex core analysis. *J Cardiovasc Mag Res* 2014. doi:10.1186/s12968-014-0078-9
- [20] Manka R, Busch J, Crelier G et al. Pre- and post-operative assessment of valvular and aortic flow using 4D flow magnetic resonance imaging. *Eur Heart J* 2013; 34: 1423
- [21] Curiie PJ, Seward JB, Reeder GS et al. Continuous-wave Doppler echocardiographic assessment of severity of calcific aortic stenosis: a simultaneous Doppler-catheter correlative study in 100 adult patients. *Circulation* 1985; 71: 1162–1169
- [22] Cohn JN, Quyyumi AA, Hollenberg NK et al. Surrogate markers for cardiovascular disease: functional markers. *Circulation* 2004. doi:10.1161/01.CIR.0000133442.99186.39
- [23] Bley TA et al. Noninvasive assessment of transstenotic pressure gradients in porcine renal artery stenoses by using vastly undersampled phase-contrast MR angiography. *Radiology* 2011; 261: 266–273
- [24] Lum DP, Johnson KM, Paul RK et al. Transstenotic pressure gradients: measurement in swine—retrospectively ECG-gated 3D phase-contrast MR angiography versus endovascular pressure-sensing guidewires. *Radiology* 2007; 245: 751–760
- [25] Wentland AL, Wieben O, François CJ et al. Aortic pulse wave velocity measurements with undersampled 4D flow-sensitive MRI: comparison with 2D and algorithm determination. *J Magn Res Im* 2013; 37: 853–859
- [26] Bogren HG, Mohiaddin RH, Kilner PJ et al. Blood flow patterns in the thoracic aorta studied with three-directional MR velocity mapping: the effects of age and coronary artery disease. *J Mag Res IM* 1997; 7: 784–793
- [27] Harloff A, Strecker C, Frydrychowicz AP et al. Plaques in the descending aorta: a new risk factor for stroke? Visualization of potential embolization pathways by 4D MRI. *J Mag Res Imag* 2007; 26: 1651–1655
- [28] Sträter A, Korte S et al. Feedforward activation of endothelial ENaC by high sodium. *FASEB* 2014; 28: 4015–4025
- [29] Mahadevia R, Barker AJ, Schnell S et al. Bicuspid aortic cusp fusion morphology alters aortic three-dimensional outflow patterns, wall shear stress, and expression of aortopathy. *Circulation* 2014; 129: 673–682
- [30] Ku DN, Giddens DP, Zarins CK et al. Pulsatile flow and atherosclerosis in the human carotid bifurcation. Positive correlation between plaque location and low oscillating shear stress. *Arteriosclerosis* 1985; 5: 293–302
- [31] Slager CJ, Wentzel JJ, Gijzen FJ et al. The role of shear stress in the destabilization of vulnerable plaques and related therapeutic implications. *Nat Clin Pract Cardiovasc Med* 2005; 2: 456–464
- [32] Monarrriz PM, Gomez PA, Paredes I et al. Basic Principles of Hemodynamics an cerebral Aneurysms. *World Neurosurg* 2016; 88: 311–319
- [33] Tanweer O, Wilson TA, Metaxa E et al. A comparative review of the hemodynamics and pathogenesis of cerebral and abdominal aortic aneurysms: lessons to learn from each other. *J Cerebrovasc Endovasc Neurosurg* 2014; 16: 335–349
- [34] Reiter U, Reiter G, Kovacs G et al. Evaluation of elevated mean pulmonary arterial pressure based on magnetic resonance 4D velocity mapping: comparison of visualization techniques. *PLoS One* 2013; 8: e82212
- [35] Vasanawala SS, Hanneman K, Alley MT et al. Congenital heart disease assesment with 4D flow MRI. *J Mag Res Imag* 2015; 42: 870–886

- [36] Goldmann ME, Pearce LA, Hart RG et al. Pathophysiologic correlates of thromboembolism in nonvalvular atrial fibrillation: Reduces flow velocity in the left atrial appendage. *J Am Soc Echocardiogr* 1999; 12: 1080–1087
- [37] Handke M, Harloff A, Hetzel A et al. Left atrial appendage flow velocity as a qualitative surrogate parameter for thromboembolic risk: determinants and relationship to spontaneous echocontrast and thrombus formation—a transoesophageal echocardiographic study in 500 patients with cerebral isch. *J Am Soc Echocardiogr* 2005; 18: 1366–1372
- [38] Lee DC, Goldberger JJ, Fluckiger J et al. Analysis of left atrial flow velocity distribution in 4D flow MRI in patients with atrial fibrillation. *Circulation* 2013; 128: A17900
- [39] Saito Y, Sakuma H, Shibata M et al. Assessment of coronary flow velocity reserve using fast velocity encoded cine MRI for noninvasive detection of restenosis after coronary stent implantation. *J Cardiovasc Mag Reson* 2001; 3: 209–214
- [40] Nagel E, Thouet T, Klein C et al. Noninvasive determination of coronary blood flow velocity with cardiovascular magnetic resonance in patients after stent deployment. *Circulation* 2003; 107: 1738–1702
- [41] Harloff A, Markl M, Frydrychowicz A et al. Diagnostik von Schlaganfallursachen. *Der Nervenarzt* 2009; 80: 929–940
- [42] Rayz VL, Bousset L, Ge L et al. Flow residence time and regions of intraluminal thrombus deposition in intracranial aneurysms. *Ann Biomed Eng* 2010; 38: 3058–3069
- [43] Isolda H, Olikura Y, Kosugi T et al. In vivo haemodynamic analysis of intracranial aneurysms obtained by magnetic resonance fluid dynamics (MRFD) based on time-resolved three-dimensional phasecontrast MRI. *Neuroradiology* 2010; 52: 921–928
- [44] Hope TA, Hope MD, Purcell DD et al. Evaluation of intracranial stenoses and aneurysms with accelerated 4D flow. *Mag Res Imaging* 2010; 28: 41–46
- [45] Markl M, Lee DC, Ng J et al. Left atrial 4-dimensional flow magnetic resonance imaging: stasis and velocity mapping in patients with atrial fibrillation. *Invest Radiol* 2016; 51: 147–154
- [46] Roland-Alzate A, Francois CJ, Wieben O et al. Emerging Applications of Abdominal 4D Flow MRI. *Am J Roentgenol* 2017