

# Importance and Qualitative Requirements of Magnetic Resonance Imaging for Therapy Planning in Rectal Cancer – Interdisciplinary Recommendations of AIO, ARO, ACO and the German Radiological Society

## Stellenwert und qualitative Voraussetzungen der Magnetresonanztomografie (MRT) für die Therapieplanung beim Rektumkarzinom – Interdisziplinäre Empfehlungen der AIO, ARO, ACO und der Deutschen Röntgengesellschaft

### Authors

Ulrike Irmgard Attenberger<sup>1</sup>, Stephan Clasen<sup>2</sup>, Michael Ghadimi<sup>3</sup>, Ulrich Grosse<sup>4</sup>, Gerald Antoch<sup>5</sup>, Andreas G. Schreyer<sup>6</sup>, Johannes Wessling<sup>7</sup>, Daniel Hausmann<sup>8</sup>, Pompiliu Piso<sup>9</sup>, Verena Plodeck<sup>10</sup>, Sebastian Stintzing<sup>11</sup>, Claus Michael Rödel<sup>12</sup>, Ralf Dieter Hofheinz<sup>13</sup>

### Affiliations

- 1 Department of Diagnostic and Interventional Radiology, University Hospital Bonn, Germany
- 2 Department of Radiology, Hospital Reutlingen, Reutlingen, Germany
- 3 Clinic for Surgery, University Hospital Göttingen, Göttingen, Germany
- 4 Department of Radiology, Cantonal Hospital Münsterlingen, Münsterlingen, Switzerland
- 5 President, German Radiological Society, Berlin, Germany
- 6 Institute for Diagnostic and Interventional Radiology, Brandenburg Medical School Theodor Fontane, Brandenburg a. d. Havel, Germany
- 7 Department of Diagnostic and Interventional Radiology and Neuroradiology, Clemenshospital GmbH Münster, Germany
- 8 Department of Radiology, Baden Cantonal Hospital, Baden, Switzerland
- 9 Clinic for General and Visceral Surgery, Barmherzige Brüder Hospital Regensburg, Germany
- 10 Institute and Polyclinic for Diagnostic and Interventional Radiology, University Hospital Carl Gustav Carus, Dresden, Germany
- 11 Division of Hematology, Oncology and Tumor Immunology, Charité, Medical Department, Berlin, Germany
- 12 Department of Radiotherapy and Oncology, University Hospital Frankfurt, Frankfurt am Main, Germany
- 13 III Medical Clinic, Day Therapy Centre, Medical Faculty of the University of Heidelberg, Mannheim, Germany

### Key words

MRI, CRM, therapeutic stratification, rectal cancer

received 25.05.2020

accepted 24.09.2020

published online 16.12.2020

### Bibliography

Fortschr Röntgenstr 2021; 193: 513–520

DOI 10.1055/a-1299-1807

ISSN 1438-9029

© 2020, Thieme. All rights reserved.

Georg Thieme Verlag KG, Rüdigerstraße 14, 70469 Stuttgart, Germany

### Correspondence

Prof. Ulrike Irmgard Attenberger

Department of Diagnostic and Interventional Radiology, University Hospital Bonn, Venusberg-Campus 1, 53127 Bonn, Germany

Tel.: +49/2 28/28 71 58 71

ulrike.attenberger@ukbonn.de

### ABSTRACT

Due to its excellent intrinsic soft tissue contrast, magnetic resonance imaging allows excellent visualization and anatomical separation of therapy-relevant risk structures such as the mesorectal fascia, local lymph nodes, and vascular structures in patients with rectal carcinoma. This makes magnetic resonance imaging (MRI) a valuable evaluation method for further therapeutic stratification. In particular, MRI is indispensable for the decision to refrain from neoadjuvant therapy and to choose a primary surgical approach. In addition to the oncologically generally relevant T-, N-, and M-criteria, two further parameters are included: the extramural vascular infiltration and the circumferential resection margin. Due to the significant impact of MRI on further therapeutic decision-making, standardized MR image quality is considered essential.

**Key Points:**

- Magnetic resonance imaging is a valuable evaluation method for further therapeutic stratification.
- Critical anatomic landmarks for evaluation are circumferential resection margins.

**Citation Format**

- Attenberger UI, Clasen S, Ghadimi M et al. Importance and Qualitative Requirements of Magnetic Resonance Imaging for Therapy Planning in Rectal Cancer – Interdisciplinary Recommendations of AIO, ARO, ACO and the German Radiological Society. *Fortschr Röntgenstr* 2021; 193: 513–520

**ZUSAMMENFASSUNG**

Die Magnetresonanztomografie (MRT) erlaubt aufgrund ihres ausgezeichneten intrinsischen Weichteilkontrastes bei Patienten

mit Rektumkarzinom eine hervorragende Darstellung und anatomische Separation therapie-relevanter Risikostrukturen wie der mesorektalen Faszie, lokaler Lymphknoten und benachbarter Organe. Dies macht die MRT zu einer wertvollen Bewertungsmethode für die therapeutische Stratifizierung. Insbesondere ist die MRT unverzichtbar für die Entscheidung für den Verzicht auf eine neoadjuvante Therapie und die Wahl eines primär operativen Vorgehens. Neben den onkologisch allgemein relevanten T-, N- und M-Kriterien finden 2 weitere Parameter Eingang: die extramurale Gefäßinfiltration und der zirkumferenzielle Resektionsrand. Aufgrund des wesentlichen Einflusses des MRTs auf die therapeutische Entscheidungsfindung ist eine flächendeckende, standardisierte Bildqualität essenziell.

**Introduction**

Today, optimized imaging makes it possible to offer treatment to rectal cancer patients in a significantly more differentiated manner. Moreover, the two prospective randomized studies that will soon be initiated by the German Rectal Study Group are based on detailed magnetic resonance imaging (MRI) diagnosis. Patients are assigned according to MRI staging to different study concepts which stipulate either intensification of neoadjuvant therapy in terms of total neoadjuvant therapy (ACO/ARO/AIO 18.1 study, see ► **Fig. 1**) in patients with a high risk for recurrence or de-escalation of local therapy in the case of a low risk of local recurrence (ACO/ARO/AIO 18.2, see ► **Fig. 2**). In the following, data on the MRI examination of rectal carcinoma are summarized to provide answers to various questions and useful suggestions for quality-assured MRI diagnostics.

**Technical requirements**

The excellent intrinsic soft tissue contrast of MRI allows outstanding visualization and anatomical separation of treatment-relevant risk structures like the mesorectal fascia (MRF), local lymph nodes, vascular structures, and adjacent organs in patients with newly diagnosed rectal cancer. This makes MRI a valuable evaluation method for further therapeutic stratification [1], particularly for deciding between a primary surgical approach and neoadjuvant treatment measures.

**Preparing for the examination**

The value of filling the rectum with ultrasound gel has not yet been clarified. While in some centers filling of the ampulla of the rectum with ultrasound gel is the clinical standard, there are those who feel that this falsifies the evaluation of the position of the tumor in relation to the MRF due to the compressive effect of the gel on the rectal wall tumor [2, 3]. To date, no general recommendation can be given. The administration of spasmolytics prior to

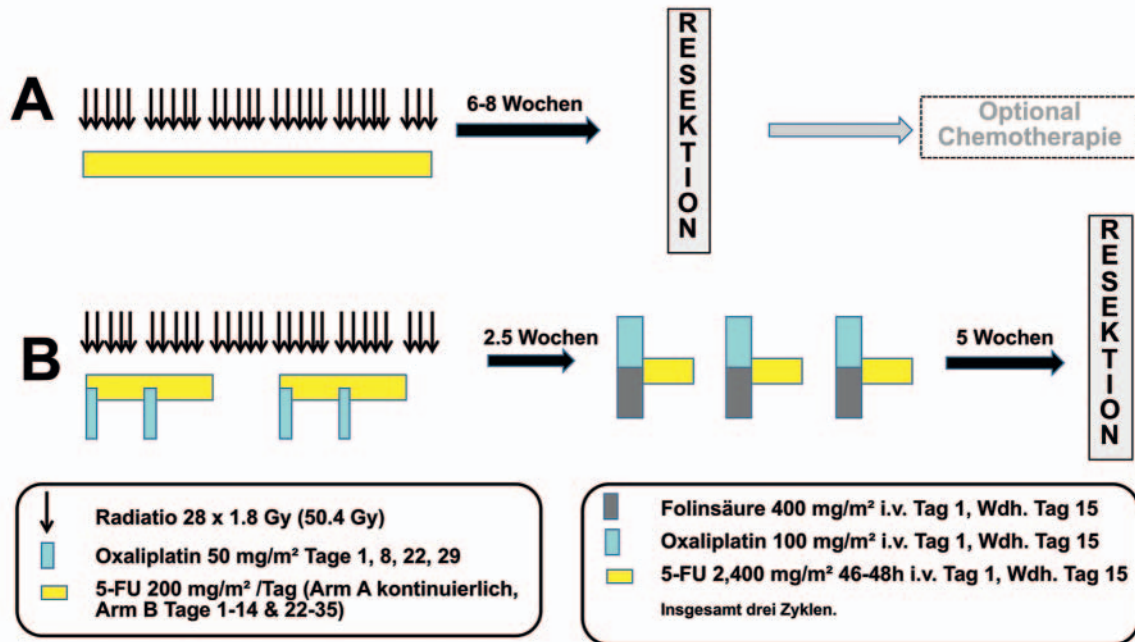
the examination to prevent peristalsis from affecting the diagnostic accuracy is recommended even though there is no general consensus here [4]. In the ACO/ARO/AIO studies 18.1 and 18.2, a dose of 20 mg butylscopolamine for patients with a body weight < 90 kg and 40 mg for patients with a body weight > 90 kg administered approx. 20 minutes prior to the examination to reduce peristalsis is recommended [5].

**MRI protocol**

For the quality-assured use of MRI for treatment stratification based on defined criteria (distance from the MRF, T-stage, extramural vascular invasion (EMVI), L-stage) in rectal cancer, minimum data acquisition requirements must be met. MRI field strength is an important factor in ensuring sufficiently high spatial resolution of risk structures. As a result of the increasing availability of MRI systems with a field strength > 1.0 Tesla, these risk structures can be imaged with a relatively high spatial resolution. Using 3 Tesla MRI systems, which is currently the most widely available field strength in clinical practice, a matrix size of 320 × 301 with a field of view (FOV) of 200 × 200 mm<sup>2</sup> can be achieved. This allows exact determination of the distance of the tumor from the mesorectal fascia and thus the most exact evaluation of the circumferential resection margin (CRM) that is possible using the available diagnostic methods [1, 6]. In addition to the relation of the tumor to the MRF, the spatial resolution is also a basic requirement for the evaluation of the presence of lymph node metastases and EMVI.

The acquisition of high-resolution T2-weighted sequences on three planes (transverse, coronal, sagittal) is recommended as the routine protocol and should be oriented to the axis of the tumor [7, 8]: In the case of tumors in the middle third of the rectum, axial and coronal views should be oriented to the axis of the tumor, while in tumors in the lower third of the rectum, the coronal sequence should be parallel to the axis of the anal canal to be able to better evaluate infiltration of the anal canal.

## German Rectal Cancer Study Group ACO/ARO/AIO 18.1 Studie



► **Fig. 1** ACO/ARO/AIO 18.1 Studie: Randomized comparison of neoadjuvant 5-FU or capecitabine-based radiochemotherapy with oxaliplatin-based “total neoadjuvant therapy”. Inclusion criteria: Carcinomas in the lower or middle third and presence of at least one of the following criteria: (i) each cT3 in the lower third, (ii) each cT3c/d in the middle third (i. e. infiltration over 5 mm), (iii) each cT3 with clear lymph node involvement, (iv) each cT4, (v) mrCRM positivity, (vi) EMVI positivity; ACO = Association of Surgical Oncology, AIO = Association of Internal Oncology, ARO = Association of Radiooncology, FU = Fluorouracil, Gy = Gray; own representation for the application of the 18.1 and 18.2 study.

By imaging on multiple planes, it is possible to evaluate additional structures that are essential for determining the therapeutic approach and predicting the outcome, including: the level of the tumor, involvement of the peritoneal fold, the infiltration of local structures like the levator sling, primarily in the case of a low rectal cancer, into organs in the lesser pelvis, and the presence of lymph node metastases [8]. ► **Table 1** provides a summary of the sequence parameters as recommended as a minimum consensus in the above-mentioned studies of the German Rectal Cancer Study Group. After initial anatomical localization of the rectum in survey sequences, sagittal T2w TSE (Turbo Spin Echo) is most important for planning (angulation on the axis of the tumor in the distal middle third of the MRI scan). Modern 3 T MRI allows the acquisition of 3 D sequences allowing reconstruction in all spatial directions so that primary image data acquisition is performed on only one plane. The data from the MERCURY Study Group (n = 679) show that the location of the tumor in relation to the MRF can be determined with an accuracy of 92.5% if MRI is performed correctly [6]. In contrast, Al-Sukhni E et al. report a sensitivity of 77% and a specificity of 94% for CRM involvement using MRI (n = 986) [9].

T2w TSE sequences are needed for the evaluation of the T-stage (best identification of the l. muscularis propria), the

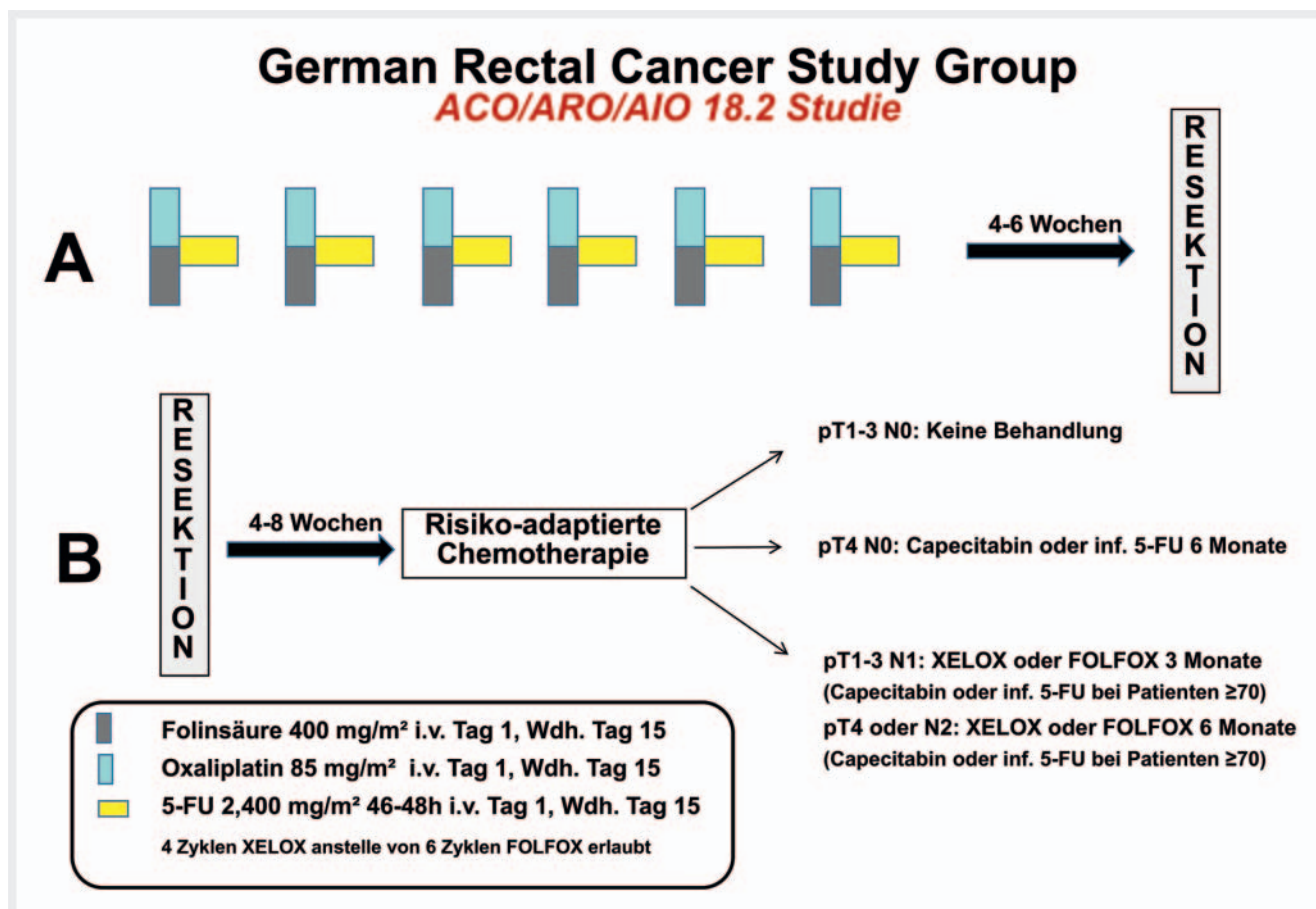
CRM, and EMVI, and for the evaluation of treatment response after radiochemotherapy (RChT).

Diffusion-weighted imaging (DWI) facilitates tumor detection, and treatment response can be evaluated by changing the apparent diffusion coefficient. DWI is suitable only on a limited basis for the evaluation of local lymph nodes. The protocol shown here represents the minimum standard used in the ACO/ARO/AIO studies. There are approaches that supplement the rectum protocol with T1w sequences +/- contrast agent with the goal of facilitating the identification of mucinous tumors and for the planning of radiation therapy.

### Value of MRI criteria for the treatment of rectal cancer

#### T-stage

The T-stage describes the local tumor extent in relation to the muscularis propria. A T3 tumor is present when the tumor has already invaded through the muscularis propria (MP) and has spread to the subserosa or the fat tissue. The tumor spread beyond the MP is <1 mm in the case of a T3a tumor and >1–5 mm



► **Fig. 2** ACO/ARO/AIO 18.2 Study: Randomized comparison of neoadjuvant chemotherapy with FOLFOX or XELOX with immediate surgery in patients with a low risk of local recurrence. Inclusion criteria: Lower third (0–6 cm): cT1/2 with clear nodal involvement if CRM negative and no EMVI; middle third ( $\geq 6$ –12 cm): cT1/2 with clear nodal involvement and cT3a/b (i. e. infiltration into perirectal fat  $\leq 5$  mm) if CRM negative, no clear nodal involvement and no EMVI; upper third ( $\geq 12$ –16 cm): cT1/2 with clear nodal involvement; each cT3–4 carcinoma, independent of nodal status. ACO = Association of Surgical Oncology, AIO = Association of Internal Oncology, ARO = Association of Radiooncology, XELOX: capecitabin/oxaliplatin; FOLFOX: 5-fluorouracil, folinic acid, oxaliplatin; own representation; own representation for the application of the 18.1 and 18.2 study.

in stage T3b [8]. The German S3 Guidelines recommend neoadjuvant RChT as soon as the perirectal, i. e., mesorectal, fat tissue has been infiltrated or the tumor has invaded through the muscularis propria [10]. A deviation from this approach is described for tumors whose infiltration into the perirectal fat tissue does not exceed 5 mm (i. e., T3a or T3b tumors) [10]. If additional criteria (adequate quality assurance regarding imaging and surgery, no EMVI, no lymph node involvement, no MRF involvement) are met, a primary surgical approach can be selected [10]. To date, MRI is superior to every other imaging method with respect to the determination of depth of tumor infiltration in the case of tumors with a stage higher than T2.

### Circumferential resection margin

In total mesorectal excision (TME), tumor resection is performed along the MRF. If the distance of the tumor from the MRF is less than 1 mm on MRI or the tumor has infiltrated the MRF, primary resection is not oncologically recommended due to the high rate

of local recurrence. An exact evaluation of the CRM, which is anatomically defined by the MRF, is therefore a significant therapy-determining criterion. ► **Fig. 3** illustrates the infiltration of the MRF by the tumor (► **Fig. 3**).

### Extramural vascular invasion

A further negative prognostic factor is the presence of EMVI. EMVI describes tumor invasion into local vessels. Primarily the dilatation of local vessels  $> 3$  mm and an alteration of the flow signal are considered criteria for the presence of EMVI [8]. Zhang et al. showed that the presence of EMVI is a significant risk factor for recurrence (local recurrence, metastases, and overall survival) [11]. The EMVI location is primarily associated with the probability of recurrence. Particularly when an EMVI is found in the upper third of the rectum, there is a significant difference with respect to the criteria vessel diameter and number of infiltrated vessels ( $p = 0.01$ ) [11].

► **Table 1** Overview of the MRI protocol of the current ACO/ARO/AIO studies (18.1 and 18.2).

sequence	slice orientation	TR/TE (ms)	slice thickness (mm)	number of slices	Dist. factor	FOV	matrix	voxel size (mm <sup>3</sup> )	acquisition time (min:s)
T2w HASTE	coronal	400/92	6	24		420	256 × 256	1.6 × 1.6 × 1.6	0:22
T2w TSE	sagittal	4700/100	3 (max)	40	10	320	384 × 384	0.8 × 0.8 × 3	2:04
T2w TSE	axial	5600/110	3 (max)	50	10	200	310 × 320	0.8 × 0.8 × 3	2:26
T2w TSE	axial		3 (max)			160	256 × 256		
T2w TSE	coronal	5850/91	3 (max)	50	10	250	310 × 384		3:20
EPI DWI	axial	6500/76	5 (max)	50	0	350	192 × 192	1.8 × 1.8 × 4	4:14
b = 50/400/800									

DWI = diffusion-weighted imaging, EPI = echo planar imaging, FOV = field of view, HASTE = Half Fourier-Acquired Single Shot Turbo Spin Echo, TE = echo time, TR = repetition time, TSE = turbo spin echo.

► **Table 2** Relevant diagnostic criteria for the evaluation of rectal cancer according to the structured diagnostic template of the German Radiological Society [13].

sites of manifestation	diagnostic criteria
primary tumor	<ul style="list-style-type: none"> <li>▪ tumor location</li> <li>▪ distance from anocutaneous line</li> <li>▪ tumor extent (length)</li> <li>▪ circumference in SSL</li> <li>▪ tumor infiltration</li> <li>▪ distance from mesorectal fascia (CRM)</li> <li>▪ vascular invasion (EMVI)</li> </ul>
lymph node local	<ul style="list-style-type: none"> <li>▪ mesorectal/presacral</li> <li>▪ distance from mesorectal fascia (CRM)</li> </ul>
distant metastases	<ul style="list-style-type: none"> <li>▪ lymph node extramesorectal</li> <li>▪ ascites</li> <li>▪ peritoneum</li> <li>▪ pelvic structures</li> <li>▪ skeleton</li> </ul>

CRM = circumferential resection margin, EMVI = extramural vascular invasion, SSL = lithotomy position.

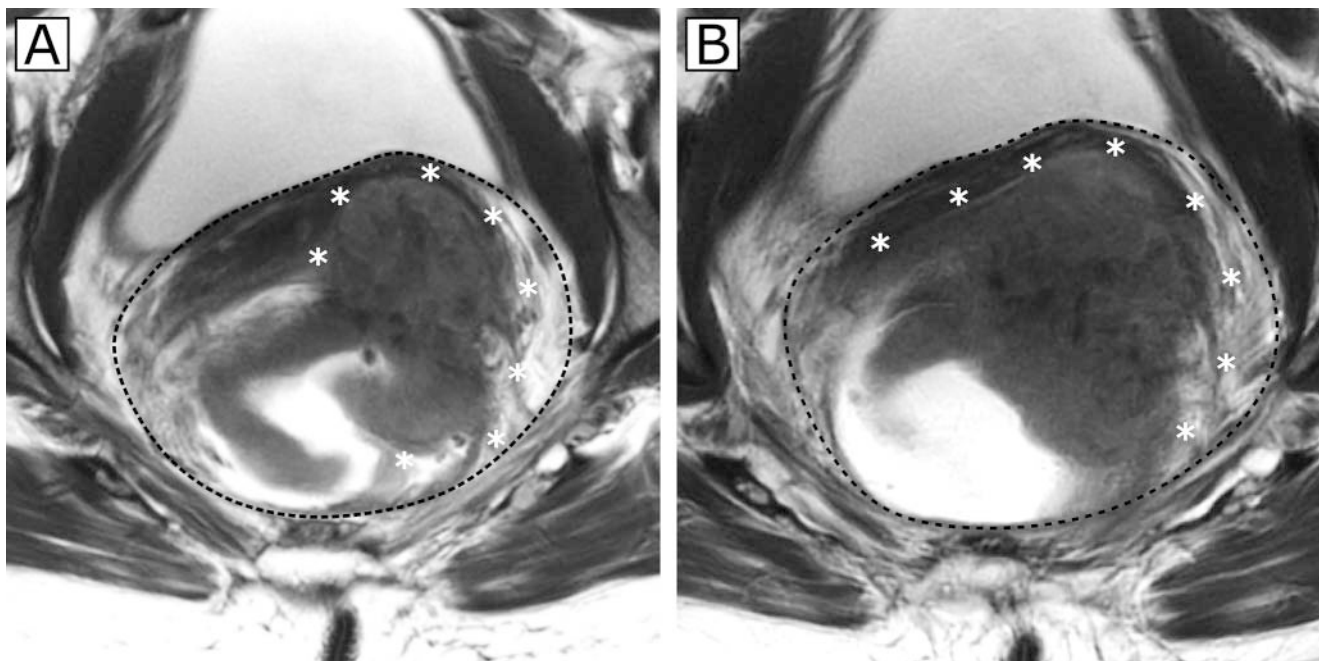
## Lymph node

Lymph node metastases are a further prognostic factor. However, there is greater uncertainty when evaluating them compared to the MRF [12]. In the most recent S3 Guidelines, the currently available diagnostic methods (endoluminal ultrasound, computed tomography, MRI [12]) for lymph nodes have sensitivities of 55–75% and specificities of 74–78% [10]. In this regard, the differential diagnosis between reactive lymph nodes and lymph node metastases is particularly difficult [8, 10]. The use of lymph node size as a criterion for lymph node positivity is highly limited here. However, if additional evaluation criteria like shape, margin, and signal intensity characteristics of lymph nodes are used in addition to size, the accuracy of MRI can be increased to up to 85% [8]. The criteria for positive lymph nodes are as follows: A lymph node is considered suspicious when

- a) It has a short-axis diameter of >9 mm or
- b) The diameter is 5–9 mm and at least two of the following criteria apply: round shape, irregular margin, heterogeneous signal or
- c) The diameter is <5 mm and it has a round shape, an irregular margin, and a heterogeneous signal [4].

► **Fig. 4** illustrates a suspicious local lymph node in primary staging (cN+).

The diagnostic criteria needed for further therapeutic stratification should be taken into account in a structured diagnostic re-



► **Fig. 3** shows two axial T2w images of the rectum of a patient with rectal carcinoma in two directly subsequent layers **a, b** at the level of the middle rectum to better visualize the tumor extension. The semi-annular tumor expands at a maximum of 10–5 o'clock SSL (the exact extent is marked with \*) **b**. Ventrolateral left the adventitia is penetrated **b**. This indicates a cT3 stage. The tumor protrusions reach the MRF, which is demarcated by the black dotted line, with a distance of <1 mm. The CRM is therefore considered positive. MRF = mesorectal fascia, SSL = lithotomy position.

port [13]. ► **Table 2** summarizes the relevant diagnostic criteria for the evaluation of rectal cancer.

Based on MRI criteria, it is increasingly possible to identify risk factors beyond the classic (clinical) UICC classification that allow escalation or de-escalation of neoadjuvant therapy and thus challenge the current standard of performing neoadjuvant therapy for all tumors in stages II and III. To facilitate treatment decisions and to allow differentiated risk-adapted therapeutic approaches, a classification system with four treatment-relevant clinical subcategories is proposed [14]. A recently published treatment algorithm identifies four risk groups:

1. *Very early-stage cancers (cT1sm1 / sm2 low risk G1/2, N0)*: Local excision via transanal endoscopic microsurgery (TEM); only in the case of negative prognostic factors (sm3, high-risk grading [G3/4], T2, V1)  
MRI is not used for the diagnosis of very early-stage cancer. Diagnosis is performed endoscopically.
2. *Early-stage cancers (cT1–2, cT3a/b in the middle or upper third, cN0, cN1 in the upper third, CRM in MRI negative, no EMVI)*  
The main information provided by MRI in this regard is evaluation of the CRM, EMVI, and the lymph node situation. This applies in a similar manner for risk groups 3 and 4.
3. *Intermediate-stage cancers (cT2 ultra-deep, cT3b/c and d, CRM negative after MRI evaluation, cT4a with low peritoneal infiltration, every N, EMVI)*

4. *Locally advanced cancers (cT3, CRM positive after MRI evaluation, cT4a/b, iliac lymph node metastases)*

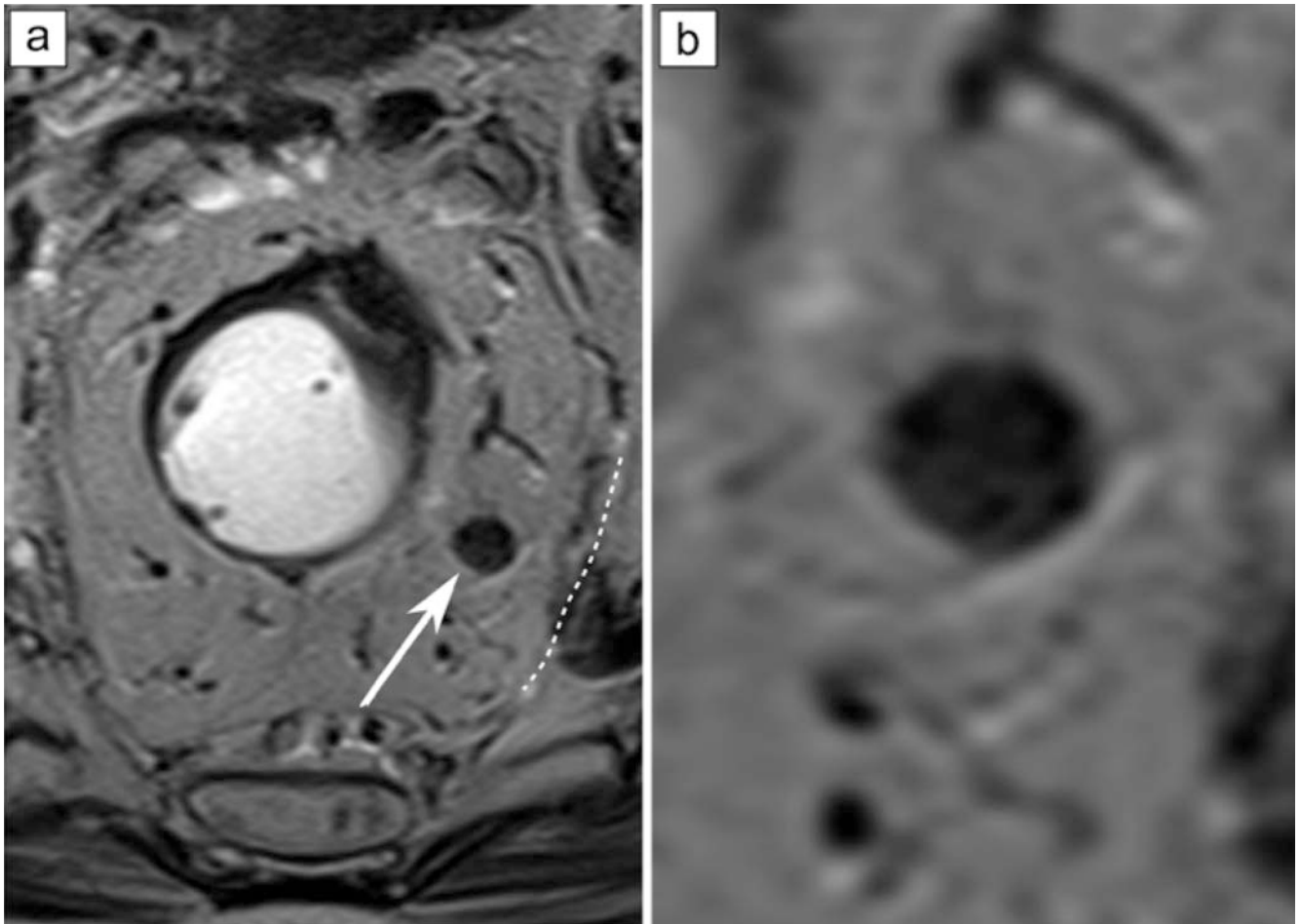
In addition to evaluation of the CRM, EMVI, and the local perimesorectal lymph node situation, the added benefit of MRI in this case is the evaluation of the iliac lymph nodes.

Based on such a classification, it will be possible in the future to develop optimized treatment concepts as part of dedicated study concepts that stipulate either de-escalation (e.g. in terms of avoiding radiation therapy of tumors in group 2) or intensification of neoadjuvant radiochemotherapy in groups 3 and 4.

## Summary

To allow a quick therapeutic decision process, treatment- or prognosis-relevant structures should be evaluated in a stratified manner. In tumors, this includes T-stage classification under consideration of the T3 subgroups (early-stage T3 a/b vs. late-stage T3 c/d) and evaluation of the mesorectal fascia, the depth of infiltration into the perirectal fat tissue, EMVI, and the local lymph nodes. MRI scans must meet a corresponding quality standard regarding slice orientation and spatial resolution for optimized visualization of these entities.

A comprehensive quality-assured MRI examination with structured visualization of all of the above-described MRI criteria is the foundation of both studies of the German Rectal Cancer Study



► **Fig. 4** illustrates a suspicious lymph node in a perirectal position on the left side. In the T2w axial image **a**, the lymph node is enlarged and round, and the fatty hilum is absent. The image on the right **b** shows a 3.4-fold enlargement of the lymph node and its inhomogeneous internal texture (**b**, 8 mm). The dotted line in figure **a** marks the course of the mesorectal fascia in this area.

Group sponsored by German Cancer Aid. Differentiated and customized perioperative treatment of patients with locally advanced rectal cancer can only be achieved in this way.

### Conflict of Interest

Ulrike Attenberger has received a speaker's honorarium from Siemens Healthineers. Sebastian Stintzing has received the following Research grants from AMGEN, Bayer, BMS, ESAI, Lilly, Merck KGaA, MSD, Pierre-Fabre, Roche, Sanofi, Servier, Taiho and Takeda; and consulting services for AMGEN, Bayer, BMS, ESAI, Lilly, Merck KGaA, MSD, Pierre-Fabre, Sanofi, Servier, Taiho, Takeda and Roche. Michael Ghadimi received: Travel expense reimbursements from the MHH Foundation, German Cancer Aid, Elsevier GmbH, German Research Foundation, Johnson & Johnson, Charité Berlin, German Cancer Society, MCI Germany, Bonn Clinic for General Surgery, Tübingen Clinic for Radiooncology, Frankfurt University Hospital Radiation Clinic, Georg Thieme Verlag, Bremerhaven Hospital, Interplan Congress, Meeting & Event Management AG, MCI Germany GmbH, Bremerhaven Reinkenheide Hospital and Boehringer Ingelheim Pharma; Fees from Klinikum Bremerhaven, MCI Deutschland GmbH and Boehringer Ingelheim Pharma. The other authors declare that they have no conflict of interest.

### References

- [1] Beets-Tan RG, Beets GL. Rectal cancer: review with emphasis on MR imaging. *Radiology* 2004; 232: 335–346. doi:10.1148/radiol.2322021326
- [2] Slater A, Halligan S, Taylor SA et al. Distance between the rectal wall and mesorectal fascia measured by MRI: Effect of rectal distension and implications for preoperative prediction of a tumour-free circumferential resection margin. *Clin Radiol* 2006; 61: 65–70. doi:10.1016/j.crad.2005.08.010
- [3] Ye F, Zhang H, Liang X et al. JOURNAL CLUB: Preoperative MRI Evaluation of Primary Rectal Cancer: Intrasubject Comparison With and Without Rectal Distention. *Am J Roentgenol* 2016; 207: 32–39. doi:10.2214/AJR.15.15383
- [4] Horvat N, Carlos Tavares Rocha C, Clemente Oliveira B et al. MRI of Rectal Cancer: Tumor Staging, Imaging Techniques, and Management. *Radiographics* 2019; 39: 367–387. doi:10.1148/rg.2019180114
- [5] Hamm B, Krestin GB, Laniado M et al. MRT von Abdomen und Becken: 2. Völlig überarbeitete und erweiterte Auflage; Thieme; 2007. doi:10.1055/b-0036-137158
- [6] Group MS. Extramural depth of tumor invasion at thin-section MR in patients with rectal cancer: results of the MERCURY study. *Radiology* 2007; 243: 132–139. doi:10.1148/radiol.2431051825

- [7] Hoeffel C, Mule S, Laurent V et al. Current imaging of rectal cancer. *Clin Res Hepatol Gastroenterol* 2015; 39: 168–173. doi:10.1016/j.clinre.2014.07.014
- [8] Nougaret S, Reinhold C, Mikhael HW et al. The use of MR imaging in treatment planning for patients with rectal carcinoma: have you checked the “DISTANCE”? *Radiology* 2013; 268: 330–344. doi:10.1148/radiol.13121361
- [9] Al-Sukhni E, Milot L, Fruitman M et al. Diagnostic accuracy of MRI for assessment of T category, lymph node metastases, and circumferential resection margin involvement in patients with rectal cancer: a systematic review and meta-analysis. *Ann Surg Oncol* 2012; 19: 2212–2223. doi:10.1245/s10434-011-2210-5
- [10] Leitlinienprogramm Onkologie (Deutsche Krebsgesellschaft, Deutsche Krebshilfe, AWMF): S3-Leitlinie Kolorektales Karzinom, Langversion 2.1, 2019, AWMF Registrierungsnummer: 021/007OL. <http://www.leitlinienprogramm-onkologie.de/leitlinien/> [abgerufen am: 27.01.2020]
- [11] Zhang XY, Wang S, Li XT et al. MRI of Extramural Venous Invasion in Locally Advanced Rectal Cancer: Relationship to Tumor Recurrence and Overall Survival. *Radiology* 2018; 289: 677–685. doi:10.1148/radiol.2018172889
- [12] Bipat S, Glas AS, Slors FJ et al. Rectal cancer: local staging and assessment of lymph node involvement with endoluminal US, CT, and MR imaging—a meta-analysis. *Radiology* 2004; 232: 773–783. doi:10.1148/radiol.2323031368
- [13] Befundungstemplate für Rektumkarzinom (L2, V1, no JS). 2017. Im Internet (Stand: 20.04.2020): [https://www.befundung.drg.de/de-DE/3199/befundvorlagen/041807.00001-mrt\\_rectalca.html/](https://www.befundung.drg.de/de-DE/3199/befundvorlagen/041807.00001-mrt_rectalca.html/)
- [14] Juchems MS, Wessling J. [Rational staging and follow-up of colorectal cancer: Do guidelines provide further help?]. *Radiologe* 2019; 59: 820–827. doi:10.1007/s00117-019-0578-6