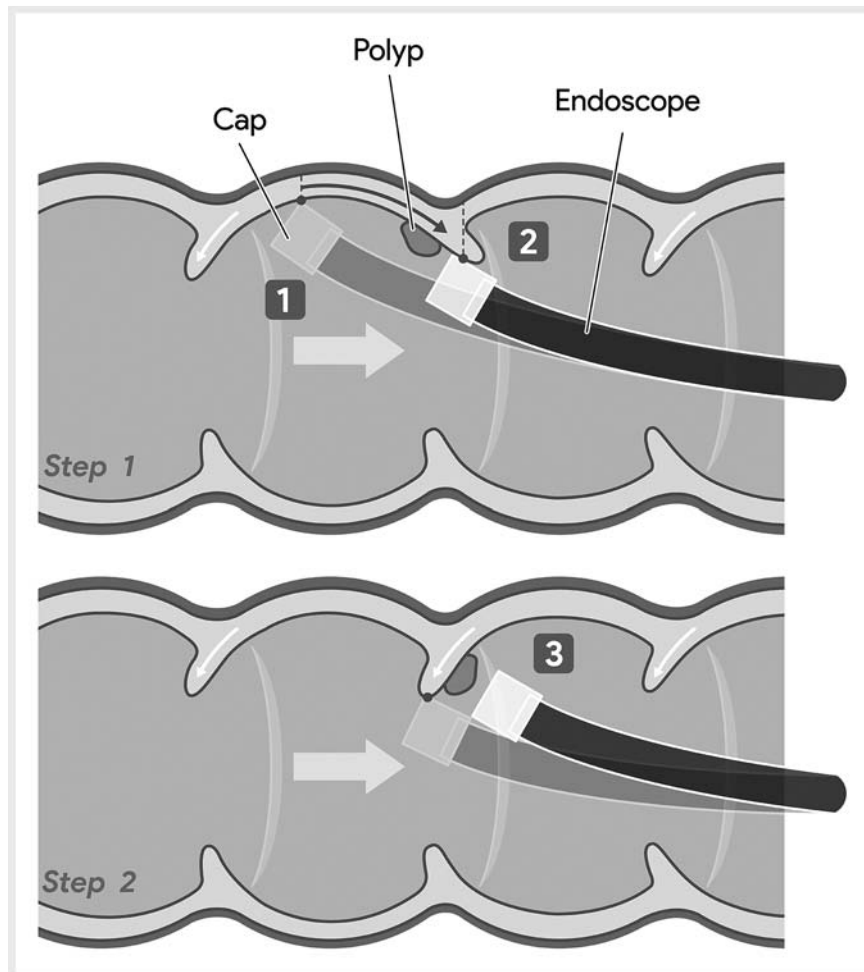


Suggestion of a standard maneuver in cap-assisted colonoscopy: hooking and dragging maneuver

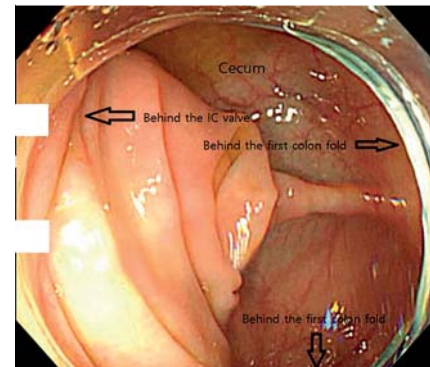


► **Fig. 1** Schematic diagram of “hooking and dragging maneuver”. Source: Park Sabeom.

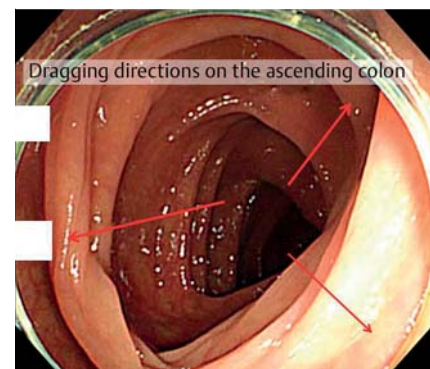
Cap-assisted colonoscopy involves the attachment of a distal transparent cap to the end of the colonoscope. This method has several advantages, such as decreasing insertion time [1] and enabling easy flattening of the mucosal folds, thus permitting visualization of the hidden polyps behind the mucosal folds [2]. However, the use of cap-assisted colonoscopy in detecting adenomas is debatable [1,3]. Until now, although the benefits of using a clear cap have been discussed, there have been no discussions on how to use it. Therefore, this study suggests a “hooking and dragging maneuver” (► **Video 1**).

This maneuver involves hooking the mucosal fold with the tip of the cap, dragging the scope, scratching along the colon wall, and stretching multiple mucosal folds simultaneously (► **Fig. 1**). This technique allows the visualization of multiple posterior regions of the mucosal fold at the same time, minimizing the hidden areas. Hooking points and dragging directions on the cecum (► **Fig. 2**), the ascending colon (► **Fig. 3**), and the hepatic flexure (► **Fig. 4**) are shown.

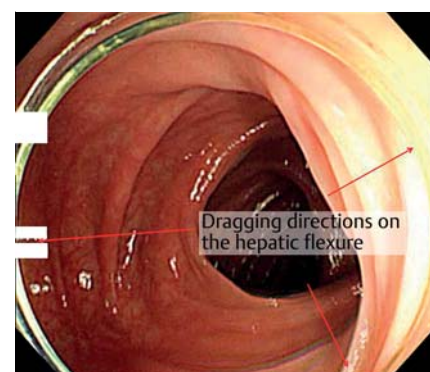
Endoscopy_UCTN_Code_TTT_1AQ_2AB



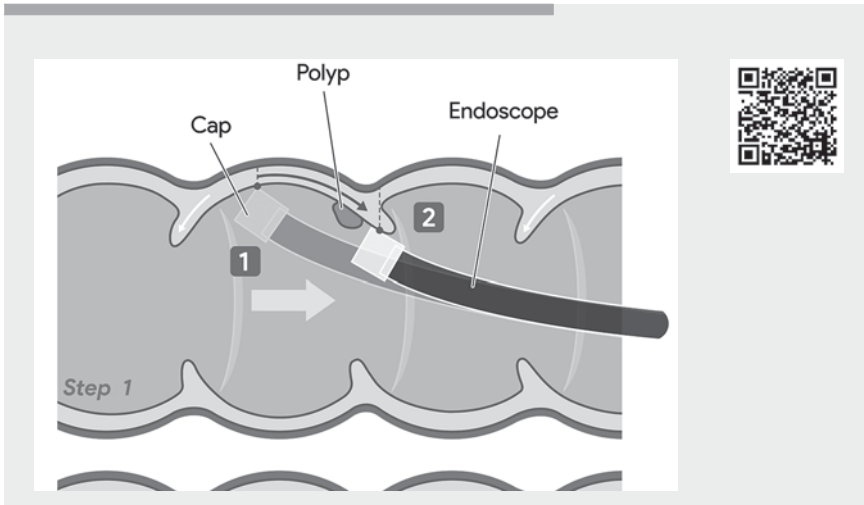
► **Fig. 2** Mucosal hooking points on the cecum.



► **Fig. 3** Mucosal hooking points on the ascending colon.



► **Fig. 4** Mucosal hooking points on the hepatic flexure.



Video 1 “Hooking and dragging maneuver” as a standard maneuver in cap-assisted colonoscopy. Source for graphical illustration: Park Sabeom.

Bibliography

Endoscopy 2022; 54: E164–E165
 DOI 10.1055/a-1446-8180
 ISSN 0013-726X
 published online 28.4.2021
 © 2021. Thieme. All rights reserved.
 Georg Thieme Verlag KG, Rüdigerstraße 14,
 70469 Stuttgart, Germany

ENDOSCOPY E-VIDEOS

<https://eref.thieme.de/e-videos>



Endoscopy E-Videos is an open access online section, reporting on interesting cases and new techniques in gastroenterological endoscopy. All papers include a high quality video and all contributions are freely accessible online. Processing charges apply (currently EUR 375), discounts and waivers acc. to HINARI are available.

This section has its own submission website at
<https://mc.manuscriptcentral.com/e-videos>

Competing interests

The authors declare that they have no conflict of interest.

The author

Jihwan Ko

Health Promotion Center, Baekyang Jeil Internal Medicine Clinic, Busan, Korea

Corresponding author

Jihwan Ko, MD

Health Promotion Center, Baekyang Jeil Internal Medicine Clinic, 108-1, Dongpyeong-ro, Busanjin-gu, Busan, Republic of Korea
 Fax: +82-51-897-1134
jihwanko65@gmail.com

References

- [1] Nutalapati V, Kanakadandi V, Desai M et al. Cap-assisted colonoscopy: a meta-analysis of high-quality randomized controlled trials. *Endosc Int Open* 2018; 6: E1214–E1223. doi:10.1055/a-0650-4258 [Epub 2018 Oct 8]
- [2] Kim HH, Park SJ, Park MI et al. Transparent-cap-fitted colonoscopy shows higher performance with cecal intubation time in difficult cases. *World J Gastroenterol* 2012; 18: 1953–1958. doi:10.3748/wjg.v18.i16.1953
- [3] Pohl H, Bensen SP, Toor A et al. Cap-assisted colonoscopy and detection of adenomatous polyps (CAP): a randomized trial. *Endoscopy* 2015; 47: 891–897. doi:10.1055/s-0034-1392261