

## Novel technique for treating simple hepatic cysts: endoscopic transgastric hepatic cyst deroofing

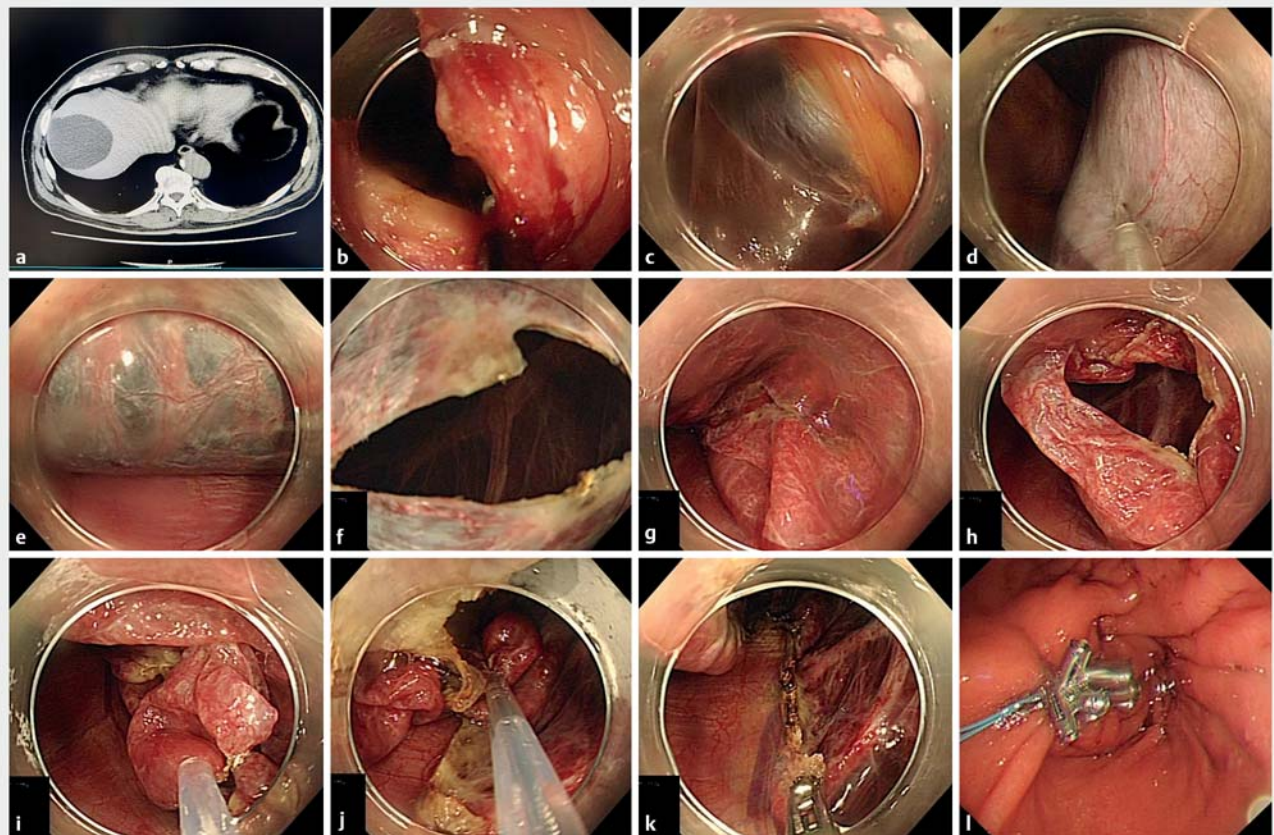


Simple hepatic cysts are common benign liver lesions which are usually asymptomatic and discovered incidentally. However, larger lesions may need surgical treatment if patients present with abdominal pain, epigastric fullness, or early satiety [1]. American Society of Gastroenterology clinical practice guidelines recommend that symptomatic simple hepatic cysts may be managed with laparoscopic deroofing rather than aspiration and sclerotherapy [2]. Natural-orifice transluminal endoscopic surgery

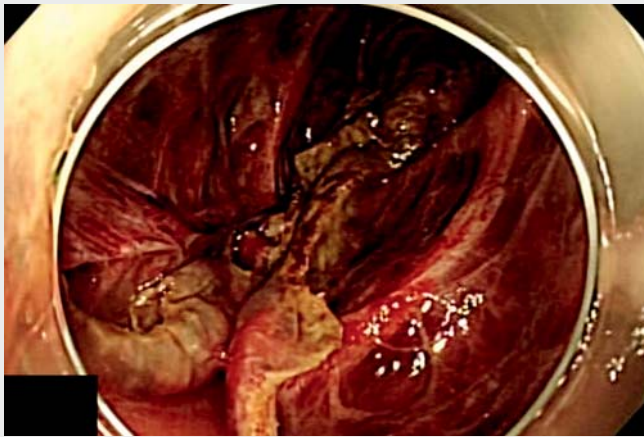
(NOTES) has been developed as a step towards less invasive procedures [3]. With the development of digestive endoscopy, some researchers have used endoscopic ultrasound-guided fine-needle aspiration or NOTES technology for cystic fluid aspiration. Herein, we report a novel approach to smoothly achieving unroofing of simple hepatic cysts, called endoscopic transgastric hepatic cyst deroofing (ETGHCD).

A 73-year-old man complained about abdominal pain and epigastric fullness,

which was significantly impacting on his daily life. Abdominal computed tomography and ultrasonography revealed an 8-cm simple cyst located in the right liver as the underlying disease. To address the issue we performed ETGHCD on the patient. During the procedure the anterior wall of the gastric antrum was perforated with a sterile colonoscope. The cyst was found at the lower edge of segment IV of the liver. After endoscopic ultrasonography reconfirmed the cyst, transparent liquid was extracted with a 23-G puncture



► **Fig. 1** Endoscopic transgastric hepatic cyst deroofing for the treatment of a simple hepatic cyst in a 73-year-old man. **a** Computed tomography showed an 8-cm simple cyst located in segment IV of the liver. **b** Active perforation of the anterior wall of the gastric antrum. **c–e** Before fenestration, the cyst was examined by ultrasonography; it was then percutaneously punctured and aspirated for compression and examination of fluid contents. **f–j** To avoid bleeding and bile leakage from the edge of the fenestrated cyst wall, dissection of the wall was initiated from its thinnest part, and the cyst wall was carefully dissected piece by piece where it joins the hepatic parenchyma, using a snare. **k** Hemostatic control. **l** Closure of the gastric wall.



**Video 1** Endoscopic transgastric hepatic cyst deroofing for the treatment of a hepatic cyst in a 73-year-old man.

needle (Boston Scientific) and sent for examination. After all fluid was extracted from the cyst, we opened the cyst wall and removed it piecemeal with a snare at the interface with the hepatic parenchyma, sealed the vessels of the cyst wall, flushed the abdominal cavity, and closed the gastric wall. The ETGHCD technique, which was applied to the large hepatic cyst located on the surface of the liver, was performed and deroofing of the cyst was achieved, thus avoiding surgery (► **Fig. 1**, ► **Video 1**). The postoperative course was uneventful. The patient was discharged 2 days after endoscopic surgery. His symptoms resolved completely during the following 6 months.

Endoscopy\_UCTN\_Code\_TTT\_1AT\_2AF

### Competing interests

The authors declare that they have no conflict of interest.

### The authors

**Congying Chen<sup>\*</sup>, Ruling Zhang<sup>\*</sup>, Rong Wan**

Department of Gastroenterology, Shanghai General Hospital, Shanghai Jiaotong University School of Medicine, Shanghai, China

### Corresponding author

**Rong Wan, MD**

Department of Gastroenterology, Shanghai General Hospital, Shanghai Jiaotong University School of Medicine, 100 Haining Road, Hongkou District, Shanghai 200080, P.R. China  
wanrong1970@163.com

### References

- [1] Gomez A, Wisneski AD, Luu HY et al. Contemporary management of hepatic cyst disease: techniques and outcomes at a tertiary hepatobiliary center. *J Gastrointest Surg* 2021; 25: 77–84

- [2] Marrero JA, Ahn J, Rajender Reddy K. American College of Gastroenterology. ACG clinical guideline: the diagnosis and management of focal liver lesions. *Am J Gastroenterol* 2014; 109: 1328–1347
- [3] Ullah S, Ali FS, Liu BR. Advancing flexible endoscopy to natural orifice transluminal endoscopic surgery. *Curr Opin Gastroenterol* 2021; 37: 470–477

### Bibliography

*Endoscopy* 2022; 54: E1045–E1046

DOI 10.1055/a-1909-1392

ISSN 0013-726X

published online 25.8.2022

© 2022. The Author(s).

This is an open access article published by Thieme under the terms of the Creative Commons Attribution-NonDerivative-NonCommercial License, permitting copying and reproduction so long as the original work is given appropriate credit. Contents may not be used for commercial purposes, or adapted, remixed, transformed or built upon. (<https://creativecommons.org/licenses/by-nc-nd/4.0/>)

Georg Thieme Verlag KG, Rüdigerstraße 14, 70469 Stuttgart, Germany



### ENDOSCOPY E-VIDEOS

<https://eref.thieme.de/e-videos>



*Endoscopy E-Videos* is an open access online section, reporting on interesting cases

and new techniques in gastroenterological endoscopy. All papers include a high quality video and all contributions are freely accessible online. Processing charges apply (currently EUR 375), discounts and waivers acc. to HINARI are available.

This section has its own submission website at

<https://mc.manuscriptcentral.com/e-videos>

\* These two authors contributed equally.