Accepted Manuscript online: 2022-11-04 Article published online: 2023-02-23

Endoscopic full-thickness resection (EFTR) compared to submucosal tunnel endoscopic resection (STER) for treatment of gastric gastrointestinal stromal tumors

Authors

Philip Wai Yan Chiu[1], Hon Chi Yip[1], Shannon Melissa Chan[1], Stephen Ka Kei Ng[1], Anthony Yuen Bun Teoh[1], Enders Kwok Wai Ng[1]

Institutions

1 Division of Upper GI and Metabolic Surgery, Department of Surgery, Institute of Digestive Disease, Faculty of Medicine, The Chinese University of Hong Kong, Hong Kong S.A.R, China

submitted 28.3.2022
accepted after revision 2.11.2022
published online 04.11.2022

Bibliography
Endosc Int Open 2023; 11: E179–E186
DOI 10.1055/a-1972-3409
ISSN 2364-3722

Georg Thieme Verlag KG, Rüdigerstraße 14, 70469 Stuttgart, Germany

Corresponding author
Professor Philip WY Chiu, Department of Surgery, 4F Lui Che Woo Clinical Science Building, Prince of Wales Hospital, 30-32 Ngan Shing Street, Shatin, N.T., Hong Kong S.A.R., China
Fax: +85226377974
philipchiu@surgery.cuhk.edu.hk

ABSTRACT

Background and study aims Submucosal tunnel endoscopic resection (STER) is being increasingly performed for treatment of gastric gastrointestinal stromal tumor (GIST), while STER has been limited by close dissection within tunnel and risking breach of tumor capsule. Endoscopic full-thickness resection (EFTR) allows resection of GIST with margins to prevent recurrence. This study aimed to compare EFTR against STER for treatment of gastric GIST.

Patients and methods We retrospectively reviewed clinical outcomes of patients with gastric GIST who received either STER or EFTR. Patients with gastric GISTs < than 4 cm were included. Clinical outcomes including baseline demographics, perioperative and oncological outcomes were compared between the two groups.

Results From 2013 to 2019, 46 patients with gastric GISTs were treated with endoscopic resection, 26 received EFTR and 20 received STER. Most of the GISTs were in the proximal stomach. There was no difference in operative time (94.9 vs 84.9 mins; $P = 0.401$), while endoscopic suturing was applied more for closure after EFTR ($P < 0.0001$). Patients after STER had earlier resumption of diet and shorter hospital stay while there was no difference in adverse event rate between two groups. The en-bloc resection rate for EFTR was significantly higher than for STER (100 % vs 80 %; $P = 0.029$), while there was no difference in the local recurrence.

Conclusions This study demonstrated that although patients who received EFTR had longer hospital stays and slower resumption of diet compared to those who underwent STER, EFTR achieved a significantly higher rate of en-bloc resection compared to STER for treatment of gastric GIST.

Introduction

Gastric subepithelial tumors are usually considered benign neoplasms. The most common pathology for gastric subepithelial tumors includes gastrointestinal stromal tumor (GIST), leiomyoma, Schwann cell tumor, pancreatic heterotopia as well as neuroendocrine tumor. Current guidelines state that surgical resection should be performed for GIST > 2 cm, while endoscopic surveillance should be conducted for GIST of low risk and < 2 cm [1, 2]. Determination of risks from these small gastric GIST depends on suspicious features on endoscopic ultraso-

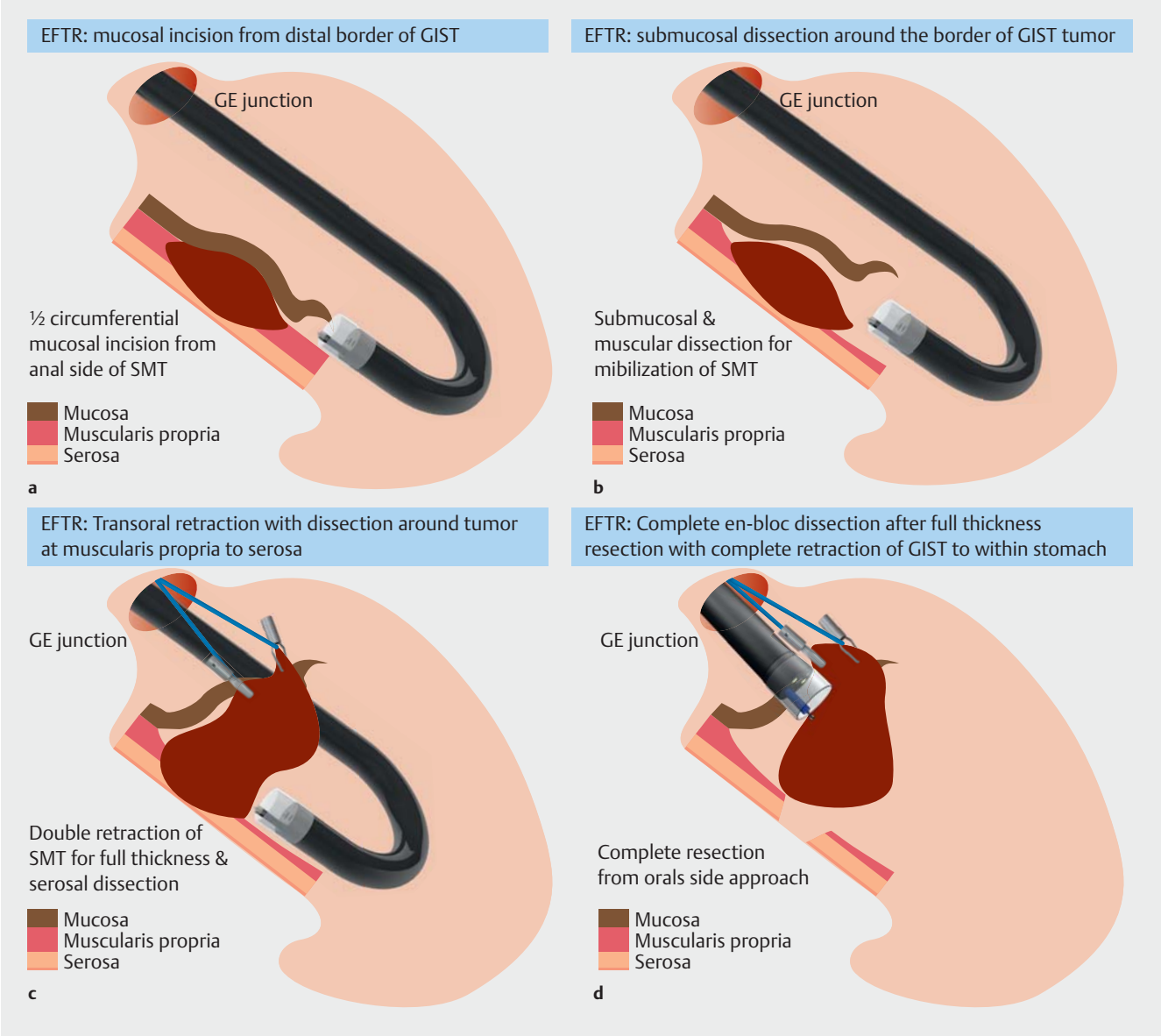

▶ **Fig.1** Schematic illustration of Gastric Endoscopic Full Thickness Resection (EFTR) for treatment of Gastric GIST in proximal stomach. **a** – ½ circumferential mucosal incision from anal side of submucosal tumor (SMT); **b** – submucosal & muscular dissection for mobilization of SMT; **c** – Double retraction of SMT for full thickness & serosal dissection; **d** – Complete resection from oral side approach.

nography (EUS), while fine-needle aspiration or biopsy could be challenging due to the small size of these GISTs [3].

Endoscopic submucosal dissection (ESD) has been established as standard treatment for intramucosal early gastrointestinal neoplasia [4]. Recently, studies have demonstrated the feasibility of applying techniques of ESD for treatment of gastric subepithelial tumors [5–7]. Despite the success in achieving resection of these tumors, various cohort studies demonstrated high risk of full-thickness perforation during resection by ESD as the majority of these tumors arise from or adherent to muscularis propria [5–9]. Submucosal tunnel endoscopic resection (STER) and per-oral endoscopic tumor resection (POET) were developed with the aim of achieving endoscopic resection of submucosal tumors of the gastrointestinal tract without inducing full-layer perforation [10–12]. However, during dissection of the tumor within the submucosal tunnel, the space for manipulation was quite narrow, which might lead to close dissection to the tumor, causing breach of the tumor capsule [13].

Recently, advances in endoscopic resection have led to development of techniques for endoscopic full-thickness resection (EFTR) [14]. The American Society for Gastrointestinal Endoscopy Technology Committee established guidelines for EFTR and STER, and EFTR is classified into exposed and non-exposed procedures. Exposed EFTR is performed with a tunneled or non-tunneled technique and subsequent closure of the defect, while for non-exposed EFTR, a secure serosa-to-serosa apposition is achieved before full-thickness resection. Recent European Society of Gastrointestinal Endoscopy (ESGE)guidelines

on management of gastrointestinal subepithelial lesions recommend endoscopic resection as an option for gastric subepithelial lesions <20 mm [15]. Meanwhile, the evidence to support the type of endoscopic resection to achieve en bloc resection of these lesions is lacking. This study aimed to compare the clinical and oncological outcomes of tunneled resection (STER) versus non-tunneled exposed EFTR of gastric GIST.

Patients and methods

This was a retrospective cohort study conducted at the endoscopy center of a university-affiliated tertiary referral hospital. The objective was to compare clinical outcomes of STER against exposed EFTR for treatment of gastric GIST. Case records of patients with a diagnosis of gastric GIST who received endoscopic resection by STER and exposed EFTR that were included in a prospectively collected database were retrospectively reviewed.

All patients received preoperative investigation of the gastric submucosal tumors, including EUS and abdominal computed tomography (CT) with contrast. The decision to use EUS-guided fine-needle aspiration cytology was at endoscopist discretion. The size of the gastric submucosal tumors was determined by esophagogastroduodenoscopy (EGD), EUS, CT or a combination. Patients with gastric GISTs located at the gastric cardia, lesser curvature, and antrum that measured 15 mm to 40 mm on preoperative testing were recruited for endoscopic resection with STER or EFTR. The study was conducted with standards according to the principles of the Declaration of Helsinki. All procedures were performed by two endoscopists who had vast experience in performing advanced endoscopic procedures including ESD, POEM, STER, and EFTR. All procedures were performed under general anesthesia at the endoscopy suite with CO_2 insufflation.

Intervention

Submucosal endoscopic tumor resection (STER)

The procedure of STER was described in a previous publication [16]. Briefly, after endoscopic location of the gastric GIST and pre-injection, a 2- to 3-cm mucosal entrance was created 2 cm proximal to the tumor border. A short submucosal tunnel was developed up to the point of visualization of the tumor. The lateral borders of the subepithelial tumor were dissected, and subsequently a 2-cm pocket was created distally for manipulation. Subsequently, the tumor was dissected away from muscularis propria layer to the subserosal layer. Upon completion of the dissection, the tumor was retrieved per orally. The mucosal entrance was closed by primary clip closure method.

Endoscopic full-thickness resection

The procedure steps of EFTR for treatment of gastric subepithelial tumors is shown in ▶ **Fig. 1**, ▶ **Fig. 2** and the ▶ **Video 1**. Procedure planning depended on the location of the gastric GIST. For gastric GISTs located over the proximal stomach, cardia and fundus, EFTR was performed with the endoscope in retroflexed position, while for those located at the antrum and prepyloric canal, the endoscope was in antegrade position.

VIDEO

▶ **Video 1** Endoscopic full thickness resection for treatment of gastric gastrointestinal stromal tumor.

After adequate lifting of the submucosa, mucosal incision was performed using a Dual Knife jet (Olympus Co Ltd, Japan). Upon trimming of the mucosal incision and exposure of submucosal plane on the surface of the muscularis propria, the tumor was identified. To ensure en bloc margin negative resection, the dissection plane was performed to preserve an intact tumor pseudo-capsule while dividing the muscularis attachment 1 to 2 mm away from the capsule. The serosal layer was often breached upon deep dissection of the muscularis propria and resulted in full-thickness resection. After adequate mobilization of the GIST, transoral clip-string countertraction was applied to retract the GIST and expose the serosal plane. Upon full-thickness incision to the peritoneum, insufflation of CO_2 was reduced to minimum manually. As the tumor and covering mucosal layer was still attached to the luminal wall, the full-thickness defect was reduced, thus minimizing CO_2 leakage by pulling the transoral clip-string. Percutaneous needle decompression of the intraperitoneal CO_2 was performed when the pressure was so high that it impaired adequate mechanical ventilation. At this juncture, the serosal border of the GIST could be clearly identified by recognizing abnormal tumor vessels, and the dissection over normal serosa and muscularis propria ensured adequate resection margins. During serosal dissection in close proximity to adjacent intraperitoneal organs such as the colon, inadvertent damage was avoided by using an insulated tip knife (IT2, Olympus Co Ltd, Japan). Once the tumor was fully mobilized and pulled inside the stomach, the resection was completed by placing the endoscope in antegrade manner. The tumor was then retrieved using a Roth Net retrieval device to avoid slippage of the tumor to peritoneal cavity.

Closure of the luminal defect after EFTR

The luminal defect in the gastric wall was re-examined to determine the optimal method of safe closure. Options for luminal defect closure included: 1. primary through the scope (TTS) clip closure; 2. clip-loop closure (Crown technique); and 3. endoscopic suturing device closure. Choice of closure depended on the size of the luminal defect and proportion of the

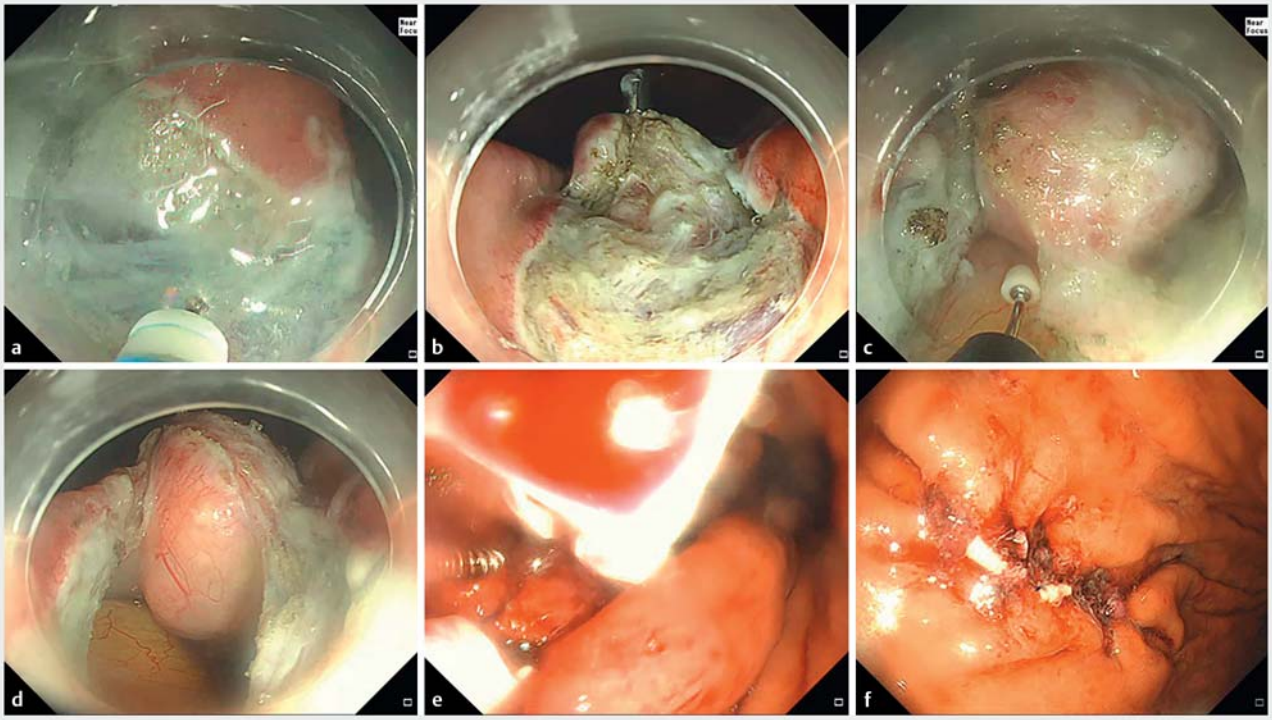

▶ **Fig. 2** Endoscopic Full Thickness Resection of Gastric GIST; **a** – ½ circumferential mucosal incision and submucosal dissection to exposure the gastric GIST; **b** – per oral clip string retraction to lift the submucosal GIST; **c** – full thickness resection with dissection at border of GIST; **d** – Exposure of the serosal margin for en-bloc dissection through pulling of the tumor by clip string retraction; **e** – Closure of luminal defect with Overstitch (Single Channel system; Apollo Surgical Co Ltd); **f** – complete closure of luminal defect evidence by full distension of stomach without gas leakage.

full-thickness segment. For a luminal defect ≤ 10 mm with minimal full-thickness segment, we used primary clip closure with multiple TTS clips. However, for most defects > 10 mm, clip-loop closure was performed if the full-thickness segment was < 50 % (▶ **Fig. 3**). If the full-thickness segment was > 50 % of the luminal defect, endoscopic suturing was the preferred closing method (▶ **Fig. 2**). The endoscopic suturing device employed was the OverStitch endoscopic suturing system including the OverStitch and OverStitch Sx (Apollo Endosurgery Inc., Austin, Texas, United States). The OverStitch was attached to the end of double channel endoscope while the OverStitch Sx was attached along the side of a single channel endoscope. The procedure of closure was similar between these two systems (▶ **Fig. 2**). First, the needle was passed over the whole thickness of one side of the luminal defect. The detachable needle was caught by anchor exchange catheter, and after opening of the needle driver the tissue was disengaged. After passage of needle back to needle driver, the needle was driven as full-thickness suture to the opposite side of the gastric wall. After repeating this procedure of suturing in "Figure of 8" manner, the needle was detached and cinching procedure performed to achieve full-thickness suture closure. The procedure was repeated as necessary until the defect was completely closed as evidence by full distension of stomach upon insufflation without gas leakage and visual confirmation of closure without remnant defect.

The specimen was sent to dedicated pathologist for analysis with immune staining as well as observation of resection margins.

Outcome measures and statistical analysis

The primary outcome was the en-bloc resection rate of GIST, while secondary outcomes included the need for conversion to other procedures for resection, operative time, length of hospital stay, and rate of complications. Oncological outcomes included the en-bloc resection rate of gastric GISTs as well as the rate of tumor recurrence. En-bloc resection was defined upon histopathological examination as resection of the GIST in one piece with clear resection margins.

Statistical analyses comparing clinical outcomes between the two groups were performed using the Student *t*-test for parametric data and Mann-Whitney U test for non-parametric data when appropriate. Categorical data were analyzed using a Chi-square test or Fisher's exact test. Statistical analyses of the data were performed using SPSS 27.0 statistical software. $P < 0.05$ was considered statistically significant.

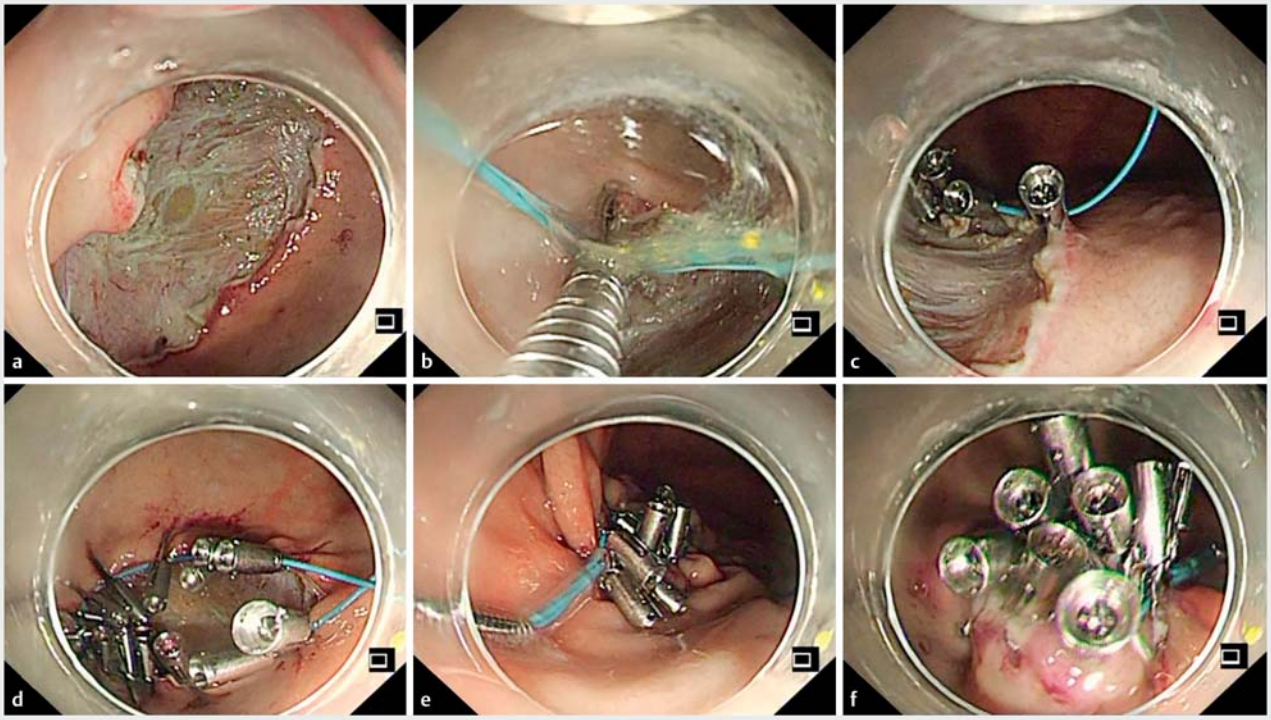

▶ **Fig. 3** Alternative closure of luminal defect with clip and loop technique (Crown technique); **a** – A relatively small portion of gastric luminal defect had involved full thickness resection; **b** – Application of first clip over detachable loop for fixation at proximal defect; **c** – further application of clips to attach the loop to mucosal border of the defect; **d** – Tightening of the detachable loop after application of multiple clips around the mucosal border; **e** – Complete closure of the defect after closure of the clip-loop; **f** – release of the detachable loop upon complete closure of the gastric luminal defect.

Results

From 2013 to 2019, 46 patients with gastric GIST received endoscopic resection at our institution, including 26 patients who received non-tunneled exposed EFTR while 20 who received tunneled exposed EFTR / STER (▶ **Table 1**). All patients recruited into this study were confirmed to have gastrointestinal stromal tumor (GIST) upon histopathology after resection. When compared between the two groups, there was no difference in basic demographics. Mean GIST size was 22.0 ± 9.79 mm for the EFTR group and 20.9 ± 12.4 mm for the STER group (P = 0.757). Most of the gastric GISTs were located at the cardia and proximal stomach, and there was no difference in the distribution of locations between the two groups. Apparently, EFTR was applied for resection of GIST at the fundus – a location which is usually contraindicated for submucosal tunnel development in the STER group.

There was no difference in operative time between the two groups (94.9 vs 84.9 mins; P = 0.401), while endoscopic suturing was applied more frequently for closure after EFTR compared to STER (P < 0.0001). Patients who received STER were able to resume on full diet 1 day earlier than those who received EFTR (mean 2.92 vs 2.0 days; P = 0.0002). Moreover, the STER group had significantly shorter hospital stays than the EFTR group (mean 4.38 days vs 3.50 days; P = 0.015). The most common complication was fever after the procedure in both groups, but there was no leakage after closure of the mucosal incision or full-thickness defect. There was no difference in overall complication rates between the two groups (P = 0.593). Of the patients in the EFTR group, 92.3 % required release of the CO_2 pneumoperitoneum that developed during the procedure, compared to only 35.0 % of patients who received STER (P < 0.0001).

All the histopathologic results confirmed gastrointestinal stromal tumors (GIST) with c-kit and CD117 positivity. There was no difference in the proportion of GISTs > 20 mm or mitotic figures between the two groups (▶ **Table 1**). Upon histopathological examination of the resected specimen, the en-bloc resection rate for EFTR was 100 %, which was significantly higher than for STER (100 % vs 80 %; P = 0.0297). Meanwhile, there was no difference in local recurrence rates between the two groups. The mean follow-up was significantly longer for the STER group compared to the EFTR group (21.15 vs 50.50 months; P < 0.0001).

Discussion

Gastric GISTs are increasingly being recognized during diagnostic endoscopy [15, 17]. The malignant potential of a GIST can be assessed by size, location as well as mitotic figures through EUS, CT and EUS-guided fine-needle biopsy [15, 18]. The National

▶ **Table 1** Comparison of clinical outcomes of EFTR against STER for treatment of gastric gastrointestinal stromal tumors (GIST).

Parameters	EFTR (26)	STER (20)	*P*
Age (mean)	59.6	57.5	0.585
Male (%)	8 (30.7 %)	8(40 %)	0.548
Location of gastric GIST			
Cardia	5	9	
Lesser curve	6	4	
Greater curve	5	3	
Body	3	0	
Fundus	4	0	
Antrum	3	4	
Size of gastric GIST (mm) (mean)	22.0 ± 9.79	20.9 ± 12.4	0.757
Size < 20 mm	8	10	0.231
Size > 20 mm	18	10	
General anesthesia	26 (100 %)	26 (100 %)	1.0
Mean procedure time (mins)	94.9	84.9	0.401
Closure method			
Clips/clip-loop	12	20	< 0.0001[1]
Endoscopic suturing	14	0	
Hospital stay (days) (mean)	4.38	3.50	0.015[2]
Days to resume full diet (mean)	2.92	2.00	0.0002[2]
Adverse event rate (overall)	1 (3.8 %)	2 (10 %)	0.593
Postoperative fever	1 (3.8 %)	2 (10 %)	
Leakage	0	0	
Release of CO_2 pneumoperitoneum	24 (92.3 %)	7 (35.0 %)	< 0.0001[1]
Conversion to laparoscopic surgery	2	0	0.497
En bloc resection rate	26 (100 %)	16 (80 %)	0.0297[1]
Mitotic figure (per HPF)			
< 1/10 HPF	26	18	0.184
> 1/10 HPF	0	2	
Follow-up period (months)	21.15	50.50	< 0.0001
Recurrence	0	1	0.435

EFTR, endoscopic full-thickness resection; STER, submucosal tunnel endoscopic resection; GIST, gastrointestinal stroma tumor; HPF, high power field.
[1] Chi square test with significant difference.
[2] Student t test with significant difference.

Comprehensive Cancer Network guidelines recommend surgical resection for treatment of gastric GIST > 20 mm or those with high-risk features upon EUS [2]. For GISTs < 20 mm without high-risk features, periodic endoscopic or radiographic surveillance is recommended. Recently, ESGE guidelines for management of gastrointestinal subepithelial lesions suggested that surveillance for gastric subepithelial lesions without definite diagnosis should be conducted with EGD at 3- to 6-month intervals. Afterward, surveillance EGD should be done at 2- to 3-year intervals for lesions < 10 mm and at 1- to 2-year intervals for lesions 10 to 20 mm [15]. Meanwhile for pathologically confirmed gastric GISTs < 20 mm, ESGE recommended management by either regular endoscopic surveillance or endoscopic resection as an acceptable alternative [15].

Although endoscopic surveillance is both feasible and safe in managing gastric GISTs < 20 mm, the long-term compliance is usually suboptimal. In a cohort study of 65 patients with foregut subepithelial lesions on endoscopic follow-up over 30 months, 25 % of these lesions demonstrated growth. However, fewer than 50 % of patients underwent surveillance EUS as recommended [19]. The authors suggested that endoscopic surveillance is a poor strategy because compliance is very low. On the contrary, when technically feasible, tissue acquisition should be pursued as tissue diagnosis will reassure patients, provide guidance for surveillance recommendations, and in some cases eliminate the need for follow-up. However, a meta-analysis of 17 studies on use of EUS-guided tissue acquisition for upper gastrointestinal subepithelial tumors only achieved a diagnostic yield of 59.9 % [20].

Endoscopic resection served as an alternative approach for definite treatment for small gastric GISTs. Endoscopic resection will not only provide tissue diagnosis but also can be curative and alleviate patient need for surveillance. Endoscopic resection can be considered for small gastric GISTs to avoid the burden of surveillance among young patients and those who have high-risk features on EUS [14, 15]. ESD was first explored as a treatment for gastric GISTs in a cohort of 33 patients [21]. The mean size of the GISTs was only 14.5 mm while 93.9 % of them were resected in one piece. However, vertical resection margin was insufficient in 4 of 33 GISTs. As GIST originates from interstitial cells of Cajal which are located in the muscularis propria, endoscopic resection would likely result in full-thickness perforation during the procedure [22]. STER was developed to avoid full-thickness perforation during resection of gastric GISTs through a submucosal tunnel [10–13]. In a retrospective cohort comparing STER with ESD for treatment of gastric GISTs at cardia, similar clinical outcomes were demonstrated, including en bloc resection and complication rates [22]. However, the en bloc resection rates for STER and ESD were only 70.2 % and 67.5 %, respectively. One of the major technical issues for STER is dissection within limited space in the submucosal tunnel, which may lead to breaching of the tumor capsule during dissection and increased risks of local recurrence. Second, as most of gastric GISTs are located in the proximal stomach, cardia, and fundus, there may be major difficulty in developing a tunnel to reach a target GIST [23].

EFTR avoids dissection close to tumor capsule as the tumor is mobilized through endoscopic dissection at the muscularis propria without space limitation. Moreover, the tumor can be retracted using a clip and string technique, which provides a clear view of the dissection plane, avoiding inadequate resection margins over both the muscularis and serosa. In our study, EFTR demonstrated significantly higher rates of en-bloc resection compared to STER while there was no difference in overall adverse event (AE) rates. Although patients who received EFTR resumed a diet later than those who received STER, there was no leakage from the full-thickness defect after EFTR. The preferred method for closure after EFTR included the clip and loop technique and endoscopic suturing. In a meta-analysis on endoscopic resection for gastric GISTs <20 mm, the complete resection rate was 97 % with an AE rate of 8 % [24]. However, in a study comparing endoscopic resection against laparoscopic resection for 130 cases of GIST >20 mm, endoscopic resection demonstrated a significantly lower R0 resection rate of 25.6 % compared to 85 % for laparoscopic resection [25]. The methods of endoscopic resection included ESD, STER, EMR, EFTR, and polypectomy and noticeably numerous important AEs occurred, including bleeding, macroscopic perforation requiring laparoscopic closure, as well as falling of the specimen into peritoneal cavity after resection. In our study, we carefully applied techniques to avoid these AEs, including adjustment of energy platform to achieve hemostasis, as well as various techniques for defect closure. Moreover, we always applied one to two per-oral clips for suture traction to avoid dropping the specimen into the peritoneal cavity after dissection. The traction by per-oral clip suture during dissection not only exposed the dissection plane but also served to minimize the full-thickness defect and reduce gas leakage during EFTR.

There are several limitations of this study. First, it was a retrospective cohort comparing EFTR with STER, in which STER was first applied for treatment of gastric GIST followed by EFTR. There could have been an improvement in endoscopic techniques over this transition period, which might partially explain the higher en bloc resection rate. Second, because all the procedures were performed by two endoscopists, there could be operator bias and the clinical outcomes may be not applicable in other centers.

Conclusions

In conclusion, our study demonstrated that EFTR achieved significantly higher rates of en bloc resection compared to STER for treatment of gastric GISTs. Although patient recovery was hastened by STER due to secure closure, there was no difference in AE rates or procedure times. Hence, EFTR should be recommended for treatment of gastric GISTs amendable to endoscopic resection.

Competing interests

The authors declare that they have no conflict of interest.

References

[1] Casaku PG, Blay JY, Abecassis N et al. Gastointestinal stromal tumors: ESMO-EURACAN-GENTURIS Clinical Practice Guidelines for diagnosis, treatment and followup. Ann Oncol 2022; 33: 20–33

[2] National Comprehensive Cancer Network Guidelines Gastrointestinal Stromal Tumors (GISTs) (Version 1.2022). https://www.nccn.org/guidelines/recently-published-guidelines

[3] Yang YT, Shen N, Ao F et al. Diagnostic value of contrast-enhanced harmonic endoscopic ultrasonography in predicting the malignancy potential of submucosal tumors: a systematic review and meta-analysis. Surg Endosc 2020; 34: 3754–3765

[4] Chiu PW, Teoh AY, To KF et al. Endoscopic submucosal dissection (ESD) compared with gastrectomy for treatment of early gastric neoplasia: a retrospective cohort study. Surg Endosc 2012; 26: 3584–3591

[5] An W, Sun PB, Gao J et al. Endoscopic submucosal dissection for gastric gastrointestinal stromal tumors: a retrospective cohort study. Surg Endosc 2017; 31: 4522–4531

[6] Karaca C, Daglilar ES, Soyer OM et al. Endoscopic submucosal resection of gastric subepithelial lesions smaller than 20 mm: a comparison of saline solution-assisted snare and cap band mucosectomy techniques. Gastrointest Endosc 2017; 85: 956–962

[7] Tan Y, Tan L, Lu J et al. Endoscopic resection of gastric gastrointestinal stromal tumors. Transl Gastroenterol Hepatol 2017; 19: 115

[8] Andalib I, Yeoun D, Reddy R et al. Endoscopic resection of gastric gastrointestinal stromal tumors originating from the muscularis propria layer in North America: methods and feasibility data. Surg Endosc 2018; 32: 1787–1792

[9] Cho JW, Korean ESD Study Group. Current guidelines in the management of upper gastrointestinal subepithelial tumors. Clin Endosc 2016; 49: 235–240

[10] Wang XY, Xu MD, Yao LQ et al. Submucosal tunneling endoscopic resection for submucosal tumors of the esophagogastric junction originating from the muscularis propria layer: a feasibility study (with videos). Surg Endosc 2014; 28: 1971–1977

[11] Chiu PW, Inoue H, Rösch T. From POEM to POET: Applications and perspectives for submucosal tunnel endoscopy. Endoscopy 2016; 48: 1134–1142

[12] Ye LP, Zhang Y, Mao XL et al. Submucosal tunneling endoscopic resection for small upper gastrointestinal subepithelial tumors originating from the muscularis propria layer. Surg Endosc 2014; 28: 524–530

[13] Chen T, Zhang C, Yao LQ et al. Management of the complications of submucosal tunneling endoscopic resection for upper gastrointestinal submucosal tumors. Endoscopy 2016; 48: 149–155

[14] Aslanian HR, Sethi A. ASGE Technology Committee. et al. ASGE guideline for endoscopic full-thickness resection and submucosal tunnel endoscopic resection. VideoGIE 2019; 29: 343–350

[15] Deprez PH, Moons LMG, O'Toole D et al. Endoscopic management of subepithelial lesions including neuroendocrine neoplasms: European Society of Gastrointestinal Endoscopy (ESGE) Guideline. Endoscopy 2022: doi:10.1055/a-1751-5742

[16] Chiu PWY, Yip HC, Teoh AYB et al. Per oral endoscopic tumor (POET) resection for treatment of upper gastrointestinal subepithelial tumors. Surg Endosc 2019; 33: 1326–1333

[17] Agaimy A, Wünsch PH, Hofstaedter F et al. Minute gastric sclerosing stromal tumors (GIST tumorlets) are common in adults and frequently show c-KIT mutations. Am J Surg Pathol 2007; 31: 113–120

[18] Trindade AJ, Benias PC, Alshelleh M et al. Fine-needle biopsy is superior to fine-needle aspiration of suspected gastrointestinal stromal tumors: a large multicenter study. Endosc Int Open 2019; 7: E931–E936

[19] Kushnir VM, Keswani RN, Hollander TG et al. Compliance with surveillance recommendations for foregut subepithelial tumors is poor: results of a prospective multicenter study. Gastrointest Endosc 2015; 81: 1378–1384

[20] Zhang XC, Li QL, Yu YF et al. Diagnostic efficacy of endoscopic ultrasound-guided needle sampling for upper gastrointestinal subepithelial lesions: a meta-analysis. Surg Endosc 2016; 30: 2431–2441

[21] Godat S, Robert M, Caillol F et al. Efficiency and safety of endoscopic resection in the management of subepithelial lesions of the stomach. United Europ Gastroenterol J 2016; 4: 250–256

[22] Du C, Chai N, Linghu E et al. Treatment of cardial submucosal tumors originating from the muscularis propria layer: submucosal tunneling endoscopic resection versus endoscopic submucosal excavation. Surg Endosc 2018; 32: 4543–4551

[23] Lu J, Jiao T, Zheng M et al. Endoscopic resection of submucosal tumors in muscularis propria: the choice between direct excavation and tunneling resection. Surg Endosc 2014; 28: 3401–3407

[24] Zhang Q, Gao LQ, Han ZL et al. Effectiveness and safety of endoscopic resection for gastric GISTs: a systematic review. Minim Invasive Ther Allied Technol 2018; 27: 127–137

[25] Joo MK, Park JJ, Kim H et al. Endoscopic versus surgical resection of GI stromal tumors in the upper GI tract. Gastrointest Endosc 2016; 83: 318–326