

Endoscopy International Open

Novel treatment with double scope technique for disconnected pancreatic duct syndrome with external pancreatic fistula

Vikas Singla, pankaj K gupta, Pankaj Singh, Sawan Bopanna, Muzaffer R Shawl, Harish Soni, Akash Goel, Kaushal Madan, Pallavi Garg, Richa Bhargava.

Affiliations below.

DOI: 10.1055/a-2290-0768

Please cite this article as: Singla V, gupta p K, Singh P et al. Novel treatment with double scope technique for disconnected pancreatic duct syndrome with external pancreatic fistula. Endoscopy International Open 2024. doi: 10.1055/a-2290-0768

Conflict of Interest: The authors declare that they have no conflict of interest.

Abstract:

Background: External pancreatic fistula in association with disconnected pancreatic duct syndrome is a common sequelae of the percutaneous step-up approach for infected pancreatic necrosis and is associated with significant morbidity. The present study aims to report the initial outcome of a novel technique of two-scope guided tractogastrostomy for the management of this condition.

Methods: The present study is a retrospective analysis of the data of the patients with external pancreatic fistula and disconnected pancreatic duct syndrome, who underwent two scope guided tractogastrostomy. All the patients had 24 Fr or larger drain placed in the left retroperitoneum. Transgastric echo endoscopy and sinus tract endoscopy were performed simultaneously to place a stent between the gastric lumen and the sinus tract. Technical success was defined as the placement of stent between the tract and the stomach. Clinical success was defined as the successful removal of the percutaneous drain without the occurrence of pancreatic fluid collection, ascites, external fistula, or another intervention after 12 weeks of the procedure.

Results: Three patients underwent two scope-guided tractogastrostomy. Technical and clinical success could be achieved in all the patients. No procedure-related side effects or recurrence occurred in any patient.

Conclusion: Two-scope guided tractogastrostomy for treatment of external pancreatic fistula due to disconnected pancreatic duct syndrome is a feasible technique and can be further evaluated.

Corresponding Author:

Dr. Vikas Singla, Max Super Speciality Hospital Saket, 1. Institute of Liver and Gastrointestinal Sciences, New Delhi, India, singlavikas1979@gmail.com

Affiliations:

Vikas Singla, Max Super Speciality Hospital Saket, 1. Institute of Liver and Gastrointestinal Sciences, New Delhi, India

pankaj K gupta, Max Super Speciality Hospital Saket, Gastroenterology, New Delhi, India

Pankaj Singh, Max Super Speciality Hospital Saket, 1. Institute of Liver and Gastrointestinal Sciences, New Delhi, India

[...]

Richa Bhargava, Max Super Speciality Hospital Saket, 1. Institute of Liver and Gastrointestinal Sciences, New Delhi, India

Introduction

The step-up approach has emerged as the preferred treatment option for the management of symptomatic pancreatic necrosis [1]. Endoscopic or percutaneous step-up approaches are performed depending on the location of the collection, feasibility, and institutional preference [2]. The endoscopic approach has a lesser chance of external pancreatic fistula (EPF) formation than the percutaneous approach [2]. Pancreatic juices secreted by the viable pancreatic parenchyma take the path of least resistance through the drainage catheter. Partial disruption can be treated with endoscopic retrograde cholangiopancreatography (ERCP), sphincterotomy, and bridging the site of disruption with prosthesis. In patients with, disconnected pancreatic duct syndrome (DPDS), due to complete disruption of the pancreatic duct, bridging of the leakage site may fail during ERCP, and is a predictor of failure [3]. Surgery and complex endoscopic techniques have been advocated for the management of these patients, with variable success rates [4-6]. Technically easier, reproducible, and safer techniques with wider acceptability are required for the management of the complex situation of DPDS with EPF. We are treating patients with DPDS and EPF with a novel technique using two endoscopes, where a stent is placed between the stomach and the drainage tract, diverting the pancreatic secretions from the tract to the gastric lumen. The present study aims to present the initial experience of this novel technique in patients with DPDS and EPF.

Methods

The present study is a retrospective analysis of a prospectively collected database of patients with EPF following a percutaneous step-up approach for acute pancreatitis. The database between July 2021 to December 2023 was searched to identify patients of DPDS who underwent internalization of EPF using a novel two-scope technique. The institutional review board approved the study protocol (BHR/RS/MSSH/DDF/SKT2/IEC/LGS/23-21). EPF was defined as the draining of more than 100 mL of amylase-rich fluid through the percutaneous tube, persisting after the stabilization of an episode of acute pancreatitis. DPDS was defined based on magnetic resonance cholangiopancreatography (MRCP) findings [7, 8]. MRCP criteria were complete ductal discontinuation with residual upstream pancreatic parenchyma (Figure 1).

The technique of endoscopic treatment of external pancreatic fistula (Video 1)

A novel EUS-guided drainage technique was attempted in patients of DPDS with EPF who had percutaneous drain (PCD) placed of at least 24 Fr in the left retroperitoneum to facilitate easy passage of the ultrathin endoscope inside the tract. Informed consent for the procedure was obtained from all the patients. All the procedures were performed in the supine position, under general anesthesia and endotracheal intubation. For this novel technique, simultaneous sinus tract endoscopy and the peroral transgastric echo endoscopy were performed by 2 different endoscopists using CO₂ insufflation. The percutaneous drain tube was removed, followed by the insertion of an ultrathin endoscope (5.2mm, Olympus, Gurugram, India) in the drain tract (Figure 2). After endoscopic evaluation of the tract and residual cavity, normal saline was flushed through the accessory channel of the ultrathin scope. At the same time, an Endoscopic ultrasound examination was performed with a linear echoendoscope (Olympus GF UCT 180, ME-2 premium plus processor, Gurugram India), and the pancreas was scanned through the duodenal bulb and proximal gastric body. Saline flushed through the ultrathin scope led to transient fluid pool formation in the tract, which could be visualized with an echoendoscope in the proximal stomach. The pool of fluid was punctured with a 19G needle (Expect 19G, Boston Scientific, Gurugram, India), followed by passage of a guidewire (0.025'' 450 cm, J shape, Visiglide, Olympus) through the needle. Both the needle and the guidewire could be visualized in the tract under direct vision with ultrathin scope. The wire was grasped with forceps passed through the accessory channel of the ultrathin endoscope. Both the ultrathin scope and the forceps were pulled out of the sinus tract and the wire was secured at the percutaneous site. Through the echoendoscope, over the wire dilatation was performed with 6 Fr cystotome (Endoflex, GmbH, Voerde, Germany, pure cut mode, effect 5, 100W) and 6mm (Hurricane, Boston Scientific, Gurugram, India) balloon. Either one or two double pigtail plastic stents (10fr x 5 cm, C-Flex Boston Scientific, Gurugram, India) were placed between the gastric lumen and tract. After the completion of the procedure, a stoma bag was attached to the PCD site. Daily output was monitored and the stoma bag was removed after the complete cessation of the fluid discharge through the PCD site. Broad-spectrum injectable antibiotic ceftriaxone was administered before the procedure and continued for 3 days after the procedure. Patients were extubated in the operative room and were monitored for vital signs and pain abdomen. In the absence of any complications, a liquid diet was started after 24 hours of the procedure. In case of uneventful recovery, patients were discharged after 72 hours of the procedure and followed in the clinic.

During follow-up, Ultrasonography was performed at 15 days, every month for 3 months, and then every 6 months. CT scan or MRI was performed if the ultrasonography was non-informative or in case of suspicion of complication.

Study Definitions:

Procedure time: Time between insertion of ultrathin scope in sinus tract and placement of stent between gastric lumen and sinus tract

Technical success: Successful placement of stent between the gastric lumen and sinus tract to create tractogastrostomy.

Clinical success: Successful closure of EPF with complete cessation of drainage of pancreatic juice from cutaneous site and no formation of new fluid collection or ascites during 12 weeks after the procedure without any need for additional endoscopic or surgical procedure.

Results (Tables 1 and 2)

Three male patients underwent EUS-guided tractogastrostomy for EPF associated with DPDS. All three patients developed external pancreatic fistula after drain placement as part of a percutaneous step-up approach for acute pancreatitis. The minimum duration between the onset of acute pancreatitis and stent placement was 62 days. One patient had developed EPF after severe pancreatitis and 2 patients had moderately severe pancreatitis. All patients had undergone sinus tract necrosectomy because of persistent sepsis.

The duration for the first procedure was 75 minutes and was reduced to 25 minutes in the third procedure. The drain tube could be easily identified with an echoendoscope and removed followed by Ultrathin scope placement inside the tract in all patients. Fluid-filled tract could be well appreciated with an echoendoscope, followed by successful puncture in all the patients. Two stents were placed in one patient, and one stent was placed in the other two patients. Technical and clinical success could be achieved in all patients. The fistula closed in all the patients at 24 hours. No procedure-related complication occurred. No patient developed a recurrence of fluid collection or complication during follow-up.

Discussion

External pancreatic fistula can occur during the percutaneous step-up approach for acute pancreatitis and can be treated with conservative care or ERCP [9]. DPDS with EPF is a predictor of failure of ERCP and warrants either surgery or complex endoscopic treatments. The principle of the treatment is either resection of the upstream pancreas or diverting the secretion of the upstream pancreas to either gastric or intestinal lumen. Various complex endoscopic techniques have been described for the same. Either the sinus tract or pancreatic duct if dilated can be connected to the gastric or intestinal lumen. Tractogastrostomy, connecting the residual sinus tract to the gastric lumen, involves passing a wire across the wall of the tract into the gastric or intestinal lumen or vice versa, followed by placement of stent between the tract and intestinal or gastric lumen. The limiting step of the procedure is the puncture of the collapsed tract. The wall of the tract can be punctured from the luminal side or the drain site and both techniques have been described previously.

In the transgastric puncture technique, the tract is distended with fluid either by clamping the external drain, or injecting fluid through the catheter leading to the formation of fluid collection, which can be drained endoscopically. The technique may not be successful in all cases, as the collection formation may not occur due to fibrosis of the wall of the residual cavity or due to leakage of fluid along the drain. In a previous study, EUS-guided tractogastrostomy was performed by injecting fluid through the catheter, which could be visualized through the gastric wall under echo-endoscopic guidance [10]. Transient fluid-filled space was punctured with a needle followed by a passage of guidewire in the tract, which was manipulated to exit alongside the catheter, and a stent was placed between the tract and gastric lumen. The technique required enhanced manipulation of the guidewire to get the wire exit through the percutaneous drain site.

The other technique involves puncture through the wall of the residual tract from the drain site to the gastric or duodenal lumen. A combined endoscopic and percutaneous rendezvous technique to close EPF associated with DPDS has been explained, where a stiff guide wire and the transjugular intrahepatic portosystemic shunt needle were passed from the existing percutaneous site by an interventional radiologist under fluoroscopic guidance [5]. Thereafter, the impression of the needle was seen during endoscopy, which guided the

puncture site. An important limitation of the technique is that it is a blind outside-to-inside puncture with a theoretical risk of injury to blood vessels around the stomach or duodenum.

Tractogastrotomy either from the drain site or luminal site appears feasible and may obviate the need for the surgery. However, the technique remains challenging and is not widely practiced. The highlight of the present study is the use of two scopes simultaneously, which is likely to increase the success and safety of the procedure as the whole procedure is carried out under endoscopic and ultrasonographic guidance, which might lead to wider adoption of this technique. The potential benefits of using ultrathin scope and echoendoscope simultaneously are

1. A flexible ultrathin endoscope can be maneuvered in the sinus tract, and a fluid pool can be created at a desired location.
2. Optimum distention of the tract as fluid can be injected through the larger channel of the ultrathin endoscope
3. Visualization of needle and wire within the tract sinus tract, which can avoid inadvertent passage of needle and wire in the false tract.
4. Ease of bringing the wire to the percutaneous site, as the wire can be visualized and pulled out of the tract with an ultrathin endoscope
5. Use of echoendoscopy with doppler prevents the inadvertent puncture of the perigastric vessels.

The ease of the procedure is substantiated by the duration of the procedure which was reduced from 75 minutes in the first case to 25 minutes in the third case

Potential disadvantages of present procedure over the previously described techniques [6, 10], where fluid was infused through percutaneous drain and only linear echoendoscope was used, are,

1. Complex set up requiring two endoscopy towers equipped with CO2 insufflation.
2. Requirement of two expert endoscopists for performing the procedure

The main limitation of the present study is the small number of patients. The results of the study need to be replicated in larger studies before the technique can be used widely.

To summarise, the novel two-scope technique is safe and feasible and may result in better outcomes and wider acceptability of this technique in the management of external pancreatic fistula.



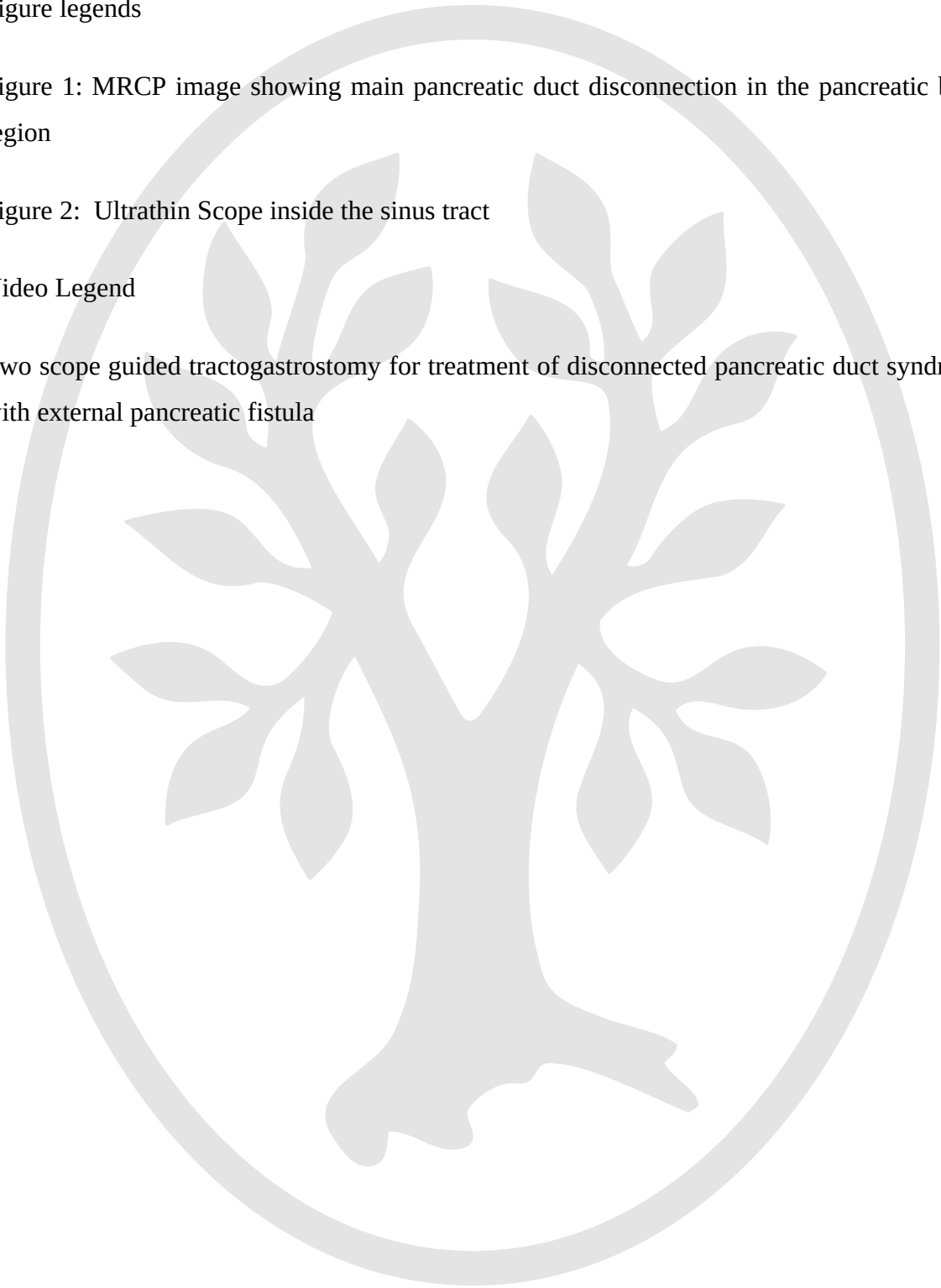
Figure legends

Figure 1: MRCP image showing main pancreatic duct disconnection in the pancreatic body region

Figure 2: Ultrathin Scope inside the sinus tract

Video Legend

Two scope guided tractogastrostomy for treatment of disconnected pancreatic duct syndrome with external pancreatic fistula



1. Van Santvoort HC, Besselink MG, Bakker OJ, et al. Dutch Pancreatitis Study Group. A step-up approach or open necrosectomy for necrotizing pancreatitis. *N Engl J Med* 2010; 362: 1491–1502.
2. Van Brunschot S, van Grinsven J, van Santvoort HC, et al. Endoscopic or surgical step-up approach for infected necrotising pancreatitis: a multicentre randomised trial. *Lancet*. 2018; 391: 51-58.
3. Varadarajulu S, Noone TC, Tutuian Z, et al. Predictors of outcome in pancreatic duct disruption managed by endoscopic transpapillary stent placement. *Gastrointest Endosc* 2005; 61: 568–575.
4. Arvanitakis M, Delhaye M, Bali MA, et al. Endoscopic treatment of external pancreatic fistulas: when draining the main pancreatic duct is not enough. *Am J Gastroenterol* 2007; 102 :516–524.
5. Irani S, Gluck M, Ross A, et al. Resolving external pancreatic fistulas in patients with disconnected pancreatic duct syndrome: using rendezvous techniques to avoid surgery (with video). *Gastrointest Endosc* 2012; 76: 586–93.
6. Rana SS, Sharma R, Gupta R. Endoscopic treatment of refractory external pancreatic fistulae with disconnected pancreatic duct syndrome. *Pancreatol* 2019; 19: 608–613.
7. Tann M, Maglinte D, Howard TJ, et al. Disconnected pancreatic duct syndrome: imaging findings and therapeutic implications in 26 surgically corrected patients. *J Comput Assist Tomogr* 2003; 27: 577–582.
8. Pelaez-Luna M, Vege SS, Petersen BT, et al. Disconnected pancreatic duct syndrome in severe acute pancreatitis: clinical and imaging characteristics and outcomes in a cohort of 31 cases. *Gastrointest Endosc* 2008; 68: 91–97.
9. Larsen M, Kozarek R. Management of pancreatic ductal leaks and fistulae. *Journal of Gastroenterology and Hepatology*. 2014; 29: 1360–70.

10. Singla V, Arora A, Rana SS et al. EUS-Guided Rendezvous and Tractogastrostomy: A Novel Technique for Disconnected Pancreatic Duct Syndrome with External Pancreatic Fistula. *J Digest Endosc* 2022; 13: 129-135.



Table : 1

Baseline characteristics of patients undergoing tractogastrostomy with newel 2 scopes technique

	Patient 1	Patient 2	Patient 3
Age, years	48	27	36
Gender	Male	Male	Male
Etiology	Biliary	Idiopathic	Idiopathic
No of Percutaneous catheters	One	One	one
Site of drain	Left retroperitoneum	Left retroperitoneum	Left retroperitoneum
Site of pancreatic ductal disconnection	Pancreatic body	Pancreatic body	Pancreatic body
The interval between onset of acute pancreatitis and procedure, days	62	65	90
Amount of fluid per day, ml/day	170	190	130
Fluid amylase value, units /Litre	12200	25300	14200

Table 2. Procedure related details of patients undergoing tractogastrostomy with newel 2 scopes technique

	Patient 1	Patient 2	Patient 3
Duration of the endoscopic procedure, minutes	75 minutes	45minutes	25 minutes
No of stents placed between the tract and gastric lumen	2	1	1
Immediate complication	Nil	Nil	Nil
Postoperative complication	Nil	Nil	Nil
Hospital stay after the procedure, days	2	3	2
Total duration of follow-up after the procedure, months	28	15	18
Recurrence of fluid collection or need for endoscopic/surgical intervention during follow-up	Nil	Nil	Nil

Video 1

0:00-0:10 - Removal of percutaneous drain

0:10-0:35 - Passage of ultrathin scope inside the sinus tract with endoscopic view

0:35-0:50 - Simultaneous passage of echoendoscope in stomach and sinus tract endoscopy

0:50-1:05 - Filling of the tract with water and visualization by echoendoscope

1:05-1:20 - Puncture of the wall of the tract with 19 G needle, visualization of the needle in tract with ultrathin scope

1:20-2:05 - Passage of guidewire and retrieval at percutaneous site

2:05-2:42 - Over the wire dilatation with 6 Fr cystotome

2:47-3:06 - Over the wire dilatation with a 6mm balloon

3:11-3:21 - Placement of stent between the gastric lumen and tract

3:29-3:50 - Passage of the second guidewire and over the wire dilatation with 6 mm balloon

3:58-4:15 - Placement of the second stent between the gastric lumen and the tract



