

Endoscopic detection of an early manifestation of EBV-related post-transplant lymphoproliferative disorder in a transplanted colon

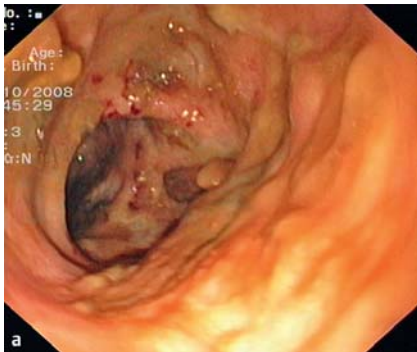
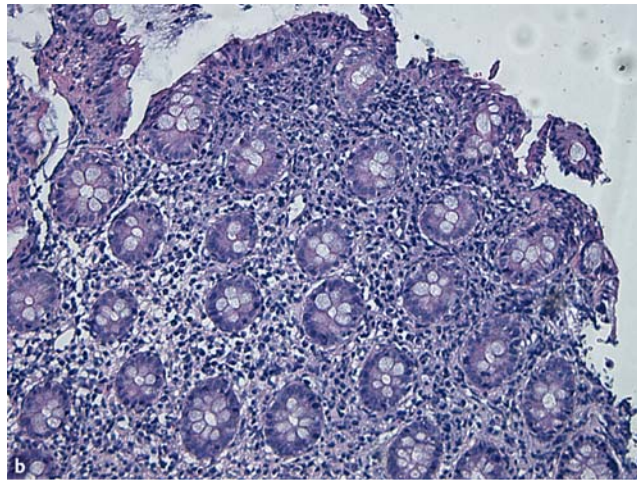
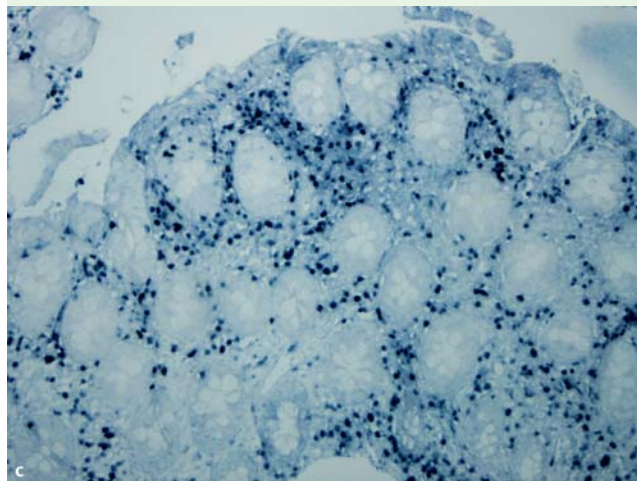


Fig. 1 a Colonoscopic view of transplanted colon 26 days after transplantation, showing erythema and easily bleeding epithelia.



b Biopsy specimen of donor colon, showing a polymorphous lymphocytic infiltrate in the lamina propria, non-tumor-forming (H&E, × 100).



c In situ hybridization for EBV-related small RNAs (EBERs) showing positive B cells surrounding negative crypts containing T cells.

Intestinal transplantation in children requires close follow-up, including endoscopic monitoring of the transplanted organ via the temporary stoma and/or anus with biopsies taken and reviewed. We present a case of post-transplant lymphoproliferative disorder (PTLD) diagnosed less than 1 month after transplantation. PTLD is a common life-threatening complication after intestinal transplantation, occurring in 13.5% of pediatric cases, and is mostly related to Epstein-Barr virus (EBV) [1, 2].

A 5-year-old boy presented with intestinal failure secondary to microvillus inclusion disease. He received an isolated intestinal allograft combined with a proximal colonic allograft. To monitor for rejection and inflammation, colonoscopy and endoscopic review through the stoma were performed twice a week in the first 2 weeks and once a week after that. Lesions were detected 26 days after transplantation (● Fig. 1 a).

Microscopy of the transplanted colon and the host colon revealed a polymorphous lymphocytic infiltrate in the lamina propria, non-tumor-forming (● Fig. 1 b). This

PTLD consisted of CD20- and CD79a-positive B cells that harbored EBV-related small RNAs (EBERs) as determined by in situ hybridization (● Fig. 1 c).

The tacrolimus dose was lowered. However, 6 days later endoscopic review showed that the lesions had grown and were also present in the donor proximal ileum (● Fig. 2 a).

Reduction of immunosuppressive therapy and administration of a monoclonal anti-

body directed against the B-cell receptor CD20 (rituximab) [3, 4] induced immediate regression of the lymphomas and complete remission of the disorder within 3 months after the first dose.

Six months after transplantation there was an acute episode of therapy-resistant rejection, which needed graft exploration and excision. The patient has been relisted for combined intestinal and liver transplantation. He is awaiting the retrans-

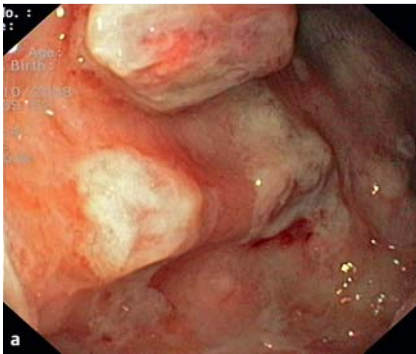
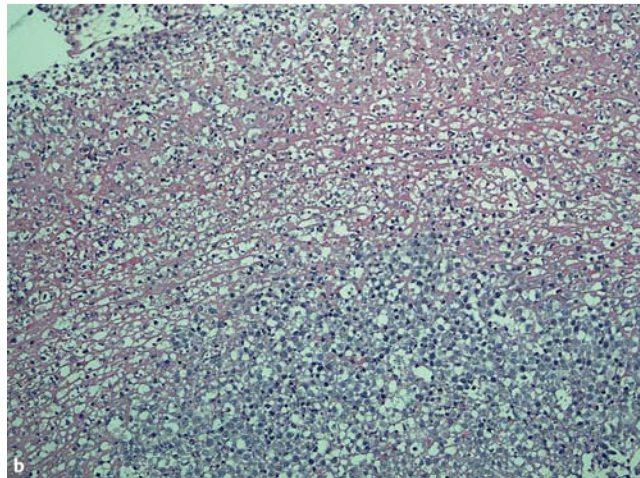
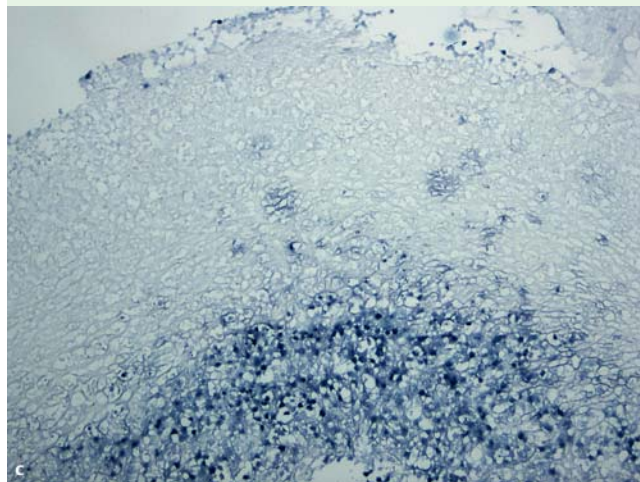


Fig. 2 a Colonoscopic view of transplanted colon 32 days after transplantation, showing tumor forming and white ulceration.



b Biopsy specimen of donor colon, showing ulceration of the colon epithelia with destruction of the crypts (H&E, × 100).



c In situ hybridization for EBERS showing positive B cells in the lamina propria, tumor forming.

plantation at home in a clinically stable condition. This case represents the earliest presentation of intestinal PTLTD found during routine endoscopic surveillance.

Acknowledgements

We would like to thank all members of the intestinal transplant team of the University Medical Center Groningen for their joint efforts to care for children with intestinal failure.

Endoscopy_UCTN_Code_CCL_1AD_2AJ

**M. W. van Ginkel¹, A. Diepstra²,
G. Dijkstra³, V. B. Nieuwenhuijs⁴,
Z. J. de Langen⁴, E. H. H. M. Rings¹**

¹ Division of Pediatric Gastroenterology, Department of Pediatrics, Beatrix Children's Hospital, University Medical Center Groningen, Groningen, The Netherlands

² Department of Pathology and Medical Biology. University Medical Center Groningen, Groningen, The Netherlands

³ Department of Gastroenterology, University Medical Center Groningen, Groningen, The Netherlands

⁴ Department of Surgery, University Medical Center Groningen, Groningen, The Netherlands

References

- 1 Intestinal Transplant Registry May 31, 2003. <http://www.intestinaltransplant.org/>; Publication date: 2003
- 2 Tanner JE, Alfeiri C. The Epstein-Barr virus and post transplant lymphoproliferative disease: interplay of immunosuppression, EBV, and the immune system in disease pathogenesis. *Transpl Infect Dis* 2001; 3: 20–69
- 3 Choquet S, Leblond V, Herbrecht R et al. Efficacy and safety of rituximab in B-cell post-transplantation lymphoproliferative disorders: results of a prospective multicenter phase 2 study. *Blood* 2006; 107: 3053–3057
- 4 Svoboda J, Kotloff R, Tsai DE. Management of patients with post-transplant lymphoproliferative disorder: the role of rituximab. *Transpl Int* 2006; 19: 259–269

Bibliography

DOI 10.1055/s-0029-1243865
Endoscopy 2010; 42: E101–E102
© Georg Thieme Verlag KG Stuttgart · New York ·
ISSN 0013-726X

Corresponding author

E. H. H. M. Rings, MD, PhD
Beatrix Children's Hospital
University Medical Center Groningen
University of Groningen
P.O. Box 30.001
9700 RB Groningen
The Netherlands
Fax: +31-50-3614235
e.h.h.m.rings@bkk.umcg.nl