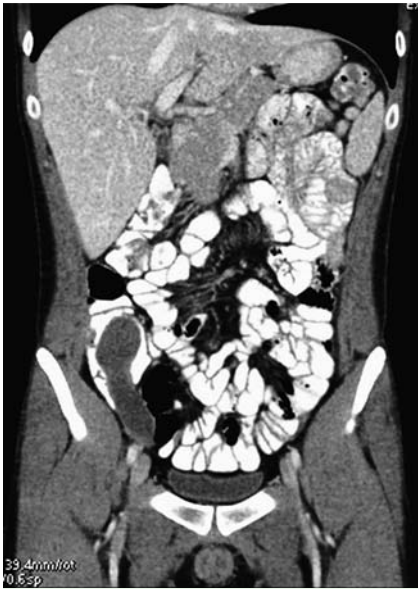
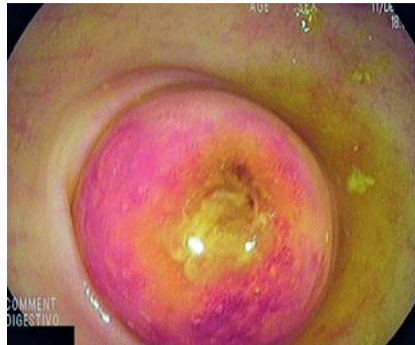
## Appendiceal mucocele in a young patient – does size matter?



**Fig. 1** Computed tomography (CT) image showing a 10 × 3.5-cm oval neoplasm with well-demarcated, thin walls in the appendiceal region in contact with the ascending colon.

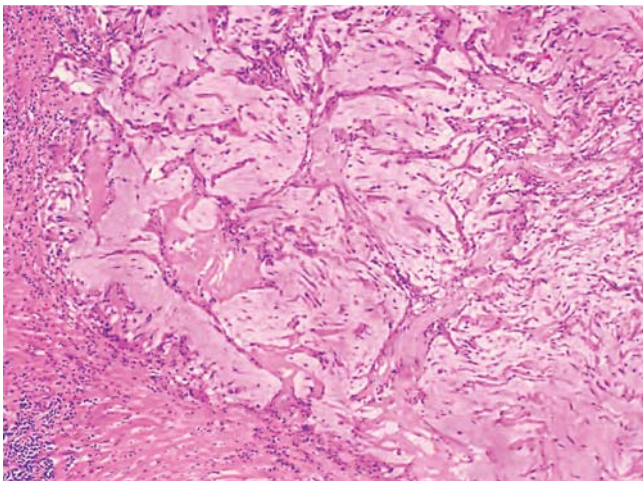
A 22-year-old man was admitted because of abdominal pain localized to the right iliac fossa. An abdominal ultrasound scan was performed, which revealed a 3.5 × 8-cm mass with heterogeneous content and calcified walls in close proximity to the ascending colon. A computed tomography (CT) scan of the abdomen showed a 10 × 3.5-cm mass in the region of the appendix with homogeneous density, thin walls, and some small areas of calcification (▶ **Fig. 1**). A colonoscopy was subsequently performed,



**Fig. 2** Colonoscopic view showing a submucosal lesion protruding from the appendiceal area with the typical “volcano sign” and erythematous mucosa.

which revealed a 5-cm mass protruding from the appendiceal area with a central orifice and surrounding erythematous mucosa (▶ **Fig. 2**). A laparotomy and appendectomy were performed, removing an 8 × 3.5-cm mass without damaging the integrity of its surface. An exploration of the cecum showed that it was not affected. Following histopathological analysis of the resected tissue, the patient was diagnosed as having a simple or retention appendiceal mucocele (▶ **Fig. 3**).

The term “appendiceal mucocele” refers to obstruction and dilatation of the appendiceal lumen due to accumulation of mucoid substance; it can be a benign or malignant process. Appendiceal mucoceles can be classified into four histopathological groups: simple or retention mucoceles, mucosal hyperplasia (5%–25% of the total), cystadenomas (63%–84%), and mucin-



**Fig. 3** Histological appearance of the appendectomy specimen showing pools of mucus, with low cellularity and without atypia, that dissect the muscular layer, compatible with a retention appendiceal mucocele.

nous cystadenocarcinomas (11%–20%) [1].

Mucoceles account for about 0.2%–0.3% of appendectomies [2]. Their clinical manifestations are usually nonspecific; up to 50% of cases are asymptomatic [3]. The typical endoscopic appearance is of a submucosal lesion with bright mucosa protruding over the appendiceal lumen, and sometimes the “volcano sign”, a central orifice in the middle of the protruding mucosa, can be seen [4].

Appendiceal mucoceles smaller than 2 cm are rarely malignant; those larger than 6 cm are usually considered malignant with a high risk of rupture (20%) [5]. In such cases, surgical treatment is always indicated because of the high risk that the mucocele will become malignant.

Endoscopy\_UCTN\_Code\_CCL\_1AD\_2AJ

**Competing interests:** None

**P. Cordero-Ruiz, J. Romero-Vázquez, F. Pellicer-Bautista, J. M. Herreras-Gutiérrez**

Gastroenterology Service, Virgen Macarena University Hospital, Seville, Spain

### References

- 1 Higa E, Rosal J, Pizzimbono C, Wise L. Mucosal hyperplasia, mucinous cystadenoma and mucinous cystadenocarcinoma of the appendix. *Cancer* 1973; 32: 1525–1541
- 2 Woodruff R, McDonald J. Benign and malignant cystic tumors of the appendix. *Surg Gynecol Obstet* 1940; 71: 751–755
- 3 Chou JW, Feng CL, Lai HC. Appendiceal mucocele presenting with lower abdominal pain. *Endoscopy* 2009; 41 Suppl 2: E222–E223
- 4 Hamilton DL, Stormont JM. The volcano sign of appendiceal mucocele. *Gastrointest Endosc* 1989; 35: 453–456
- 5 Stocchi L, Wolff BC, Larson DR, Harrington JR. Surgical treatment of appendiceal mucocele. *Arch Surg* 2003; 138: 585–590

### Bibliography

DOI 10.1055/s-0030-1256527

*Endoscopy* 2011; 43: E243

© Georg Thieme Verlag KG Stuttgart · New York · ISSN 0013-726X

### Corresponding author

**J. Romero-Vázquez, MD**

Virgen Macarena University Hospital

Avda Dr. Fedriani s/n

P.O. Box 41071

Seville

Spain

Fax: +34-95-5008805

javiromerov@telefonica.net