

## Intraluminal injection of indigo carmine facilitates identification of the afferent limb during double-balloon ERCP

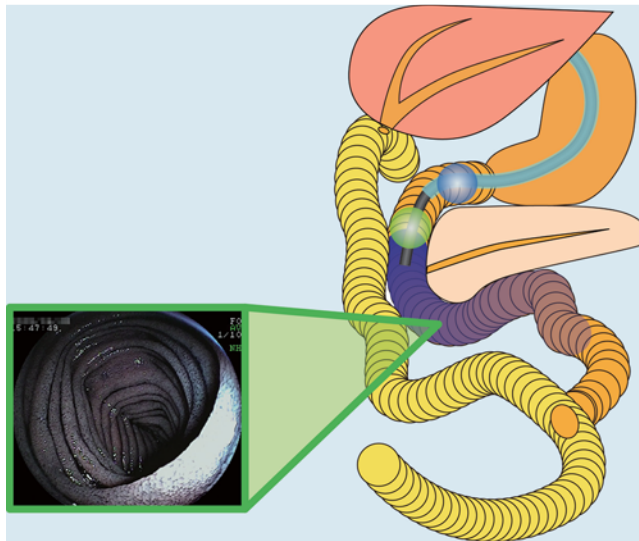
Double-balloon endoscopy facilitates endoscopic retrograde cholangiopancreatography (ERCP) in patients with a Roux-en-Y anastomosis [1]. However, it is difficult to identify the afferent limb during double-balloon ERCP [2]. According to retrospective data from February 2007 to January 2009, the rate of accurate identification was 50% (14/28). We report a useful technique to identify the afferent limb of the Roux-en-Y anastomosis during double-balloon ERCP.

In the second portion of the duodenum or at the distal site of the esophagojejunostomy, after inflation of a balloon at the tip of the endoscope to prevent backflow, 50 ml of 0.2% indigo carmine was injected into the lumen using the accessory channel (● Fig. 1). At the Roux-en-Y site, we evaluated the inflow of indigo carmine into both limbs and identified the limb with less inflow as the afferent limb (● Fig. 2).

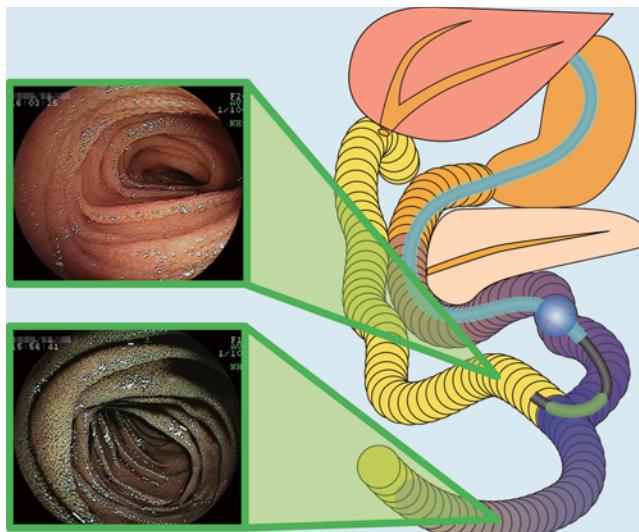
Between February 2009 and September 2011, this technique was used and evaluated prospectively in 52 consecutive patients with a Roux-en-Y anastomosis. Of the 52, 11 patients were excluded because of the following: unrecognized Roux-en-Y in 3, inaccessible Roux-en-Y in 2, and no indigo carmine at the Roux-en-Y in 6. In 33 of the remaining 41 patients (80%), the afferent limb was accurately identified. In 5 patients, identification was difficult because the amount of inflow was similar in both limbs. In 3 patients, the identification was incorrect.

This technique is based on the theory that little indigo carmine will flow into the afferent limb, but the dye will easily flow into the efferent limb by peristalsis. Double-balloon ERCP is usually performed with the patient in the left lateral position. In some patients, the influence of gravity on the inflow of indigo carmine made identification of the afferent limb difficult or led to incorrect identification.

Intraluminal injection of indigo carmine facilitates identification of the afferent limb during double-balloon ERCP in patients with a Roux-en-Y anastomosis.



**Fig. 1** After inflation of a balloon at the tip of the endoscope to prevent backflow, 50 ml of 0.2% indigo carmine was injected into the lumen using the accessory channel.



**Fig. 2** At the site of the Roux-en-Y anastomosis, we evaluated the inflow of indigo carmine into both limbs and identified the limb with less inflow as the afferent limb.

Endoscopy\_UCTN\_Code\_TTT\_1AR\_2AK

**Competing interests:** Yamamoto has applied for a patent in Japan for the double-balloon system described in the article. All other authors disclosed no financial relationships relevant to this publication.

**T. Yano, H. Hatanaka, H. Yamamoto, K. Nakazawa, N. Nishimura, S. Wada, K. Tamada, K. Sugano**

Department of Medicine, Division of Gastroenterology, Jichi Medical University, Shimotsuke, Tochigi, Japan

### Acknowledgments

▼ We thank Professor Alan Lefor of the Department of Surgery at Jichi Medical University for language editing of the manuscript.

## References

- 1 Haruta H, Yamamoto H, Mizuta K et al. A case of successful enteroscopic balloon dilation for late anastomotic stricture of choledochojejunostomy after living donor liver transplantation. *Liver Transpl* 2005; 11: 1608–1610
- 2 Shimatani M, Matsushita M, Takaoka M et al. Effective “short” double-balloon enteroscope for diagnostic and therapeutic ERCP in patients with altered gastrointestinal anatomy: a large case series. *Endoscopy* 2009; 41: 849–854

## Bibliography

**DOI** <http://dx.doi.org/10.1055/s-0032-1309865>  
*Endoscopy* 2012; 44: E340–E341  
© Georg Thieme Verlag KG  
Stuttgart · New York  
ISSN 0013-726X

## Corresponding author

**T. Yano, MD, PhD**  
Department of Medicine  
Division of Gastroenterology  
Jichi Medical University  
3311-1 Yakushiji, Shimotsuke  
Tochigi 329-0498  
Japan  
Fax: +81-285-44-8297  
tomonori@jichi.ac.jp