Calcium polystyrene sulfonate bezoar in the ileum: diagnosis and treatment with double-balloon endoscopy

An 86-year-old man, admitted for transarterial chemoembolization of a hepatoma, developed fever and acute renal failure following the procedure. He was given antibiotic therapy and oral calcium polystyrene sulfonate (30 g daily) for hyperkalemia. After 1 week, the patient developed bilious vomiting with abdominal pain. An abdominal X-ray disclosed diffuse dilatation of the small bowel (**Fig. 1**) and computed tomography was suspicious for a bezoar in the ileum along with intestinal obstruction (**Fig. 2**). A surgeon was consulted but surgical therapy was declined due to the high surgical risk. The patient received conservative medical therapy but his intestinal obstruction failed to resolve. A decision was made to carry out retrograde enteroscopy to emove the bezoar. When the ileum was entered, we found a large, tubular-shaped, firm yellowish bezoar occupying the intestinal lumen (**Fig. 3** and **Video 1**). There were also some ileal ulcers. Irrigation with water and fragmentation using a snare helped mobilize the bezoar. Multiple small brownish granules were seen after the bezoar was fragmented (**Fig. 4**) and the aspirated fluid contained resin granules. Given the endoscopic findings and the drug history of the patient, he was diagnosed as having a calcium polystyrene sulfonate resin-associated bezoar. Despite the efforts to remove the bezoar, the patient died of multiple organ failure 1 month later.

Calcium polystyrene sulfonate is an exchange resin used to treat hyperkalemia. A few cases of resin-related bezoars with intestinal obstruction have been reported [1–3]. Such bezoars most often form in critically ill infants [1–3] or in debilitated elderly patients with decreased bowel mobility and prolonged usage of the agent. The treatment of polystyrene sulfonate-related intestinal obstruction is surgery; only one case of non-surgical management has been reported [3]. The present case report documents the endoscopic findings related to resin-associated bezoar. In addition, we have found enteroscopy may be a useful tool in the treatment of intestinal obstruction resulting from the presence of such a bezoar.

Fig. 1 Abdominal X-ray showing diffuse small-bowel dilatation in an 86-year-old man with a drug-induced bezoar.

Fig. 2 Abdominal computed tomography (CT) showing radiopaque material (arrows) in the ileum and which caused the intestinal obstruction.

Video 1

A calcium polystyrene sulfonate resin-associated bezoar in the small intestine removed by endoscopic fragmentation.

Endoscopy_UCTN_Code_TTT_1AP_2AD

Competing interests: None

Fig. 3 Endoscopic view showed a large, tubular and firm, yellowish structure occupying the ileal lumen.

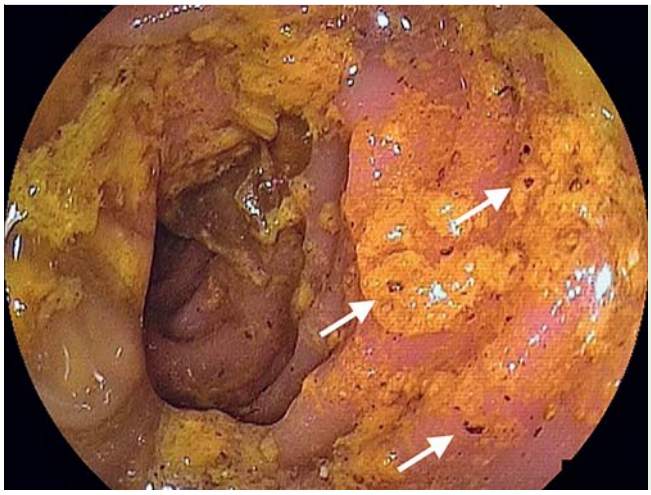

Fig. 4 Post-fragmentation endoscopic view of the bezoar. Multiple small granules (arrows) were observed.

Tien P. Lai[1], Chia W. Yang[2], Fu Y. Siaop[1], Hsu H. Yen[2]

[1] Department of Emergency Medicine, Changhua Christian Hospital, Changhua, Taiwan, Republic of China
[2] Department of Gastroenterology, Changhua Christian Hospital, Changhua, Taiwan, Republic of China

References

1 *Metlay LA, Klionsky BL.* An unusual gastric bezoar in a newborn: Polystyrene resin and candida albicans. J Pediatr 1983; 102: 121–123
2 *Garcia-Pardo G, Martinez-Vea A, Auguet T* et al. Intestinal obstruction complicating calcium polystyrene sulphonate therapy. Nephrol Dial Transplant 1996; 11: 751
3 *Koneru P, Kaufman RA, Talati AJ* et al. Successful treatment of sodium PolyStyrene sulfonate bezoars with serial water-soluble contrast enemas. J Perinatol 2003; 23: 431–433

Bibliography

DOI http://dx.doi.org/10.1055/s-0033-1344835
Endoscopy 2013; 45: E378–E379

ISSN 0013-726X

Corresponding author

Hsu H. Yen
Endoscopy Center
Department of Gastroenterology
Changhua Christian Hospital
Changhua City
135 Nanhsiao Street Changhua
500 Taiwan
China
91646@cch.org.tw