

Surgical Therapy of Endometriosis: Challenges and Controversies

Herausforderungen und Kontroversen bei der operativen Therapie der Endometriose

Authors

S. Rimbach¹, U. Ulrich², K. W. Schweppe³

Affiliations

¹ Gynäkologie und Geburtshilfe, Landeskrankenhaus Feldkirch, Feldkirch, Austria

² Klinik für Gynäkologie und Geburtshilfe, Martin-Luther-Krankenhaus, Berlin

³ Endometriose-Zentrum Ammerland, Westerstede

Key words

- reproductive medicine
- dyspareunia
- endometriosis
- gynaecology
- infertility
- ovary

Schlüsselwörter

- Reproduktionsmedizin
- Dyspareunie
- Endometriose
- Gynäkologie
- Infertilität
- Ovar

received 4. 8. 2013

revised 4. 9. 2013

accepted 4. 9. 2013

Bibliography

DOI <http://dx.doi.org/10.1055/s-0033-1350890>
 Geburtsh Frauenheilk 2013; 73: 918–923 © Georg Thieme Verlag KG Stuttgart · New York · ISSN 0016-5751

Correspondence

Priv.-Doz. Dr. Stefan Rimbach
 Landeskrankenhaus Feldkirch
 Gynäkologie und Geburtshilfe
 Carinagasse 47
 6800 Feldkirch
 Österreich
 stefan.rimbach@vlkh.net

Abstract

▼
 Endometriosis is one of the most common disorders encountered in surgical gynaecology. The laparoscopic technique, the planning of the surgical intervention, the extent of information provided to patients and the interdisciplinary coordination make it a challenging intervention. Complete resection of all visible foci of disease offers the best control of symptoms. However, the possibility of achieving this goal is limited by the difficulty of detecting all foci and the risks associated with radical surgical strategies. Thus, the excision of ovarian endometrioma can result in a significant impairment of ovarian function, while damage to nerve structures during resection of the uterosacral ligaments, the parametrium, the rectovaginal septum or the vaginal cuff to treat deep infiltrating endometriosis can lead to serious functional impairments such as voiding disorders. A detailed risk-benefit analysis is therefore necessary, and patients must be treated using an individual approach.

Zusammenfassung

▼
 Die Endometriose gehört zu den häufigsten Krankheitsbildern in der operativen Gynäkologie mit erheblichen Herausforderungen an die laparoskopische Technik, aber auch die OP-Planung, Patientinnenaufklärung und Interdisziplinarität. Ziel im Hinblick auf eine bestmögliche Symptomkontrolle ist die vollständige Entfernung der erkennbaren Krankheitsherde, die aber limitiert wird durch nachweisliche Grenzen der Detektierbarkeit und die Risiken radikaler Operationsstrategien. So kann die Exzision ovarieller Endometriome zu einer signifikanten Beeinträchtigung der Ovarialfunktion, die Läsion nervaler Strukturen bei der Resektion tief-infiltrierender Endometriose der Sakrouterinligamente, der Parametrien, des Septum rectovaginale und des Vaginalpols zu schwerwiegenden Funktionsbeeinträchtigungen wie Blasenentleerungsstörungen führen. Eine gründliche Nutzen-Risiko-Abwägung muss daher symptomorientiert erfolgen und in einem individualisierten Vorgehen resultieren.

Introduction

▼
 Endometriosis is one of the most common gynaecological disorders but also one of the greatest challenges facing gynaecological surgeons [1]. A guideline-oriented approach [2], extensive experience of surgical techniques and interdisciplinary cooperation [3] are the prerequisites for successful treatment.

A detailed history of individual symptoms, adequate diagnostics and special surgical skills are indispensable for diagnosing endometriosis and for

preoperative planning and surgery [4]. It is also important that the surgeon and patient take the time to consider the “difficult”, in some instances, controversial, and potentially risky aspects of possible surgical interventions.

Factors to consider include individual risks, such as the risk of recurrence, as well as factors intrinsic to the disease and the risks associated with the surgical technique. This paper discusses several such combinations which deserve particular consideration due to their prevalence and potentially serious consequences.

Extent of Surgery and Dealing with Unexpected Findings

Both from the surgeon's and the patient's point of view, the extent of the actual manifestation of disease and the associated extent of the planned surgery are the most important preoperative considerations, but these are also the factors which are most difficult to assess preoperatively. Frequently, the extent of surgery will only become clear intraoperatively.

The lines of resection are primarily determined by the extent of disease spread. The goal of surgery is complete resection, which can include resection of parts of the intestine and involve the ureters and bladder [5–11].

In addition to the necessary surgical experience, a good interdisciplinary cooperation and close involvement of the patient are important during the planning stage. Despite adequate diagnostics, it may be necessary to broaden the scope of the primary intervention. This may also be unexpectedly necessary during surgery, for example, if there is intestinal involvement beyond the rectovaginal septum or non-obstructive involvement of the ureter (● Fig. 1 a and b).

This not untypical constellation represents a considerable challenge as regards the information routinely provided to the patient preoperatively and for surgical logistics. The problem is commonly tackled using one of two approaches: either a flexible surgical strategy with the patient given a maximum of information about all eventualities or a two-stage approach compatible with the disease constellation. It is important in every individual case to weigh up the psychological burden for the patient which may be affected by the amount of information given (which may be far too extensive) and, depending on the structure of the hospital department, the possibly unnecessary allocation of operating room capacity and interdisciplinary personnel resources against the disadvantages of a second operation.

In each case, clear positioning during preoperative planning is recommended to guard against surprises.

In addition to the extent of endometriosis, secondary factors such as the presence of adhesions or, in the case of the retroperitoneal space, the presence of fibrotic lesions also have a significant impact on surgery. These factors can change the anatomy to such an extent that extensive dissection is necessary for reconstruction. Intestinal adhesiolysis and extensive ureterolysis may be required to reach the endometriotic lesion and to avoid iatrogenic injury to structures close to the margins of the endometriotic lesion. At the same time, dissection is also associated with an intrinsic risk of injury.

Injuries are by no means rare; in fact, they are fairly common, particularly when treating deep infiltrating endometriosis, and require awareness and appropriate discussion preoperatively.

Limits of Detectability of Endometriotic Lesions and Differentiation from Healthy Tissue

The detection and differentiation of endometriotic lesions from healthy tissue is a challenge (● Fig. 2), particularly in cases of recurrence.

Out of a total of 39 patients with persistence of complaints after excision or ablation of histologically verified endometriosis, repeat laparoscopy found peritoneal recurrence in 37%. Recurrence occurred significantly more frequently in previously operated (RR 2.54; 95% confidence interval [CI]: 1.63–3.97) or immediate-

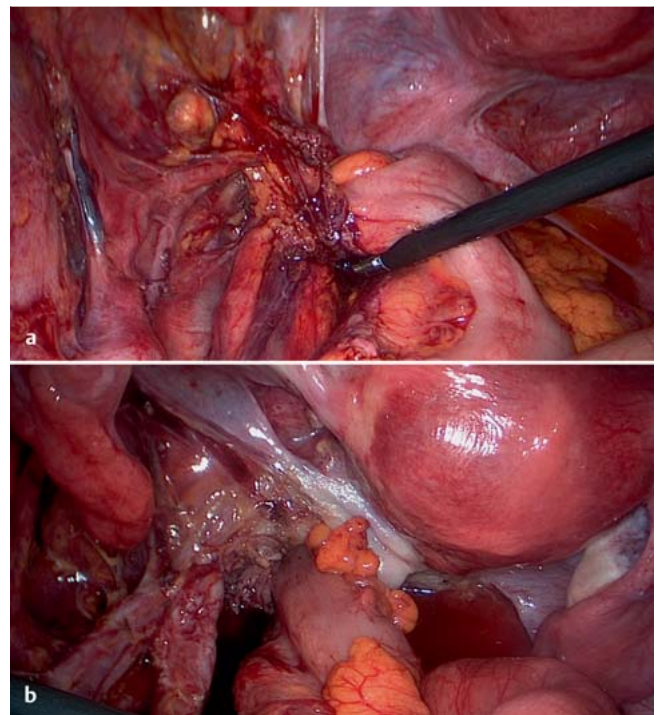


Fig. 1 a and b a Involvement of the left ureter in a case with rectosigmoid endometriosis. b After ureterolysis and rectosigmoid resection.

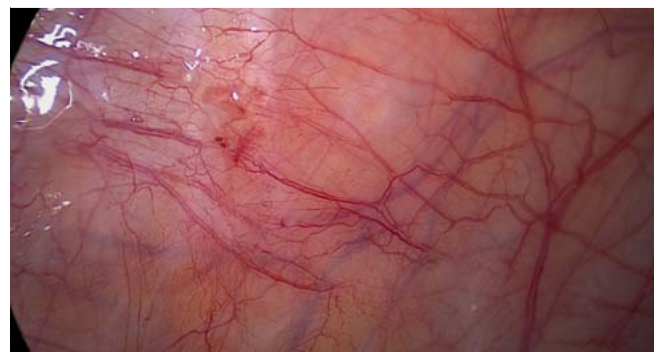

Fig. 2 Peritoneal endometriosis with unclear extent and spread: red lesions with typical vascular patterns next to fibrotic peritoneal defects.

ly adjacent (RR 1.29; 95% CI: 0.84–2.0) areas compared to areas distant to the original localisation, which supports the hypothesis that primary resection was probably incomplete [12]. The reason for this could be that endometriotic lesions in the peritoneum can extend far beyond the visible foci, as has been shown in examinations using scanning electron microscopy [13]. The presence of residual foci of endometriosis in a number of patients could also explain the success of a combined approach using surgery and hormone therapy. This interpretation is supported by the results of a prospective randomised study in 450 patients which compared outcomes after surgery, hormone therapy or combined surgery and hormone therapy. The combined approach had significantly better results, with a 60% success rate as measured by the clinical parameters “dysmenorrhea” and “dyspareunia” and findings at second-look laparoscopy, com-

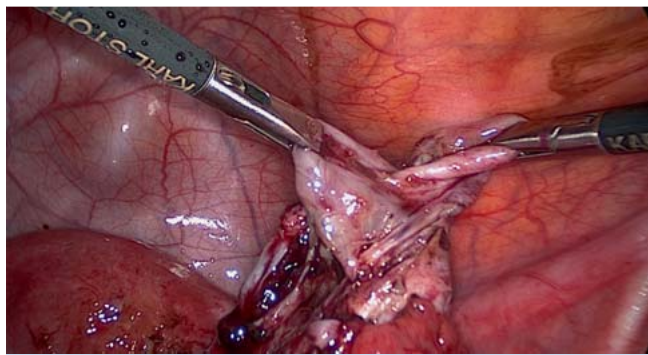


Fig. 3 Meticulous dissection to expose the cleavage plane in right-sided ovarian endometriosis.

pared to rates of 55% for exclusively hormone therapy and 50% for exclusively surgical treatment [14].

Radical Dissection: Opportunities and Risks

Peritoneal endometriosis

Exclusively endocrine therapy has been shown to have results comparable to the outcomes after surgery, at least for peritoneal endometriosis. Given the existing uncertainty about detecting the extent of endometriotic lesions and the potential use of exclusively endocrine therapy as an alternative to surgery [15, 16], it is important in individual cases to weigh the extent of the potential excision against the risk of overtreatment.

Ovarian endometriosis

After peritoneal endometriosis, the ovaries are the second most common site for endometriosis. But although surgery to treat ovarian endometriomas is assumed to be a routine procedure, it involves particular challenges for the surgeon.

As the reported rate of recurrence ranges from 9.6–45.5% [17, 18], the surgeon must weigh the necessity for adequate excision against the potential iatrogenic decrease in ovarian reserve. Analysis of anti-Müllerian hormone (AMH) levels showed that surgery for ovarian endometriosis was associated with a significant decrease in AMH concentrations [19–21]. AMH levels decreased by 24% after unilateral surgery and by up to 67% after bilateral surgery [22, 23].

Meticulous dissection to expose the correct cleavage plane (● **Fig. 3**) by an experienced surgeon taking special care to preserve the ovarian hilum is recommended as the optimal surgical technique [24–26]. The benefits of excision as opposed to electro-surgical ablation have been demonstrated and confirmed in an extensive meta-analysis [27–29]. The analysis by Dan and Limin [29] compared the data of seven studies and found that, compared to ablation, excision was associated with a significantly reduced risk of symptom recurrence (RR 0.29; 95% CI: 0.15–0.55; $p < 0.001$) and a significantly reduced rate of recurrence (RR 0.50; 95% CI: 0.26–0.97; $p = 0.04$). Recurrence rates after excision were also lower compared to laser vaporisation (RR 0.33; 95% CI: 0.12–0.88; $p = 0.03$). The achieved pregnancy rates after excision were also significantly better compared to electro-surgical coagulation (RR: 2.64; 95% CI: 1.49–4.69; $p < 0.001$), but not compared to laser vaporisation (RR: 0.92; 95% CI: 0.30–2.80; $p = 0.89$). Data on ovarian reserve was not analysed in this meta-analysis.

One study postulated that impairment of ovarian function could be prevented by replacing bipolar coagulation with a haemostatic suture [30], but this could not be confirmed in a prospective randomised study; instead, it was found that AMH levels decreased, irrespective of the technique used [31].

The indication for surgery requires the potential benefits of better pain management or better access to growing follicles in IVF, which would otherwise be obscured by endometrioma, to be weighed against a potentially significant impairment of ovarian reserve [32]. It is, of course, obvious that unclear ovarian masses need to be identified histologically.

Deep infiltrating endometriosis

The indication for surgery for deep infiltrating endometriosis is usually severe pain. Complete excision may require expanding the procedure to include the vagina, intestines and ureters, but complete surgery has been shown to control symptoms and reduce the rate of recurrence [7, 33–35]. The majority of procedures can be carried successfully using laparoscopy; the rate of conversion to laparotomy is between 1.6 and 12% [36–38].

In addition to the demanding surgical technique which requires a high degree of specialisation, other major challenges are planning and correctly determining the extent of surgery. A risk-benefit analysis weighing the benefits of pathological and anatomical radicality against benefits and risks of more limited procedures may be necessary. The question whether limited surgery could potentially not increase the rate of recurrence if the remnants left in situ in the intestine or vagina were asymptomatic preoperatively is still discussed controversially [39], but can obviously not always be estimated properly.

For specialised centres, the reported complication rates in the immediate postoperative period are 2–4% [8, 9], the overall rate of serious complications is 7–9% [36–38, 44] and the rate of recurrence is 8–13% [38, 40–42]. In view of the complexity of the intervention, these rates appear to be within “acceptable” ranges. However, the potentially serious nature of early and late complications and unwanted side-effects and outcomes may make the final result after surgery almost insupportable for individual patients.

Factors which need to be taken into account range from the general risks which depend on the extent of the intervention to the specific risks of surgery for endometriosis.

General risks can be irrespective of the diagnosis of endometriosis. For example, observational studies have reported a causal association between lengthy surgical procedures with the patient in the lithotomy position and serious lower limb compartment syndrome [43, 44].

Colorectal surgery is a common endometriosis-specific risk. In one case series, revision surgery after segmental resection was required in the first week after primary surgery in 4.1% of cases [9]. Anastomotic insufficiency was reported in 0.7–3% of cases [36, 45].

A protective ileostomy is done in 3–14.5% of cases. One study reported the regular creation of a protective ileostomy during surgery in 95.2% of cases [36, 38, 45, 46]. From a surgical point of view, this is not a complication but a necessary measure to avoid complications, but for a young woman with endometriosis this frequently constitutes a barrier against intervention when taking the decision to undergo surgery.

Another study reported late functional impairments which took the form of either severe constipation or pathologically increased frequency of daily stools in 52% of patients who had segmental

resection, and in 19% of patients who had nodule resection [47]. When surgery is adapted intraoperatively, the goal is to reduce the radicality of the procedure as far as possible. Less radical surgical techniques include the so-called shaving technique to preserve the intestinal wall [42] and discoid resection instead of segmental resection to preserve bowel continuity [48, 49]. Unfortunately there are no comparative prospective studies for these techniques. But adequate complete resection of the endometriotic nodule must be ensured, as otherwise there is an increased risk of recurrence. In the study of Brouwer and Woods, the recurrence rates of 2.19% after segmental rectal resection and 5.17% after full-thickness excision of the anterior rectal wall rose significantly to 22.2% after what was probably incomplete dissection off the rectal wall [45].

Another study reported severe urological complications such as hydronephrosis in 4.8%, urinary fistulas in 3% and bladder voiding dysfunction in 28.9% after colorectal resection with partial colectomy [50].

Voiding dysfunction rates after resection are reported to be 15–30%, but voiding dysfunction is likely to affect the majority of all patients in a mild and transient form after complex resection of deep infiltrating endometriosis and can even result in a permanent need for self-catheterisation. The cause of voiding dysfunction is autonomic nerve damage, particularly iatrogenic injury to the inferior hypogastric plexus at the proximal portion of the uterosacral ligament during resection of the uterosacral ligaments, of the parametrium, the deep rectum and the vaginal cuff [51–53] (● Fig. 4a und b). Postoperative rates of urinary dysfunction could be reduced if nerve structures are identified and spared intraoperatively [54, 55].

If hydronephrosis is present, ureteral involvement must always be considered; however, ureteral involvement may be silent and completely asymptomatic [56]. In one study of patients with retrocervical endometriosis in the vicinity of the uterosacral ligaments, ureteral involvement was present in 17.9% of cases with nodules ≥ 3 cm compared to 1.6% of cases with nodules < 3 cm [57]. Ureterolysis was reported to be successful in the majority of cases (53.8–73.3%) [56, 58, 59], but complication rates were between 23 and 31.4% [58, 59].

Special Situations: Adolescence and Recurrence

Both situations, although completely dissimilar, confront the surgeon with the same necessity to weigh the benefits against the risks of an invasive or repeat invasive procedure.

In adolescence, qualms about the invasiveness of laparoscopy may result in a delay in diagnosis of several years [60]. Further systematic reviews will be necessary to confirm the data of one study which reported the prevalence of endometriosis to be 70–75% in girls with therapy-resistant, chronic, pelvic pain and dysmenorrhea [61]. The limited data available on treatment outcomes is controversial. One study came to the conclusion, based on the data for re-interventions, that early laparoscopic excision had the potential to eradicate disease [62]. Another study of 57 women ≤ 21 years who underwent laparoscopy for endometriosis reported an unusually high rate of 56% of patients suspicious for recurrence and a constant increase in recurrence rates over the 5-year follow-up period and concluded, based on these data, that early surgical intervention was associated with a particularly high risk of recurrence [63].

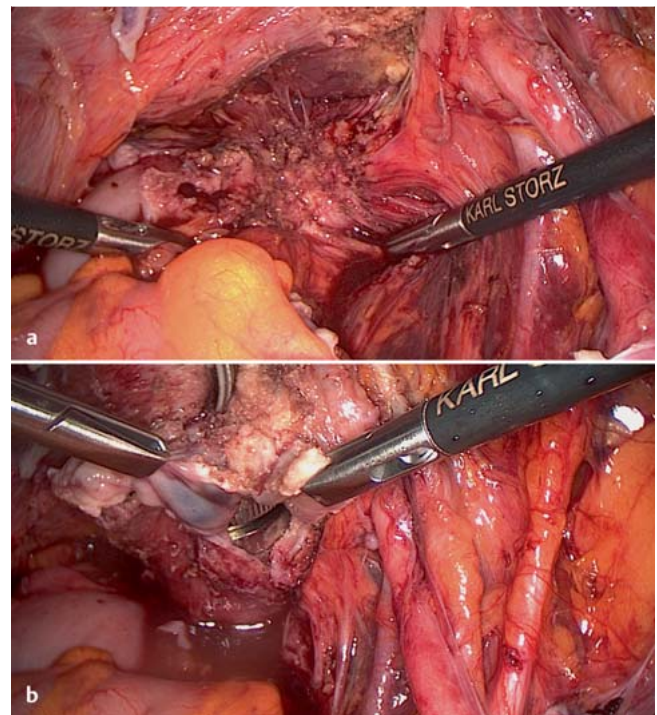


Fig. 4a and b a Endometriotic nodules with infiltration of the vaginal cuff; the fibres of the right inferior hypogastric plexus are immediately lateral to the nodules. b Resection of vaginal endometriosis preserving the inferior hypogastric plexus.

Caution is advised with regard to re-operations of patients with symptomatic recurrence, particularly patients who have had repetitive surgical interventions for endometriosis. The cumulative probability for further surgical interventions was found to be at least 15–20%, although the authors of the study surmised that publication bias meant that these data were probably an underestimate [64]. Re-operation for recurrence and pelvic pain was as efficacious as primary surgery and had comparable limitations [65]; however, with regard to the desire for conception, pregnancy rates after re-operation were only half of those achieved after primary operation.

Conclusion

The aim of this overview was to discuss controversial aspects and challenges in the surgical treatment of endometriosis. This discussion has made it clear that significant challenges still remain with regard to preoperative diagnosis and decision-making, the provision of information to patients and surgical techniques to treat endometriosis.

Conflict of Interest

None.

References

- 1 Deguara CS, Pepas L, Davis C. Does minimally invasive surgery for endometriosis improve pelvic symptoms and quality of life? *Curr Opin Obstet Gynecol* 2012; 24: 241–244
- 2 AWMF. Diagnostik und Therapie der Endometriose. AWMF Leitlinien Register 015/045. awmf.org/leitlinien/detail/ll/015-045.html
- 3 Wattiez A, Puga M, Albornoz J et al. Surgical strategy in endometriosis. *Best Pract Res Clin Obstet Gynaecol* 2013; 27: 381–392
- 4 Kondo W, Bourdel N, Zomer MT et al. Surgery for deep infiltrating endometriosis: technique and rationale. *Front Biosci (Elite Ed)* 2013; 5: 316–332
- 5 Berkes E, Bokor A, Rigó jr. J. Current treatment of endometriosis with laparoscopic surgery. *Orv Hetil* 2010; 151: 1137–1144
- 6 Fritzer N, Tammaa A, Salzer H et al. Effects of surgical excision of endometriosis regarding quality of life and psychological well-being: a review. *Womens Health (Lond Engl)* 2012; 8: 427–435
- 7 Koninckx PR, Ussia A, Adamyan L et al. Deep endometriosis: definition, diagnosis, and treatment. *Fertil Steril* 2012; 98: 564–571
- 8 Pandis GK, Saridogan E, Windsor AC et al. Short-term outcome of fertility-sparing laparoscopic excision of deeply infiltrating pelvic endometriosis performed in a tertiary referral center. *Fertil Steril* 2010; 93: 39–45
- 9 Minelli L, Ceccaroni M, Ruffo G et al. Laparoscopic conservative surgery for stage IV symptomatic endometriosis: short-term surgical complications. *Fertil Steril* 2010; 94: 1218–1222
- 10 Schonman R, Dotan Z, Weintraub AY et al. Deep endometriosis inflicting the bladder: long-term outcomes of surgical management. *Arch Gynecol Obstet* 2013; DOI: 10.1007/s00404-013-2917-6
- 11 Kovoov E, Nassif J, Miranda-Mendoza I et al. Endometriosis of bladder: outcomes after laparoscopic surgery. *J Minim Invasive Gynecol* 2010; 17: 600–604
- 12 Taylor E, Williams C. Surgical treatment of endometriosis: location and patterns of disease at reoperation. *Fertil Steril* 2010; 93: 57–61
- 13 Lessey BA, Higdon HL 3rd, Miller SE et al. Intraoperative detection of subtle endometriosis: a novel paradigm for detection and treatment of pelvic pain associated with the loss of peritoneal integrity. *J Vis Exp* 2012; DOI: 10.3791/4313
- 14 Alkatout I, Mettler L, Beteta C et al. Combined surgical and hormone therapy for endometriosis is the most effective treatment: prospective, randomized, controlled trial. *J Minim Invasive Gynecol* 2013; 20: 473–481
- 15 Vercellini P, Somigliana E, Consonni D et al. Surgical versus medical treatment for endometriosis-associated severe deep dyspareunia: I. Effect on pain during intercourse and patient satisfaction. *Hum Reprod* 2012; 27: 3450–3459
- 16 Vercellini P, Frattaruolo MP, Somigliana E et al. Surgical versus low-dose progestin treatment for endometriosis-associated severe deep dyspareunia II: effect on sexual functioning, psychological status and health-related quality of life. *Hum Reprod* 2013; 28: 1221–1230
- 17 Porpora MG, Pallante D, Ferro A et al. Pain and ovarian endometrioma recurrence after laparoscopic treatment of endometriosis: a long-term prospective study. *Fertil Steril* 2010; 93: 716–721
- 18 Hayasaka S, Ugajin T, Fujii O et al. Risk factors for recurrence and re-occurrence of ovarian endometriomas after laparoscopic excision. *J Obstet Gynaecol Res* 2011; 37: 581–585
- 19 Uncu G, Kasapoglu I, Ozerkan K et al. Prospective assessment of the impact of endometriomas and their removal on ovarian reserve and determinants of the rate of decline in ovarian reserve. *Hum Reprod* 2013; 28: 2140–2145
- 20 Raffi F, Metwally M, Amer S. The impact of excision of ovarian endometrioma on ovarian reserve: a systematic review and meta-analysis. *J Clin Endocrinol Metab* 2012; 97: 3146–3154
- 21 Streuli J, de Ziegler D, Gayet V et al. In women with endometriosis anti-Müllerian hormone levels are decreased only in those with previous endometrioma surgery. *Hum Reprod* 2012; 27: 3294–3303
- 22 Urman B, Alper E, Yakin K et al. Removal of unilateral endometriomas is associated with immediate and sustained reduction in ovarian reserve. *Reprod Biomed Online* 2013; 27: 212–216
- 23 Celik HG, Dogan E, Okyay E et al. Effect of laparoscopic excision of endometriomas on ovarian reserve: serial changes in the serum antimüllerian hormone levels. *Fertil Steril* 2012; 97: 1472–1478
- 24 Canis M, Kondo W, Botchorishvili R et al. Surgical arrows should be identified on the cyst wall. *Fertil Steril* 2013; 99: e7
- 25 Donnez J, Squifflet J, Jadoul P et al. Fertility preservation in women with ovarian endometriosis. *Front Biosci (Elite Ed)* 2012; 4: 1654–1662
- 26 Bourdel N, Roman H, Mage G et al. Surgery for the management of ovarian endometriomas: from the physiopathology to the pre-, peri- and postoperative treatment. *Gynecol Obstet Fertil* 2011; 39: 709–721
- 27 Somigliana E, Benaglia L, Viganò P et al. Surgical measures for endometriosis-related infertility: a plea for research. *Placenta* 2011; 32 (Suppl. 3): S238–S242
- 28 Hart RJ, Hickey M, Maouris P et al. Excisional surgery versus ablative surgery for ovarian endometriomata. *Cochrane Database Syst Rev* 2008; 2: CD004992
- 29 Dan H, Limin F. Laparoscopic ovarian cystectomy versus fenestration/coagulation or laser vaporization for the treatment of endometriomas: a meta-analysis of randomized controlled trials. *Gynecol Obstet Invest* 2013; 76: 75–82
- 30 Litta P, D'Agostino G, Conte L et al. Anti-Müllerian hormone trend after laparoscopic surgery in women with ovarian endometrioma. *Gynecol Endocrinol* 2013; 29: 452–454
- 31 Ferrero S, Venturini PL, Gillott DJ et al. Hemostasis by bipolar coagulation versus suture after surgical stripping of bilateral ovarian endometriomas: a randomized controlled trial. *J Minim Invasive Gynecol* 2012; 19: 722–730
- 32 Ruiz-Flores FJ, Garcia-Velasco JA. Is there a benefit for surgery in endometrioma-associated infertility? *Curr Opin Obstet Gynecol* 2012; 24: 136–140
- 33 Kössi J, Setälä M, Mäkinen J et al. Quality of life and sexual function 1 year after laparoscopic rectosigmoid resection for endometriosis. *Colorectal Dis* 2013; 15: 102–108
- 34 Setälä M, Härkki P, Matomäki J et al. Sexual functioning, quality of life and pelvic pain 12 months after endometriosis surgery including vaginal resection. *Acta Obstet Gynecol Scand* 2012; 91: 692–698
- 35 Bassi MA, Podgaec S, Dias jr. JA et al. Quality of life after segmental resection of the rectosigmoid by laparoscopy in patients with deep infiltrating endometriosis with bowel involvement. *J Minim Invasive Gynecol* 2011; 18: 730–733
- 36 Ruffo G, Sartori A, Crippa S et al. Laparoscopic rectal resection for severe endometriosis of the mid and low rectum: technique and operative results. *Surg Endosc* 2012; 26: 1035–1040
- 37 Maytham GD, Dowson HM, Levy B et al. Laparoscopic excision of rectovaginal endometriosis: report of a prospective study and review of the literature. *Colorectal Dis* 2010; 12: 1105–1112
- 38 Koh CE, Juszczyk K, Cooper MJ et al. Management of deeply infiltrating endometriosis involving the rectum. *Dis Colon Rectum* 2012; 55: 925–931
- 39 Borghese B, Santulli P, Streuli I et al. [Recurrence of pain after surgery for deeply infiltrating endometriosis: How does it happen? How to manage?]. *J Gynecol Obstet Biol Reprod (Paris)* 2012; DOI: 10.1016/j.jgyn.2012.11.009
- 40 Meuleman C, Tomassetti C, Wolthuis A et al. Clinical outcome after radical excision of moderate-severe endometriosis with or without bowel resection and reanastomosis: a prospective cohort study. *Ann Surg* 2013; Apr 10 [Epub ahead of print]; PMID: 23579578
- 41 Dubuisson J, Pont M, Roy P et al. Female sexuality after surgical treatment of symptomatic deep pelvic endometriosis. *Gynecol Obstet Fertil* 2013; 41: 38–44
- 42 Donnez J, Squifflet J. Complications, pregnancy and recurrence in a prospective series of 500 patients operated on by the shaving technique for deep rectovaginal endometriotic nodules. *Hum Reprod* 2010; 25: 1949–1958
- 43 Boesgaard-Kjer DH, Boesgaard-Kjer D, Kjer JJ. Well-leg compartment syndrome after gynecological laparoscopic surgery. *Acta Obstet Gynecol Scand* 2013; 92: 598–600
- 44 Tomassetti C, Meuleman C, Vanacker B et al. Lower limb compartment syndrome as a complication of laparoscopic laser surgery for severe endometriosis. *Fertil Steril* 2009; 92: 2038.e9–2038.e12
- 45 Brouwer R, Woods RJ. Rectal endometriosis: results of radical excision and review of published work. *ANZ J Surg* 2007; 77: 562–571
- 46 Canon B, Collinet P, Piessen G et al. Segmentary rectal resection and rectal shaving by laparoscopy for endometriosis: peri-operative morbidity. *Gynecol Obstet Fertil* 2013; 41: 275–281
- 47 Roman H, Loisel C, Resch B et al. Delayed functional outcomes associated with surgical management of deep rectovaginal endometriosis with rectal involvement: giving patients an informed choice. *Hum Reprod* 2010; 25: 890–899
- 48 Darai E, Touboul C, Chéreau E et al. Segmental resection for colorectal endometriosis: are there alternatives? *Gynecol Obstet Fertil* 2012; 40: 116–120

- 49 Roman H, Vassiliev M, Gourcerol G et al. Surgical management of deep infiltrating endometriosis of the rectum: pleading for a symptom-guided approach. *Hum Reprod* 2011; 26: 274–281
- 50 Zilberman S, Ballester M, Touboul C et al. Partial colpectomy is a risk factor for urologic complications of colorectal resection for endometriosis. *J Minim Invasive Gynecol* 2013; 20: 49–55
- 51 Deffieux X, Raibaut P, Hubeaux K et al. Voiding dysfunction after surgical resection of deeply infiltrating endometriosis: pathophysiology and management. *Gynecol Obstet Fertil* 2007; 35 (Suppl. 1): S8–S13
- 52 Dubernard G, Rouzier R, Piketty M et al. Assessment of the urinary side effects after surgery for deep pelvic endometriosis. *Gynecol Obstet Fertil* 2007; 35 (Suppl. 1): S1–S7
- 53 Ceccaroni M, Clarizia R, Roviglione G et al. Neuro-anatomy of the posterior parametrium and surgical considerations for a nerve-sparing approach in radical pelvic surgery. *Surg Endosc* 2013; DOI: 10.1007/s00464-013-3043-2
- 54 Possover M, Chiantera V, Baekelandt J. Anatomy of the sacral roots and the pelvic splanchnic nerves in women using the LANN technique. *Surg Laparosc Endosc Percutan Tech* 2007; 17: 508–510
- 55 Ceccaroni M, Clarizia R, Bruni F et al. Nerve-sparing laparoscopic eradication of deep endometriosis with segmental rectal and parametrial resection: the Negrar method. A single-center, prospective, clinical trial. *Surg Endosc* 2012; 26: 2029–2045
- 56 Seracchioli R, Mabrouk M, Manuzzi L et al. Importance of retroperitoneal ureteric evaluation in cases of deep infiltrating endometriosis. *J Minim Invasive Gynecol* 2008; 15: 435–439
- 57 Kondo W, Branco AW, Trippia CH et al. Retrocervical deep infiltrating endometriotic lesions larger than thirty millimeters are associated with an increased rate of ureteral involvement. *J Minim Invasive Gynecol* 2013; 20: 100–103
- 58 Mereu L, Gagliardi ML, Clarizia R et al. Laparoscopic management of ureteral endometriosis in case of moderate-severe hydroureteronephrosis. *Fertil Steril* 2010; 93: 46–51
- 59 Miranda-Mendoza I, Kovoov E, Nassif J et al. Laparoscopic surgery for severe ureteric endometriosis. *Eur J Obstet Gynecol Reprod Biol* 2012; 165: 275–279
- 60 Brosens I, Gordts S, Benagiano G. Endometriosis in adolescents is a hidden, progressive and severe disease that deserves attention, not just compassion. *Hum Reprod* 2013; 28: 2026–2031
- 61 Janssen EB, Rijkers AC, Hoppenbrouwers K et al. Prevalence of endometriosis diagnosed by laparoscopy in adolescents with dysmenorrhea or chronic pelvic pain: a systematic review. *Hum Reprod Update* 2013; 19: 570–582
- 62 Yeung jr. P, Sinervo K, Winer W et al. Complete laparoscopic excision of endometriosis in teenagers: is postoperative hormonal suppression necessary? *Fertil Steril* 2011; 95: 1909–1912, 1912.e1
- 63 Tandoi I, Somigliana E, Riparini J et al. High rate of endometriosis recurrence in young women. *J Pediatr Adolesc Gynecol* 2011; 24: 376–379
- 64 Vercellini P, Barbara G, Abbiati A et al. Repetitive surgery for recurrent symptomatic endometriosis: what to do? *Eur J Obstet Gynecol Reprod Biol* 2009; 146: 15–21
- 65 Berlanda N, Vercellini P, Fedele L. The outcomes of repeat surgery for recurrent symptomatic endometriosis. *Curr Opin Obstet Gynecol* 2010; 22: 320–325

Deutschsprachige Zusatzinformationen online abrufbar unter:
www.thieme-connect.de/ejournals/toc/gebfra.