A new tissue acquisition technique in pancreatic cystic neoplasm: endoscopic ultrasound-guided through-the-needle forceps biopsy

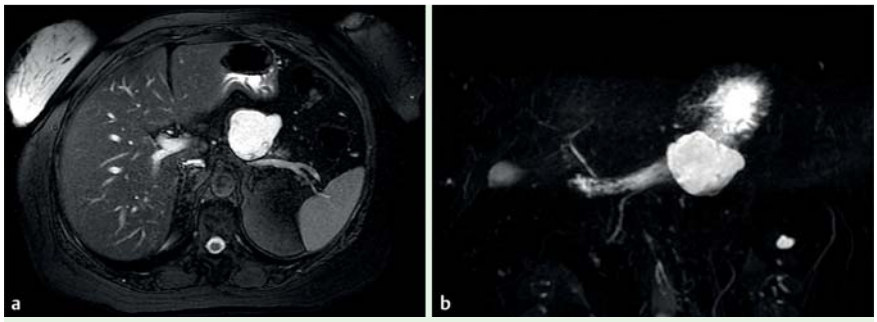

Fig. 1 **a, b** Magnetic resonance images of a 5-cm cystic lesion in the pancreatic body of a 46-year-old woman with type 2 diabetes mellitus. The lesion, which was incidentally diagnosed, contains debris.

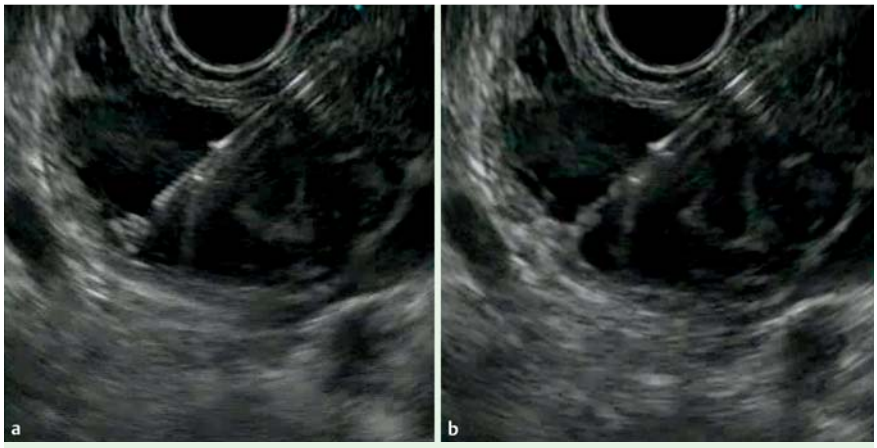

Fig. 3 **a** Endoscopic ultrasound (EUS) image of the pancreatic cystic lesion with granular aspect inside, suspicious for viscous mucin; through-the-needle forceps with open valve. **b** EUS-guided through-the-needle forceps biopsy of the cystic wall: the "tent sign."



Fig. 2 Through-the-needle (19 gauge) biopsy forceps (0.8 mm).

A 46-year-old woman with diabetes mellitus type 2 was admitted for endoscopic ultrasound-guided fine-needle aspiration/biopsy (EUS-FNA/B) because of the incidental diagnosis of a 5-cm pancreatic cystic lesion (PCL) in the pancreatic body, suspicious for pseudocyst (▶ **Fig. 1**). The procedure was performed through the patient's stomach with a standard 19-gauge needle. FNA/B targeting the pancreatic cystic wall was followed by several bites with a through-the-needle forceps (mini biopsy forceps, 0.8 mm in diameter; Endoflex GmbH, Voerde, Germany) (▶ **Fig. 2** and ▶ **Fig. 3**, ▶ **Video 1**).

Because of their small size, we treated these specimens as cytologic samples. They were collected in formalin, entrapped in fibrin coagulum after being centrifuged, and then embedded in paraffin for sectioning. The procedure ended with complete aspiration of the cystic fluid for cytologic, biochemical, and molecular biological testing.

The results of pancreatic cystic wall FNA/B with the 19-gauge needle and cytologic analysis of the cystic fluid were both inadequate, but the through-the-needle forceps biopsy specimens yielded microhistologic samples of mucinous cylindric epithelium with mild dysplasia (▶ **Fig. 4**). In the cystic fluid, the carcinoembryonic antigen level was 7300 ng/mL and the amylase level was 30 U/L. The result of testing for the K-*ras* mutation was negative. Mucinous cystic neoplasm was diagnosed, and the patient was referred for surgery, which confirmed the diagnosis.

The cytohistologic diagnosis of PCLs is challenging. The cytologic testing of cystic fluid has a diagnostic yield of less than 50%, and attempts have been made to improve these results with other techniques. Brush cytology (EchoBrush; Cook Medical, Bloomington, Indiana, USA) [1] and FNA/B targeting the pancreatic cystic walls with a standard needle [2] or ProCore needle (Cook Medical) [3] provide better results. Targeting the cystic wall appears to be the right choice because the cells from the cyst are there. Only two case reports (total of three patients) of EUS-guided through-the-needle forceps biopsy of PCLs have been published [4, 5], with the same results as in our

Video 1

Use of through-the-needle biopsy forceps in pancreatic cystic lesions.

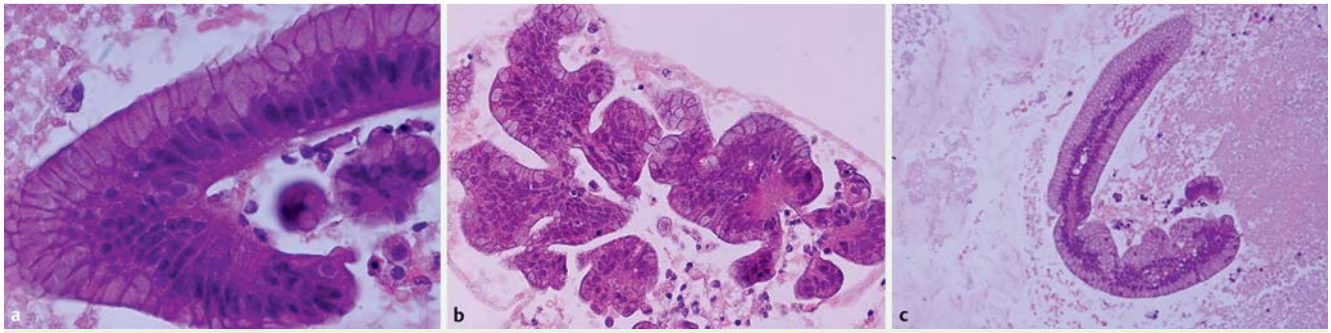

Fig. 4 **a, b** Mucinous epithelium with mild dysplasia. **c** Small papillary projection of the mucinous epithelium.

case. For our patient, this promising new technique was the only one to result in an adequate cytohistologic diagnosis. Clinical studies are needed to validate our results.

Endoscopy_UCTN_Code_TTT_1AS_2AD

Competing interests: None

Luca Barresi, Ilaria Tarantino, Dario Ligresti, Gabriele Curcio, Antonino Granata, Mario Traina

Endoscopy Service, Department of Diagnostic and Therapeutic Services, IRCCS (Istituti di Ricovero e Cura di Carattere Scientifico) – ISMETT (Istituto Mediterraneo per i Trapianti e Terapie ad Alta Specializzazione), Palermo, Italy

References

1 *Sendino O, Fernández-Esparrach G, Solé M* et al. Endoscopic ultrasonography guided brushing increases cellular diagnosis of pancreatic cysts: a prospective study. Dig Liver Dis 2010; 42: 877 – 881
2 *Hong SK, Loren DE, Rogart JN* et al. Targeted cyst wall puncture and aspiration during EUS-FNA increases the diagnostic yield of premalignant and malignant pancreatic cysts. Gastrointest Endosc 2012; 75: 775 – 782
3 *Barresi L, Tarantino I, Traina M* et al. Endoscopic ultrasound-guided fine needle aspiration and biopsy using a 22-gauge needle with side fenestration in pancreatic cystic lesions. Dig Liver Dis 2014; 46: 45 – 50
4 *Aparacio JR, Martínez J, Niveiro M* et al. Direct intracystic biopsy and pancreatic cystoscopy through a 19-gauge needle EUS (with videos). Gastrointest Endosc 2010; 72: 1285 – 1288
5 *Samarasena JB, Nakai Y, Shinoura S* et al. EUS-guided through-the-needle forceps biopsy: a novel tissue acquisition technique. Gastrointest Endosc 2015; 81: 225 – 226

Bibliography
DOI http://dx.doi.org/10.1055/s-0034-1392031
Endoscopy 2015; 47: E297–E298

ISSN 0013-726X

Corresponding author
Luca Barresi, MD
Endoscopy Service
ISMETT
Via Tricomi 5
90127 Palermo
Italy
Fax: +39-091-2192400
lbarresi@ismett.edu