

# Applying Fibrin Glue under Pleurography for Intractable Secondary Spontaneous Pneumothorax

Jeong Su Cho<sup>1</sup> Hyo Yeong Ahn<sup>1</sup> Yeong Dae Kim<sup>1</sup> Hoseok I.<sup>1</sup> Jung Seop Eom<sup>2</sup>

<sup>1</sup>Department of Thoracic and Cardiovascular Surgery, Pusan National University Hospital, Busan, Republic of Korea

<sup>2</sup>Department of Internal Medicine, Pusan National University Hospital, Busan, Republic of Korea

Address for correspondence Hyo Yeong Ahn, MD, Department of Thoracic and Cardiovascular Surgery, Pusan National University Hospital, 305, Gudeok-Ro, Seo-Gu, Busan, 602-739, Republic of Korea (e-mail: doctorahn02@hanmail.net).

Thorac Cardiovasc Surg 2021;69:466–469.

## Abstract

**Background** Prolonged air leakage is a problem that can frequently develop in patients with a secondary spontaneous pneumothorax (SSP) or in those who undergo thoracic surgery. However, the management of an air leak is difficult and reoperation might be avoided due to several reasons including adhesions. Herein, we introduce a fibrin glue application under pleurography (FGAP) and short-term outcomes in patients who underwent this procedure.

**Methods** FGAP was performed in 20 patients with an intractable persistent air leakage who had poor lung function, comorbidities to undergo general anesthesia and were expected severe adhesions due to previous surgery. All medical records were retrospectively reviewed.

**Results** Eighteen cases sealed soon after dropping the glue. One patient had a prolonged air leak for 12 days and another patient required an operation to control air leakage 16 days after the procedure. The mean duration of postoperative drainage was  $4.17 \pm 2.11$  days (range: 3–14 days). No postprocedural complications were recorded. The mean duration of follow-up was  $12.01 \pm 5.02$  months (range: 4–22 months).

**Conclusion** FGAP could be a treatment option to seal air leaks, especially in cases with intractable air leakage.

## Keywords

- ▶ fibrin glue
- ▶ pleurography
- ▶ pneumothorax

## Introduction

Although a primary spontaneous pneumothorax can be easily treated by excision of blebs, a secondary spontaneous pneumothorax (SSP) is much more difficult to treat.<sup>1,2</sup> Despite the development of techniques, excision of bullae in a patient with an SSP and an adhesiotomy could result in a prolonged air leakage or a recurrence of pneumothorax and postoperative pneumonia. Therefore, there is a need for an innovative technique without surgical invasiveness in patients with an SSP. Herein, we introduce the procedure “fibrin glue application under pleurography” (FGAP) and analyze the short-term outcomes of patients who underwent this procedure.

## Patients and Methods

Twenty patients were underwent the glue application procedure under pleurography for an intractable persistent air leak

in our hospital from November 2016 to March 2018. Of them, 14 patients suffered from a SSP; two for a cancer-related pneumothorax, and the others for emphysema. The other six patients had prolonged air leaks after previous operations; one patient underwent a wedge resection of the right lower lobe and previously had a right upper lobectomy due to lung cancer 3 years ago; two patients had wedge resections of the right lower lobe to exclude a malignancy; one patient was scheduled to undergo esophagectomy but failed the operation because of severe adhesions that developed from tuberculous pleurisy. Two patients had already undergone bullae ligation under epidural anesthesia (▶ **Table 1**).

The FGAP was considered in patients with intractable persistent air leakage even after bed-side dextrose pleurodesis who had at least one of the following: poor pulmonary function test results, comorbidities to undergo general anesthesia, such as heart disease, interstitial lung disease,

received

August 30, 2018

accepted after revision

November 28, 2018

published online

February 6, 2019

© 2019, Thieme. All rights reserved.  
Georg Thieme Verlag KG,  
Rüdigerstraße 14,  
70469 Stuttgart, Germany

DOI <https://doi.org/10.1055/s-0038-1676986>.  
ISSN 0171-6425.

**Table 1** The etiology of persistent pneumothorax

Causes of air leakage	Underlying disease	n	
Secondary spontaneous pneumothorax		14	
	Lung cancer	2	
	Bullous emphysema	12	
Postoperative air leakage		6	
	Wedge resection	Lung cancer	3
	Exploratory thoracotomy	Esophageal cancer with tuberculous pleurisy	1
	Bullae ligation under epidural anesthesia	Secondary spontaneous pneumothorax	2

or systemic disease, and expected severe adhesions due to previous surgery.<sup>1</sup>

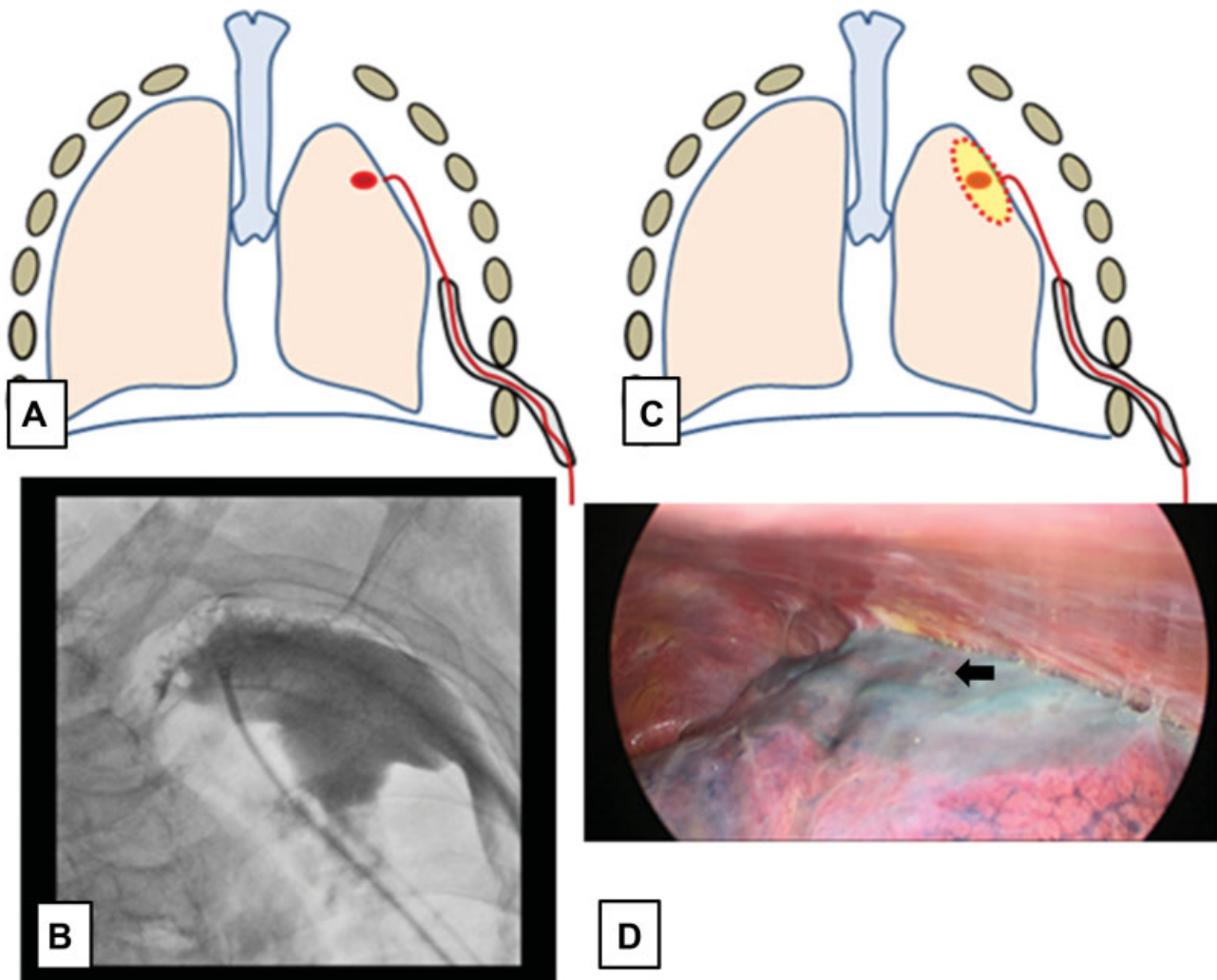
All medical records were retrospectively reviewed for frequency of bed-side pleurodesis, pre- and postprocedural

chest tube drainage, postprocedural complications, postprocedural hospital stay, and hospital death.

This study was approved by the Institutional Review Board of Pusan National University, Busan, Republic of Korea. Informed consent was not required for this retrospective study. Data were analyzed with IBM Statistical Package for Social Sciences software (version 16.0; SPSS Inc., Chicago, Illinois, United States).

#### FGAP Technique

A Flexor Check-Flo Introducer (Cook Medical Inc., Bloomington, Indiana, United States) was inserted through a chest tube, and contrast media, Xenetix 300 (Roissy, France), was injected through the introducer. To precisely identify the air leak point, the patient was requested to breathe in and out deeply. After the air-leak point was identified by pleurography with contrast medium which was shown as bubbling from the air leak focus depending on respiration, a double lumen catheter was inserted through the introducer and guided to the air-leak point by twisting the introducer and advancing the double lumen catheter through the introducer to the leak point. Fibrin sealant Tisseel



**Fig. 1** (A) Schematic illustrations showing the air leak point identified using contrast medium according to image (B); (C) schematic illustrations showing applied the fibrin glue in the air leak point, which was found out to be well covered around the small fistula, but still having air leak from here making us to re-explore (D, arrow).

(Baxter Healthcare Corp., Deerfield, Illinois, United States) 4 cc consisting with fibrin (2 cc) and thrombin (2 cc), each diluted with contrast media, were alternately dropped slowly at the air-leak point (► Fig. 1). Then, a 24 F chest tube was reinserted. The chest tube bottles were not under negative suction.

### Postoperative Care

No suction was allowed for 1 to 2 days to prevent the glue from failing. The chest tube was removed when an X-ray showed full expansion and the air leak had stopped for 2 days. The chest tube was clamped for 1 day to detect any minor air leakage. A natural drain was inserted for 2 to 3 days when persistent air leakage continued after the procedure; however, in cases with space, the chest bottles were placed under 20 cm H<sub>2</sub>O of negative suction. Bedside pleurodesis using 50% dextrose was applied or pleurography was tried again if there was full expansion with continuous air leakage (► Fig. 2).

### Results

Most of patients had bed-side pleurodesis at least twice before FGAP. Mean procedure time was 20.5 ± 5.4 minutes (median: 17.5 minutes, range: 13–29 minutes), and the mean duration of preprocedure drainage was 21.44 ± 3.71 days (range: 16–31 days). The mean duration of postprocedure drainage was 4.17 ± 2.11 days (range: 3–14 days). Nineteen patients had one chest tube and one patient had two chest tubes because of a previous operation. The mean hospital stay was 30.56 ± 7.02 days (range: 21–45 days) and the mean postprocedural hospital stay was 7.93 ± 2.43 days (range: 4–20 days; ► Table 2).

Air leakage stopped just after the procedure in most cases ( $n = 18$ ); however, the patient who had previous operation for lung cancer had the decreased air leakage just after FGAP and stopped after 12 days, and another patient suffered from

**Table 2** Results in patients who underwent the glue application under pleurography

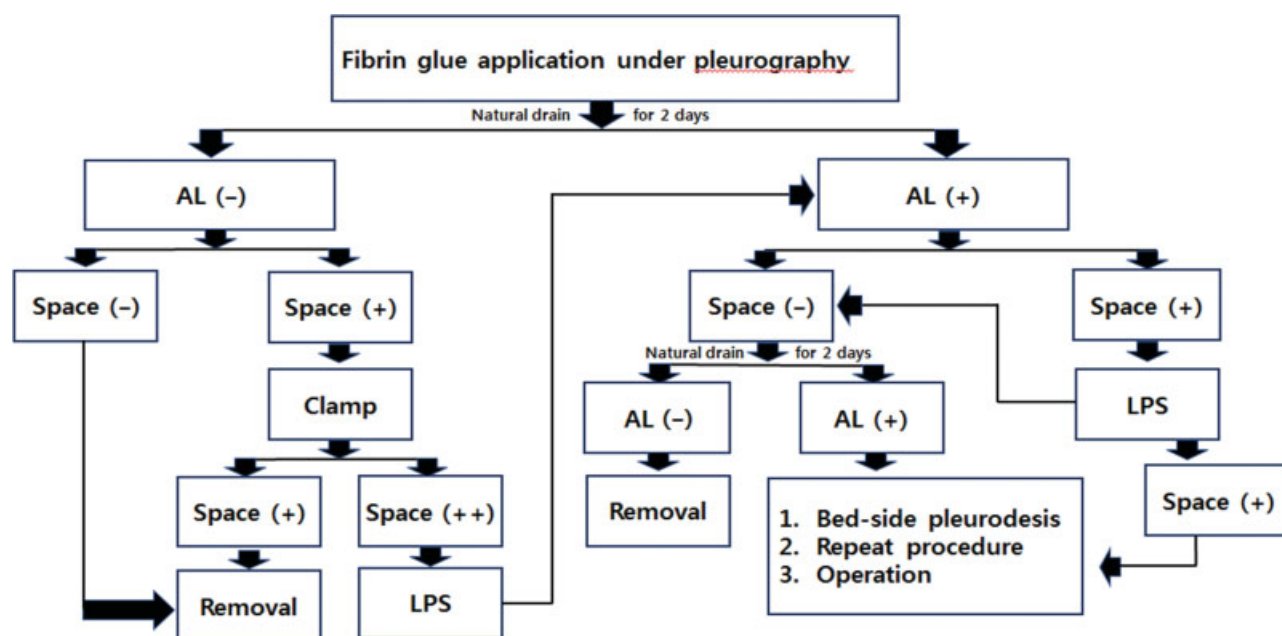
Characteristics	Mean
Frequency of dextrose pleurodesis before procedure ( $n$ )	2.5 ± 0.5
Operative time (min)	20.5 ± 5.4
Preprocedural drainage (d)	21.44 ± 3.71
Postprocedural drainage (d)	4.17 ± 2.11
Total hospital stay (d)	30.56 ± 7.02
Postprocedural hospital stay (d)	7.93 ± 2.43
Postoperative pain score for the first postprocedure	1.7 ± 0.17

pneumothorax caused by bullous emphysema needed an operation to control the air leakage 16 days after the initial procedure (► Fig. 1).

No postprocedural complications were detected, such as empyema, acute respiratory distress syndrome, or pneumonia. The mean duration of follow-up was 12.01 ± 5.02 months (range: 4–22 months).

### Discussion

An intractable persistent air leak can lead to death due to respiratory insufficiency or combined severe infection, particularly in a patient with an SSP and concomitant lung diseases; thus proper management to control an air leak is necessary and unavoidable. However, it is difficult to decide whether to perform a surgical intervention in high risk patients or patient expecting a prolonged postoperative air leakage.<sup>2–5</sup> Although awake surgery has been performed worldwide, it is difficult to



**Fig. 2** Algorithm for management after applying fibrin glue under pleurography in cases of a secondary spontaneous pneumothorax. AL, air leakage; LPS, low power suction.

find the air leak focus in cases with severe adhesions and it is hard for patients to endure the operation.

Some studies have recommended chemical pleurodesis using antibiotics or chemo agents for a prolonged air leak, as it generally induces symphysis between the parietal pleura and visceral pleura to stop the air leak. However, side effects can develop, such as acute respiratory distress syndrome or severe chest pain.<sup>6–9</sup> Then we usually prefer bed-side pleurodesis using 50% dextrose 50 cc several times.

However, considering an air leak that developed from one minimal focus and a pneumothorax as a visceral disease, development of symphysis between the whole pleura might be an unnecessary procedure and rather cause pleuritic chest pain.<sup>6</sup> FGAP is an option to detect the air leak point and apply a sticking agent, such as fibrin glue, to heal the tear point without additional anesthesia or pain control.

We usually wait to see if a persistent postoperative air leak spontaneously resolves in 10 to 14 days after applying suction with bedside dextrose pleurodesis to avoid a second operation. Considering re-exploring the pleural cavity, many surgeons are reluctant to re-operate due to the high risk of secondary lung injury. FGAP could be convenient in these cases because of no additional dissection of the adhesions.

Although the operation was unavoidable in one case in our series, the air leaks were successfully sealed with fibrin glue in the other cases (19/20, 95%), and there were no complications. Therefore, FGAP should be considered to treat patients with an intractable persistent air leak to prevent a high-risk surgery under general anesthesia or a prolonged postoperative air leak.

Nevertheless, an advanced technique to confirm the air leak focus, place the catheter to deliver the fibrin glue and also to get successful results, FGAP needs to be considered in limited cases, such as expecting fully lung expansion under low power suction, which means there might be no adhesion to prevent lung expansion.

#### Authors' Contributions

Dr. H.Y.A. contributed in study designing, data collection, analysis and interpretation of the data, writing manuscript, and critical revision of the manuscript for important intellectual content.

Drs. J.S.C. and Y.D.K. contributed to critical revision of the manuscript for important intellectual content.

#### Conflicts of Interest

The authors declare no conflicts of interest.

#### Editor's Note

On January 14, 2019 the Editorial Office received a request by the corresponding author to change the author list, subsequently agreed to by all authors concerned.

Readers should be aware that the original author list and sequence at the time of final acceptance of the manuscript was as follows:

Hyo Yeong Ahn, Jeong Su Cho, Yeong Dae Kim, Hoseok I.

Markus K. Heinemann, MD, PhD  
Editor-in-Chief

#### References

- Ahn HY, Kim YD, Cho JS, i H, Lee J, Kwon JY. Thoracoscopic surgery under epidural anesthesia for intractable secondary spontaneous pneumothorax. *Asian J Surg* 2017;40(04):285–289
- Mukaida T, Andou A, Date H, Aoe M, Shimizu N. Thoracoscopic operation for secondary pneumothorax under local and epidural anesthesia in high-risk patients. *Ann Thorac Surg* 1998;65(04):924–926
- Kiss G, Claret A, Desbordes J, Porte H. Thoracic epidural anaesthesia for awake thoracic surgery in severely dyspnoeic patients excluded from general anaesthesia. *Interact Cardiovasc Thorac Surg* 2014;19(05):816–823
- Noda M, Oishi H, Maeda S, et al. [Management of surgical approach for intractable secondary spontaneous pneumothorax]. *Kyobu Geka* 2011;64(04):291–295
- Zhang Y, Jiang G, Chen C, Ding J, Zhu Y, Xu Z. Surgical management of secondary spontaneous pneumothorax in elderly patients with chronic obstructive pulmonary disease: retrospective study of 107 cases. *Thorac Cardiovasc Surg* 2009;57(06):347–352
- Ng CK, Ko FW, Chan JW, et al. Minocycline and talc slurry pleurodesis for patients with secondary spontaneous pneumothorax. *Int J Tuberc Lung Dis* 2010;14(10):1342–1346
- Pletinckx P, Muysoms F, De Decker C, Daeter E, Claeys D. Thoracoscopic talc pleurodesis for the treatment of spontaneous pneumothorax. *Acta Chir Belg* 2005;105(05):504–507
- Stumpf C, Büssing A. Stimulation of antitumour immunity by intrapleural instillation of a *Viscum album L.* extract. *Anticancer Drugs* 1997;8(Suppl 1):S23–S26
- Tschopp JM, Brutsche M, Frey JG. Treatment of complicated spontaneous pneumothorax by simple talc pleurodesis under thoracoscopy and local anaesthesia. *Thorax* 1997;52(04):329–332