

Pancreatic Incidentalomas: Review and Current Management Recommendations

Binit Sureka¹ Vaibhav Varshney²

¹Department of Diagnostic and Interventional Radiology, All India Institute of Medical Sciences, Jodhpur, Rajasthan, India

²Department of Surgical Gastroenterology, All India Institute of Medical Sciences, Jodhpur, Rajasthan, India

Address for correspondences Binit Sureka, MD, DNB, MBA, Department of Diagnostic and Interventional Radiology, All India Institute of Medical Sciences, Basni Industrial Area, MIA 2nd Phase, Basni, Jodhpur 342005, Rajasthan, India (e-mail: binitasurekapgi@gmail.com).

Ann Natl Acad Med Sci (India) 2019;55:6–13

Abstract

Keywords

- ▶ duct
- ▶ incidentaloma
- ▶ pancreas
- ▶ pancreatic cyst

There has been significant increase in the detection of incidental pancreatic lesions due to widespread use of cross-sectional imaging like computed tomography and magnetic resonance imaging supplemented with improvements in imaging resolution. Hence, accurate diagnosis (benign, borderline, or malignant lesion) and adequate follow-up is advised for these incidentally detected pancreatic lesions. In this article, we would review the various pancreatic parenchymal (cystic or solid) and ductal lesions (congenital or pathological), discuss the algorithmic approach in management of incidental pancreatic lesions, and highlight the key imaging features for accurate diagnosis.

Introduction

The term “pancreatic incidentaloma” (PI) refers to those lesions in the pancreas that are diagnosed incidentally when obtaining an imaging study of the abdomen not intended to look for a pancreatic pathological process.¹ This phenomenon is not new to the pancreas and has been quite often observed in other organs such as adrenal glands, thyroid, parathyroid, pituitary, liver, prostate, and kidneys. The first case of PI was described by Kostiuk in 2001.² Incidental pancreatic cysts are frequently encountered now due to advancements and easy availability of imaging. The reported incidence of incidental cystic pancreatic lesions varies, depending on the imaging technique used. In computed tomography (CT), the prevalence varies from 0.5 to 3%, whereas in magnetic resonance imaging (MRI), this prevalence increases to 18 to 19.6%.^{3,4} In a postmortem study by Kimura et al, cysts less than 1 cm in size were detected in 24% of cases.⁵ Recent published studies have shown that the incidence of incidental PI is rising.⁶

When a PI is encountered, the first aim is to classify whether it is a pancreatic parenchymal or ductal lesion. PIs in the pancreatic parenchyma can be either cystic or solid. Incidental lesions in the main pancreatic duct (MPD) can be congenital variations or a pathological process involving the

MPD. The second aim is to further classify the lesion into benign or malignant. Various cystic and solid incidentalomas in the pancreatic parenchyma are listed in ▶ **Table 1**.⁷

Incidental Cystic Pancreatic Tumors

Most incidental cystic pancreatic lesions are benign.^{8,9} The first step is to differentiate these cystic lesions from pancreatic pseudocysts. Serous cystadenoma, mucinous cystic lesions, and intraductal papillary mucinous neoplasms (IPMNs) account for more than 90% of primary cystic pancreatic tumors.¹⁰ Most of the patients are asymptomatic at the time of presentation. Symptomatic patients may present with abdominal pain, jaundice, weight loss, and/or recurrent episodes of pancreatitis. Morphological classification of cystic lesions of the pancreas is given in ▶ **Table 2**.¹¹

Unilocular Cysts

Pancreatic pseudocysts are the most commonly encountered unilocular cysts. Others include mucinous and serous cystadenoma, lymphoepithelial cysts, retention cyst, developmental cyst, epidermoid cyst in intrapancreatic spleen, endometrial cyst, and cystic neuroendocrine tumor or an infectious cyst (▶ **Figs. 1 and 2**). A unilocular lesion in

Table 1 Pancreatic incidentalomas⁷

Exocrine	Infections
Benign SCN MCN IPMN Mature cystic teratoma	<i>Mycobacterium avium</i> complex <i>Mycobacterium tuberculosis</i> Rare and atypical fungal and viral infections
Borderline Mucinous cystic tumor with moderate dysplasia Intraductal papillary mucinous tumor with moderate dysplasia SPN	Mesenchymal tumors Kaposi's sarcoma Lipoma Lymphangioma Pancreatic Castleman's disease Pancreatic hamartoma Schwannoma Teratoma
Malignant Ductal adenocarcinoma Osteoclastlike giant cell tumor Serous cystadenocarcinoma Mucinous cystadenocarcinoma IPMN Acinar cell carcinoma Pancreatoblastoma Solid pseudopapillary carcinoma Ampullary adenocarcinoma	Metastases Colon, breast, lung, lymphoma, melanoma, renal cell carcinoma
Endocrine	Nonislet cell tumors
Gastrinoma Glucagonoma GRF-secreting tumor Insulinoma PP-secreting tumor Somatostatinoma VIPoma Serotoninoma	Adenosquamous carcinoma Anaplastic tumors Colloid carcinoma Granulocytic sarcoma Leukemia Lymphoma Primitive neuroectodermal tumor
Cystic lesions	Inflammatory
Benign pancreatic cysts Dysontogenic cysts Hydatid cyst Cysticercosis LECs Pancreatic dermoid cysts Retention pancreatic cysts	Eosinophilic pancreatitis Focal pancreatitis Inflammatory myofibroblastic tumor Lymphoid hyperplasia Wegener's disease Xanthogranulomatous pancreatitis
Congenital	
Congenital cyst Epidermoid cyst in IPAS	

Abbreviations: GRF, growth hormone releasing factor; IPAS, intrapancreatic accessory spleen; IPMN, intraductal papillary mucinous adenoma; LEC, lymphoepithelial cyst; MCN, mucinous cystadenoma; PP, pancreatic polypeptide; SCN, serous cystadenoma; SPN, solid pseudopapillary tumor; VIPoma, pancreatic neuroendocrine tumor that secretes vasoactive intestinal peptide.

a patient with a clinical history of pancreatitis is almost always a pseudocyst. A lobulated unilocular cyst located in the head of the pancreas should raise the suspicion of a serous cystadenoma.

Table 2 Classification according to imaging morphology¹¹

Unilocular	Microcystic
Pseudocyst Cystic neuroendocrine tumor Unilocular serous cystadenoma Unilocular mucinous cystadenoma Retention cyst Developmental cyst Epithelial cyst Lymphoepithelial cyst Epidermoid cyst in intrapancreatic accessory spleen Endometrial cyst Infectious cyst	Serous cystadenoma Microcystic variant of ductal adenocarcinoma (very rare)
Macrocystic	Cystic transformation of the pancreas
Mucinous cystadenoma BD-IPMN Oligocystic serous cystadenoma Lymphangioma Lymphoepithelial cyst Infectious cyst Duplication cyst Mesothelial cyst	Dysontogenic cyst Cystic fibrosis Disseminated serous cystadenoma Congenital syndromes such as von Hippel-Lindau's disease, polycystic kidney disease, Ivemark's syndrome, trisomy 13 or 15, Meckel-Gruber's syndrome
Cyst with ductal communication	Multifocal
IPMN Collections postpancreatitis as a part of disconnected duct syndrome Retention cyst/squamoid cyst	BD-IPMN Pseudocysts Serous cystadenoma Neuroendocrine tumor Developmental cyst Epithelial cyst
Solid cystic	
SPN Pancreatoblastoma Cystic metastasis Cystic degeneration in solid tumors Malignant transformation in cystic tumors Metastases Hemorrhagic pseudocyst	

Abbreviations: BD-IPMN, branch-duct intraductal papillary mucinous neoplasm; IPMN, intraductal papillary mucinous neoplasm; SPN, solid pseudopapillary tumor.

Microcystic Lesions

The most important differential diagnosis of a microcystic lesion in the pancreas is serous cystadenoma. It usually demonstrates a polycystic or microcystic pattern consisting of cysts up to 2 cm in size. They are usually lobulated. The septa and wall may show enhancement (►Fig. 3). A stellate pattern of calcification is visible in 30% of the patients and is considered a characteristic of a serous cystadenoma.¹² A rare

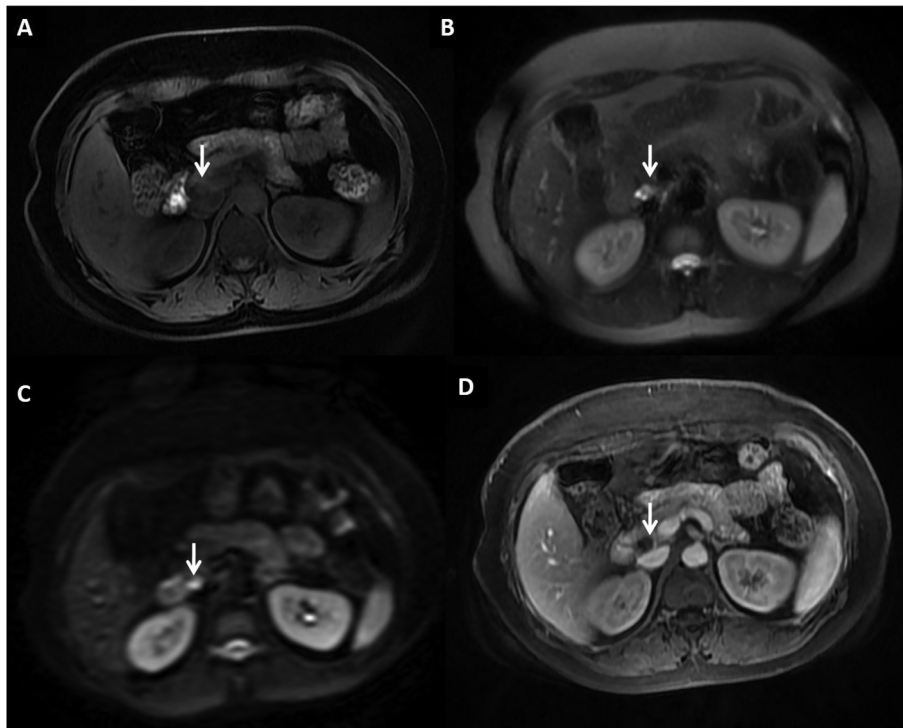


Fig. 1 A 43-year-old-female with incidentally detected lymphoepithelial cyst postcholecystectomy in the pancreas. (A) Axial T1-weighted magnetic resonance imaging showing unilocular cystic lesion, which is mildly hyperintense in the head of the pancreas (B) and hyperintense on T2-weighted images (C), showing bright signal on diffusion-weighted imaging (D) with no enhancement on T1-weighted postcontrast gradient echo images.

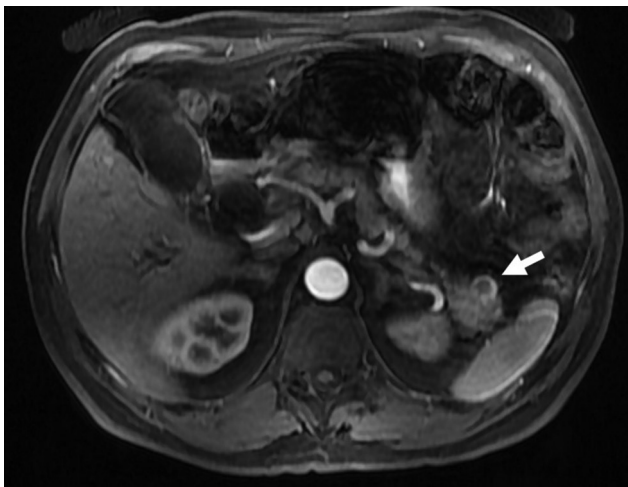


Fig. 2 A 60-year-old male with incidental cystic pancreatic neuroendocrine tumor. Axial postcontrast T1-weighted image showing incidental unilocular cystic lesion (arrow) in the tail of the pancreas, showing peripheral arterial enhancement suggestive of cystic neuroendocrine tumor.

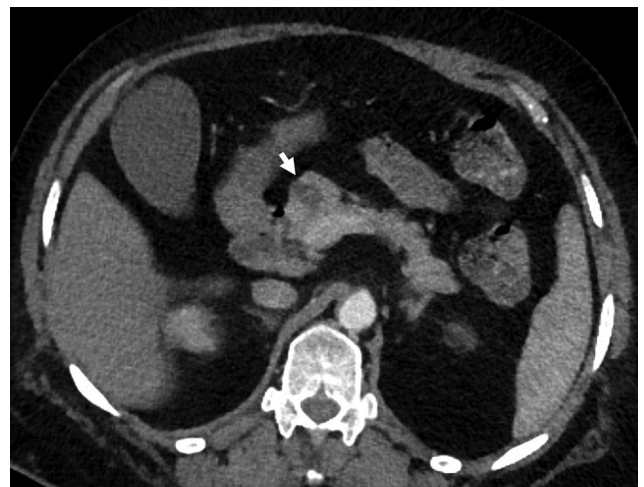

Fig. 3 A 68-year-old-female with incidental serous cystadenoma. Axial contrast-enhanced computed tomography image showing polycystic lesion in the head of the pancreas (arrow) with thin internal septations in a case of serous cystadenoma.

differential diagnosis of a microcystic lesion in the pancreas is a microcystic variant of ductal adenocarcinoma.¹³

Macrocytic Lesions

Mucinous cystic neoplasms (cystadenomas) and branch-duct (BD) IPMNs usually present as macrocystic lesions. Mucinous cystadenomas mainly involve the body and tail of the pancreas and do not communicate with the MPD. It is important to differentiate serous from mucinous cystic neoplasm as surgery is the treatment of choice in mucinous

cystic neoplasm.¹⁴ A peripheral eggshell calcification is highly suggestive of a potentially malignant mucinous cystic neoplasm.¹⁵ Other differential diagnoses of macrocystic lesions in the pancreas are lymphangiomas, lymphoepithelial cysts, infectious cysts, mesothelial cysts, and duplication cysts.

Cyst with Solid Component (Solid Cystic)

Tumors with this morphology are solid pseudopapillary neoplasms, pancreatoblastomas, cystic metastases, cystic degeneration in solid tumors, malignant transformation in cystic tumors, and hemorrhagic pseudocysts. Cysts with

a solid component can be unilocular or multilocular and may or may not have ductal communication. Therefore, true cystic tumors with solid component as well as solid pancreatic neoplasms with a cystic component or cystic degeneration are included in this category. Most tumors in this category are malignant and should be surgically treated. MR cholangiopancreatography (MRCP) is superior to single-section helical CT to characterize these tumors.^{16,17}

Cystic Transformation of the Pancreas

Cystic transformation of the pancreas is seen in dysontogenetic cyst, cystic fibrosis, disseminated variant of serous cystadenoma, congenital syndromes such as von Hippel-Lindau's disease (VHL), autosomal dominant polycystic kidney disease (ADPKD), Ivemark's syndrome, trisomy 13 or 15, Meckel-Gruber's syndrome, and so on.^{18,19} Polycystic disease of the pancreas is also known as dysontogenetic cysts or congenital cysts of the pancreas. It is a very rare entity that may occur as a solitary cyst, polycystic disease in association with renal cysts, and liver, central nervous system, or retinal abnormalities. Pancreatic involvement in VHL is in the form of simple cysts (71%), serous cystadenomas (15%), pancreatic neuroendocrine tumors (pNETs; 10%) and rarely cystic replacement of the entire pancreas.^{20,21} Kim et al²² have shown that pancreatic cysts are five times more prevalent in patients with ADPKD with PKD2 mutation than in patients with PKD1 mutation. PKD1 has a more aggressive disease course, with an earlier age of symptom onset, end-stage renal disease, and death. Thus, the potential to discriminate PKD1 from PKD2 on MRI has important prognostic implications. MRI identification of pancreatic cysts in ADPKD significantly increases the likelihood that a PKD2 mutation is present.^{23,24}

Cyst with Ductal Communication

Tumors included in this subgroup are IPMNs, collections postpancreatitis as a part of disconnected duct syndrome, and retention cysts. IPMNs are more common in elderly males in the sixth to seventh decade of life. Three types of IPMNs may be observed: main duct, BD, and mixed variant.²⁵ Retention cysts are cystic dilatation of the pancreatic duct. It may or may not be associated with an obstructive cause such as calculi, stricture, mucin plugs, and tumors.²⁶

Multifocal Cystic Lesions

BD-IPMN, pseudocysts, serous cystadenomas, neuroendocrine tumors, developmental cysts, and epithelial cysts can be multifocal and should be considered in the differential diagnoses of multifocal cystic lesions of the pancreas.¹¹

Incidental Solid Pancreatic Tumors

The incidence of benign disease in solid pancreatic tumors suspicious of cancer ranges from 6 to 21%. Chronic pancreatitis presenting as inflammatory pancreatic mass accounts for almost 70% of the benign lesions,²⁷ with alcoholic pancreatitis being the most common cause (60%) with autoimmune pancreatitis (AIP) in up to 11% of the patients.^{28,29}

Pancreatic Adenocarcinoma

The most frequent solid lesion in the pancreas is pancreatic ductal adenocarcinoma (PDAC). Symptomatic patients present with advanced disease at the time of diagnosis (extensive local disease in ~40% and metastases in 40–55%), leaving less than 20% of patients as candidates for potentially curative resection.^{30,31} The earliest imaging finding of a PDAC before a mass becomes apparent is pancreatic ductal dilatation or pancreatic duct cutoff. On imaging, pancreatic carcinomas (PCs) are hypovascular, hypoenhancing lesions when compared with the surrounding pancreatic parenchyma. On MRI, most PDACs are hypointense on unenhanced T1-weighted sequences when compared with the surrounding pancreas and are hypointense or isointense on T2-weighted images.^{32,33} The sensitivity and specificity of fluoro-2-deoxy-d-glucose-positron emission tomography (FDG-PET) for the diagnosis of PC in patients with normal blood glucose levels range from 85 to 100% and 67 to 99%, respectively. Combination of PET and CT may offer a better accuracy.³⁴ Serum tumor markers can be helpful in differentiating benign from malignant pancreatic masses. The addition of other tumor markers such as Ca-125 does not increase the diagnostic accuracy of CA19-9 and is the gold standard marker for PDAC with sensitivity and specificity as high as 87 and 98%, respectively.³⁵

Pancreatic Neuroendocrine Tumors

Over the last decade, the wide use of imaging technology has led to the rising incidence of pNETs. pNETs are rare and account for 2 to 4% of all pancreatic neoplasms, with an incidence of 1.5 in 100,000.^{36,37} In recent years, the detection of incidentally nonfunctioning pNETs (NF-pNETs) has rapidly increased due to the widespread use of endoscopic and cross-sectional imaging. Nearly 60% secrete one or more biologically active peptides, resulting in clinical syndromes. The most frequent functioning tumors are insulinomas, gastrinomas, glucagonomas, VIPomas (a pancreatic neuroendocrine tumor that secretes vasoactive intestinal peptide), and somatostatinomas. Between 30 and 40% of pNETs are

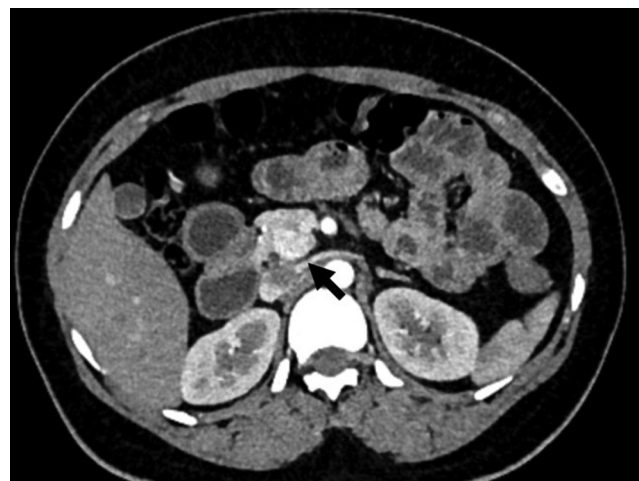

Fig. 4 A 27-year-old female with incidental pancreatic neuroendocrine tumor. Axial contrast-enhanced computed tomography image showing incidental well-defined hypervascular lesion (arrow) in head uncinate of the pancreas.

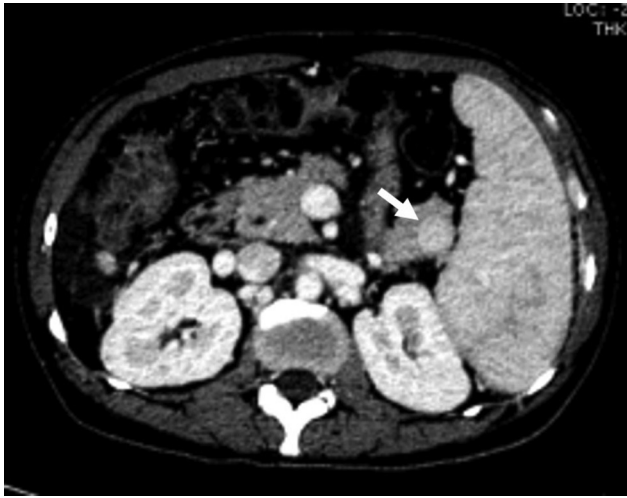

Fig. 5 A 45-year-old-male with intrapancreatic spleen. Axial contrast-enhanced computed tomography image showing solid enhancing lesion (arrow) in the tail of the pancreas with enhancement similar to splenic parenchyma suggestive of intrapancreatic spleen.

nonfunctioning, and this is more likely to be discovered incidentally when symptoms due to the presence of the mass are not yet obvious.³⁸

On CT scan, most pNETs are isodense or moderately hypodense masses showing good arterial enhancement (► **Fig. 4**). Calcification, necrosis, and cystic degeneration seem to be more common in large nonfunctioning tumors or with malignant transformation. MRI has a diagnostic sensitivity of 78 to 91%, which is equivalent to that of dynamic CT.^{39,40} On MRI, pNETs show low signal intensity on T1-weighted images and high signal intensity on T2-weighted images.^{41,42} The most important imaging differential diagnosis is intrapancreatic spleen, which shows enhancement characteristics similar to those of splenic parenchyma (► **Fig. 5**).

Inflammatory Pancreatic Mass

The combination of acute pancreatitis and cancer is unusual. Pancreatic cancer represents 1 to 2% of acute pancreatitis etiologies, and only 3% of cancers manifest as acute pancreatitis.⁴³ The risk of developing pancreatic cancer in patients with chronic pancreatitis is around 15 times higher than in the average population.⁴⁴ Dilatation of the pancreatic duct, and double-duct sign with both biliary and pancreatic obstruction or interruption of the pancreatic duct are unusual and should lead to considering an underlying carcinoma. Sheathing of the celiac trunk and/or mesenteric artery is seen in 30 to 60% of CT scans of adenocarcinoma.⁴⁵ But this can also be seen in AIP or IgG4 (immunoglobulin G4 related) conditions with extrapancreatic lesions in sclerosing mesenteritis and retroperitoneal fibrosis.⁴⁶

Adenocarcinoma developing in the background of chronic pancreatitis is difficult to detect on imaging. In the context of chronic pancreatitis, calcifications displaced by the mass is a pointer suggesting a coexisting PC.^{47,48} Nearly 10% of presumed PCs that are surgically operated have been composed of pseudotumoral forms of pancreatitis, nearly half of which are thought to be focal forms of AIP, involving mainly the head.^{49,50} Certain imaging criteria are helpful in

diagnosing AIP, such as both early and delayed homogeneous enhancement of the lesion close to that of normal parenchyma, peripheral pseudocapsule, a duct visible in the mass with an hourglass stenosis, absence of upstream atrophy or marked dilatation of the pancreatic duct (<4 mm), multifocal involvement, absence of vascular involvement, and presence of extrapancreatic manifestations.⁵¹

Incidental Congenital Main Pancreatic Duct Anomalies

Congenital anomalies and normal variants of the pancreas and pancreatic duct may not be detected until adulthood and are often discovered as an incidental finding in asymptomatic patients. These anomalies are considered and detected only when patients present with idiopathic pancreatitis. MRCP is the modality of choice nowadays for the assessment of congenital pancreatic anomalies since it depicts ductal anatomy rapidly and noninvasively. Anatomic variations and developmental anomalies of the pancreas and pancreatic duct include variations of the course of the pancreatic duct (descending, sigmoid, vertical, and loop-shaped course), variation of the configuration of the pancreatic duct (bifid configuration with dominant duct of Wirsung [60%], dominant duct of Santorini without divisum [1%], absent duct of Santorini, and ansa pancreatica), duplication anomalies, anomalous pancreaticobiliary ductal junction, pancreas divisum (4–14%), annular pancreas, ectopic pancreas, and pancreatic agenesis and hypoplasia of the dorsal pancreas and accessory pancreatic lobe.^{52,53}

Incidental Pathological Processes Involving the MPD

Genetic mutation associated pancreatitis (GMAP) also sometimes referred to as idiopathic painless chronic pancreatitis can present as an incidental ductal disease process while imaging for symptoms not related to the pancreas. Several gene mutations associated with chronic pancreatitis have been identified, with the most frequent involving the *CFTR* (cystic fibrosis transmembrane regulator) gene, the *SPINK1* (serine protease inhibitor, Kazal type 1) gene, and the *PRSS1* (cationic trypsinogen) gene. According to some authors, the patients with pancreatitis associated with one of these gene mutations show onset at a younger age than those with pancreatitis related to other factors, even though the diagnosis is often late compared with the appearance of symptoms. Accurate diagnosis of GMAP is important for a careful follow-up of these patients, as the risk of developing pancreatic adenocarcinoma is higher in this group than in the normal population or in patients affected by chronic pancreatitis not associated with gene mutations. On imaging, typical bull's eye pattern of stones, with a dense peripheral rim and a noncalcified radiolucent central core with stones greater than 15 mm in size, is seen.^{54,55}

pNETs expressing serotonin (carcinoid tumors) account for a small portion of neuroendocrine tumors.⁵⁶ Segmental changes in the pancreatic duct are being increasingly encountered as patients undergo abdominal imaging for

evaluation of a variety of symptoms. The two most common causes of segmental pancreatic duct dilatation and pancreatic atrophy are chronic pancreatitis and malignant neoplasms such as PDAC. In rare instances, small serotonin secretin neuroendocrine tumors (serotoninoma) can induce fibrogenesis due to production of 5-hydroxyindoleacetic acid and serotonin, leading to obstruction of the pancreatic duct.^{57,58} These tumors are often detected incidentally while imaging patients for symptoms other than pancreatic etiology.

Management of Incidental Pancreatic Lesions

Most guidelines reach the consensus that the presence of a potentially resectable solid pancreatic mass in a CT scan or endoscopic ultrasound (US) in an otherwise healthy patient, with no clinical or biochemical characteristics suggesting a benign condition, should prompt surgical treatment.²⁷ Management of incidentally detected pNETs is a debatable topic. Indications for surgery in pNETs are functioning pNET and

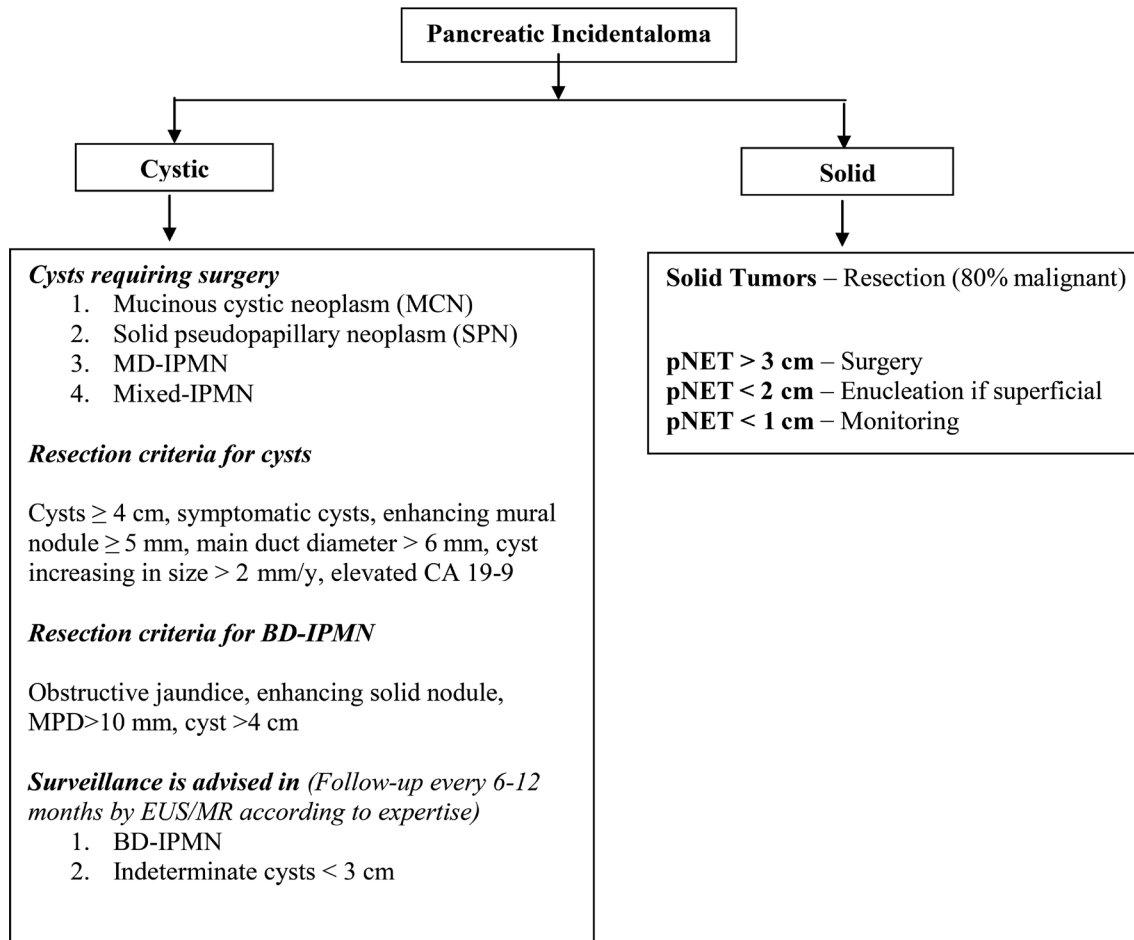


Fig. 6 Algorithm for the management of pancreatic incidentalomas.⁶¹⁻⁶⁴

Table 3 Practical tips in pancreatic incidentalomas

CT using pancreatic protocol is the imaging of choice for solid lesions
 MRI is the modality of choice in characterizing and for follow-up of cystic lesions
 EUS and fluid aspirate analysis are used for indeterminate lesions
 Solid pancreatic incidentalomas are considered malignant unless until proven otherwise
 High amylase and CEA levels in fluid suggest pseudocyst and mucinous neoplasms, respectively
 Simple cysts up to 3 cm in size with no worrisome features can be safely monitored
 Surgery is considered for MCN, SPN, MD-IPMN, mixed IPMN
 Surgery is considered for cysts > 3 cm and serous cystadenoma > 4 cm
 Solid lesions up to 2 cm in size are likely to be malignant and will require surgical intervention
 Small pNETs (<1 cm) are simply monitored
 Larger pNETs (>2 cm) lesions are treated by enucleation or resection
 Generally, pancreatic incidentalomas have a better prognosis than symptomatic lesions

Abbreviations: CEA, carcinoembryonic antigen; CT, computed tomography; EUS, endoscopic ultrasound; IPMN, intraductal papillary mucinous neoplasm; MCN, mucinous cystadenoma; MD-IPMN, main-duct intraductal papillary mucinous neoplasm; MRI, magnetic resonance imaging; pNETs, pancreatic neuroendocrine tumors; SPN, solid pseudopapillary tumor.

NF-pNETs > 2 cm. pNET < 1 cm can be kept on monitoring, and pNETs of 1 to 2 cm should be considered for enucleation if superficial in location.⁵⁹⁻⁶¹

Various published guidelines for the management of cystic lesions recommend resection of potentially malignant tumors such as mucinous cystadenomas, solid pseudo-papillary tumors, and main and mixed type of intraductal papillary mucinous neoplasms and observe benign lesions such as serous cystadenoma (< 4 cm) and BD IPMN.⁶²⁻⁶⁵ Close follow-up and surgical consideration are recommended in cases with worrisome features (symptomatic, cytology suspicious for malignancy, enhancing mural nodule < 5 mm, MPD > 6 mm, cyst size increasing > 2 mm/year, elevated CA19-9).⁶²⁻⁶⁵ The International Association of Pancreatology recommends surveillance for simple cysts < 3 cm in size. Patients with cysts < 1 cm are imaged at an interval of 2 to 3 years (CT/MRI), those with cysts 1 to 2 cm in diameter at an interval of 1 year (CT/MRI), and those with cysts of size 2 to 3 cm at an interval of 3 to 6 months (preferably endoscopic US).⁶⁴ An algorithmic approach to the management of PIs is illustrated in ►Fig. 6.

Conclusion

PIs are increasingly encountered by the radiologists today and are worrisome. These can be cystic or solid. An incidentally discovered pancreatic cystic lesion without any evidence of worrisome features and of < 2 cm is highly unlikely to cause morbidity or mortality. Around half of these lesions may eventually grow to be larger than 2 cm; therefore, adequate follow-up is advised. Solid PIs > 1 cm are potentially considered malignant, unless proven otherwise, and resection or enucleation is recommended. Key practical tips for the radiologists when dealing with PIs are given in ►Table 3.

Conflict of Interest

None declared.

References

- 1 Tsuda S, Pancreatic Incidentaloma [Internet] (updated 2013 June 06; cited 2017 April 09). Available at: <https://www.sages.org/wiki/pancreatic-incidentoma>. Accessed July 10, 2019
- 2 Kostiuik TS. Observation of pancreatic incidentaloma [in Russian] *Klin Khir* 2001;9(9):62-63
- 3 de Jong K, Nio CY, Hermans JJ, et al. High prevalence of pancreatic cysts detected by screening magnetic resonance imaging examinations. *Clin Gastroenterol Hepatol* 2010;8(9):806-811
- 4 Zhang XM, Mitchell DG, Dohke M, Holland GA, Parker L. Pancreatic cysts: depiction on single-shot fast spin-echo MR images. *Radiology* 2002;223(2):547-553
- 5 Kimura W, Nagai H, Kuroda A, Muto T, Esaki Y. Analysis of small cystic lesions of the pancreas. *Int J Pancreatol* 1995;18(3):197-206
- 6 Winter JM, Cameron JL, Lillemoe KD, et al. Periampullary and pancreatic incidentaloma: a single institution's experience with an increasingly common diagnosis. *Ann Surg* 2006;243(5):673-680
- 7 Pantoja M, Salazar M, Vela'zquez-Ferna'ndez D, Pancreatic incidentaloma. In: Hubbard JGH, Inabnet WB, Lo C-Y, eds.

Endocrine Surgery: Principles and Practice (Springer Specialist Surgery Series). 1st ed. London: Springer; 2009

- 8 Fernández-del Castillo C, Targarona J, Thayer SP, Rattner DW, Brugge WR, Warshaw AL. Incidental pancreatic cysts: clinicopathologic characteristics and comparison with symptomatic patients. *Arch Surg* 2003;138(4):427-433
- 9 Allen PJ, D'Angelica M, Conen M, et al. A selective approach to the resection of cystic lesions of the pancreas: results from 539 consecutive patients. *Ann Surg* 2006;244(4):572-582
- 10 Allen PJ, Jaques DP, D'Angelica M, Bowne WB, Conlon KC, Brennan MF. Cystic lesions of the pancreas: selection criteria for operative and nonoperative management in 209 patients. *J Gastrointest Surg* 2003;7(8):970-977
- 11 Surekha B, Bihari C, Arora A, et al. *JOP* 2016;17:452-465
- 12 Curry CA, Eng J, Horton KM, et al. CT of primary cystic pancreatic neoplasms: can CT be used for patient triage and treatment? *Am J Roentgenol* 2000;175(1):99-103
- 13 Bagci P, Andea AA, Basturk O, Jang KT, Erbarut I, Adsay V. Large duct type invasive adenocarcinoma of the pancreas with microcystic and papillary patterns: a potential microscopic mimic of non-invasive ductal neoplasia. *Mod Pathol* 2012;25(3):439-448
- 14 Horvath KD, Chabot JA. An aggressive resectional approach to cystic neoplasms of the pancreas. *Am J Surg* 1999;178(4):269-274
- 15 Mathieu D, Guigui B, Valette PJ, et al. Pancreatic cystic neoplasms. *Radiol Clin North Am* 1989;27(1):163-176
- 16 Taouli B, Vilgrain V, Vullierme MP, et al. Intraductal papillary mucinous tumors of the pancreas: helical CT with histopathologic correlation. *Radiology* 2000;217(3):757-764
- 17 Klöppel G, Kosmahl M. Cystic lesions and neoplasms of the pancreas. The features are becoming clearer. *Pancreatol* 2001;1(6):648-655
- 18 Nygaard KK, Walters W. Polycystic disease of the pancreas (dysontogenetic cysts): report of a case with partial pancreatectomy. *Ann Surg* 1937;106(1):49-53
- 19 Rodrigues-Pinto E, Pereira P, Cunha R, Macedo G. Pancreatic dysontogenetic cysts. *Rev Esp Enferm Dig* 2014;106(7):477-478
- 20 Hammel PR, Vilgrain V, Terris B, et al. Pancreatic involvement in von Hippel-Lindau disease. The Groupe Francophone d'Etude de la Maladie de von Hippel-Lindau. *Gastroenterology* 2000;119(4):1087-1095
- 21 van Asselt SJ, de Vries EG, van Dullemen HM, et al. Pancreatic cyst development: insights from von Hippel-Lindau disease. *Cilia* 2013;2(1):3
- 22 Kim JA, Blumenfeld JD, Chhabra S, et al. Pancreatic cysts in autosomal dominant polycystic kidney disease: prevalence and association with PKD2 gene mutations. *Radiology* 2016;280(3):762-770
- 23 Harris PC, Torres VE. Polycystic kidney disease. *Annu Rev Med* 2009;60:321-337
- 24 Chapman AB, Devuyst O, Eckardt KU, et al; Conference Participants. Autosomal-dominant polycystic kidney disease (ADPKD): executive summary from a Kidney Disease: Improving Global Outcomes (KDIGO) Controversies Conference. *Kidney Int* 2015;88(1):17-27
- 25 Palmucci S, Trombatore C, Foti PV, et al. The utilization of imaging features in the management of intraductal papillary mucinous neoplasms. *Gastroenterol Res Pract* 2014;2014:765451
- 26 Ren F, Zuo C, Chen G, et al. Pancreatic retention cyst: multi-modality imaging findings and review of the literature. *Abdom Imaging* 2013;38(4):818-826
- 27 Wolfson D, Barkin JS, Chari ST, et al. Management of pancreatic masses. *Pancreas* 2005;31(3):203-217
- 28 Steer ML, Waxman I, Freedman S. Chronic pancreatitis. *N Engl J Med* 1995;332(22):1482-1490
- 29 Finkelberg DL, Sahani D, Deshpande V, Brugge WR. Autoimmune pancreatitis. *N Engl J Med* 2006;355(25):2670-2676

- 30 McMahon PM, Halpern EF, Fernandez-del Castillo C, Clark JW, Gazelle GS. Pancreatic cancer: cost-effectiveness of imaging technologies for assessing resectability. *Radiology* 2001; 221(1):93–106
- 31 Nichols MT, Russ PD, Chen YK. Pancreatic imaging: current and emerging technologies. *Pancreas* 2006;33(3):211–220
- 32 Saisho H, Yamaguchi T. Diagnostic imaging for pancreatic cancer: computed tomography, magnetic resonance imaging, and positron emission tomography. *Pancreas* 2004;28(3):273–278
- 33 Lopez Hänninen E, Amthauer H, Hosten N, et al. Prospective evaluation of pancreatic tumors: accuracy of MR imaging with MR cholangiopancreatography and MR angiography. *Radiology* 2002;224(1):34–41
- 34 Kalra MK, Maher MM, Boland GW, Saini S, Fischman AJ. Correlation of positron emission tomography and CT in evaluating pancreatic tumors: technical and clinical implications. *Am J Roentgenol* 2003;181(2):387–393
- 35 Cwik G, Wallner G, Skoczylas T, Ciecchanski A, Zinkiewicz K. Cancer antigens 19-9 and 125 in the differential diagnosis of pancreatic mass lesions. *Arch Surg* 2006;141(10):968–973
- 36 Yao JC, Hassan M, Phan A, et al. One hundred years after “carcinoid”: epidemiology of and prognostic factors for neuroendocrine tumors in 35,825 cases in the United States. *J Clin Oncol* 2008;26(18):3063–3072
- 37 Bettini R, Boninsegna L, Mantovani W, et al. Prognostic factors at diagnosis and value of WHO classification in a mono-institutional series of 180 non-functioning pancreatic endocrine tumours. *Ann Oncol* 2008;19(5):903–908
- 38 Brentjens R, Saltz L. Islet cell tumors of the pancreas: the medical oncologist’s perspective. *Surg Clin North Am* 2001;81(3):527–542
- 39 Kaltsas GA, Besser GM, Grossman AB. The diagnosis and medical management of advanced neuroendocrine tumors. *Endocr Rev* 2004;25(3):458–511
- 40 Debray MP, Geoffroy O, Laissy JP, et al. Imaging appearances of metastases from neuroendocrine tumours of the pancreas. *Br J Radiol* 2001;74(887):1065–1070
- 41 Thoeni RF, Mueller-Lisse UG, Chan R, Do NK, Shyn PB. Detection of small, functional islet cell tumors in the pancreas: selection of MR imaging sequences for optimal sensitivity. *Radiology* 2000;214(2):483–490
- 42 Semelka RC, Custodio CM, Cem Balci N, Woosley JT. Neuroendocrine tumors of the pancreas: spectrum of appearances on MRI. *J Magn Reson Imaging* 2000;11(2):141–148
- 43 Gambill EE. Pancreatitis associated with pancreatic carcinoma: a study of 26 cases. *Mayo Clin Proc* 1971;46(3):174–177
- 44 McKay CJ, Glen P, McMillan DC. Chronic inflammation and pancreatic cancer. *Best Pract Res Clin Gastroenterol* 2008;22(1):65–73
- 45 Megibow AJ, Bosniak MA, Ambos MA, Beranbaum ER. Thickening of the celiac axis and/or superior mesenteric artery: a sign of pancreatic carcinoma on computed tomography. *Radiology* 1981;141(2):449–453
- 46 Luetmer PH, Stephens DH, Fischer AP. Obliteration of periarterial retropancreatic fat on CT in pancreatitis: an exception to the rule. *Am J Roentgenol* 1989;153(1):63–64
- 47 Frampas E, Morla O, Regenet N, Eugène T, Dupas B, Meurette G. A solid pancreatic mass: tumour or inflammation? *Diagn Interv Imaging* 2013;94(7-8):741–755
- 48 Kim T, Murakami T, Takamura M, et al. Pancreatic mass due to chronic pancreatitis: correlation of CT and MR imaging features with pathologic findings. *Am J Roentgenol* 2001;177(2):367–371
- 49 Kajiwara M, Gotohda N, Konishi M, et al. Incidence of the focal type of autoimmune pancreatitis in chronic pancreatitis suspected to be pancreatic carcinoma: experience of a single tertiary cancer center. *Scand J Gastroenterol* 2008;43(1):110–116
- 50 Manfredi R, Graziani R, Cicero C, et al. Autoimmune pancreatitis: CT patterns and their changes after steroid treatment. *Radiology* 2008;247(2):435–443
- 51 Learn PA, Grossman EB, Do RK, et al. Pitfalls in avoiding operation for autoimmune pancreatitis. *Surgery* 2011;150(5):968–974
- 52 Türkvatan A, Erden A, Türkoğlu MA, Yener Ö. Congenital variants and anomalies of the pancreas and pancreatic duct: imaging by magnetic resonance cholangiopancreatography and multidetector computed tomography. *Korean J Radiol* 2013;14(6):905–913
- 53 Schulte SJ. Embryology, normal variation, and congenital anomalies of the pancreas. In: Stevenson GW, Freeny PC, Margulis AR, Burhenne HJ, eds. *Margulis and Burhenne’s Alimentary Tract Radiology*, 5th ed. St. Louis, MO: Mosby 1994;1039–1051
- 54 Graziani R, Frulloni L, Cicero C, et al. Bull’s-eye pattern of pancreatic-duct stones on multidetector computed tomography and gene-mutation-associated pancreatitis (GMAP) *Radiol Med (Torino)* 2012;117(8):1275–1286
- 55 Cohn JA, Friedman KJ, Noone PG, Knowles MR, Silverman LM, Jowell PS. Relation between mutations of the cystic fibrosis gene and idiopathic pancreatitis. *N Engl J Med* 1998;339(10):653–658
- 56 Wilson RW, Gal AA, Cohen C, DeRose PB, Millikan WJ. Serotonin immunoreactivity in pancreatic endocrine neoplasms (carcinoid tumors) *Mod Pathol* 1991;4(6):727–732
- 57 Druce M, Rockall A, Grossman AB. Fibrosis and carcinoid syndrome: from causation to future therapy. *Nat Rev Endocrinol* 2009;5(5):276–283
- 58 Kawamoto S, Shi C, Hruban RH, et al. Small serotonin-producing neuroendocrine tumor of the pancreas associated with pancreatic duct obstruction. *Am J Roentgenol* 2011;197(3):W482–8
- 59 Stratilatovas E, Sangaila E, Cicenias S. Radical surgery for large-sized slow-growing neuroendocrine tumor of the pancreas. *J BUON* 2002;7(4):381–383
- 60 Franko J, Feng W, Yip L, Genovese E, Moser AJ. Non-functional neuroendocrine carcinoma of the pancreas: incidence, tumor biology, and outcomes in 2,158 patients. *J Gastrointest Surg* 2010;14(3):541–548
- 61 Karatzas T, Dimitroulis D, Charalampoudis P, Misiakos EP, Vasileiadis I, Kouraklis G. Management of cystic and solid pancreatic incidentalomas: a review analysis. *J BUON* 2013;18(1):17–24
- 62 Hol L, Bruno MJ, Cahen DL. Follow-up of asymptomatic pancreatic cysts in clinical practice: a vignette questionnaire. *Pancreatol* 2016;16(3):416–422
- 63 Vege SS, Ziring B, Jain R, Moayyedi P; Clinical Guidelines Committee; American Gastroenterology Association. American Gastroenterological Association Institute guideline on the diagnosis and management of asymptomatic neoplastic pancreatic cysts. *Gastroenterology* 2015;148(4):819–822
- 64 Tanaka M, Fernández-Del Castillo C, Kamisawa T, et al. Revisions of international consensus Fukuoka guidelines for the management of IPMN of the pancreas. *Pancreatol* 2017;17(5):738–753
- 65 Del Chiaro M, Verbeke C, Salvia R, et al; European Study Group on Cystic Tumours of the Pancreas. European experts consensus statement on cystic tumours of the pancreas. *Dig Liver Dis* 2013;45(9):703–711