

# Comparative Analysis and Long-Term Results of Various Septal Extension Graft Types

M. Brandstetter, MD<sup>1</sup> M. Bhatt, MD<sup>2</sup> M. Pham, MD<sup>1</sup> W. Gubisch, PhD<sup>1</sup> S. Haack, MD<sup>1</sup>

<sup>1</sup>Department of Facial Plastic Surgery, Marienhospital Stuttgart, Stuttgart, Germany

<sup>2</sup>ENT Clinic Mumbai, Mumbai, Maharashtra, India

Address for correspondence Michael Brandstetter, MD, Department of Facial Plastic Surgery, Marienhospital Stuttgart, Stuttgart 70199, Germany (e-mail: brandstetter.md@gmail.com).

Facial Plast Surg 2020;36:263–267.

## Abstract

Shape, tip projection, and position can be controlled by the use of septal extension grafts (SEG). A retrospective cohort study of patients undergoing primary and secondary rhinoplasty was reviewed. The purpose of this study was to analyze maintenance of nasal length, dorsal length, and nasolabial angle postoperatively comparing different types of SEG using standardized photography and digital measurement. Two-hundred twenty-one patients undergoing rhinoplasty were included. There was a statistically significant change regarding the nasolabial angle during the time of follow-up decreasing from 97.53 to 95.30 degrees. No changes could be found in dorsal and nasal length. There was no significant difference among the techniques used to fixate the SEG. The nasolabial angle appeared to decrease from the position 2 weeks postoperatively without changes in the dorsal and nasal length. This means that the decrease in the nasolabial angle depends on the swelling effect and not on drooping of the tip confirming the reliability of SEG over time.

## Keywords

- ▶ septal extension graft
- ▶ rhinoplasty
- ▶ tongue in groove
- ▶ double-layered conchal graft

One of the major challenges in rhinoplasty is to gain an adequate tip position ensuring a stable projection and rotation. Nasal tip plasty is a key component in aesthetic rhinoplasty. To obtain the ideal nasal tip position, both projection and rotation need to be considered. The nasal tip tripod theory suggested by Anderson in 1966 has led to the development of several important techniques.<sup>1–3</sup> Of these, the septal extension graft (SEG) is currently the favored technique in primary and secondary rhinoplasty to provide a stable tip projection and rotation.<sup>4</sup>

The SEG, first introduced by Byrd et al<sup>5</sup> in 1997, lengthens the septum by fixating a graft to the caudal septal boarder. It is positioned between the medial crura and therefore defines the nasal length, tip projection, and rotation.

In contrast to the columellar strut, the SEG has been found to be more reliable for maintaining tip position over time, specifically in patients with a midvault or weak lower lateral cartilages.<sup>6</sup>

## Materials and Methods

This is a retrospective study of patients who underwent a septorhinoplasty with SEG in the Department of Facial Plastic Surgery at Marienhospital, Stuttgart, from January 2015 to December 2017. During this period, a septorhinoplasty was performed on 1,876 patients. In 221 of the cases, a SEG was used.

The study includes patients who underwent either a primary or secondary rhinoplasty with SEG. We compared the side-to-side fixation, end-to-end fixation with unilateral splinting (perpendicular plate or thinned ethmoid bone), end-to-end fixation with extended spreader grafts, and double-layered conchal sandwich graft used as SEG.

In all cases, the medial crura were sutured directly to the SEG in a tongue-in-groove fashion.<sup>7</sup>

The nasolabial angle was measured, 2 weeks postoperatively and on follow-up consultation after 1 year. Further, the dorsal length, which is defined as distance between the nasion and the tip defining point, as well as the nasal length,

published online  
June 8, 2020

Issue Theme Facial Plastic Surgery  
Original Research; Guest Editors: Anthony P. Sclafani, MD, MBA, FACS, and Alwyn D'Souza, MBBS, FRCS Eng, FRCS (ORL-HNS)

Copyright © 2020 by Thieme Medical Publishers, Inc., 333 Seventh Avenue, New York, NY 10001, USA.  
Tel: +1(212) 760-0888.

DOI <https://doi.org/10.1055/s-0040-1712468>.  
ISSN 0736-6825.

describing the length from the nasion to the subnasale point, were recorded.

Standardized pictures were taken with a fixed distance to the sagittal facial plane (SFP). SFP was determined using a Multipurpose Laser Level Ruler (Loskii, Multipurpose Laser Level Ruler, built-in 3 measuring water drop, max output < 0.5 mW) to assure reproducibility in taking standard profile view pictures, scaling for digital measurement within the same sagittal plane.

The aligned pictures taken were processed digitally using the professional measuring program PixelStick 2.15.0 (Plum Amazing Software LLC for Mac).

The digital measurements were taken by pixel count given by the scaling of 1 cm at the aligned MPP Laser being seen within the picture.

Postoperative measurements were compared with the ones from the last follow-up (average 11 months) using the *t*-test paired two sample for means with 0 hypothesis.

In this study, 221 patients, who received a SEG, were included. Sixty-three of them were males and 158 were females. The mean age was 35 years. Ninety-eight patients were secondary cases, while 123 were primary ones. In 42 patients, we used extended spreader grafts for fixation of the SEG; in 74 cases, the SEG was fixed in an end-to-end manner by bony splints. In 22 cases, double-layered conchal grafts were sutured to the anterior border of the septum.

In 83 cases, we fixed the graft side to side, while in 138 cases, we used the end-to-end techniques.

### Surgical Technique

An open approach technique was performed in all cases.

A large cartilaginous graft from the septum was harvested preserving a residual L-shaped frame of 18 to 20 mm. In addition, a piece of ethmoid bone or perpendicular plate was resected and thinned to create a bony splint. To avoid a bad fracture during the bone harvest, we cut the bone at the intercanthal level using a side cutting burr, ~2 cm under the dorsal line choosing an angle of ~60 degrees downward.

If not enough cartilage was found, for example in cases of a weak and over-resected septum, we created a strong framework using double-layered rib grafts (beam graft). We tried to include at least a straight part of the residual septum as a SEG.

### Side-to-Side Fixation

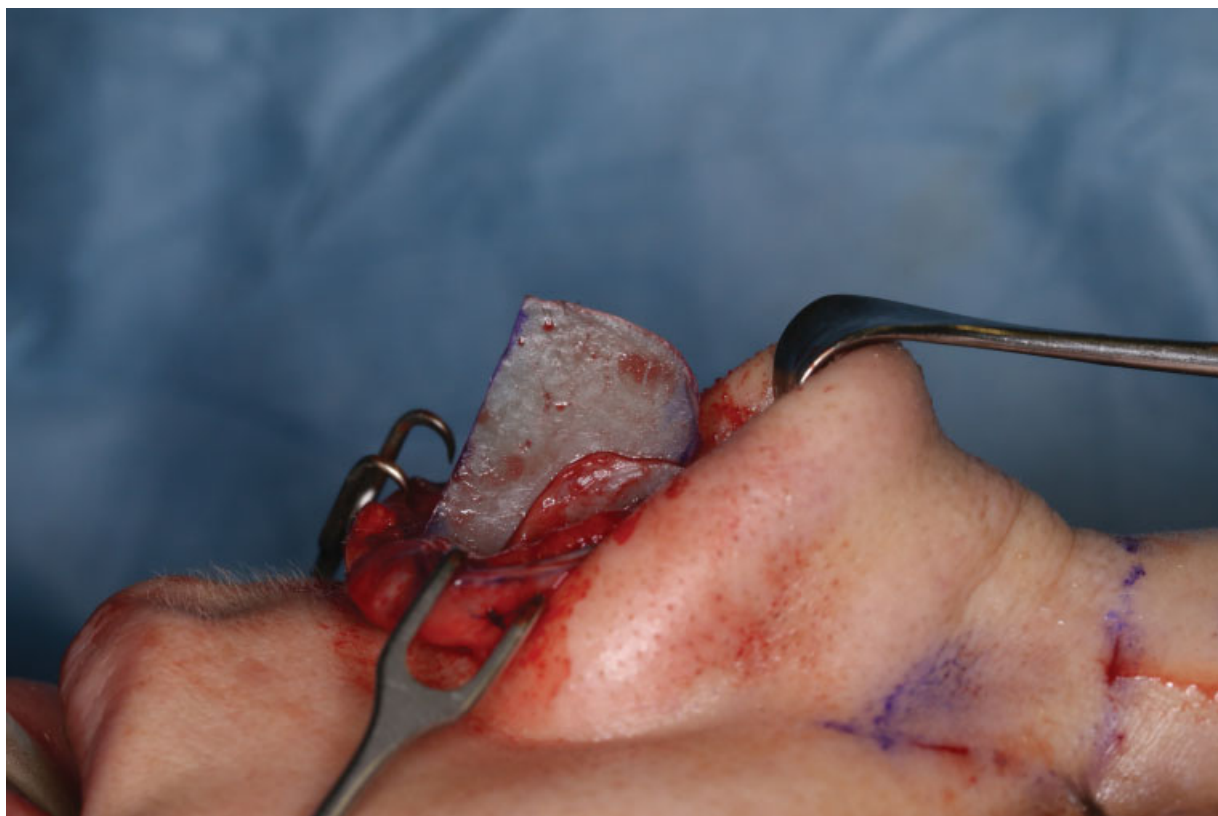Side-to-side fixation is technically easier, but needs a larger amount of cartilage. Further this technique creates an asymmetry.

The side-to-side fixation of the SEG can be used for correction of the asymmetry in cases where the anterior septal border is not exactly in the midline.

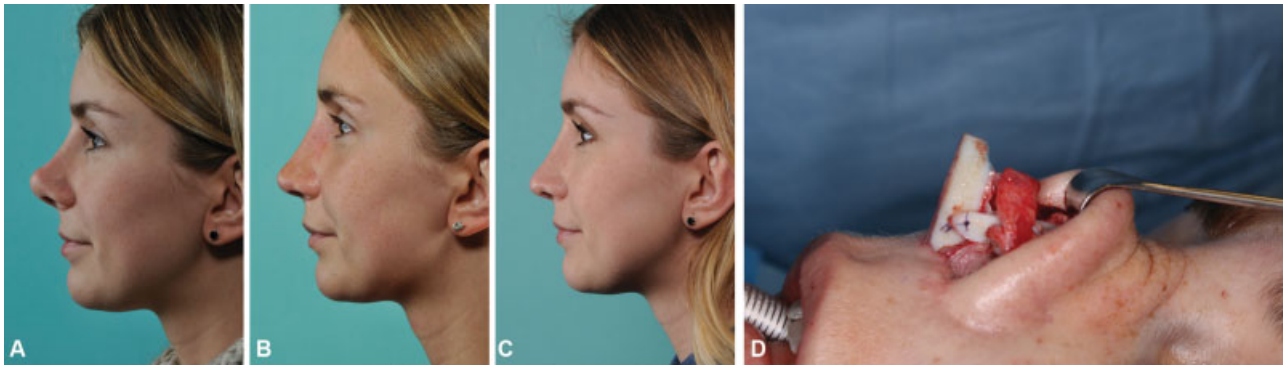
Side-to-side fixation was performed with multiple mattress sutures using a Keith needle (4.0 polydioxanone suture [PDS]) (→Fig. 1).

### Fixation by Extended Spreader Grafts

Guyuron and Varghai proposed fixing the SEG with extended spreader grafts to the caudal septal border (→Fig. 2). This technique maintains symmetry and ensures a stable fixation.



**Fig. 1** Intraoperative view of a side-to-side septal extension graft.



**Fig. 2** A 31-year-old female patient with short nose and overprojected tip after previous rhinoplasty. (A) Profile view before revision rhinoplasty. (B) 2 weeks postoperatively. (C) At 7 months follow-up. (D) Intraoperative view with extended spreader grafts made from rib cartilage (1.5 mm thickness) with the septal extension fixed in between with 5.0 polydioxanone suture.

In secondary cases, there frequently is a lack of adequate septal cartilage to create two extended spreader grafts as well as a sufficient SEG. Therefore, rib grafts may become necessary. The end of the extended spreader grafts has to be beveled carefully to avoid any bulging into the upper vestibule.

### Bony Splinting

This technique is based on harvesting some septal bone and thinning it to create a somewhat small but stable graft.

We treat the bone with a cylindrical burr until it gets paper thin. Then we apply as many drill holes as possible with a thin side cutting burr or a spiral drill. The graft is fixed unilaterally with multiple mattress sutures. We are using 4.0 PDS with a

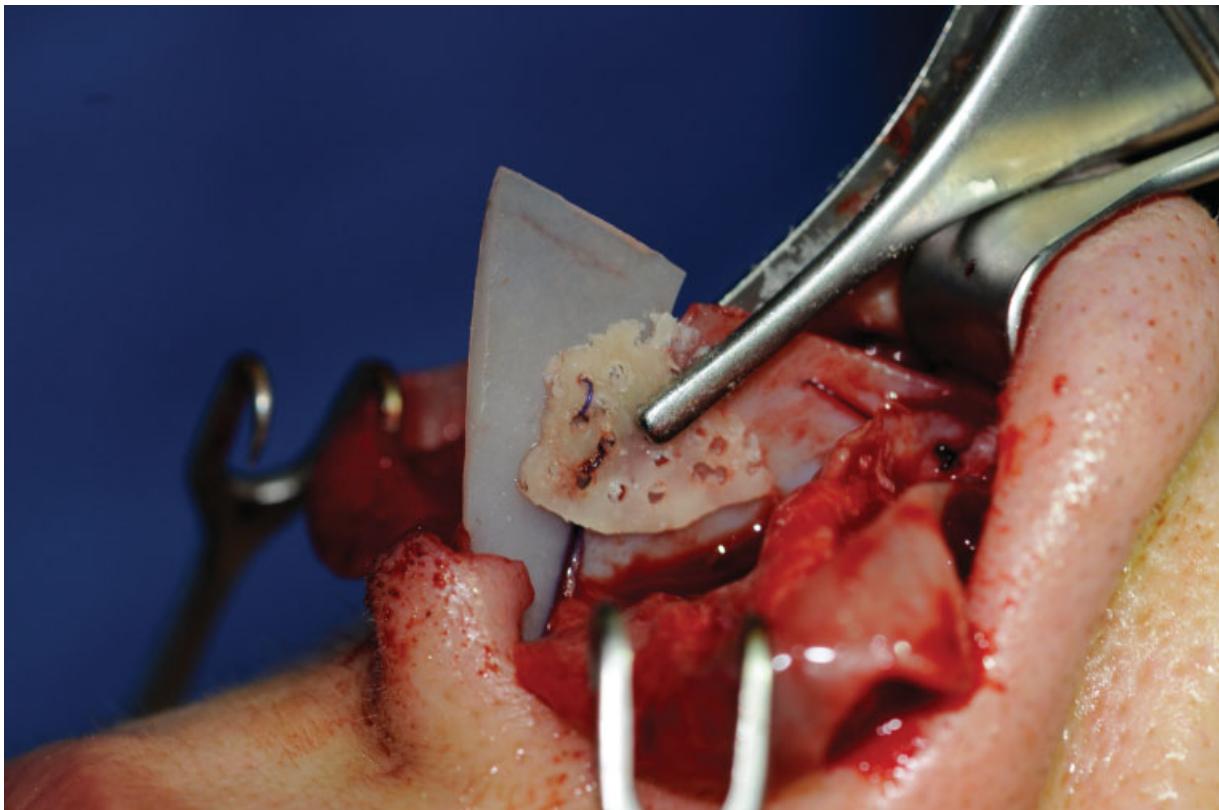
straight needle. The multiple perforations in the bony graft facilitate to hit one of the holes coming from the backside during mattress suturing (→Fig. 3).

Furthermore, the perforations of the graft will facilitate fibrous tissue ingrowth giving additional stabilization.

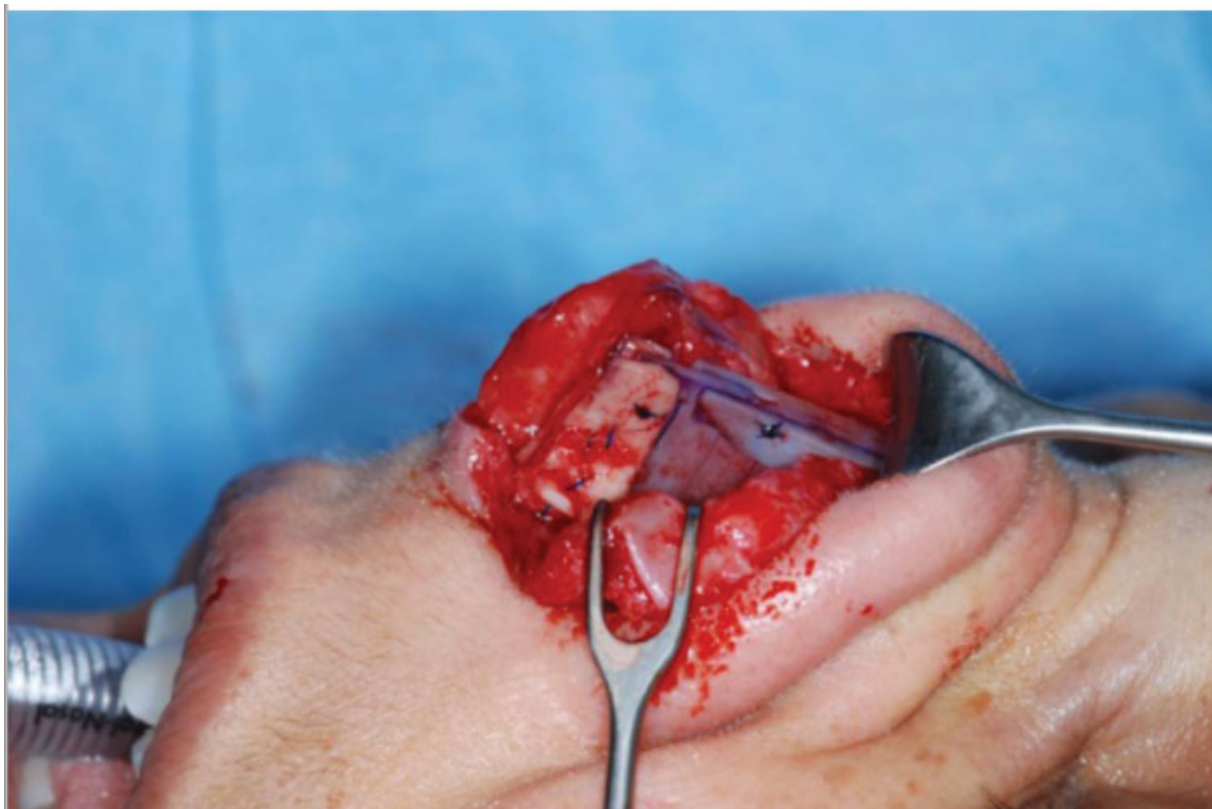This component graft existing from the SEG and the bony splint is prepared first on the table, before it is replanted and fixed to the residual septum.

### Double-Layered Conchal Graft

If there is not enough adequate septal cartilage, conchal cartilage can be used as SEG. Because conchal cartilage grafts are anatomically curved, it is necessary to cut the concha from the concave side to the perichondrium of the opposite



**Fig. 3** Septal extension end to end fixed with an ethmoid bone plate.



**Fig. 4** Double layered conchal graft fixed to the anterior septal border.

side, then to fold these parts backward and suture the opposing convexities of the conchal cartilage to one another.

Two or three horizontal mattress sutures are placed using 4–0 PDS. The ends of the folded graft are intentionally left unsutured so the graft can straddle the septum to fixate it in a tongue-in-groove fashion to extend the caudal septum.<sup>8</sup> (→**Fig. 4**)

## Results

Goal of the study was to proof the long-term effect of SEG and to compare the different techniques of graft fixation.

We measured the nasolabial angle 2 weeks postoperatively and at the final consultation, which took place around 11 months after surgery (ranging from 5 to 44 months). During that time, the nasolabial angle decreased from 97.53 to 95.30.

Because we could not find any change in the dorsal length, we conclude that the decrease in the nasolabial angle is due to reduction in the swelling and is not created by drooping of the tip.

The study showed that the nasolabial angle decreased 2.2 degrees (from 97.53 to 95.30) between 2 weeks follow-up and the last consultation. It is noteworthy that the dorsal and nasal length did not change statistically. This means that the decrease in the nasolabial angle depends on the swelling effect and not on drooping of the tip.

There was no significant difference among the techniques used to fixate the SEG (→**Table 1**).

## Discussion

The anterior septal boarder is the most important tip supporting element.<sup>9</sup> This can be enforced by a columella strut or SEG. For these techniques, autogenous cartilages, preferably septal cartilage, but also conchal or rib cartilage are good graft materials and guarantee correct nasal tip placement.<sup>6</sup>

The SEG technique has been popularized within the last years. Therefore, we wanted to analyze the long-term reliability of SEG.

In principle, there are two different techniques: side-to-side or end-to-end fixation of the graft. The selection of the technique depends on the amount and quality of septal cartilage, which is the material of choice.

Side-to-side fixation needs a large piece of cartilage. End-to-end fixation is a cartilage-saving technique. On the other hand, side-to-side fixation gives a very stable result. End-to-end extension is technically more demanding. Our study shows that there is no difference in the long-term effect whatever technique is chosen.

Next to our techniques of fixing the graft in an end-to-end manner, there are other techniques, which we only used in selected cases. For example, SEG fixation with multiple figure of eight sutures, or a caudal septal transposition strut.<sup>10,11</sup>

Septal cartilage is preferable for many reasons. The graft is slim and strong and it can be harvested easily without any additional morbidity.

It seems that the SEG graft is more reliable than the columella strut, but SEG graft produces more rigidity and

**Table 1** Measurements of nasal length, dorsal length, and nasolabial angle comparing different types of SEG, 2 weeks and 11.5 months, postoperatively

Time	Nasolabial angle (degree)	Nasal length (mm)	Dorsal length (mm)
SEG types (mean value)			
2 wk postoperatively	97.53	50.38	42.55
Follow-up (mean 11.5 mo)	95.30	50.49	43.36
Side-to-side fixation			
2 wk postoperatively	99.39	50.79	43.38
Follow-up (mean 11.5 mo)	97.22	51.11	44.46
Bony splinting			
2 wk postoperatively	95.98	50.82	43.38
Follow-up (mean 11.5 mo)	91.63	51.01	44.46
Double layered conchal graft			
2 wk postoperatively	98.31	49.33	40.02
Follow-up (mean 11.5 mo)	96.68	50.36	41.26
Fixation by extended spreader grafts			
2 wk postoperatively	96.44	50.57	43.08
Follow-up (mean 11.5 mo)	95.66	49.47	44.03

Abbreviation: SEG, septal extension graft.

stiffness of the tip, whereas the columella strut gives a more natural mobility. The surgeon has to find a compromise for each individual between these two surgical aspects.

The results of this study show a change of the nasolabial angle over time, but no change in nasal length. This means that the alteration of the nasolabial angle results most probably more from the decrease in swelling, but not of tip drooping. Therefore, this study confirms the reliability of the SEG concerning the tip position.

## Conclusion

The SEG is a very reliable graft for long-term support of the tip position. The long-term result does not depend on the individual technique of graft fixation or graft material used.

The surgeon has to decide individually which SEG technique seems to be most comfortable for him; the final result most probably will be the same.

### Conflict of Interest

None declared.

## References

- Gubisch W, Eichhorn-Sens J. The sliding technique: a method to treat the overprojected nasal tip. *Aesthetic Plast Surg* 2008;32(05):772–778
- Dobratz EJ, Tran V, Hilger PA. Comparison of techniques used to support the nasal tip and their long-term effects on tip position. *Arch Facial Plast Surg* 2010;12(03):172–179
- Gruber RP, Chang E, Buchanan E. Suture techniques in rhinoplasty. *Clin Plast Surg* 2010;37(02):231–243
- Toriumi DM. Discussion: septum-based nasal tip plasty: a comparative study between septal extension graft and double-layered conchal cartilage extension graft. *Plast Reconstr Surg* 2018;141(01):57–58
- Byrd HS, Andochick S, Copit S, Walton KG. Septal extension grafts: a method of controlling tip projection shape. *Plast Reconstr Surg* 1997;100(04):999–1010
- Akkus AM, Eryilmaz E, Guneren E. Comparison of the effects of columellar strut and septal extension grafts for tip support in rhinoplasty. *Aesthetic Plast Surg* 2013;37(04):666–673
- Guyuron B, Varghai A. Lengthening the nose with a tongue-and-groove technique. *Plast Reconstr Surg* 2003;111(04):1533–1539, discussion 1540–1541
- Haack S, Gubisch W. Reconstruction of the septum with an autogenous double-layered conchal L-strut. *Aesthetic Plast Surg* 2014;38(05):912–922
- Erol O, Buyuklu F, Koycu A, Bas C, Erbek SS. Evaluation of nasal tip support in septorhinoplasty. *Aesthetic Plast Surg* 2019;43(04):1021–1027
- Han K, Jin HS, Choi TH, Kim JH, Son D. A biomechanical comparison of vertical figure-of-eight locking suture for septal extension grafts. *J Plast Reconstr Aesthet Surg* 2010;63(02):265–269
- Kim MH, Choi JH, Kim MS, Kim SK, Lee KC. An introduction to the septal extension graft. *Arch Plast Surg* 2014;41(01):29–34