

Successful Use of Argatroban to Treat a Critically Ill Patient with Coagulopathy and Nephropathy Secondary to COVID-19

Matthew C. Frise^{1,2}  Rebecca E.V. Gates¹ Nicola S. Curry³ Christopher M. Danbury¹

¹Royal Berkshire NHS Foundation Trust, Royal Berkshire Hospital, Reading, United Kingdom

²Department of Physiology, Anatomy and Genetics, University of Oxford, Oxford, United Kingdom

³Oxford University Hospitals NHS Foundation Trust, Churchill Hospital, Headington, Oxford, United Kingdom

Address for correspondence Matthew C. Frise, DPhil, Intensive Care Unit, Royal Berkshire Hospital, London Road, Reading, RG1 5AN, United Kingdom (e-mail: matthew.frise@royalberkshire.nhs.uk).

TH Open 2020;4:e400–e402.

Data from early case series of patients infected with severe acute respiratory syndrome coronavirus 2 (SARS-CoV-2) indicated that disordered thrombosis and hemostasis were frequent features of coronavirus disease 2019 (COVID-19) portending a worse outcome.^{1–4} For example, in a case series of 191 patients from two Wuhan hospitals, an elevated admission D-dimer level was associated with almost a 20-fold increased risk of death.⁵ A further single center study of 183 patients from another Wuhan hospital found that elevated fibrin degradation product levels, as well as a prolonged prothrombin time and activated partial thromboplastin time (APTT), were associated with a significantly higher mortality.⁶

As the pandemic has progressed, it has become clear that while the coagulopathy of COVID-19 shares features with both disseminated intravascular coagulation (DIC)⁷ and thrombotic microangiopathy (TMA),⁸ several aspects make it distinct from each of these entities.^{9,10} It has even been suggested that in an extreme form, the coagulopathy of COVID-19 resembles antiphospholipid syndrome, evidenced by multiple thrombotic events and positive serological tests in keeping with such a diagnosis.^{11,12}

One aspect of the challenges posed by this unusual coagulopathy that has received relatively little attention is the impact on instituting renal replacement therapy (RRT). Acute kidney injury necessitating RRT occurs in at least one in five COVID-19 patients requiring intensive care unit (ICU) admission.^{13,14} Difficulties related to thrombosis of extracorporeal circuits have been described^{15,16}; strategies to overcome this problem are urgently required, not simply so that RRT can be instituted in a timely manner and delivered effectively, but also because prolonging circuit life is essential in the context of a pandemic when supplies of consumables risk becoming exhausted.¹⁴

Here we describe a patient with multiple organ failure secondary to COVID-19 who exhibited significant derangement of laboratory coagulation indices, and in whom attempts to institute acute RRT were hampered by repeated thrombosis of the hemofiltration circuit and vascular access catheters. In late March 2020, the patient, a 62-year-old man with hypertension, obesity, and hypercholesterolemia, presented to the Emergency Department with profound hypoxemia refractory to supplemental oxygen therapy. Admission laboratory findings of note included a D-dimer of 1,868 µg FEU/L, fibrinogen 10.17 g/L, creatinine 150 µmol/L, urea 12.2 mmol/L, C-reactive protein 364 mg/L, and ferritin 2,428 ug/L. He required intubation, mechanical ventilation, and circulatory support with norepinephrine, and went on to become anuric within 24 hours.


Ten hours after admission the decision was taken to institute continuous venovenous hemodiafiltration (CVVHDF). A 12 Fr 20-cm dual-lumen Arrow vascular access catheter (Teleflex Inc, Reading, Pennsylvania, United States) was inserted into the right femoral vein under real-time ultrasound guidance. CVVHDF was commenced using a Prismaflex platform and ST150 filter set (Baxter International Inc, Deerfield, Illinois, United States) at 25 mL/kg/h using a predilution strategy. Anticoagulation was provided by systemic infusion of unfractionated heparin (UFH) aiming for an APTT of 45 to 70 seconds. It was impossible to institute effective RRT, as evidenced by a relentlessly climbing serum creatinine despite multiple attempts and repeated insertion of new vascular access catheters at different sites. The hemofiltration circuits clotted very quickly, one of them within minutes of commencement of therapy. Tinzaparin 175 units/kg once daily was given on

received
July 8, 2020
accepted after revision
October 28, 2020

DOI <https://doi.org/10.1055/s-0040-1721501>.
ISSN 2512-9465.

© 2020 Georg Thieme Verlag KG
Rüdigerstraße 14, 70469 Stuttgart,
Germany

License terms



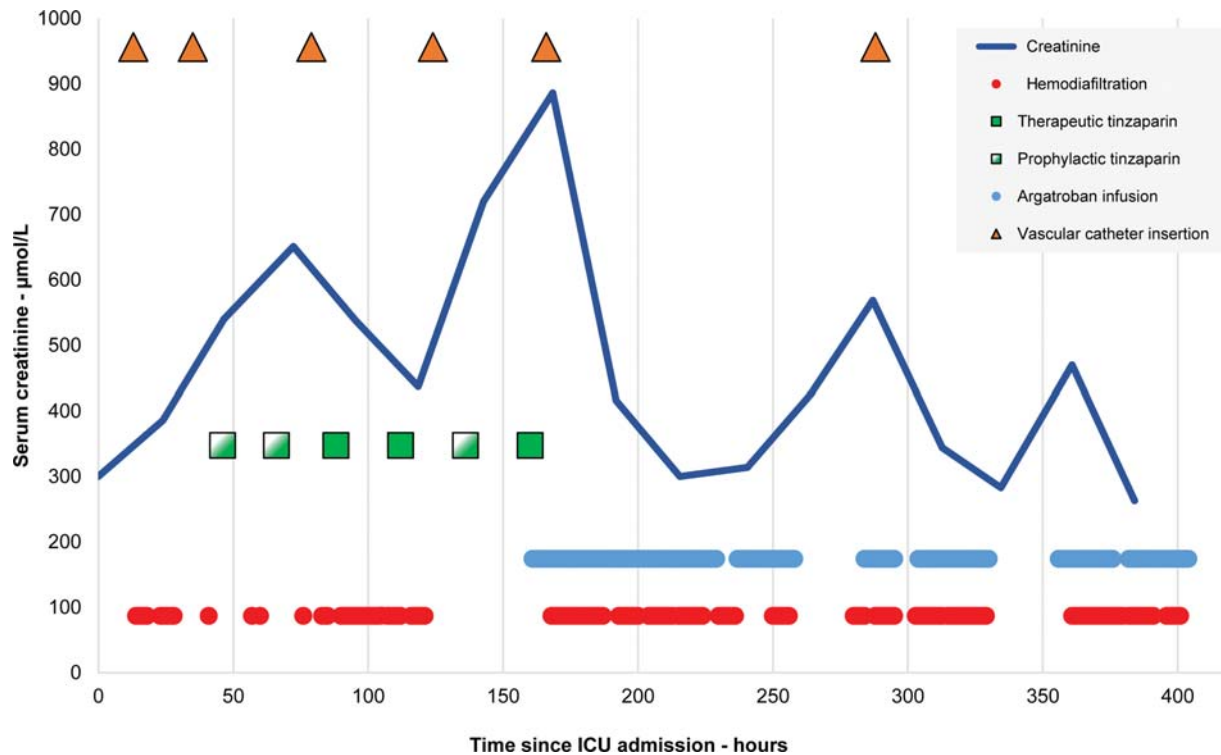


Fig. 1 Anticoagulation therapy, vascular access catheter insertions, and periods of hemodiafiltration after ICU admission. The final line inserted was a tunneled semi-permanent dialysis catheter. ICU, intensive care unit.

three occasions in addition to intravenous UFH, with no obvious benefit. **Fig. 1** illustrates these events.

Six days into his ICU stay all heparin was discontinued and an infusion of argatroban commenced at an initial rate of 0.5 µg/kg/min. The APTT was measured every 4 hours and the infusion rate increased by 0.1 µg/kg/min until the APTT ratio was consistently between 1.5 and 3. A rapid improvement in the life of the hemofiltration circuits and vascular access catheters followed, and a corresponding decrease in the serum creatinine was swiftly observed. After several days of argatroban therapy, a tunneled semi-permanent dialysis catheter was sited under fluoroscopic guidance. This continued to function throughout a subsequent tracheostomy wean. On the 18th day of his admission the D-dimer had risen to 6,309 µg FEU/L, ultimately peaking at 18,775 µg FEU/L on the 28th day. He was eventually successfully decannulated, became independent of RRT, and was discharged home after nearly 2 months in hospital.

Many intensivists will be familiar with the utility of argatroban, a small molecule direct thrombin inhibitor, from its use in critically ill patients with heparin-induced thrombocytopenia.¹⁷ That we overcame the difficulties encountered in this case using argatroban supports the view that heparin resistance plays a central role in the coagulopathy of COVID-19. It also accords with the observation that rates of venous thromboembolism (VTE) in critically ill patients with COVID-19 are extremely high when prophylactic anticoagulation with low molecular weight heparin is used, and that VTE can be detected in the majority of patients with severe COVID-19 even when therapeutic anticoagulation is employed empirically early in the course of the disease.¹⁸ Heparin resistance in this setting

has been attributed to the combination of high factor VIII and fibrinogen levels accompanied by low circulating antithrombin,¹⁹ a picture that has been described as a prothrombotic variant of DIC.²⁰

Since our patient's discharge from hospital, a single-center study has suggested argatroban to be effective when utilized as an escalation therapy in patients with COVID-19 who have already developed thromboembolism and who require continuous RRT.²¹ Additionally, argatroban use has been described in a small group of patients more profoundly critically ill with SARS-CoV-2 infection, most of whom required extracorporeal membrane oxygenation (ECMO).²² Aside from RRT and ECMO, an extracorporeal approach to removing circulating SARS-CoV-2 from the bloodstream is also being explored²³; effective anticoagulation strategies will be essential if such extracorporeal therapies are to be successful.

Further studies are urgently required to determine the molecular pathogenesis of, and optimum treatment for, the coagulopathy seen in COVID-19.^{3,4} Although direct infection of renal tissue by SARS-CoV-2 appears to be of greater importance than TMA in the pathophysiology of the nephropathy seen in the condition,²⁴ the prothrombotic state may seriously compromise the supportive care of these patients when critically ill. We believe it is important to highlight our experience with argatroban in this patient, in whom it appeared to be life-saving. We believe that the efficacy of argatroban in this setting should be explored in a randomized controlled trial.

Conflict of Interest
None declared.

References

- 1 Lippi G, Favaloro EJ. D-dimer is associated with severity of coronavirus disease 2019: a pooled analysis. *Thromb Haemost* 2020;120(05):876–878
- 2 Terpos E, Ntanasis-Stathopoulos I, Elalamy I, et al. Hematological findings and complications of COVID-19. *Am J Hematol* 2020;95(07):834–847
- 3 Kollias A, Kyriakoulis KG, Dimakakos E, Poulakou G, Stergiou GS, Syrigos K. Thromboembolic risk and anticoagulant therapy in COVID-19 patients: emerging evidence and call for action. *Br J Haematol* 2020;189(05):846–847
- 4 Levi M, Thachil J, Iba T, Levy JH. Coagulation abnormalities and thrombosis in patients with COVID-19. *Lancet Haematol* 2020;7(06):e438–e440
- 5 Zhou F, Yu T, Du R, et al. Clinical course and risk factors for mortality of adult inpatients with COVID-19 in Wuhan, China: a retrospective cohort study. *Lancet* 2020;395(10229):1054–1062
- 6 Tang N, Li D, Wang X, Sun Z. Abnormal coagulation parameters are associated with poor prognosis in patients with novel coronavirus pneumonia. *J Thromb Haemost* 2020;18(04):844–847
- 7 Violi F, Pastori D, Cangemi R, Pignatelli P, Loffredo L. Hypercoagulation and antithrombotic treatment in coronavirus 2019: a new challenge. *Thromb Haemost* 2020;120(06):949–956
- 8 Bikdeli B, Madhavan MV, Gupta A, et al; Global COVID-19 Thrombosis Collaborative Group. Pharmacological agents targeting thromboinflammation in COVID-19: review and implications for future research. *Thromb Haemost* 2020;120(07):1004–1024
- 9 Iba T, Levy JH, Levi M, Connors JM, Thachil J. Coagulopathy of coronavirus disease 2019. *Crit Care Med* 2020;48(09):1358–1364
- 10 Spiezia L, Boscolo A, Poletto F, et al. COVID-19-related severe hypercoagulability in patients admitted to intensive care unit for acute respiratory failure. *Thromb Haemost* 2020;120(06):998–1000
- 11 Zhang Y, Xiao M, Zhang S, et al. Coagulopathy and antiphospholipid antibodies in patients with COVID-19. *N Engl J Med* 2020;382(17):e38
- 12 Harzallah I, Debliquis A, Drénou B. Lupus anticoagulant is frequent in patients with COVID-19. *J Thromb Haemost* 2020;18(08):2064–2065
- 13 Ronco C, Reis T, Husain-Syed F. Management of acute kidney injury in patients with COVID-19. *Lancet Respir Med* 2020;8(07):738–742
- 14 Goldfarb DS, Benstein JA, Zhdanova O, et al. Impending shortages of kidney replacement therapy for COVID-19 patients. *Clin J Am Soc Nephrol* 2020;15(06):880–882
- 15 Sise ME, Baggett MV, Shepard JO, Stevens JS, Rhee EP. Case 17–2020: A 68-year-old man with COVID-19 and acute kidney injury. *N Engl J Med* 2020;382(22):2147–2156
- 16 Wilbers TJ, Koning MV. Renal replacement therapy in critically ill patients with COVID-19: a retrospective study investigating mortality, renal recovery and filter lifetime. *J Crit Care* 2020;60:103–105
- 17 Saugel B, Phillip V, Moessmer G, Schmid RM, Huber W. Argatroban therapy for heparin-induced thrombocytopenia in ICU patients with multiple organ dysfunction syndrome: a retrospective study. *Crit Care* 2010;14(03):R90
- 18 Llitjos JF, Leclerc M, Chochois C, et al. High incidence of venous thromboembolic events in anticoagulated severe COVID-19 patients. *J Thromb Haemost* 2020;18(07):1743–1746
- 19 White D, MacDonald S, Bull T, et al. Heparin resistance in COVID-19 patients in the intensive care unit. *J Thromb Thrombolysis* 2020;50(02):287–291
- 20 Wang J, Hajizadeh N, Moore EE, et al. Tissue plasminogen activator (tPA) treatment for COVID-19 associated acute respiratory distress syndrome (ARDS): a case series. *J Thromb Haemost* 2020;18(07):1752–1755
- 21 Shankaranarayanan D, Muthukumar T, Barbar T, et al. Anticoagulation strategies and filter life in COVID-19 patients receiving continuous renal replacement therapy: a single-center experience. *Clin J Am Soc Nephrol* 2020 (e-pub ahead of print). Doi: 10.2215/CJN.08430520
- 22 Arachchillage DJ, Remington C, Rosenberg A, et al. Anticoagulation with argatroban in patients with acute antithrombin deficiency in severe COVID-19. *Br J Haematol* 2020;190(05):e286–e288
- 23 Seffer MT, Cottam D, Forni LG, Kielstein JT. Heparin 2.0: a new approach to the infection crisis. *Blood Purif* 2020 (e-pub ahead of print). Doi: 10.1159/000508647
- 24 Su H, Yang M, Wan C, et al. Renal histopathological analysis of 26 postmortem findings of patients with COVID-19 in China. *Kidney Int* 2020;98(01):219–227