

Ultrasound Vascular Elastography as a Tool for Assessing Atherosclerotic Plaques – A Systematic Literature Review

Authors

B. Mahmood, C. Ewertsen, J. Carlsen, M. B. Nielsen

Affiliations

Department of Radiology, University Hospital of Copenhagen, Rigshospitalet, Denmark

Key words

- systematic literature review
- atherosclerotic plaque
- ultrasound
- elastography
- strain

Abstract

Atherosclerosis is a widespread disease that accounts for nearly 3-quarters of deaths due to cardiovascular disease. Ultrasound elastography might be able to reliably identify characteristics associated with vulnerable plaques. There is a need for the evaluation of elastography and its ability to distinguish between vulnerable and stable plaques. The aim of this paper is to provide an overview of the literature on vascular elastography. A systematic search of the available literature for studies using elastography for assessing atherosclerotic plaques was conducted using the MEDLINE, Embase, Cochrane Library and Web of Science databases. A standardized

template was used to extract relevant data following the PRISMA 2009 checklist. 20 articles were included in this paper. The studies were heterogeneous. All studies reported that elastography was a feasible technique and provided additional information compared to B-mode ultrasound alone. Most studies reported higher strain values for vulnerable plaques. Ultrasound elastography has potential as a clinical tool in the assessment of atherosclerotic plaques. Elastography is able to distinguish between different plaque types, but there is considerable methodological variation between studies. There is a need for larger studies in a clinical setting to determine the full potential of elastography.

received 20.05.2016
accepted 05.08.2016

Bibliography

DOI <http://dx.doi.org/10.1055/s-0042-115564>
Published online:
October 13, 2016
Ultrasound International Open
2016; 2: E106–E112
© Georg Thieme Verlag KG
Stuttgart · New York
ISSN 2199-7152

Correspondence

Badar Mahmood, Medical student

Department of Radiology
Rigshospitalet
Blegdamsvej 9
2100 København
Denmark
Tel.: +45/263/93 799
badar@me.com

Introduction

Atherosclerosis is a slowly progressive disease that accounts for nearly 3-quarters of deaths due to cardiovascular disease. Cardiovascular disease is the leading cause of mortality worldwide [1]. Despite the clinical significance of atherosclerotic plaques, it is difficult to assess the risk of plaque rupture and thrombosis with current imaging modalities [2]. Recently plaque morphology, histology and mechanical properties have gained interest as potential important factors for discerning vulnerable from stable plaques. Evidence in the published literature suggests that ischemic events are more frequent in patients with plaques containing a large lipid core than stiffer calcified and fibrous plaques [3, 4].

Ultrasound is commonly used for both the evaluation of plaque morphology and the evaluation of the hemodynamic consequences of plaques in blood vessels. Ultrasound elastography evaluates tissue stiffness. Several ultrasound elastography techniques are available [5]. 2 techniques, strain and shear wave elastography, have been applied in the assessment of vascular plaques [6, 7]. In

strain elastography mechanical stress is applied manually by compressing the skin with the transducer or by physiological motion, i.e., arterial pulsation. The tissue strain is measured relative to the surrounding tissue and translated into a color-coded map, which may be shown as an overlay on the B-mode image. The method is qualitative, but semi-quantitative measurements may be made where the strain in a region of interest is calculated relative to the surrounding tissue. Shear wave elastography is a quantitative method in which tissue displacement is caused by an ultrasound push pulse. Tissue displacement is measured by measuring the speed of shear waves occurring perpendicularly to the ultrasound push pulse [6]. Strain elastography is well evaluated in breast tumors, thyroid nodules and lymph nodes, whereas shear wave elastography is well evaluated in liver fibrosis assessment and breast tumors [8]. Vascular elastography may be performed endovascularly or noninvasively. Elastography images or measurements may be used to differentiate between vulnerable and stable plaques. Elastography could potentially play an important role in identifying vulnerable

License terms



plaques and help gain insight into the pathophysiology of acute coronary syndrome or stroke and identify high-risk patients. The aim of this paper was to provide a systematic overview of the literature on the use of vascular ultrasound elastography.

Methods

Search strategy and selection

A literature search was performed in MEDLINE, EMBASE, Web of Science and the Cochrane Library databases. We use MEDLINE here as an example of the systematic searches. In Medline the following search terms were applied: the MeSH terms used were “elasticity imaging techniques” AND “plaque, atherosclerotic”. To ensure the inclusion of studies not yet indexed with MeSH terms, a free text search was performed using the terms “acoustic radiation force imaging” OR “real-time tissue elastography” OR “supersonic” OR “Fibroscan” OR “elasticity imaging techniques” AND “atherosclerosis” AND “plaque”. 2 authors reviewed all titles and abstracts (B. Mahmood and C. Ewertsen). Eligible papers were read by 2 of 3 authors (B. Mahmood, J. Carlsen and C. Ewertsen). Only original research articles in English concerning ultrasound elastography of atherosclerotic plaques in humans, animals or phantoms were included. Consensus was obtained through discussion. Furthermore, all reference lists of included articles were hand-searched for further references. The following data were extracted from the included manuscripts: a) type of study, b) elastography method, c) study population, d) number of subjects, e) method of comparison, f) artery examined, g) quantification method, h) outcome of study and i) any additional relevant information about the studies. The following exclusion criteria were used: editorials, reviews, case reports investigating 5 subjects or less, letters to the editor, conference abstracts and articles on mathematical optimization of elastography. The PRISMA 2009 checklist was used as a guideline for reporting the findings for each article [9]. Before the search process was initiated, the aim of the review was agreed upon. The searches were performed on April 9, 2016.

Results

Selection of studies and overview

The initial search yielded 219 citations. Based on the title, 182 articles were excluded (including duplicates) and another 9 articles were excluded after review of the abstract. **Fig. 1** shows a flowchart of the systematic review process. 28 articles were retrieved for full text reading, 20 studies were eligible and therefore included in the final analysis. 4 studies investigated elastography in either humans or animals in addition to phantom studies and are therefore presented in more than one subgroup in **Table 1**. A predefined standardized template for data extraction was employed for all studies. The elastography methods employed in all of the included studies are presented and described in **Table 2**.

In 12 of the studies data was acquired from human subjects. 4 studies included data from animals: 3 were performed on pigs and one study was conducted on rabbits. The remaining 4 articles described data from either phantoms only or a combination of phantoms and humans or animals. No cut-off values for measured strain in plaques were described in the included studies to differentiate between vulnerable and stable plaques.

Noninvasive elastography

To evaluate plaque stiffness, a noninvasive approach was employed in 10 of the included articles in human subjects [10–19]. 8 studies investigated elastography in humans only and 2 studies investigated elastography in both humans and phantoms [13,19]. 8 studies used strain elastography and 2 studies used shear wave elastography [12,14] to assess plaques stiffness. In 8 studies strain or shear wave values were obtained from atherosclerotic plaques in the carotid, whereas 2 studies assessed strain values from the femoral and/or popliteal artery [13,18]. All studies reported that noninvasive elastography was able to distinguish between different types of plaques, however with different methods of reference. [6] studies describe a positive correlation between tissue strain and plaque vulnerability [12,14,15,17–19]. Only one study found that mean strain values were significantly lower in vulnerable plaques implying that vulnerable plaques were less stiff than non-vulnerable plaques [11]. This study estimated mean strain values for the entire plaques while other studies evaluated plaques based on smaller regions of interest and maximal measured strain values. 2 strain elastography studies and one shear wave elastography study compared elastography findings with histology and concluded that elastography could differentiate between plaques with fibrous tissue, lipid core, intra-plaque hemorrhage and foam cells [12,15,19]. 2 studies investigated the relationship between the patient’s neurological status and plaque strain and found that patients with focal neurological symptoms had plaques with higher strain values, which represented soft plaques [17,20]. The above mentioned studies described plaques with 2 parameters: high strain spots and/or average strain values for the entire plaques. Only plaques with focal high strain spot values were associated with diminished cognitive function. 2 studies compared their strain investigation with B-mode images and found that strain values provided additional information compared to B-mode only [10,13].

Endovascular elastography

In 2 studies endovascular elastography, a method based on strain elastography, was used to evaluate atherosclerotic plaques in coronary arteries in-vivo in humans [21–23]. Endovascular elastography was able to distinguish between plaques and their composition in both studies, although these studies were quite heterogeneous. In the first study the outcome was compared to histology [21], and in the second it was compared to B-mode images [23]. Only strain elastography has been used so far in endovascular elastography studies. Lower mean strain values were reported for vulnerable plaques compared to stable plaques. No difference in mean strain values was reported between normal artery intima and calcified plaques. One study evaluated inflammation measured by histologic presence of macrophages and reported higher strain values for plaques with inflammation compared with plaques without inflammation [21]. In one of the studies lower strain values were reported after atherectomy was performed as an intervention [21].

Elastography in animals

Elastography was evaluated in animals in 5 studies [5,22,24–26]. As presented in **Table 1**, 3 studies investigated vascular elastography in animals only, while 2 studies assessed elastography in both animals and phantoms [25,26], the latter 2 are therefore presented twice in **Table 1**. All 5 studies used an invasive approach to assess strain values in animals. 4 studies

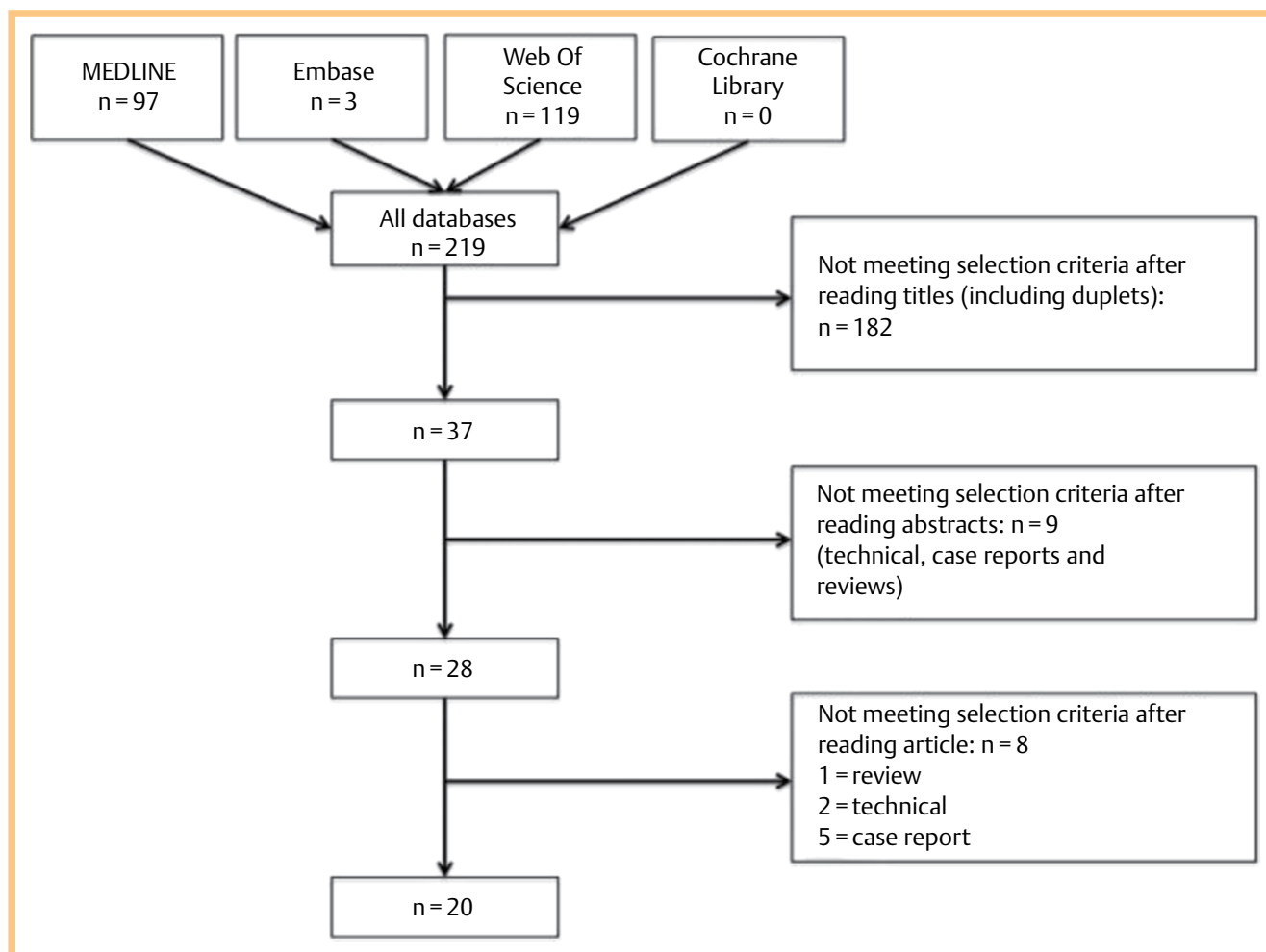


Fig. 1 Flowchart of the systematic review process with number of articles included and excluded.

were performed in pigs and one in rabbits [24]. One study investigated plaques in the iliac and/or femoral artery [22], while the other studies were performed on the carotid artery; abdominal aorta; renal and coronary arteries, respectively [5,24–26]. Histology was the method of comparison in all of the animal studies. The histological parameters evaluated for plaque vulnerability differed between the 4 studies, but all of them reported higher strain values in vulnerable plaques.

Elastography in phantoms and excised vessels

7 studies were performed in phantoms or in excised vessels from either humans or animals [13,14,19,25–28]. 2 of the 7 studies had an additional in-vivo data collection from animals [25,26], and similarly 2 phantom studies investigated elastography in humans in-vivo [13,19]. Most studies performed in phantoms and excised vessels were performed to evaluate new mathematical models for calculating strain. These studies were heterogeneous, but all found that high strain values were associated with vulnerable plaques. Excised human vessels were examined in 3 studies, where strain values were compared to histology [19,27,28]. 2 of these studies described an association between vulnerable plaques and high strain values [27,28], and one study reported that noninvasive elastography was feasible on the carotid arteries [19]. In 2 studies strain methods were evaluated in phantoms and followed by validation in pigs

[25,26]. Both studies found that elevated strain was correlated to histologically proven vulnerable plaques.

Discussion



All 20 studies included in this review reported that ultrasound elastography was able to distinguish between different types of heterogeneous atherosclerotic plaques and that additional information was obtained compared to B-mode ultrasound only. Both endovascular elastography and noninvasive elastography methods were used. Both in-vivo and ex-vivo endovascular elastography studies showed that increased strain is associated with histologically vulnerable plaques [21,23,27]. No cut-off values for distinguishing between vulnerable and stable atherosclerotic plaques were suggested for future implementation. To our knowledge this is the first systematic review to evaluate the available literature on ultrasound elastography studies assessing atherosclerotic plaques.

Noninvasive methods for evaluating atherosclerotic stenosis and the risk for stroke include duplex ultrasonography which is recommended as the first choice by North American guidelines [29–31]. The method uses flow velocity-based estimation for measuring the severity of stenosis, but does not indicate whether a particular plaque may be prone to rupture, and does not directly measure the diameter of the artery. Among the pitfalls

Table 1 Characteristics of included studies.

Author, year and country	Type of study; study population (no. of subjects)	Elastography method; quantification	Method of comparison	Artery	Conclusion
Dahl et al., 2009, USA [10]	Noninvasive; human (23)	ARFI* ; quantitative	B-mode	Carotid	ARFI was able to discriminate between different plaque areas in heterogeneous plaques.
Naim et al., 2013, Canada [11]	Noninvasive; human (31)	Strain elastography; semi-quantitative	MRI	Carotid	The strain was significantly lower in plaques containing a lipid core compared with those without.
Garrard et al., 2015, UK [12]	Noninvasive; human (25)	Shear wave; quantitative	Histology	Carotid	The mean Young Modulus of vulnerable plaques was significantly lower than in stable plaques.
Dumont et al., 2009, USA [13]	Noninvasive and ex-vivo; human and phantom (18)	ARFI* ; quantitative	B-mode	Popliteal	The investigated method can be used in deep vessels such as the popliteal.
Ramnarine et al., 2014, UK [20]	Noninvasive; human (81)	Shear wave; quantitative	Neurological symptoms	Carotid	The mean plaque Young Modulus of symptomatic patients was significantly lower than in asymptomatic patients.
Liu et al., 2014, China [15]	Noninvasive; human (19)	Strain elastography; qualitative (visual score)	Histology	Carotid	Elastography was able to assess plaque stiffness when compared to histology. May serve as an adjunct to B-mode.
Okimoto et al., 2006, Japan [16]	Noninvasive; human (242)	ARFI* ; quantitative	Cardiovascular risk factors	Carotid	Carotid artery elasticity was associated with increasing number of risk factors.
Wang et al., 2014, USA [17]	Noninvasive; human (24)	Strain elastography; semi-quantitative	Cognitive performance	Carotid	There is an association between axial and lateral strain and cognitive impairment.
Takimura et al., 2014, Japan [18]	Noninvasive; human (65)	Strain elastography; semi-quantitative	Endovascular evaluation	Femoral and popliteal	Elastography is able to detect the hardness of plaques.
Ribbers et al., 2006, The Netherlands [19]	Noninvasive and ex-vivo; human and phantom (12)	Strain elastography; semi-quantitative	Histology	Carotid	2D elastography is feasible on carotid artery plaques.
de Korte et al., 2002, The Netherlands [23]	Invasive; human (12)	Strain elastography; semi-quantitative	Echogram	Coronary	Significantly higher strain values in non-calcified than in calcified plaques.
Keshavarz-Motamed et al., 2014, Canada [21]	Invasive; human (12)	Strain elastography; semi-quantitative	Histology	Coronary	Significantly lower strain values in arteries after atherectomy.
de Korte et al., 2002, The Netherlands [22]	Animal; pigs (6)	Strain elastography; semi-quantitative	Histology	Iliac and femoral	There are higher average strain values for fatty compared with fibrous plaques.
Zhang et al., 2010, China [5]	Animal; pigs (7)	Strain elastography; semi-quantitative	Histology	Renal arteries	The extent of macrophage infiltration is correlated positively with strain values.
Hu et al., 2011, China [24]	Animal; rabbits (40)	Strain elastography; semi-quantitative	Histology	Abdominal aorta	There are significantly higher strain values for fatty plaques compared with fibrous or fibro-fatty plaques.
Liang et al., 2009, USA [25]	Ex-vivo and in-vivo; pigs and phantom (3)	Strain elastography; qualitative	Histology	Coronary	Endovascular elastography is able to identify some vulnerable plaque features.
Majdouni et al., 2013, Canada [26]	Ex-vivo and in-vivo; pigs and phantom (8)	Strain elastography; quantitative and qualitative	Histology	Both carotid	Strain values are positively correlated with plaque condition defined by American Heart Association.
Schaar et al., 2003, The Netherlands [27]	Ex-vivo; human (24)	Strain elastography; semi-quantitative	Histology	Coronary	Plaques assessed as vulnerable on elastography had a thinner cap.
de Korte et al., 2000, The Netherlands [28]	Ex-vivo, invasive; human (13)	Strain elastography; semi-quantitative	Histology	Femoral and coronary	Different strain values were reported for fibrous, fibro-fatty and fatty plaques.
Majdouni et al., 2013, Canada [26]	Ex-vivo and in-vivo, invasive; phantom and pigs (8)	Strain elastography; quantitative and qualitative	Histology	Both carotid	Strain values are positively correlated with plaque condition defined by American Heart Association.
Liang et al., 2009, USA [25]	Ex-vivo and in-vivo; phantom and pigs (3)	Strain elastography; qualitative	Histology	Coronary	Endovascular elastography is able to identify some vulnerable plaque features.
Ribbers et al., 2006, The Netherlands [19]	Ex-vivo; phantom and human (12)	Strain elastography; semi-quantitative	Histology	Carotid	2D elastography is feasible on carotid artery plaques.
Ramnarine et al., 2014, UK [14]	Ex-vivo; phantom	Shear wave; quantitative	Validation in phantom	Popliteal	SSWE can quantify YM in carotid artery phantoms.
Dumont et al., 2009, USA [13]	Noninvasive; phantom and human (18)	ARFI* ; quantitative	B-mode		The investigated method can be used in deep vessels such as the popliteal artery.

* Early non-commercial ARFI method that uses an ultrasonic push-pulse for displacement and measures tissue displacement by speckle tracking

§ Studies that evaluate strain values in both phantoms and other subjects. They are therefore presented more than once in respective subgroups

Table 2 The elastography methods used in the included studies.

	Strain elastography	Acoustic radiation force impulse imaging [§]	Shear wave elastography [#]
Displacement/stimulation of tissue obtained through	Manual compression using US transducer or physiological movement, i. e., pulsation	Focused radiation force impulse	Focused radiation force impulse
Property measured/displayed	Tissue strain [*]	Tissue displacement	Shear wave speed [§]
Quantitative or qualitative data	Qualitative (semi-quantification may be applied)	Qualitative (semi-quantification may be applied)	Quantitative
Real-time/still frames	Real-time	Still frames	Real-time

§ The acoustic radiation force impulse method used in some of the included studies and described here is different from the method usually referred to as ARFI, which is a method used for point measurements of shear wave speed by placing an ROI on the B-mode image

The shear wave elastography method described here is the trademark of Supersonic Imaging (Aix-en-Provence, France), which uses a plane wave technique, which allows shear wave elastograms to cover the entire B-mode image and be refreshed at the same frame rate as the B-mode image

* Tissue strain is inversely proportional to the Young's modulus (E), which is a measure of tissue elasticity, following the equation: $\gamma = \text{stress}/\text{strain}$, where the stress is the force applied to compress the tissue. Tissue strain is unitless

§ The Young's modulus (E) is proportional to the square of the shear-wave speed (s_c): $E = 3 \times \rho \times s_c^2$, where ρ is the tissue density

of the duplex ultrasonography estimation are gender differences, high carotid bifurcation, obesity and in situ carotid stents. Magnetic resonance imaging is another noninvasive method, which has high diagnostic accuracy for fatty vulnerable plaques [32–34], but is very expensive and time-consuming for widespread clinical use [35,36]. It has been suggested that further risk stratification of atherosclerotic plaques may improve patient outcome. Ultrasound elastography may help in this risk stratification. Most noninvasive studies of ultrasound elastography have investigated strain elastography in the carotid arteries and reported higher strain values or described vulnerable plaques as soft [12,14,15]. One study reported lower strain values for vulnerable plaques utilizing a non-commercially available strain measuring method [11]. This finding is in contradiction to other findings both in endovascular elastography and noninvasive strain measurements [17,23]. The reason for these contradictory findings may be a lack of consensus as to how to evaluate strain. Most studies define a plaque as vulnerable if localized high strain spots are found. One of the included studies reported mean values over entire plaques and contrary to other studies failed to find an association between high strain values and vulnerable plaques. This was the only study to use MRI as the method of reference [11].

Endovascular elastography studies in-vivo and ex-vivo have demonstrated the ability to differentiate between fibrous plaques and fatty plaque components [23,28]. Furthermore, the ability to detect vulnerable areas in heterogeneous plaques was demonstrated, i.e., fatty regions with an increased macrophage content were located on the basis of high strain values [21]. One study provided further evidence by demonstrating lower strain values in the coronary arteries after an atherectomy was performed [21]. Although endovascular elastography studies showed promise in the assessment of plaques, they were limited by the small number of subjects and this technique still needs to be validated in a larger prospective clinical setting. One central problem with endovascular elastography is the acquisition of data in a pulsating artery located in a contracting heart. There is a risk of catheter movement and thereby a mismatch between the data acquired at the low and high pressure of a cardiac cycle. This can partly be avoided by systematically obtaining values at a specific time point in the cardiac cycle. Other intravascular modalities primarily describing morphological and histological qualities of plaques such as optical coherence tomography and ultrasound-based virtual histology have been developed [37,38], but they also lack evaluation in larger clinical studies [39–43].

All animal studies describe an association between high strain values and vulnerable plaques. The studies on elastography in animals are limited by the low number of investigated subjects ranging from 6 pigs to 40 rabbits [22,24] and were performed to evaluate mathematical models for elastography. Another limitation of these studies is the phenotype of the plaques, which is homogeneous contrary to the heterogeneous plaques seen in patients due to very controlled diets and environmental settings for animals. Most of the studies only reported strain values for early fatty lesions [22] and in one case no fatty lesion was observed which can be partly explained by the short timeframe of the study [5].

Ex-vivo studies with excised vessels indicate that elastography is a reliable method for the estimation of plaque morphology and thereby risk [27,28]. Currently available elastography methods have been proven feasible in phantom studies [13,14,19]. However, techniques can still be optimized and more consistent reporting of the reliability of the methods used is desirable. Additional information could be gained by larger prospective controlled trials with endpoints such as mortality and morbidity for both endovascular and noninvasive modalities. Studies with a longer follow-up time could add information on the development of vulnerable plaques and their strain values or shear wave speed. Recent papers bring light to the relationship between strain in plaques and the stability of plaques for noninvasive elastography [12]. However, these strain values have not been correlated to patient outcome. Therefore, there is a need for prospective studies describing the relationship between strain values and patient outcome in a clinical setting, and noninvasive elastography would be the best way to start, as it does cause any harm to patients. Moreover, the technology is easily accessible in most hospitals with high-end equipment. Once the technology has been validated noninvasively, further endovascular studies would be appropriate. So far endovascular studies have been limited by the small number of subjects and few research groups. Future endovascular studies would require a larger cohort to provide additional information in the field. Interventional endovascular studies describing elasticity in arteries before and after an intervention would be welcome. To date, only one study has described this [21].

Limitations

Different issues limit the comparability of the present studies. Very few studies reported if any blinding was employed between investigators measuring strain and investigators defining plaques as vulnerable. In general, studies were heterogeneous

and the outcomes therefore differed [11,27]. There were no prospective intervention studies showing a better outcome if elastography was utilized in a clinical setting. No cut-off values for strain or shear wave elastography have been established and values may differ between different manufacturers of ultrasound equipment. Included patient groups differ between studies and the overall number of included patients is too low to evaluate the efficacy of elastography in a clinical setting.

Conclusion

Elastography is a feasible modality to distinguish between vulnerable and stable plaques in atherosclerosis. There is, however, a lack of larger prospective studies examining the efficacy of this technique in a clinical setting and the impact on mortality and morbidity. Current results show promise for this technique to be utilized in clinical studies evaluating the performance of new drugs for the reduction of plaque burden.

References

- 1 *GBD 2013*. Mortality and Causes of Death Collaborators. Global, regional, and national age-sex specific all-cause and cause-specific mortality for 240 causes of death, 1990–2013: a systematic analysis for the Global Burden of Disease Study 2013. *Lancet* 2015; 385: 117–171
- 2 *Behler RH, Nichols TC, Zhu H et al*. ARFI imaging for noninvasive material characterization of atherosclerosis. Part II: toward in vivo characterization. *Ultrasound Med Biol* 2009; 35: 278–295
- 3 *Nandalur KR, Baskurt E, Hagspiel KD et al*. Calcified carotid atherosclerotic plaque is associated less with ischemic symptoms than is non-calcified plaque on MDCT. *AJR Am J Roentgenol* 2005; 184: 295–298
- 4 *Gomez SM, Gomez CR, Hall IS*. Transcranial Doppler ultrasonographic assessment of intermittent light stimulation at different frequencies. *Stroke* 1990; 21: 1746–1748
- 5 *Zhang P-F, Su H-J, Zhang M et al*. Atherosclerotic plaque components characterization and macrophage infiltration identification by intravascular ultrasound elastography based on b-mode analysis: validation in vivo. *Int J Cardiovasc Imaging* 2011; 27: 39–49
- 6 *Bamber J, Cosgrove D, Dietrich CF et al*. EFSUMB guidelines and recommendations on the clinical use of ultrasound elastography. Part 1: Basic principles and technology. *Ultraschall in Med* 2013; 34: 169–184
- 7 *Cosgrove D, Piscaglia F, Bamber J et al*. EFSUMB guidelines and recommendations on the clinical use of ultrasound elastography. Part 2: Clinical applications. *Ultraschall in Med* 2013; 34: 238–253
- 8 *Garra BS*. Elastography. *Ultrasound* 2011; 3: 177–186
- 9 *Moher D, Liberati A, Tetzlaff J et al*. PRISMA Group. Preferred reporting items for systematic reviews and meta-analyses: the PRISMA statement. *Ann. Intern. Med.* 2009; 151: 264–294
- 10 *Dahl JJ, Dumont DM, Allen JD et al*. Acoustic radiation force impulse imaging for noninvasive characterization of carotid artery atherosclerotic plaques: a feasibility study. *Ultrasound Med Biol* 2009; 35: 707–716
- 11 *Naim C, Douziech M, Therasse E et al*. Vulnerable atherosclerotic carotid plaque evaluation by ultrasound, computed tomography angiography, and magnetic resonance imaging: An overview. *Canadian Association of Radiologists Journal* 2014; 65: 275–286
- 12 *Garrard JW, Ummur P, Nduwayo S et al*. Shear wave elastography may be superior to greyscale median for the identification of carotid plaque vulnerability: A comparison with histology. *Ultraschall in Med* 2015; 36: 386–390
- 13 *Dumont D, Dahl J, Miller E et al*. Lower-limb vascular imaging with acoustic radiation force elastography: demonstration of in vivo feasibility. *IEEE Trans Ultrason Ferroelectr Freq Control* 2009; 56: 931–944
- 14 *Ramnarine KV, Garrard JW, Dexter K et al*. Shear wave elastography assessment of carotid plaque stiffness: in vitro reproducibility study. *Ultrasound Med Biol* 2014; 40: 200–209
- 15 *Liu F, Yong Q, Zhang Q et al*. Real-time tissue elastography for the detection of vulnerable carotid plaques in patients undergoing endarterectomy: a pilot study. *Ultrasound Med Biol* 2015; 41: 705–712
- 16 *Okimoto H, Ishigaki Y, Koiwa Y et al*. A novel method for evaluating human carotid artery elasticity: possible detection of early stage atherosclerosis in subjects with type 2 diabetes. *Atherosclerosis* 2008; 196: 391–397
- 17 *Wang X, Jackson DC, Varghese T et al*. Correlation of cognitive function with ultrasound strain indices in carotid plaque. *Ultrasound Med Biol* 2014; 40: 78–89
- 18 *Takimura H, Hirano K, Muramatsu T et al*. Vascular elastography: a novel method to characterize occluded lower limb arteries prior to endovascular therapy. *J Endovasc Ther* 2014; 21: 654–661
- 19 *Ribbers H, Lopata RGP, Holewijn S et al*. Noninvasive two-dimensional strain imaging of arteries: validation in phantoms and preliminary experience in carotid arteries in vivo. *Ultrasound Med Biol* 2007; 33: 530–540
- 20 *Ramnarine KV, Garrard JW, Kanber B et al*. Shear wave elastography imaging of carotid plaques: feasible, reproducible and of clinical potential. *Cardiovasc Ultrasound* 2014; 12: 49
- 21 *Keshavarz-Motamed Z, Saijo Y, Majdoulina Y et al*. Coronary artery atherectomy reduces plaque shear strains: an endovascular elastography imaging study. *Atherosclerosis* 2014; 235: 140–149
- 22 *De Korte CL, Siervogel MJ, Mastik F et al*. Identification of atherosclerotic plaque components with intravascular ultrasound elastography in vivo: a Yucatan pig study. *Circulation* 2002; 105: 1627–1630
- 23 *de Korte CL, Carlier SG, Mastik F et al*. Morphological and mechanical information of coronary arteries obtained with intravascular elastography: feasibility study in vivo. *Eur. Heart J.* 2002; 23: 405–413
- 24 *Hu X-B, Zhang P-F, Su H-J et al*. Intravascular ultrasound area strain imaging used to characterize tissue components and assess vulnerability of atherosclerotic plaques in a rabbit model. *Ultrasound Med Biol* 2011; 37: 1579–1587
- 25 *Liang Y, Zhu H, Friedman MH*. The correspondence between coronary arterial wall strain and histology in a porcine model of atherosclerosis. *Phys Med Biol* 2009; 54: 5625–5641
- 26 *Majdoulina Y, Ohayon J, Keshavarz-Motamed Z et al*. Endovascular shear strain elastography for the detection and characterization of the severity of atherosclerotic plaques: in vitro validation and in vivo evaluation. *Ultrasound Med Biol* 2014; 40: 890–903
- 27 *Schaar JA, De Korte CL, Mastik F et al*. Characterizing vulnerable plaque features with intravascular elastography. *Circulation* 2003; 108: 2636–2641
- 28 *de Korte CL, Pasterkamp G, van der Steen AF et al*. Characterization of plaque components with intravascular ultrasound elastography in human femoral and coronary arteries in vitro. *Circulation* 2000; 102: 617–623
- 29 *Lorenz MW, Markus HS, Bots ML et al*. Prediction of clinical cardiovascular events with carotid intima-media thickness: a systematic review and meta-analysis. *Circulation* 2007; 115: 459–467
- 30 *Chambless LE, Folsom AR, Clegg LX et al*. Carotid wall thickness is predictive of incident clinical stroke: the Atherosclerosis Risk in Communities (ARIC) study. *Am J Epidemiol* 2000; 151: 478–487
- 31 *Brott TG, Halperin JL, Abbara S et al*. 2011; ASA/ACCF/AHA/AANN/AANS/ACR/ASNR/CNS/SAIP/SCAI/SIR/SNIS/SVM/SVS guideline on the management of patients with extracranial carotid and vertebral artery disease: executive summary. A report of the American College of Cardiology Foundation/American Heart Association Task Force on Practice Guidelines, and the American Stroke Association, American Association of Neuroscience Nurses, American Association of Neurological Surgeons, American College of Radiology, American Society of Neuroradiology, Congress of Neurological Surgeons, Society of Atherosclerosis Imaging and Prevention, Society for Cardiovascular Angiography and Interventions, Society of Interventional Radiology, Society of NeuroInterventional Surgery, Society for Vascular Medicine, and Society for Vascular Surgery. *Circulation* 2011; 124: 489–532
- 32 *Lovett JK, Redgrave JNE, Rothwell PM*. A critical appraisal of the performance, reporting, and interpretation of studies comparing carotid plaque imaging with histology. *Stroke* 2005; 36: 1091–1097
- 33 *Saam T, Ferguson MS, Yarnykh VL et al*. Quantitative evaluation of carotid plaque composition by in vivo MRI. *Arterioscler. Thromb Vasc Biol* 2005; 25: 234–239
- 34 *Kawahara I, Morikawa M, Honda M et al*. High-resolution magnetic resonance imaging using gadolinium-based contrast agent for atherosclerotic carotid plaque. *Surg Neurol* 2007; 68: 605–656
- 35 *Loree HM, Kamm RD, Stringfellow RG et al*. Effects of fibrous cap thickness on peak circumferential stress in model atherosclerotic vessels. *Circ. Res.* 1992; 71: 850–858

- 36 Ohayon J, Finet G, Gharib AM *et al.* Necrotic core thickness and positive arterial remodeling index: emergent biomechanical factors for evaluating the risk of plaque rupture. *Am. J. Physiol. Heart Circ. Physiol* 2008; 295: 717–727
- 37 Nair A, Margolis MP, Kuban BD *et al.* Automated coronary plaque characterisation with intravascular ultrasound backscatter: ex vivo validation. *Euro Intervention* 2007; 3: 113–120
- 38 Nair A, Kuban BD, Tuzcu EM *et al.* Coronary plaque classification with intravascular ultrasound radiofrequency data analysis. *Circulation* 2002; 106: 2200–2206
- 39 Frutkin AD, Mehta SK, McCrary JR *et al.* Limitations to the use of virtual histology-intravascular ultrasound to detect vulnerable plaque. *Eur Heart J* 2007; 28: 1783–1784
- 40 Thim T, Hagensen MK, Wallace-Bradley D *et al.* Unreliable assessment of necrotic core by virtual histology intravascular ultrasound in porcine coronary artery disease. *Circ Cardiovasc Imaging* 2010; 3: 384–391
- 41 Brugaletta S, Gomez-Lara J, Garcia-Garcia HM *et al.* Analysis of 1 year virtual histology changes in coronary plaque located behind the struts of the everolimus eluting bioresorbable vascular scaffold. *Int J Cardiovasc Imaging* 2012; 28: 1307–1314
- 42 Guo J, Maehara A, Mintz GS *et al.* A virtual histology intravascular ultrasound analysis of coronary chronic total occlusions. *Catheter Cardiovasc Interv* 2013; 81: 464–470
- 43 Murray SW, Stables RH, Hart G *et al.* Defining the magnitude of measurement variability in the virtual histology analysis of acute coronary syndrome plaques. *Eur Heart J Cardiovasc Imaging* 2013; 14: 167–174