

# Nerve-End Capping Treatment with a Polyglycolic Acid Conduit for Rat Sciatic Neuroma: A Preliminary Report

Ema Onode, MD, PhD<sup>1</sup> Takuya Uemura, MD, PhD<sup>1,2</sup> Shunpei Hama, MD<sup>1</sup> Takuya Yokoi, MD, PhD<sup>1,3</sup>  
Mitsuhiro Okada, MD, PhD<sup>1</sup> Kiyohito Takamatsu, MD, PhD<sup>1,4</sup> Hiroaki Nakamura, MD, PhD<sup>1</sup>

<sup>1</sup>Department of Orthopaedic Surgery, Osaka City University Graduate School of Medicine, Osaka, Japan

<sup>2</sup>Department of Orthopaedic Surgery, Osaka General Hospital of West Japan Railway Company, Osaka, Japan

<sup>3</sup>Department of Orthopaedic Surgery, Seikeikai Hospital, Osaka, Japan

<sup>4</sup>Department of Orthopaedic Surgery, Yodogawa Christian Hospital, Osaka, Japan

Address for correspondence Takuya Uemura, MD, PhD, Department of Orthopaedic Surgery, Osaka General Hospital of West Japan Railway Company, 1-2-22 Matsuzakicho, Abeno-ku, Osaka, 545-0053 Japan (e-mail: t-uemura@med.osaka-cu.ac.jp).

J Reconstr Microsurg 2022;38:711–720.

## Abstract

**Background** The treatment of painful neuroma remains challenging. Recently, a nerve-end capping technique using a bioabsorbable nerve conduit was newly introduced to treat amputation neuroma. A collagen-coated polyglycolic acid (PGA) conduit has been commercially available for the reconstruction of peripheral nerve defects, yielding successful clinical outcomes. However, no experimental research has been conducted using this PGA nerve conduit as capping device for treating amputation neuroma. The purpose of this study was to investigate nerve-end capping treatment with the PGA conduit in the rat sciatic nerve amputation model, focusing on histological scar formation and neuroinflammation.

**Methods** Forty-seven rats were divided into two groups: no capping (transected nerve stump without capping;  $n = 25$ ) and capping (nerve-end capping with collagen-coated PGA nerve conduit;  $n = 22$ ). Twelve weeks after sciatic neurectomy, neuropathic pain was evaluated using the autotomy score. Stump neuromas were histologically evaluated for perineural scar and neuroinflammation.

**Results** While autotomy scores gradually exacerbated in both groups, they were consistently lower in the capping group at 4, 8, and 12 weeks postprocedure. Twelve weeks after surgery, the transected nerve stumps in the no-capping group had formed macroscopic bulbous neuromas strongly adhering to surrounding tissues, whereas they remained wrapped with the PGA nerve conduits loosely adhering to surrounding tissues in the capping group. Histologically, distal axonal fibers were expanded radially and formed neuromas in the no-capping group, while they were terminated within the PGA conduit in the capping group. Perineural scars and neuroinflammation were widely found surrounding the randomly sprouting nerve end in the no-capping group. In capped counterparts, scars and inflammation were limited to closely around the terminated nerve end.

## Keywords

- ▶ nerve conduit
- ▶ pain
- ▶ peripheral nerve

received  
May 26, 2021  
accepted after revision  
January 30, 2022  
published online  
March 10, 2022

© 2022, Thieme. All rights reserved.  
Thieme Medical Publishers, Inc.,  
333 Seventh Avenue, 18th Floor,  
New York, NY 10001, USA

DOI <https://doi.org/10.1055/s-0042-1757208>.  
ISSN 0743-684X.

**Conclusion** Nerve-end capping with a collagen-coated PGA conduit after rat sciatic neurectomy might prevent neuroma formation by suppressing perineural scar formation and neuroinflammation around the nerve stump, potentially relieving neuropathic pain.

Amputation neuroma often induces neuropathic pain, interfering with the patient's activity of daily life.<sup>1–3</sup> Many kinds of surgical treatments have been reported in this context, such as simple resection of the neuroma, translocation of the resected nerve stump into a bone cavity or a muscle belly, wrapping it with a vein, covering it with an adipofascial flap, and targeted muscle reinnervation (TMR).<sup>1,4–10</sup> However, given the paucity of superior standard surgical treatment for painful amputation neuroma and the fact that treating it is still challenging, there remains plenty of room for improvement.

Recently, several bioabsorbable artificial nerve conduits have been commercially available for the treatment of peripheral nerve defects as an alternative to autologous nerve grafting.<sup>11</sup> Moreover, the nerve-end capping technique using a bioabsorbable nerve conduit has been newly developed for treating painful amputation neuroma, both in basic animal studies and clinical cases; this method serves to protect a peripheral nerve stump from surrounding scarring to reduce the development of a symptomatic end-neuroma.<sup>12–23</sup> In Japan, a collagen-coated polyglycolic acid (PGA) conduit containing porous collagen fibers within the tube was introduced in 2013; it has been successfully used for the treatment of peripheral nerve defects ever since, producing clinical outcomes similar to autologous nerve grafting.<sup>24–27</sup> This PGA nerve conduit was also approved for regenerating peripheral nerves by the Food and Drug Administration in the United States in 2016.<sup>28</sup> However, no experimental data are available for using the conduit as a capping device for preventing and treating amputation neuroma.

In the current study, we preliminarily investigated whether nerve-end capping with a collagen-coated PGA nerve conduit could prevent formation of painful neuroma using the rat sciatic nerve amputation model. In the evaluation of this novel method, we focused on histological scar formation and neuroinflammation.

## Materials and Methods

Study approval was obtained from the Animal Care and Use Committee at Osaka City University Graduate School of Medicine. According to a previous systematic review, the rat sciatic nerve transection model was used to cause terminal neuromas and neuropathic pain in the current study.<sup>2,16</sup> Forty-seven male Sprague-Dawley rats (8 weeks old) weighing approximately 250 g were randomly allocated into two groups: (1) no-capping group, transected nerve stump without capping ( $n=25$ ); and (2) capping group, nerve-end capping with a collagen-coated PGA nerve con-

duit (Nerbridge; Toyobo Co., Ltd., Osaka, Japan;  $n=22$ ) (►Fig. 1). All rats were treated according to the Federal Animal Care Guidelines and had free access to rat chow and water. Twelve weeks after sciatic neurectomy, neuropathic pain was assessed using autotomy scoring based on the states of rat toenails. Stump neuromas were histologically evaluated with regard to perineural scar formation and neuroinflammation.

### Surgical Procedure

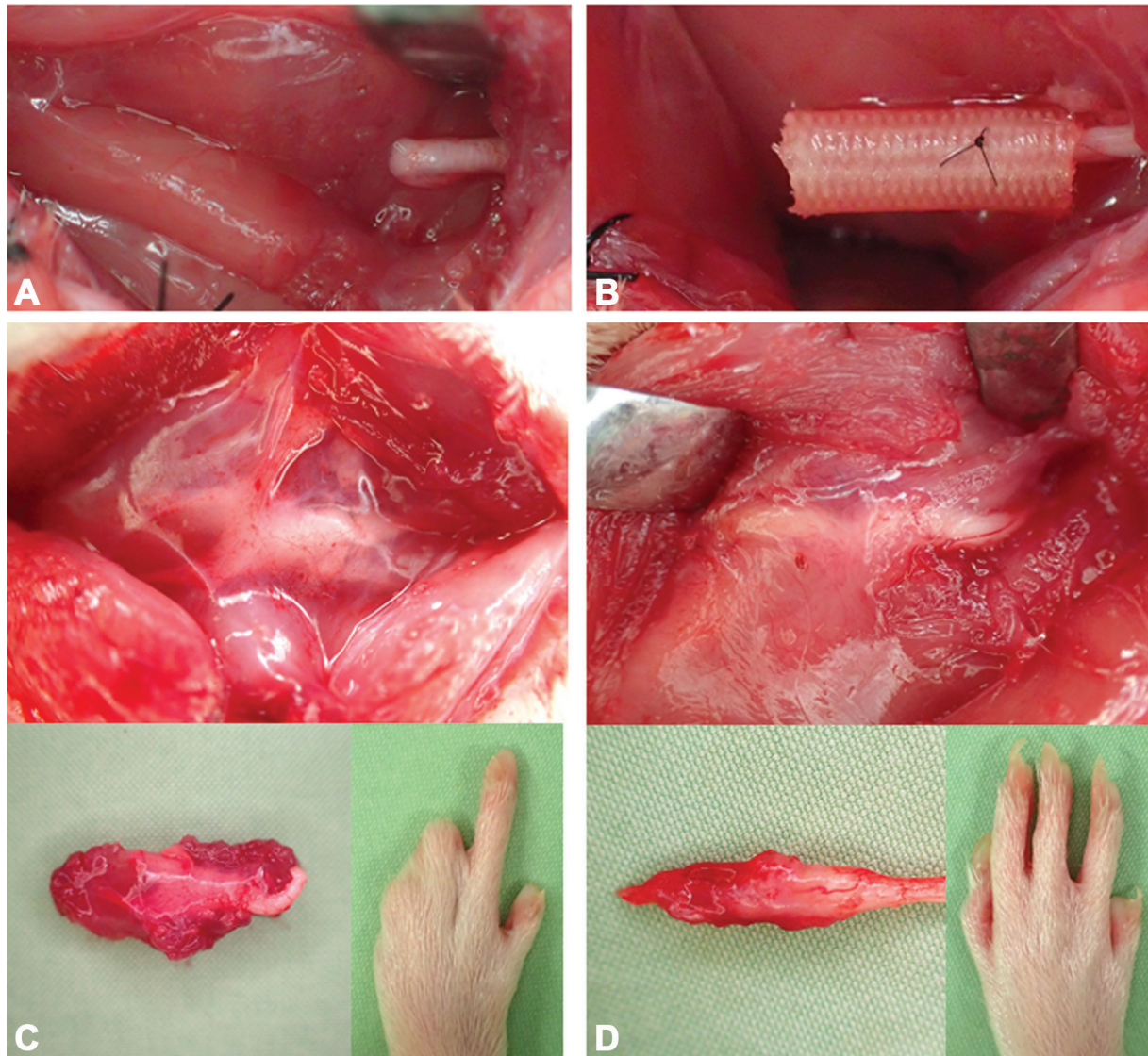
Rats were anesthetized by subcutaneous injection of 1 mL of ketamine (50 mg/mL) and 0.3 mL of 2% xylazine into the right dorsal back. Following exposure of the left sciatic nerve, which had a diameter of approximately 1.5 mm, it was sharply transected at the mid-thigh level; the transected nerve was removed to prevent nerve regeneration, resulting in a 15-mm nerve defect.<sup>16,18,20</sup> In the no-capping group, the proximal nerve stump was left without capping. In the capping group, the proximal nerve stump was pulled by 2 mm into the proximal end of the collagen-coated PGA nerve conduit, which had an inner diameter of 2 mm and a length of 8 mm, and sutured with 9–0 nylon sutures in a horizontal mattress pattern on the lumen wall under a microscope. The distal end of the PGA nerve conduit remained open. The muscle wound beds and skin incisions were closed with a 4–0 nylon suture in both groups.

### Evaluation of Neuropathic Pain: Autotomy Score

Autotomy is a behavior observed in animal models with neuropathic pain, such as allodynia, anesthesia dolorosa, or phantom limb pain (►Fig. 1).<sup>2,16,18,20,22,29</sup> The scoring scale devised by Wall et al was used to assess the severity of neuropathic pain in the current study.<sup>29</sup> Briefly, one point was assigned for the removal of one or more toenails, an additional point for each distal half digit attacked, and one more point for each proximal half digit attacked. Thus, if all digits were attacked, a maximum score of 11 was achieved. The autotomy scores of all rats in each group were recorded at 4, 8, and 12 weeks after surgery.

### Histological Evaluation of Neuroma

The proximal nerve stumps with and without capping with a PGA conduit, including their surrounding soft tissue, were harvested at 12 weeks after surgery (►Fig. 1). The specimens were immersed in 4% paraformaldehyde overnight and embedded in paraffin. Five-micrometer-thick longitudinal sections were stained with Masson's trichrome method to evaluate scarring surrounding stump neuromas.<sup>16,30</sup>



**Fig. 1** (A, B) Intraoperative gross findings of the transected sciatic proximal nerve stump with and without capping with the polyglycolic acid nerve conduit. (C, D) Gross appearances of the nerve stump and toes at 12 weeks after neurectomy in the no-capping (C) and capping (D) groups.

Furthermore, they were immunohistochemically stained using anti-neurofilament antibody (1:200, rabbit; Millipore, Temecula, CA) to evaluate axons, anti- $\alpha$  smooth muscle actin ( $\alpha$ -SMA) antibody (1:400, mouse; Sigma Aldrich, St. Louis, MO) to evaluate scarring surrounding the nerve stump, and anti-sigma-1 receptor (S1R) antibody (1:400, rabbit; Proteintech, Chicago, IL) to evaluate neuroinflammation of stump neuromas.<sup>16,18,19</sup> The neurofilament-,  $\alpha$ -SMA-, and S1R-positive areas were morphometrically analyzed using computer-assisted imaging as previously described.<sup>16</sup> Five random sections of two representative proximal nerve stumps in each group were photographed at 200 $\times$  magnification using an Olympus DP74 microscope (Olympus Corporation, Tokyo, Japan), and the percentages of areas positive for neurofilament,  $\alpha$ -SMA, and S1R were counted automati-

cally using the ImageJ software (National Institutes of Health, Bethesda, MD) and averaged.

#### Statistical Analysis

All data were expressed as mean and 95% confidence interval (CI), and statistically analyzed using the Student's *t*-test. A *p*-value of  $< 0.05$  denoted statistical significance. To determine an adequate sample size, a power analysis was performed for the autotomy score evaluation. At a two-tailed significance level of 5%, 40 rats (20 rats per group) were required to achieve 80% statistical power based on our pilot study. Assuming that approximately 20% of rats might die in the present study, the final sample size was found to be 50 rats (25 rats in each group). However, the final sample size decreased to 47 rats because 3 rats in the capping group died during surgery.

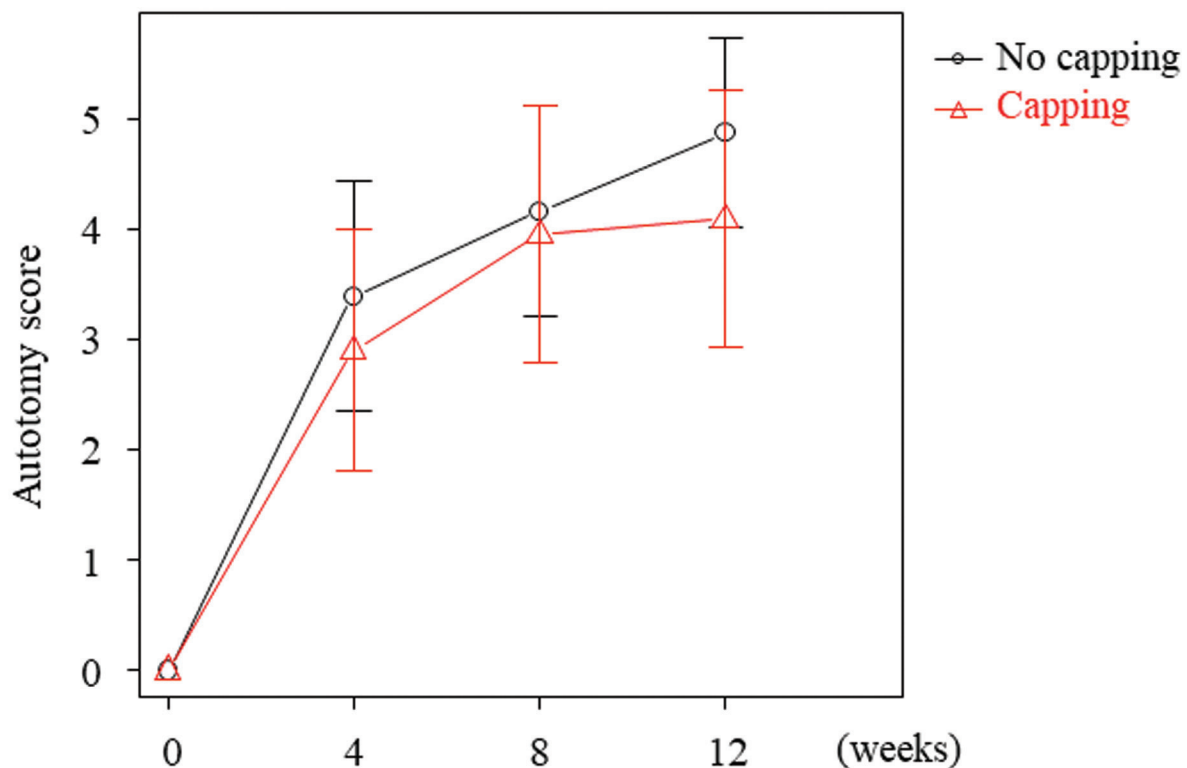
## Results

Autotomy behavior was observed on the left side of rats, on which the sciatic neurectomy with and without nerve-end capping was performed. At sacrifice 12 weeks postoperatively, the proximal nerve stumps in the no-capping group had formed macroscopic bulbous neuromas strongly adhering to surrounding tissues. In contrast, those in the capping group had remained wrapped with the PGA nerve conduits, which were macroscopically visible but mostly dissolved, loosely adhering to surrounding tissues (►Fig. 1).

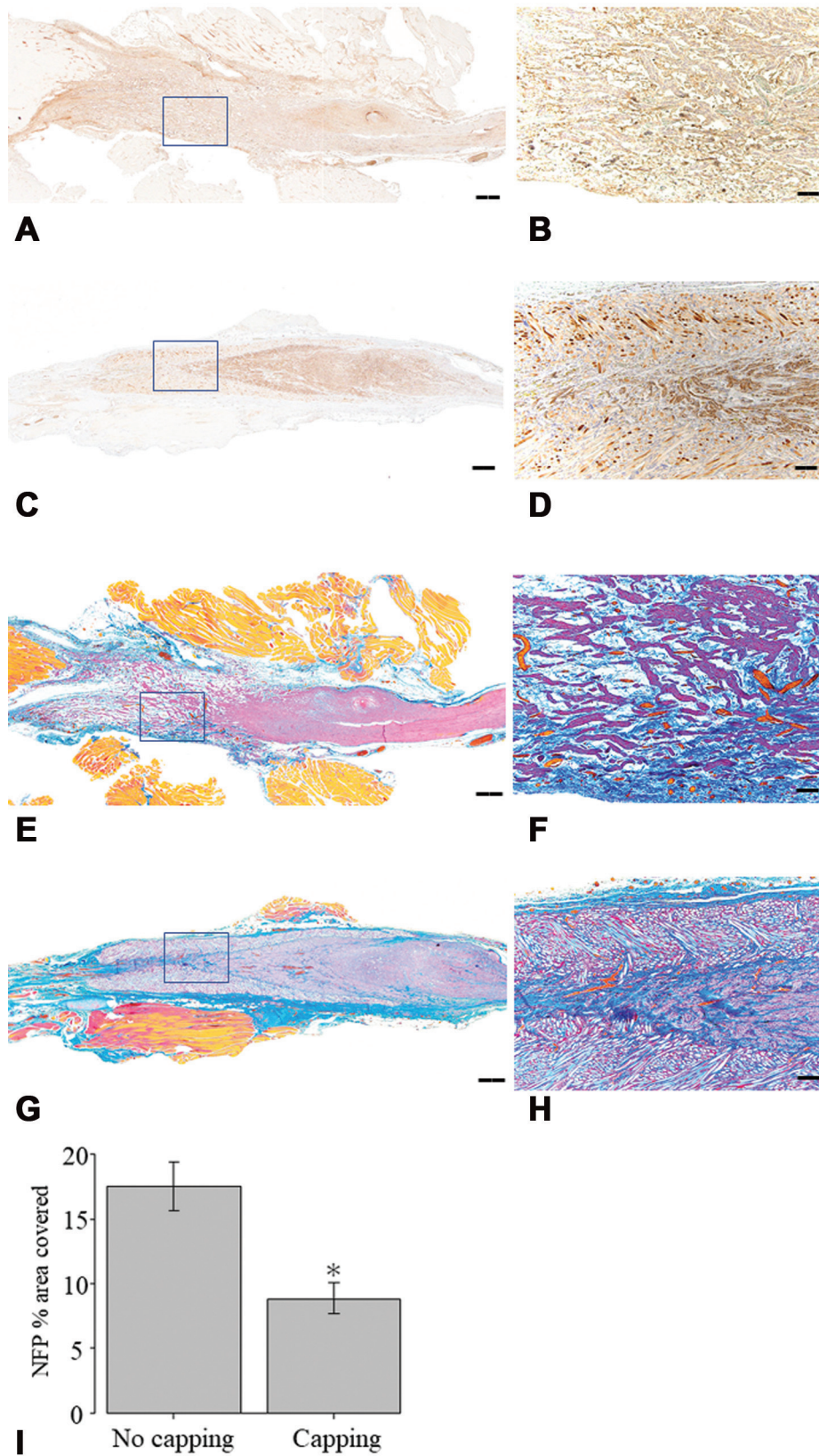
The representative gross appearances of the left toes after neurectomy with and without nerve-end capping, which were assessed using the autotomy score, are shown in ►Fig. 1. The autotomy scores of both groups gradually exacerbated at 4, 8, and 12 weeks after surgery. However, lower mean autotomy scores were consistently observed in the capping group compared with the non-capped counterparts, although there was no statistically significant difference between the two groups at all points (►Fig. 2). The mean autotomy scores at 12 weeks after surgery in the no-capping and capping groups were 4.92 (95% CI = 4.07–5.76) and 4.05 (95% CI = 2.90–5.19), respectively ( $p = 0.206$ ). These results suggest that nerve-end capping with the PGA nerve conduit after neurotomy could have a potential to relieve neuroma-induced neuropathic pain.

Histologically, distal axonal fibers, visualized by anti-neurofilament antibody, were expanded radially and formed a

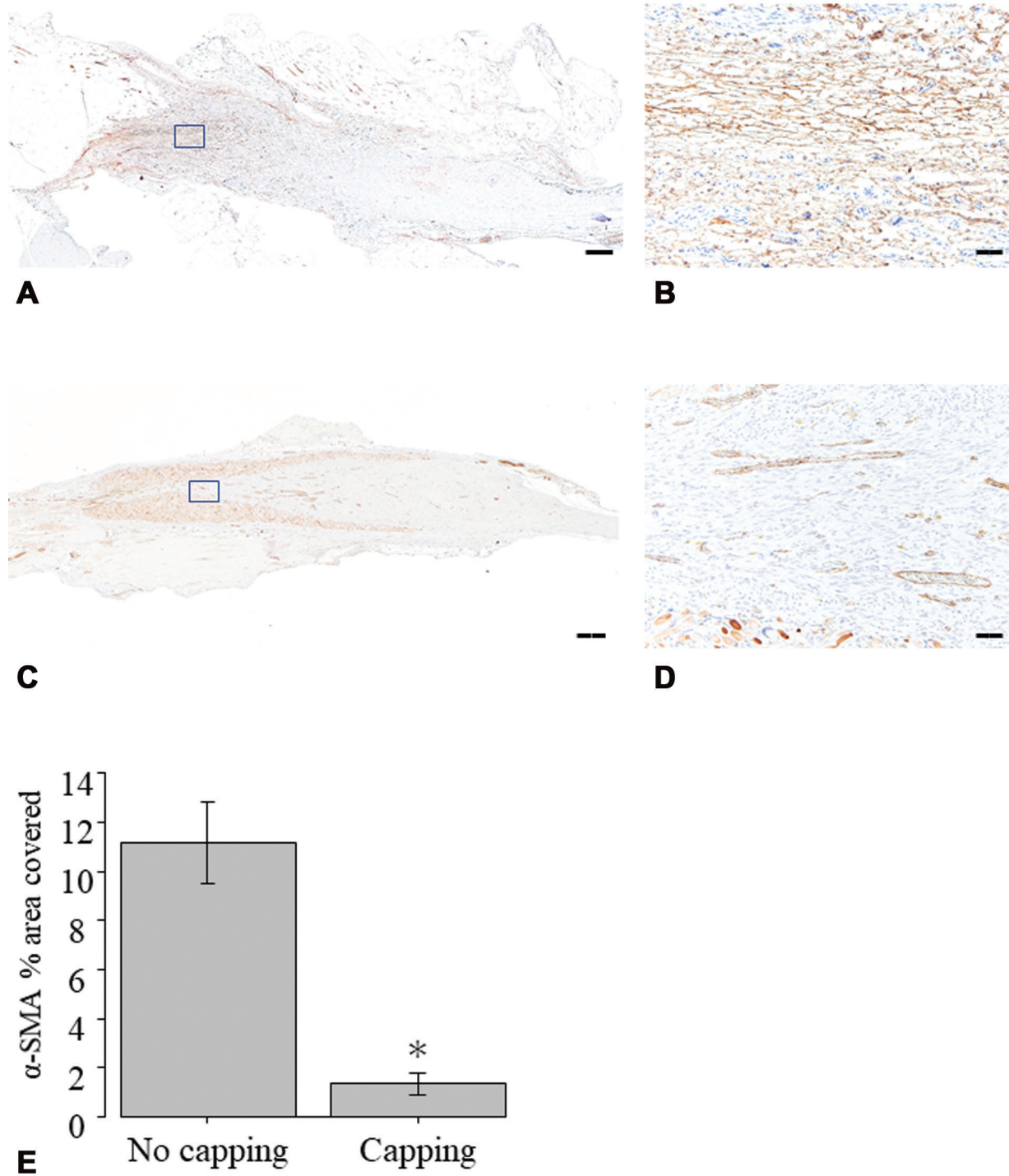
typical bulbous neuroma in the no-capping group. In the capping group, these fibers became thinner and terminated within the PGA nerve conduit (►Fig. 3). Morphometric analysis showed that the areas of distal axons that were positive for anti-neurofilament antibody were significantly lower in the capping group than in the no-capping group. Fibrotic adhesion, including collagenous fibers analyzed with Masson's trichrome staining, was widely found surrounding the randomly sprouting distal nerve end in the no-capping group. In contrast, fibrotic adhesion was limited to the immediate proximity of the tapering distal nerve end in the capping group. Notable perineural fibrotic scar formation, immunohistochemically visualized using anti- $\alpha$ -SMA antibody, was observed around the bulbous end-neuroma in the no-capping group, whereas minimal scar formation was observed around the terminated axonal fibers in the capping group. Morphometric analysis revealed significantly lower percentages of areas positive for anti- $\alpha$ -SMA antibody in the capping group compared with the no-capping group (►Fig. 4). Immunostaining demonstrated extensive expression of S1R in the nerve end in the no-capping group. However, in the capping group, only slight S1R expression was observed in the terminated axonal fibers (►Fig. 5); morphometric analysis showed that this difference was significant. Together, these histological results indicate that terminated axonal fibers were protected from perineural scar formation and neuroinflammation by nerve-end capping with the PGA nerve conduit.



**Fig. 2** Autotomy scores over time in the no-capping and capping groups. Data are expressed as mean and 95% confidence interval.



**Fig. 3** Histological images showing longitudinal sections of the proximal nerve stump immunohistochemically stained with anti-neurofilament antibody (A–D) and Masson’s trichrome method (E–H) at 12 weeks after neurectomy in the no-capping (A, B, E, and F) and capping (C, D, G, and H) groups. Regions marked with rectangles in A, C, E, and G are depicted at a higher magnification in B, D, F, and H, respectively. Scale bars = 500  $\mu$ m (A, C, E, and G) and 50  $\mu$ m (B, D, F, and H). (I) Quantitative analysis of the percentages of areas positive for neurofilament. \* $p < 0.05$  versus the no-capping group.

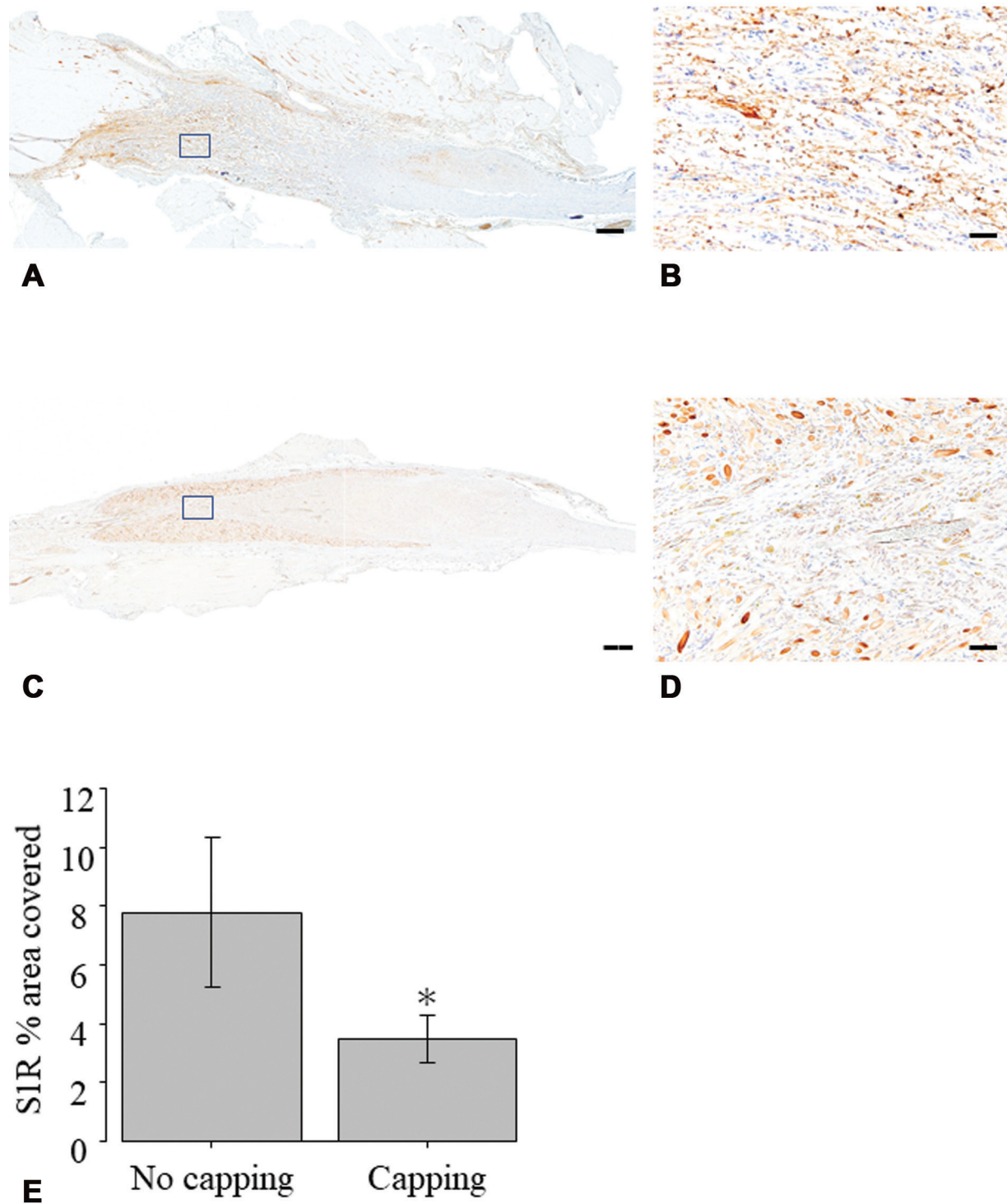


**Fig. 4** Histological images showing longitudinal sections of the proximal nerve stump immunohistochemically stained with anti- $\alpha$  smooth muscle actin ( $\alpha$ -SMA) antibody at 12 weeks after neurectomy in the no-capping (A and B) and capping (C and D) groups. Regions marked with rectangles in A and C are depicted at a higher magnification in B and D, respectively. Scale bars = 500  $\mu$ m (A and C) and 50  $\mu$ m (B and D). (E) Quantitative analysis of the percentages of areas positive for  $\alpha$ -SMA. Data are expressed as mean and 95% confidence interval. \* $p < 0.05$  versus the no-capping group.

## Discussion

In this study, we used the rat sciatic nerve amputation model preliminary to show that nerve-end capping with the collagen-coated PGA nerve conduit prevented the

development of stump neuromas, potentially relieving neuropathic pain. Perineural scar formation and neuroinflammation around the nerve stump was blocked by the PGA nerve conduit. A peripheral nerve-end capping device, NEUROCAP (Polyganics, Groningen, Netherland),



**Fig. 5** Histological images showing longitudinal sections of the proximal nerve stump immunohistochemically stained with anti-sigma-1 receptor (S1R) antibody at 12 weeks after neurectomy in the no-capping (A and B) and capping (C and D) groups. Regions marked with rectangles in A and C are depicted at a higher magnification in B and D, respectively. Scale bars = 500  $\mu$ m (A and C) and 50  $\mu$ m (B and D). (E) Quantitative analysis of the percentages of areas positive for S1R. Data are expressed as mean and 95% confidence interval. \* $p < 0.05$  versus the no-capping group.

has been clinically used for the treatment of painful amputation neuroma mainly in Europe since 2017.<sup>14,15,31,32</sup> However, no nerve-end capping device is commercially available in Asia, including Japan. Based on the results of the current study, the Nerbridge colla-

gen-coated PGA nerve conduit is a promising nerve-end capping device suitable to treat painful amputation neuroma.

Clinical reports on the treatment of painful neuromas utilizing the nerve-end capping technique with bioabsorbable

nerve conduits have been limited to two case series and four case reports.<sup>12–15</sup> Gould et al reported on 69 painful neuromas of the foot and ankle in 50 patients treated with simple excision of the neuroma and capping of the resected nerve stump with a collagen conduit, Neuroflex (Stryker, NJ).<sup>12</sup> de Vrij et al reported 10 patients having end-neuromas of 8 superficial radial nerves and 2 median nerves treated by the capping device, NEUROCAP, with 12 months of follow-up.<sup>31</sup> de Ru et al documented the treatment of three patients who underwent transection of the causative nerves, including two greater auricular nerves and a supraorbital nerve, followed by capping of their nerve ends with a NEUROCAP, which resulted in a marked reduction in pain scores.<sup>14</sup> George et al also demonstrated that nerve-end capping with NEUROCAP was effective in a case of digital end-neuroma.<sup>32</sup> Parker and Merced-O'Neil presented a 49-year-old female treated by capping of the intermetatarsal neuroma with a processed porcine extracellular matrix wrap, Axoguard (AxoGen, FL), the distal open end of which was sealed using MicroClip (Synovis, AL), and implanting it into the intrinsic muscle belly.<sup>13</sup> Our own work presented the first clinical case of a painful digital amputation neuroma of a 49-year-old female successfully treated by nerve-end capping with a collagen nerve conduit, Renreve (Nipro, Osaka, Japan).<sup>15</sup> Thus, there have been no reports of applying a collagen-coated PGA nerve conduit as a capping device to treat painful amputation neuroma. On the other hand, recently, TMR has offered a novel and potentially more effective therapy for the management of neuroma pain after limb amputation.<sup>10,33,34</sup> TMR surgically transfers amputated nerves to nearby motor nerves for prevention of neuroma and reinnervation of functional target muscles. However, TMR is utilized in extremity major amputations, mainly proximal to the elbow and rarely proximal to the metacarpophalangeal joints, while nerve-end capping technique is available in more distal parts, such as hands and fingers.

In contrast, numerous animal studies have revealed the effectiveness and pain relief mechanism of nerve-end capping with nerve conduits for the treatment of painful neuroma since Swanson et al have first introduced this technique in this context using a silicone tube.<sup>16–23,35</sup> The findings demonstrated that the expression of such pain-related factors as c-fos and substance P in the local neuroma or lumbar spinal cord were notably suppressed by nerve-end capping with a nerve conduit in the acute inflammation phase.<sup>20,23</sup> In the chronic inflammation phase, as examined in the current study, the elevation of S1R expression within the stump neuroma was sufficiently suppressed by nerve-end capping with a nerve conduit.<sup>16,36</sup> S1R is known as a molecular biomarker of nerve injury and neuroinflammation and is associated not only with acute pain but also with memorizing pain, which is responsible for the chronic and self-perpetuating nature of certain pain conditions.<sup>37–39</sup> In addition,  $\alpha$ -SMA is involved in painful neuroma as a direct cause of neuroma-associated pain or an indirect marker of local mechanical stimuli.<sup>1,18,21</sup> The expression of  $\alpha$ -SMA was observed to be higher in neuroma resulting from rat sciatic neurectomy and suppressed by nerve capping in previous reports.<sup>16,18</sup> Thus,

nerve-end capping using a nerve conduit protected the transected nerve stump from scarring, fibrotic adhesion, and neuroinflammation, thereby suppressing pain-related factors within the local neuroma or spinal cord.

The main limitation of the present study is that the follow-up period was 12 weeks after the operation. We think that the time point of 12 weeks seems reasonable, as our study has an advantage in terms of the longer follow-up of 12 weeks compared with other studies using animal models for experimental amputation neuroma with a follow-up duration of 4 or 8 weeks.<sup>2,17–20,22,23</sup> The distal axonal fibers were terminated within the PGA nerve conduits without forming neuromas at 12 weeks in the present study. We can hypothesize that the distal axonal fibers remain tapered without reforming the bulbous end-neuroma and comfortable in the surrounding soft tissue environment keeping minimal perineural scar adhesions after the nerve conduits are completely dissolved, because the nerve conduits are gradually and slowly absorbed at approximately 3 to 4 months without foreign body response and excessive inflammation reaction.<sup>28</sup> Moreover, it is important for pain relief to prevent perineural scar formation and neuroinflammation in the early stage, as some authors described that scar adhesion occurs earlier than 3 or 6 weeks after the peripheral nerve surgery.<sup>40,41</sup> If the distal axonal fibers are protected by the nerve conduits from perineural adhesion, which is a direct cause of neuroma-associated pain, in the early stage, the minimal adhesion-related nerve damage can be maintained for a long time after the nerve conduit is dissolved. Further studies are warranted to evaluate the long-term effects of nerve capping with a PGA nerve conduit after the nerve conduit is absorbed completely.

In the current study, while the autotomy score was lower in the capping group than in the no-capping group, this difference was not statistically significant. That could be due to the properties of the material of the PGA nerve conduit used. The PGA conduit is soft and degrades relatively quickly, being completely dissolved by 12 weeks postimplantation.<sup>25,26,28</sup> Consequently, the axonal extension originating from the transected nerve stump might have been blocked prior to its complete termination by collapse of the PGA conduit, which diminishes the protective effect of the capping.<sup>25,42</sup> On the other hand, in our previous study of nerve-end capping with a nerve conduit consisting of poly L-lactide and polycaprolactone copolymer, the axonal extension could be terminated without collapse of the conduit and the neuropathic pain was significantly reduced.<sup>16</sup> The nerve conduit had a higher tubular rigidity and longer degradation time than the PGA conduit, so that it remained structurally stable at 12 weeks postprocedure. Future studies will be needed to corroborate the effects of the conduit material and design, to further improve the PGA nerve conduit as a suitable capping device for the treatment of painful stump neuromas.

## Conclusion

Nerve-end capping with a collagen-coated PGA conduit after rat sciatic neurectomy might prevent neuroma



formation by suppressing perineural scar formation and neuroinflammation around the nerve stump, potentially relieving neuropathic pain.

#### Funding

This work was supported by MEXT/JSPS KAKENHI Grant Number JP21K07300.

#### Conflict of Interest

The collagen-coated polyglycolic acid conduit was donated by Toyobo Co.

#### Acknowledgment

We would like to thank Editage (www.editage.com) for English language editing.

#### References

- 1 Yao C, Zhou X, Zhao B, Sun C, Poonit K, Yan H. Treatments of traumatic neuropathic pain: a systematic review. *Oncotarget* 2017;8(34):57670–57679
- 2 Toia F, Giesen T, Giovanoli P, Calcagni M. A systematic review of animal models for experimental neuroma. *J Plast Reconstr Aesthet Surg* 2015;68(10):1447–1463
- 3 van der Avoort DJ, Hovius SE, Selles RW, van Neck JW, Coert JH. The incidence of symptomatic neuroma in amputation and neurotomy patients. *J Plast Reconstr Aesthet Surg* 2013;66(10):1330–1334
- 4 Elliot D. Surgical management of painful peripheral nerves. *Clin Plast Surg* 2014;41(03):589–613
- 5 Dellon AL, Mackinnon SE. Treatment of the painful neuroma by neuroma resection and muscle implantation. *Plast Reconstr Surg* 1986;77(03):427–438
- 6 Mass DP, Ciano MC, Tortosa R, Newmeyer WL, Kilgore ES Jr. Treatment of painful hand neuromas by their transfer into bone. *Plast Reconstr Surg* 1984;74(02):182–185
- 7 Kakinoki R, Ikeguchi R, Matsumoto T, Shimizu M, Nakamura T. Treatment of painful peripheral neuromas by vein implantation. *Int Orthop* 2003;27(01):60–64
- 8 Kakinoki R, Ikeguchi R, Atiyya AN, Nakamura T. Treatment of posttraumatic painful neuromas at the digit tip using neurovascular island flaps. *J Hand Surg Am* 2008;33(03):348–352
- 9 Wu J, Chiu DT. Painful neuromas: a review of treatment modalities. *Ann Plast Surg* 1999;43(06):661–667
- 10 Lans J, Hoftiezer Y, Lozano-Calderón SA, Heng M, Valerio IL, Eberlin KR. Risk factors for neuropathic pain following major upper extremity amputation. *J Reconstr Microsurg* 2021;37(05):413–420
- 11 Griffin JW, Hogan MV, Chhabra AB, Deal DN. Peripheral nerve repair and reconstruction. *J Bone Joint Surg Am* 2013;95(23):2144–2151
- 12 Gould JS, Naranje SM, McGwin G Jr, Florence M, Cheppalli S. Use of collagen conduits in management of painful neuromas of the foot and ankle. *Foot Ankle Int* 2013;34(07):932–940
- 13 Parker RG, Merced-O'Neil O. Management of painful recurrent intermetatarsal neuroma using processed porcine extracellular matrix material: a case report. *Clin Podiatr Med Surg* 2016;33(02):235–242
- 14 de Ru JA, M Thomeer HG, Tjink BM, van Doormaal TPC. Neurocap use for the treatment of iatrogenic neuropathic pain: preliminary operative results in 3 patients. *Ear Nose Throat J* 2021;100(5\_suppl1):830S–834S
- 15 Uemura T, Onode E, Yokoi T, et al. Nerve capping technique with nerve conduit for treating painful digital neuroma: a case report. *J Orthop Sci* 2022;27(01):284–287
- 16 Onode E, Uemura T, Takamatsu K, et al. Nerve capping with a nerve conduit for the treatment of painful neuroma in the rat sciatic nerve. *J Neurosurg* 2019;132(03):856–864
- 17 Yi J, Jiang N, Li B, et al. Painful terminal neuroma prevention by capping PRGD/PDLLA conduit in rat sciatic nerves. *Adv Sci (Weinh)* 2018;5(06):1700876
- 18 Weng W, Zhao B, Lin D, Gao W, Li Z, Yan H. Significance of alpha smooth muscle actin expression in traumatic painful neuromas: a pilot study in rats. *Sci Rep* 2016;6:23828
- 19 Yan H, Zhang F, Wang C, Xia Z, Mo X, Fan C. The role of an aligned nanofiber conduit in the management of painful neuromas in rat sciatic nerves. *Ann Plast Surg* 2015;74(04):454–461
- 20 Yan H, Zhang F, Kolkin J, Wang C, Xia Z, Fan C. Mechanisms of nerve capping technique in prevention of painful neuroma formation. *PLoS One* 2014;9(04):e93973
- 21 Yan H, Gao W, Pan Z, Zhang F, Fan C. The expression of  $\alpha$ -SMA in the painful traumatic neuroma: potential role in the pathobiology of neuropathic pain. *J Neurotrauma* 2012;29(18):2791–2797
- 22 Okuda T, Ishida O, Fujimoto Y, et al. The autotomy relief effect of a silicone tube covering the proximal nerve stump. *J Orthop Res* 2006;24(07):1427–1437
- 23 Sakai Y, Ochi M, Uchio Y, Ryoke K, Yamamoto S. Prevention and treatment of amputation neuroma by an atelocollagen tube in rat sciatic nerves. *J Biomed Mater Res B Appl Biomater* 2005;73(02):355–360
- 24 Kusuhashi H, Hirase Y, Isogai N, Sueyoshi Y. A clinical multi-center registry study on digital nerve repair using a biodegradable nerve conduit of PGA with external and internal collagen scaffolding. *Microsurgery* 2019;39(05):395–399
- 25 Zukawa M, Osada R, Kimura T. Clinical outcome and ultrasonographic evaluation of treatment using polyglycolic acid-collagen tube for chronic neuropathic pain after peripheral nerve injury. *J Orthop Sci* 2019;24(06):1064–1067
- 26 Suzuki H, Araki K, Matsui T, et al. Value of a novel PGA-collagen tube on recurrent laryngeal nerve regeneration in a rat model. *Laryngoscope* 2016;126(07):E233–E239
- 27 Yamanaka T, Hosoi H, Murai T, Kobayashi T, Inada Y, Nakamura T. Regeneration of the nerves in the aerial cavity with an artificial nerve conduit –reconstruction of chorda tympani nerve gaps. *PLoS One* 2014;9(04):e92258
- 28 Saltzman EB, Villa JC, Doty SB, Feinberg JH, Lee SK, Wolfe SW. A comparison between two collagen nerve conduits and nerve autograft: a rat model of motor nerve regeneration. *J Hand Surg Am* 2019;44(08):700.e1–700.e9
- 29 Wall PD, Devor M, Inbal R, et al. Autotomy following peripheral nerve lesions: experimental anaesthesia dolorosa. *Pain* 1979;7(02):103–113
- 30 Shintani K, Uemura T, Takamatsu K, et al. Protective effect of biodegradable nerve conduit against peripheral nerve adhesion after neurolysis. *J Neurosurg* 2018;129(03):815–824
- 31 de Vrij EL, Schäfer TR, van Mulken T, Bertleff MJOE. Surgical treatment of symptomatic neuromas: a feasibility study using the NEUROCAP® bioresorbable nerve capping device. *J Hand Surg Eur Vol* 2022;47(02):212–214
- 32 George S, Pohl U, Power D. Analysis of an end neuroma 6 months after capping with a bioresorbable polycaprolactone cap (NEUROCAP®) in a human model. *Surg Case Rep* 2020;3:2–4
- 33 McNamara CT, Iorio ML. Targeted muscle reinnervation: outcomes in treating chronic pain secondary to extremity amputation and phantom limb syndrome. *J Reconstr Microsurg* 2020;36(04):235–240
- 34 Souza JM, Cheesborough JE, Ko JH, Cho MS, Kuiken TA, Dumanian GA. Targeted muscle reinnervation: a novel approach to postamputation neuroma pain. *Clin Orthop Relat Res* 2014;472(10):2984–2990
- 35 Swanson AB, Boeve NR, Lumsden RM. The prevention and treatment of amputation neuromata by silicone capping. *J Hand Surg Am* 1977;2(01):70–78

- 36 Shen B, Behera D, James ML, et al. Visualizing nerve injury in a neuropathic pain model with [ $^{18}\text{F}$ ]FTC-146 PET/MRI. *Theranostics* 2017;7(11):2794–2805
- 37 Romero L, Zamanillo D, Nadal X, et al. Pharmacological properties of S1RA, a new sigma-1 receptor antagonist that inhibits neuropathic pain and activity-induced spinal sensitization. *Br J Pharmacol* 2012;166(08):2289–2306
- 38 Puente B, Nadal X, Portillo-Salido E, et al. Sigma-1 receptors regulate activity-induced spinal sensitization and neuropathic pain after peripheral nerve injury. *Pain* 2009;145(03):294–303
- 39 Nieto FR, Cendán CM, Cañizares FJ, et al. Genetic inactivation and pharmacological blockade of sigma-1 receptors prevent paclitaxel-induced sensory-nerve mitochondrial abnormalities and neuropathic pain in mice. *Mol Pain* 2014;10:11
- 40 Petersen J, Russell L, Andrus K, MacKinnon M, Silver J, Kliot M. Reduction of extraneural scarring by ADCON-T/N after surgical intervention. *Neurosurgery* 1996;38(05):976–983, discussion 983–984
- 41 Crosio A, Valdatta L, Cherubino M, et al. A simple and reliable method to perform biomechanical evaluation of postoperative nerve adhesions. *J Neurosci Methods* 2014;233:73–77
- 42 Shin RH, Friedrich PF, Crum BA, Bishop AT, Shin AY. Treatment of a segmental nerve defect in the rat with use of bioabsorbable synthetic nerve conduits: a comparison of commercially available conduits. *J Bone Joint Surg Am* 2009;91(09):2194–2204