



# Vascularized Bone Graft Reconstruction for Upper Extremity Defects: A Review

Ava G. Chappell, MD<sup>1</sup> Matthew D. Ramsey, MD<sup>1</sup> Parinaz J. Dabestani, MD, MS<sup>2</sup>   
Jason H. Ko, MD, MBA<sup>1</sup>

<sup>1</sup>Division of Plastic and Reconstructive Surgery, Department of Surgery, Northwestern University Feinberg School of Medicine, Chicago, Illinois

<sup>2</sup>Division of Plastic and Reconstructive Surgery, Department of Surgery, Loyola University Medical Center, Maywood, Illinois

Address for correspondence Jason H. Ko, MD, MBA, Associate Professor, Program Director, Plastic Surgery Residency, Division of Plastic and Reconstructive Surgery, Department of Orthopedic Surgery, Northwestern University Feinberg School of Medicine, Chicago, IL 60611 (e-mail: Jason.ko@nm.org).

Arch Plast Surg 2023;50:82–95.

## Abstract

### Keywords

- ▶ vascularized bone graft
- ▶ upper extremity
- ▶ composite tissue transfer
- ▶ microsurgery
- ▶ reconstructive surgery
- ▶ surgical flaps
- ▶ pedicled bone graft
- ▶ free bone graft

Upper extremity reconstruction may pose clinical challenges for surgeons due to the often-critical, complex functional demands of the damaged and/or missing structures. The advent of vascularized bone grafts (VBGs) has aided in reconstruction of upper extremity (UE) defects due to their superior regenerative properties compared with nonvascularized bone grafts, ability to reconstruct large bony defects, and multiple donor site options. VBGs may be pedicled or free transfers and have the potential for composite tissue transfers when bone and soft tissue are needed. This article provides a comprehensive up-to-date review of VBGs, the commonly reported donor sites, and their indications for the treatment of specific UE defects.

## Introduction

The use of vascularized bone grafts (VBGs) has emerged as a primary treatment modality for the repair of upper extremity (UE) bone defects due to their regenerative properties, mechanical size, and nutrient vascular supply. The first successful VBG was achieved by Huntington<sup>1</sup> in 1905 with the rotation of a pedicled fibular flap to repair a large tibial defect. In 1974, Taylor et al were credited with the first successful human free VBG using a fibular flap to repair a 12.5 cm tibial defect in an adolescent male.<sup>2</sup> Within the last three decades, multiple studies have shown the effective use of VBGs for the repair

of UE bone defects secondary to infection, avascular necrosis (AVN), trauma, and tumor resection.<sup>3–6</sup>

VBGs are indicated when bony defects are too extensive for adequate repair via local osteogenesis, in cases of non-union, and/or AVN. Bone graft options are classically divided into three categories: autograft, allograft, and bone graft substitutes. These differ quite substantially in their osteoconductive, osteoinductive, osteogenic, and structural support properties.<sup>7–9</sup> Nonvascular bone grafts (NVBGs), such as cancellous bone autografts, are reliable in most situations due to their osteoconductive, osteoinductive, osteogenic, and structural support properties. Allografts, such as cancellous

### received

September 19, 2021

### accepted after revision

August 4, 2022

DOI <https://doi.org/>

10.1055/s-0042-1758639.

eISSN 2234-6171.

© 2023. The Korean Society of Plastic and Reconstructive Surgeons. All rights reserved.

This is an open access article published by Thieme under the terms of the Creative Commons Attribution-NonDerivative-NonCommercial-License, permitting copying and reproduction so long as the original work is given appropriate credit. Contents may not be used for commercial purposes, or adapted, remixed, transformed or built upon. (<https://creativecommons.org/licenses/by-nc-nd/4.0/>)

Thieme Medical Publishers, Inc., 333 Seventh Avenue, 18th Floor, New York, NY 10001, USA

cadaveric bone graft, have weaker osteoconductive and structural properties.<sup>10</sup> Conventional cancellous autografts have become the most widely used due to favorable aforementioned properties, ease of obtaining donor tissue, and lack of immune rejection and infectious transmission.<sup>11–13</sup> Previous authors, such as Klifto et al,<sup>14</sup> have published comprehensive reviews on bone graft options for the upper extremity with organized summary of union percent and time to union for each study discussed. Here, we presented a detailed review of indications and technical considerations of reported VBGs for UE reconstruction.

Autogenous NVBGs are typically reserved for smaller defects less than 5 to 6 cm, with rich local vasculature and no concern for infection.<sup>12,13,15,16</sup> If these conditions are not met, use of VBG is advantageous. Literature analyses by Merrell et al 2002<sup>17</sup> and Munk and Larsen 2004<sup>18</sup> showed improved union rates with the use of a VBG as opposed to NVBG, especially in cases of AVN of the scaphoid proximal pole and/or prior failed surgery. Of note, for long bone defects of the upper and lower extremities, the use of the two-staged Masquelet technique, which involves 1) soft tissue coverage and placement of a cement spacer into the bony defect, 2) removal of spacer with preservation of the induced membrane, bone grafting and fixation, has proven successful for large bony defects (up to 25 cm).<sup>19–22</sup> A VBG can be used with the Masquelet technique during the second stage.

VBGs are considered the gold standard for reconstruction when defects are more than 5 to 6 cm, have poor local vascularization, and/or when previous bone grafting has failed, as in the cases of recalcitrant nonunion.<sup>2,9,23–25</sup> Given vascularized reconstruction provides an immediate, robust blood supply, VBGs readily incorporate into the recipient sites and are actively resorbed and remodeled into healthy bone via primary bone healing.<sup>23,25</sup> Furthermore, they contribute immunologically to the recipient site to fight and lower the risk of infection. They can also be raised as osteocutaneous flaps for additional soft tissue coverage when needed. This review presents common donor sites for VBG transfers, encompassing both free and pedicled flaps, followed by UE recipient sites with their respective most common etiology of injury and utilized donor VBGs. All patients provided informed consent at the time of operation for the potential use of clinical photography in research publications.

## Vascularized Bone Graft Options for Upper Extremity Reconstruction

### Pedicled Flaps in the Upper Extremity (– Table 1)

Pedicled VBGs have similar advantages to free VBGs over NVBGs in that they preserve viable osteoblasts and osteocytes, have faster and improved bone remodeling, and less risk of osteopenia.<sup>26,27</sup> Some argue that free VBGs may have increased vascular supply compared with pedicled VBGs, secondary to larger diameter arterial vessels, but the reported clinical outcomes are equivocal.<sup>28</sup> However, when compared with free VBGs, pedicled VBGs have the advantages of less donor-site morbidity and avoiding the need for

microsurgical anastomoses. A recent systematic review of the literature on VBG for scaphoid nonunion found that pedicled VBG compared with free VBG demonstrated significantly greater postoperative percent improvement in absolute range of motion in extension and flexion ( $p < 0.05$ ).<sup>28</sup> However, the indications for pedicled vascularized bone flaps in the hand and wrist are limited due to the small size of bone that can be harvested and short pedicle lengths.

Much innovation in pedicled VBGs for UE reconstruction occurred to treat scaphoid nonunions with proximal pole AVN. Sheetz et al<sup>29</sup> in 1995 examined the vascularity of the distal radius and ulna to demonstrate the potential for multiple pedicled VBGs. A recent systematic review identified 34 studies on pedicled VBG to treat scaphoid nonunion.<sup>28</sup> These VBGs can be utilized for other carpal bone necrosis/defects within reach of the specific pedicles. VBGs from the distal radius often are categorized by dorsal or volar origin.

## Dorsal Distal Radius Pedicled VBGs

### 1,2-Intercompartmental Supraretinacular Artery

The 1,2-intercompartmental supraretinacular artery (1,2-ICSRA) flap was first described by Zaidenberg et al in 1991<sup>27</sup> and has been one of the most commonly described pedicled VBGs for scaphoid nonunion. The 1,2-ICSRA is found on the dorsum of the wrist, above the extensor retinaculum between the first and second extensor compartments, which makes this flap less applicable if a humpback deformity is present. The vascular pedicle derives from the radial artery, and anatomic studies have demonstrated it typically has a pedicle length of 22.5 mm (range: 15–31 mm).<sup>30</sup> The length of the pedicle makes this VBG available for both proximal and distal scaphoid nonunions; however, due to its short rotation arc, a radial styloidectomy may be required to avoid pedicle kinking, especially if trying to place the bone volarly.<sup>31</sup> Zaidenberg et al<sup>27</sup> reported bony union in 11/11 patients at an average of 6 weeks. Studies have shown similar positive outcomes for proximal scaphoid nonunion and/or AVN with union rates up to 100%.<sup>32,33</sup> Nevertheless, several studies have shown poorer union rates from 27 to 60%, which may have been due to failed prior surgeries and/or higher proportions of AVN.<sup>34–36</sup>

### 2,3-Intercompartmental Supraretinacular Artery

The 2,3-ICSRA flap stems from the radial artery (like the 1,2-ICSRA) and is located between second and third extensor compartments above the extensor retinaculum, adherent to Lister's tubercle. Flap elevation is achieved via a dorsoradial curvilinear incision on top of Lister's tubercle. A 2013 case series of 52 patients with scaphoid nonunions demonstrated 92.3% bony union at an average of 14.5 weeks after 2,3-ICSRA pedicle VBGs.<sup>37</sup>

### 4,5-Extensor Compartmental Artery

The 4,5-extensor compartmental artery (4,5-ECA) flap is pedicled off the fifth extensor compartmental artery and/or the fourth extensor compartmental artery, both derived from the anterior interosseous artery. Often, the combined fourth and fifth pedicle is chosen as the fourth ECA

has a long pedicle and the fifth has a large diameter (~0.49mm).<sup>29,38</sup> For the combined pedicle technique, the fifth ECA is accessed from a dorsal incision over the fifth dorsal extensor compartment and traced to its origin from the anterior interosseus artery where the fourth ECA is then identified. The bone graft overlies the fourth ECA to include nutrient vessels and is approximately 1 cm proximal to the radiocarpal joint.<sup>38</sup> Due to its proximity to the lunate, this VBG is often used for Kienböck's disease (AVN of the lunate), but the long pedicle length makes it applicable for scaphoid proximal pole defects.<sup>26</sup> When used for Kienböck's disease, internal fixation is not necessary as long as the lunate is not fractured.<sup>38</sup> However, the lunate is unloaded during the initial revascularization 6 to 8 weeks post op, with an external fixator, scaphocapitate pins, or scaphocapitate and triquetrum-capitate joints Kirschner wire (K-wire) temporary fixation.<sup>38,39</sup> Moran et al<sup>38</sup> demonstrated significant improvement in pain relief and grip strength in 26 patients with Kienböck's disease after treatment with 4,5-ECA grafts. Özalp et al<sup>40</sup> demonstrated proximal pole scaphoid union in 8/9 patients at an average of 9.5 weeks after treatment with 4,5-ECA grafts. Reported contraindications for the 4,5-ECA pedicled VBG are midcarpal arthritis, radiocarpal arthritis, complete collapse of the lunate, or significant destruction of cartilaginous shell of the lunate. In addition, 4,5-ECA VBGs cannot treat severe humpback deformities<sup>26</sup> (see **Fig. 1** clinical case example).

### Dorsal Capsular Based Distal Radius Graft

In 2006, Sotereanos et al described a pedicled VBG from the distal radius based off of the dorsal joint capsule for proximal pole scaphoid nonunion and lunate reconstruction.<sup>41</sup> The fourth ECA provides the vascular supply to this graft and has a 0.4mm diameter.<sup>29</sup> Some of the advantages of this VBG are the ease of dissection and minimal donor site morbidity. Sotereanos et al<sup>41</sup> found that 10/13 nonunions achieved solid bone union at a mean follow-up of 19 months.

### Volar Distal Radius Pedicled VBGs

#### Volar Carpal Artery

Volar distal radius VBGs are pedicled off of the volar (palmar) carpal artery that has a 0.5 to 1.0mm diameter and has periosteal and cortical perforators.<sup>42</sup> These VBGs are useful for treating scaphoid nonunion<sup>42-45</sup> and Kienböck's disease.<sup>43,46</sup> Kuhlmann et al<sup>42</sup> first reported results using volar distal radius VBGs. These grafts are elevated from the volar and ulnar distal radius, and one incision can be used for harvest and transfer. Volar distal radius VBGs are the preferred pedicled VBGs for the treatment of humpback deformities of the scaphoid as they tend to be better in restoring normal carpal geometry, specifically the intrascaphoid angle, scapholunate angle, and carpal height ratio.<sup>26,42</sup> Relative contraindications to these VBGs are prior trauma and/or surgeries to the volar distal radius region.<sup>26</sup>

Reported outcomes from pedicled volar distal radius VBG have been positive. Mathoulin and Haerle<sup>43</sup> demonstrated

**Table 1** Characteristics of common pedicled VBGs

Donor site	Common indications	Graft type	Arterial supply	Mean pedicle length	Donor site morbidity	Advantages	Contraindications
Dorsal radius	Proximal scaphoid nonunions Displaced proximal scaphoid pole fractures AVN proximal fragment Chronic nonunion failed NVBGs <sup>26,37</sup>	Cortico-cancellous	1,2-ICSRA 2,3-ICSRA 4,5-ECA	22.5 mm <sup>26</sup> 13 mm <sup>37</sup> -	Minimal	Can be transferred for proximal and distal nonunions <sup>26,37</sup> Greater arc of rotation than 1,2-ICSRA <sup>26,37</sup> Useful for Kienböck's and proximal pole scaphoid nonunion, large pedicle length <sup>26,37</sup> Ease of dissection, useful for lunate and proximal pole of scaphoid <sup>26,37</sup>	Periscaphoid arthritis Humpback deformity Carpal instability Carpal collapse <sup>26,37</sup>
Volar radius	Humpback deformity Dorsal intercalated segment instability Non-union of the scaphoid waist <sup>26,46</sup>	Cortico-cancellous	Capsular based Palmar carpal a Pronator quadratus Cubitodorsal a.	15 mm <sup>41</sup> 3 cm <sup>43</sup> 4-5 cm <sup>46</sup> —	Minimal pain <sup>43,46</sup>	Restores carpal geometry, protects blood supply of scaphoid, minimal loss wrist extension <sup>26,46,58</sup> Ease of manipulation due to the anastomoses between the radial, ulnar, and anterior interosseous arteries <sup>26,37</sup> Rich vascular supply from anastomoses between anterior interosseous, radial and ulnar artery branches <sup>51</sup>	Requirement of long pedicle injury to radial or ulnar artery Previous volar wrist surgery Radiocarpal and/or midcarpal osteoarthritis <sup>26,43</sup>

Abbreviations: a., artery; AVN, avascular necrosis; ICSRA, extracompartmental supraetnacular arteries; NVBG, nonvascularized bone graft.

100% union at an average of 8.6 weeks in a study of 17 patients treated for scaphoid waist nonunion with volar radius VBGs. Another study demonstrated union in all nine patients with scaphoid waist nonunions, at an average of 9 weeks.<sup>44</sup>

### Pronator Quadratus

Pronator quadratus pedicled VBGs derive from branches off the anastomoses between the anterior interosseous, radial and ulnar arteries.<sup>26</sup> A main advantage of this flap is the rich, sturdy blood supply. Kawai and Yamamoto<sup>47</sup> were the first to report outcomes from using a VBG from the volar distal radius based on the pronator quadratus to treat scaphoid nonunion. In eight patients, 100% union was observed.<sup>47</sup> In a study of 45 patients, Noaman et al<sup>48</sup> reported a 95% union rate for patients with scaphoid nonunions treated with pronator quadratus pedicled grafts. More recently, Lee et al<sup>49</sup> used a headless compression screw to fixate this graft in patients with scaphoid nonunion and dorsal intercalated segment instability or humpback deformity. They reported good functional results and 100% union rate.<sup>49</sup>

### Pisiform and Scaphoid Tubercle

Pedicled scaphoid tubercle and pisiform VBGs have been described for the treatment of scaphoid nonunions and lunate reconstruction in advanced Kienböck's disease.<sup>50</sup> Saffar<sup>51</sup> described in 1982 the technique of replacing the lunate in Stage IIIb Kienböck's disease with vascularized pisiform. In this technique, the pisiform is transferred based on the cubitodorsal artery off of the ulnar artery.<sup>51</sup> In a long-term follow-up study of 11 patients with advanced Kienböck's disease who underwent vascularized pisiform transfer, 81.8% of patients had good-to-excellent results in terms of clinical outcomes and radiographic imaging parameters.<sup>52</sup>

### Metacarpal

The vascular anatomy of the index metacarpal has at least six arterial patterns that permit flap transfer within the radial region of the hand.<sup>53</sup> The dorsal metacarpal arteries (2–4) are based on the dorsal carpal arch and are connected to the palmar metacarpal arteries via distal anastomoses. Brunelli et al<sup>54</sup> described a VBG from the distal index metacarpal transferred with a soft tissue pedicle. Khan et al<sup>55</sup> reported a VBG from the second or third metacarpal, based on the second

dorsal metacarpal artery. VBGs from the second, third, and first metacarpals have also been described to treat defects of distal radius, scaphoid nonunions, Kienböck's disease, and distal finger reconstruction.<sup>56–58</sup>

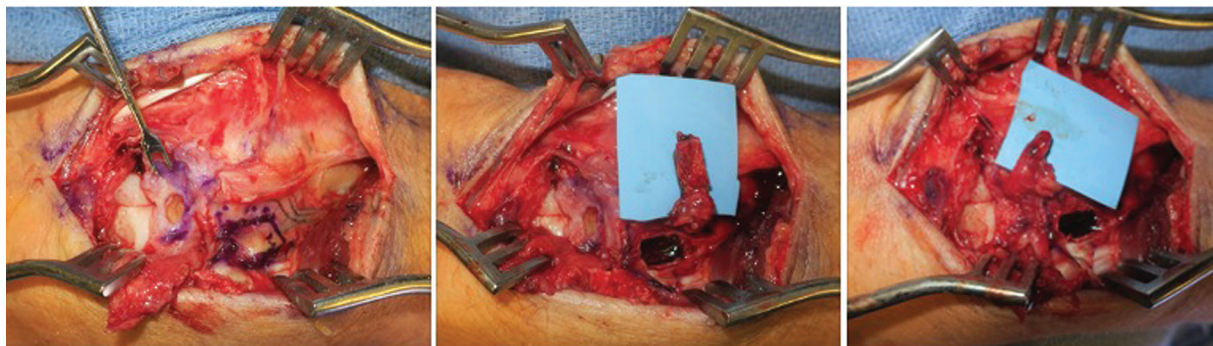
### Free Flaps (– Table 2)

Free tissue transfer of vascularized bone is indicated when local pedicled flaps are unavailable or insufficient to reconstruct the bony defect based on size and/or location. Various sources of free vascularized bone flaps are summarized here (– Table 2).

### Fibula

The free vascularized fibula graft (FVFG) is a tricortical long bone flap with a dimension of up to 3 cm × 40 cm. It can be sized to fit long bone defects and appropriately into the medullary cavity. Success of the flap is aided by the adequately sized pedicle; endosteal and periosteal vessels—branches of the peroneal artery—supply blood to the diaphysis and distal portion of the fibula. In contrast, the epiphysis and proximal fibular head receive blood from the anterior tibial artery, which should be taken into consideration when performing vascularized proximal fibula epiphyseal transfer.<sup>59,60</sup> For sufficient vascular supply to the free flap, the endosteal artery must be harvested in concert with the bone flap. This vessel can be found posterior to the interosseous membrane approximately 17 cm distal to the fibular head in the middle third of the fibular diaphysis.<sup>61</sup> The peroneal artery also sends out cutaneous perforators that can be dissected with the soft tissue to create an osteocutaneous flap. Additionally, the ability to transfer the epiphysis with the diaphysis of the fibula allows continued growth of the graft.<sup>61</sup>

Anatomical variation, such as hypoplasia of the anterior and posterior tibial arteries, known as peronea arteria magna, has been reported in 8% of the population. Anatomic studies have shown that if a dominant peroneal system is observed in one leg, the likelihood of finding the same variation in the other leg is 20%.<sup>62</sup> Failure to identify this anatomic variation can result in ischemia to the lower limb.<sup>61,63</sup> A thorough pulse examination of both lower extremities is essential, and preoperative computed tomography angiography is recommended. Donor-site morbidity includes localized pain, valgus deformity, temporary peroneal nerve deficits, foot drop, and lateral knee instability due



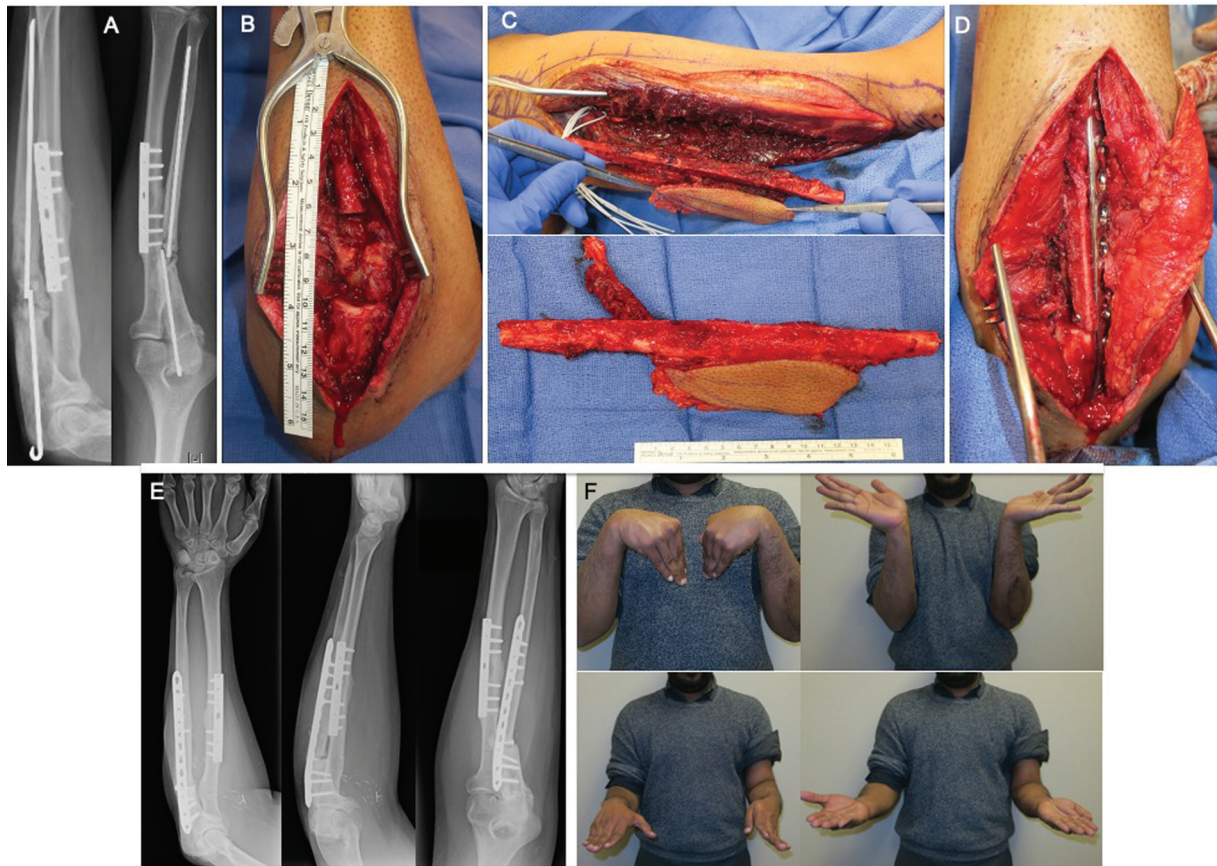
**Fig. 1** Case example of a 4+5 extensor compartment artery pedicled flap being marked, raised, and implanted for a case of Kienböck's.

**Table 2** Characteristics of free VBG donor sites

Donor site	Graft type	Arterial supply	Maximal size	Common indications	Donor-site morbidity	Contraindications
Fibula <sup>59,60,62</sup>	Tricorticalosteocutaneous	Peroneal	40 cm	Large defects, upper extremity	Valgus deformity, foot drop, lateral knee instability, lower extremity fractures	DVT, peripheral vascular disease
Iliac crest <sup>50,67,68</sup>	Corticocancellousosteocutaneous	Deep circumflex a.	10 cm	Medium size defectsAVN scaphoid bone	Trendelenburg gait, lateral femoral cutaneous nerve lesion, lower extremity fractures	Previous surgery at graft site, external pelvic fixator
Scapula <sup>90</sup>	Corticocancellousosteocutaneous	Angular branch of the thoracodorsal a.	14 cm	Small defects, humerus, clavicle	Scar, wound dehiscence	Previous axillary or thoracic surgery ipsilateral to graft site, small females with limited bone, need to re-position patient for flap harvest
Ribs <sup>75</sup>	Corticocancellous Osteocartilaginous Osteocutaneous	Posterior intercostals, periosteal perforators, thoracodorsal a.	8 cm	Humerus, clavicle	Hemothorax, pneumothorax, stress fractures, chronic pain	Rib fractures, lung pathology
MFC <sup>73,75,77</sup>	Corticocancellous Osteocartilaginous Osteocutaneous	Descending genicular a.—longitudinal branchSMGA	11 cm	Long bone nonunionCarpal defects	Minimal, knee pain, saphenous nerve hypoesthesia	Injury to medial knee, advanced osteoarthritis, cartilage lesions
MFT <sup>77</sup>	Corticocancellous Osteocartilaginous Osteocutaneous	Descending genicular a.—transverse branchSMGA	13 cm	Carpal defects	Minimal, iatrogenic fracture, knee discomfort	Advanced osteoarthritis, knee instability, medial knee trauma
LFC <sup>87</sup>	Corticocancellous Osteocartilaginous Osteocutaneous	SGLA	12 cm	Carpal defects	Minimal	Advanced osteoarthritis, knee instability, lateral knee trauma
LFT <sup>89</sup>	Corticocancellous Osteocartilaginous Osteocutaneous	SGLA	-	Carpal defects	Minimal, knee pain	Advanced osteoarthritis, knee instability, lateral knee trauma
Proximal radius <sup>50,103-105</sup>	Corticocancellous	Radial a., dorsal or palmar carpal arcade of vessels	6 cm	Metacarpals, phalanges, thumb amputation	Minimal, fractures at donor site	Vascular injury to the palmar archPositive Allen test

Abbreviations: a., Artery; AVN, avascular necrosis; DVT, deep venous thrombosis; LFC, lateral femoral condyle; LFT, lateral femoral condyle; MFC, medial femoral condyle; MFT, medial femoral trochlea; MFT, medial femoral trochlea; SGLA, superolateral genicular artery; SMGA, superomedial genicular artery; VBG, vascularized bone graft.

Note: Relative contraindications: Diabetes, obesity, alcoholism, tobacco use, infection, immunosuppression, tumor.



**Fig. 2** Case example of a man with ulnar nonunion having undergone 13 previous surgeries now successfully treated with a free, vascularized fibular graft. A) Depicts his lateral and anterior-posterior X-ray prior to his fibular graft reconstruction. B) Depicts his forearm recipient surgical site. The donor site and free vascularized fibular osteocutaneous graft are depicted in C) with the graft implanted in D). E) Depicts X-rays at 8-month post-op with a successfully healed union, and the patient's corresponding range of motion in F).

to the insertion site of the lateral collateral ligament on the fibula. Two studies evaluated lower extremity function following fibular VBG and showed good overall functional outcomes at the donor site using the Finnish Translation of the lower extremity functional scale and the Kofoed score<sup>3,64</sup> (see ▶Figs. 2 and 3 for clinical case examples).

Prior to use of autologous bone grafting for repair of these bone defects, large cadaveric allografts were used and resulted in poor outcomes such as infection and nonunion. The Capanna technique combines this older approach with the FVFG transfer, by using a cadaveric allograft with a vascularized fibular flap supplied by the intramedullary pedicle.<sup>65</sup> Studies directly comparing union rates between pedicled and free VBGs can be found for scaphoid nonunion but prove difficult to find for other UE reconstruction sites. Two such studies<sup>28,66</sup> did conclude higher rates of union with free VBGs, one by 11% but not statistically significant and one concluded free VBGs achieved a significantly shorter time to union with a significantly higher union rate. This allows proper fixation of the allograft with nutrient supply and growth benefits of the vascularized fibula.<sup>25</sup>

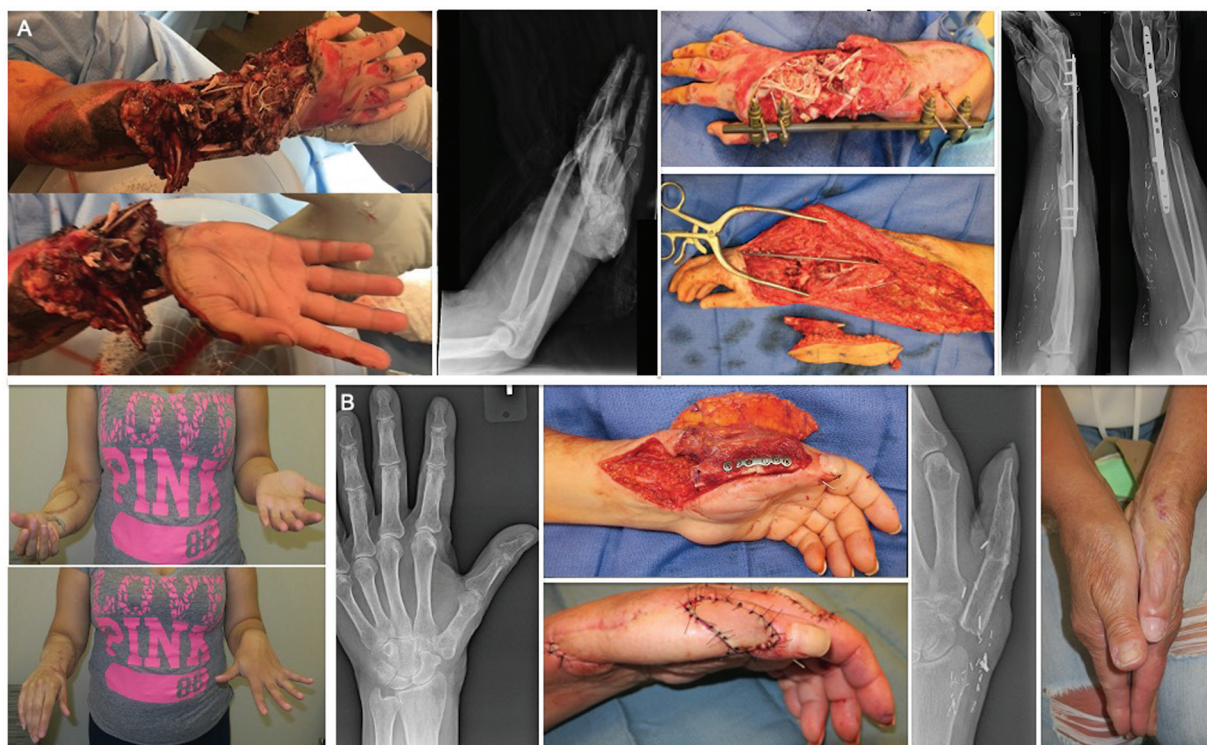### Iliac Crest

Similarly, the iliac crest can be used as a free VBG for larger bony defects. The iliac crest VBG contains cancellous bone

and provides good coverage for intermediate bone loss (5–10 cm), preventing fracture complications at the donor site.<sup>50</sup> Incidentally, increased incidence of lower extremity fracture has been observed with use of iliac crest flaps for defects more than 12cm. The pedicle used for this flap is the deep circumflex iliac artery, which is supplied from the femoral artery (in most of the population) or the external iliac artery. While vascularized Iliac crest flaps are commonly used for mandibular reconstruction, experience with their use in UE bone reconstruction is relatively limited. One case series describing 60 patients receiving iliac VBG for recalcitrant AVN of the scaphoid bone found a 91.7% union rate.<sup>67,68</sup> Donor-site morbidity includes pain, hematoma, infection, Trendelenburg gait, and lesion of the lateral femoral cutaneous nerve.<sup>67</sup> Careful superficial dissection to identify and preserve motor and sensory nerves paired with thorough hemostasis prior to closure can aid in reducing the donor-site morbidity. Attention to postoperative care, including cold packs to the donor site and a physical therapy evaluation, can help with recovery and early return to ambulation.

### Medial Femur

Since first being described in 1991 by Sakai et al,<sup>69</sup> the free medial femoral condyle (MFC) corticoperiosteal or



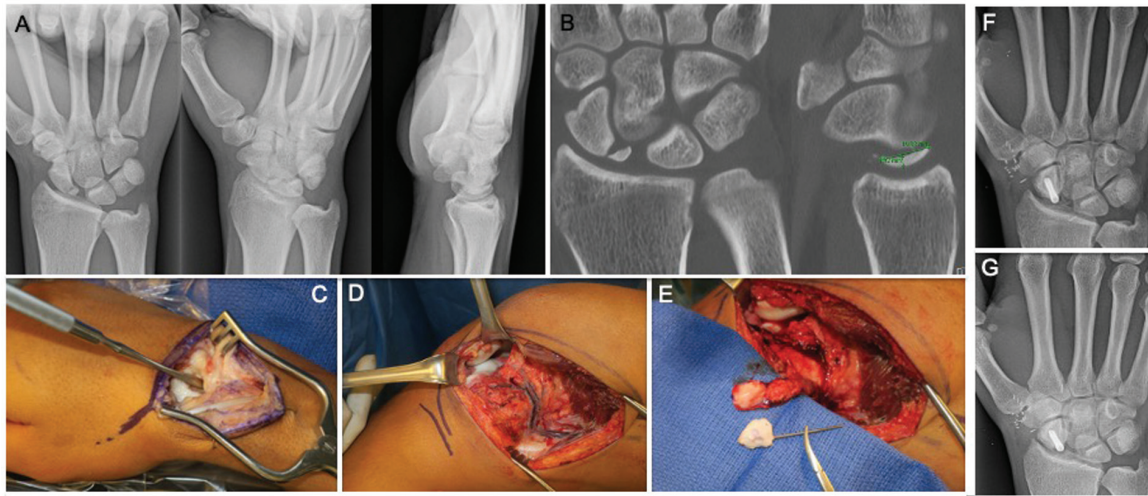
**Fig. 3** Top panel A): Case example of a post-traumatic, free fibular osteocutaneous forearm reconstruction. This patient had a latissimus flap over an antibiotic spacer more than one year prior to the presented photographs. From left to right: immediate post-traumatic photographs, corresponding X-ray, initial external fixation for stabilization, delayed intra-operative photograph of the free graft with the forearm surgical site, X-rays at 20 months post-op, range of motion at 20 months (bottom left). Bottom panel B): Case example of a 60-year-old woman with a chronic draining sinus of her thumb refractory to five previous debridement procedures. From left to right: X-ray on presentation, surgical site with fibular graft fixed, first dorsal metacarpal artery flap required for additional cutaneous coverage, X-ray after fixation removed, healed photograph.

corticocancellous flap has been increasingly applied to various pathologies in the UE due to its ease of dissection, preservation of distal arteries, variable size and shape for donor-site conformability, and osteogenic nature. Following an initial muscular dissection, the descending genicular artery (DGA) becomes readily identifiable in 89 to 93% of patients.<sup>70,71</sup> The DGA originates from the superficial femoral artery and distally supplies the MFC via longitudinal and transverse branches. In 15 to 23% of cases, the superomedial genicular artery (SMGA) off the popliteal is the dominant arterial supply, and if both are present and deemed viable options for the pedicle, the larger caliber vessel should be taken for anastomosis.<sup>70,72</sup> The SMGA pedicle, however, only supports a pedicle less than or equal to 5 cm in length on average—approximately one-third of the potential length of a DGA-pedicled MFC flap.<sup>70</sup>

The MFC flap can be taken with or without a skin paddle. The MFC flap with skin paddle is a truly “chimeric” flap as distinct branches from the DGA supply the skin and bony components<sup>73,74</sup>. An initial curvilinear incision is taken for an osteocutaneous flap with a pedicle from the cutaneous branch of the DGA—perfusing an area of 70 cm<sup>2</sup>—or the saphenous artery branch—perfusing 361 cm<sup>2</sup> of cutaneous tissue on average.<sup>73,75</sup> Higgins and Bürger support the use of the cutaneous island for accurate bone graft perfusion monitoring in cases of nonunion and its utility in providing soft tissue for tension-free anastomosis coverage.<sup>70,76,77</sup> The

longitudinal branch of the DGA is most commonly followed for harvesting MFC corticocancellous bone for long bone or scaphoid nonunion.<sup>75,77</sup> A vascularized portion of the adductor longus tendon can also be harvested with the MFC flap, if needed.

With increasing vascular anatomic studies of the distal femur in recent years and realization of the utility of a convex, cartilage-bearing VBG, the medial femoral trochlea (MFT) flap has grown in popularity since its description in 2008 by Bürger, Higgins et al.<sup>75,78,79</sup> The MFT flap technique differs from the MFC harvest only after identification of the distal DGA branches. For the MFT flap, the transverse branch of the DGA is followed until it invests proximally into the medial cartilage of the MFT. In cases of rare vascular variations, this flap may also be pedicled on the medial metaphyseal periosteal artery.<sup>80</sup> The harvested flap is then employed in articular reconstruction of the wrist.<sup>75,77</sup> Hugon et al<sup>78</sup> have described and quantified how the unique convex, cartilaginous surface of the MFT matches the proximal pole of the scaphoid to 0.01 mm radii of curvature with the lunate and capitate closely matched as well. Hill et al<sup>81</sup> expanded on this to specify the radioulnar axis of the proximal scaphoid pole is most closely matched by the proximodistal axis of the MFT. Beyond the carpus, the MFT was also quantified as topographically matching the humeral capitellum to less than 0.1 mm, the best fit of the four distal femur donor sites analyzed.<sup>82</sup> Higgins and Bürger have described the use of a



**Fig. 4** Case example of an 18-year-old right hand dominant man presenting with significant wrist pain. A) Depicts his X-rays on presentation, significant for a scaphoid nonunion secondary to an unknown injury, and B) his CT scan. C) and D) Depict intra-operative photographs of the carpal site on the left and medial femoral on the right with E) displaying the morphologically matched resected carpal bone with the raised MFT graft. F) Depicts the A-P X-ray at 8 weeks post-op and G) 5 months with two views.

combined free MFT with vascularized medial patella for reconstruction of complex defects requiring resurfacing of two separate cartilage defects, such as the radiocapitellar joint, see ►**Fig. 4** for clinical case example.<sup>76</sup>

Donor-site morbidity for femoral VBGs is overall minimal, with the most common long-term complication being sensory changes, such as paresthesia or numbness in the saphenous nerve distribution.<sup>83,84</sup> There have been reports of femur fractures with the MFC flap,<sup>85</sup> which is a devastating complication that is likely due more to torsional forces than axial loads. Proponents of the MFC flap have advocated that the bone harvest does not extend proximally beyond the transverse branch of the DGA into the diaphysis of the femur to minimize the chances of fracture.

## Lateral Femur

The lateral femoral condyle (LFC) provides a convex vascularized bone flap. Additionally, it can be transferred with an accessory tendon for repair of aggregate carpal bone and tendon defects. This is done through the concurrent harvesting of the vascularized iliotibial band and the composite transfer of tendon and bone. Vascular supply to the LFC is provided by the superior lateral genicular artery (SLGA) from the popliteal artery with an average pedicle length of 4.8 cm. Therefore, the LFC graft has a shorter pedicle with a larger diameter compared with the MFC and can be more advantageous for small carpal reconstruction defects.<sup>86,87</sup> In cadaver studies, up to 12 cm of LFC bone receives adequate vascularization and may potentially be used for grafting. Other cases supporting the use of an LFC VBG over MFC include unavailability of the MFC due to medial knee injury, and recipient sites requiring a thicker graft with a greater area of cortical bone. Some studies have shown an increased anterior condylar height in the LFC compared with the MFC supporting this use.<sup>87</sup>

The lateral femoral trochlea (LFT) can be used as an osteocartilaginous flap for carpal reconstruction. The LFT

receives arterial supply via the SLGA<sup>88</sup> and can be used in cases where trauma precludes the use of an MFT flap or based on surgeon preference. Windhofer et al<sup>89</sup> used the LFT to for lunate reconstruction in patients with Grade III Kienböck's disease and found most patients to be satisfied with their results. The authors suggest that the LFT is amenable to the curved shape of the lunate fossa. Donor-site morbidity included knee pain.<sup>89</sup> Future studies are necessary due to limited experience with LFT flaps for UE reconstruction.

## Scapula

Vascularized scapular bone flaps have been primarily used for bone reconstruction of the head and neck and occasionally the proximal humeral head.<sup>6,90</sup> It has been suggested that the vascularized scapular bone flap is advantageous for UE reconstruction due to its straight shape and strength.<sup>25,90</sup> The lateral scapular border contains 14 cm of straight cancellous bone that optimizes bone regeneration, can be harvested as an osteocutaneous flap with plentiful soft tissue coverage, and has a reliable arterial supply.<sup>91</sup> The scapular bone flap is generally harvested as a chimeric flap along with soft-tissue flaps such as the scapular/parascapular, latissimus, and serratus flaps based off the subscapular vascular system. Two pedicles are available for scapular bone flap harvesting: the circumflex scapular artery and the angular branch of the thoracodorsal artery. Because the angular branch is a longer pedicle, it may be better suited for grafting.

Donor-site morbidity is limited. Mild paresthesias are possible at the donor site, but scapular bone grafting does not result in the mobility difficulties that would be seen with the use of lower extremity donor sites. Therefore, use of scapular bone grafting for UE bone reconstruction is promising, although the logistics of surgical positioning during harvesting can prove challenging, especially for UE reconstruction.



## Ribs

Vascularized rib free flaps have gained popularity in maxillofacial and lower extremity reconstruction with currently limited applications in the UE due to donor-site morbidity and other preferred vascularized bone options.<sup>25</sup> However, when employed as a second-line option, there are two main advantages to the vascularized rib flap: A rich dual blood supply and ample potential for soft tissue coverage. The dual blood supply originates from the posterior intercostals and periosteal perforators from the serratus anterior derived from the thoracodorsal artery, which can also be used to significantly lengthen the pedicle of the free flap.<sup>92–94</sup> The soft tissue potential of the flap is maximized when raised as an osteomyocutaneous flap with either or both the serratus anterior and latissimus dorsi. Limited case reports and series have shown beneficial outcomes in reconstruction of the clavicle,<sup>95</sup> humerus (including in pediatrics),<sup>96,97</sup> forearm,<sup>96–98</sup> metacarpal,<sup>95,96</sup> and phalanx accounting for 38 cases.<sup>99</sup> Donor-site morbidity includes hemothorax, pneumothorax or pleural tears, stress fractures, paresthesia or chronic pain given the neurovascular bundle is invariably taken with the posterior intercostal, and rarely, winged scapula.<sup>92,93</sup>

## Humerus with Lateral Arm Flap

The lateral arm flap can be combined with vascularized humerus to address bone and soft tissue defects of the UE.<sup>100,101</sup> The lateral arm flap is based on the posterior radial collateral artery (PRCA) and posterior branches off the PRCA directly supply the lateral supracondylar ridge of the humerus.<sup>100</sup> A three-patient case series demonstrated effective treatment for segmental bony and soft tissue defects in the forearm following trauma.<sup>102</sup> Okada et al<sup>103</sup> have reported a case of using a reverse lateral arm flap in conjunction with vascularized distal humerus for reconstruction of a distal ulnar fracture following a malignant resection. They demonstrated a successful result and supported the use of this flap for simultaneous coverage of bone and soft tissue defects.

## Radius

The proximal radius composite osteocutaneous flap based off the radial artery can be transferred as free or pedicled flaps. These VBGs can be osteocutaneous and/or osteomuscular composite grafts with the advantage of offering bone reconstruction and soft tissue defect coverage of the wrist or hand.<sup>104</sup> Thus, these flaps are indicated for combined bone and soft tissue defects of the metacarpals or phalanges, as well as thumb amputations.<sup>50,104–106</sup> In osteocutaneous radial forearm flaps, a segment of radial cortex is transferred attached to the radial forearm flap. The mean length of bone harvested is 5 cm, and mean time until union evidenced on X-rays is 2.6 months. This VBG can be a sensory flap when harvested with the lateral antebrachial cutaneous nerve, which is helpful for hand reconstruction.<sup>107</sup> The forearm

donor site is often covered with a skin graft. Several studies have demonstrated the use of this flap for thumb reconstruction after distal tip amputations, one-stage reconstruction of intercalated defects of the thumb, and total thumb reconstruction when other options are not available.<sup>104–106</sup> Complications from this flap include fractures from harvesting the radius cortical strut, so prophylactic plate fixation of the radius is recommended.<sup>104,107</sup> This flap, which sacrifices the radial artery, is contraindicated in patients with an incomplete palmar arch.<sup>50</sup> Preoperative Allen's test is essential prior to considering a radial forearm flap with vascularized radius.

## Specific Upper Extremity Defect Sites

### Clavicle

Clavicular fractures following trauma tend to be managed nonoperatively unless the fracture is significantly displaced and/or symptomatic nonunion occurs (rate of nonunion ranges 0.1 to 5%). Surgical repair with nonvascularized iliac crest bone grafting, plating, and/or intramedullary fixation can be performed.<sup>97</sup> When attempted repair fails, VBG can be used to reconstruct the defect. Anatomically, the acromioclavicular joint poses a challenge as it must be preserved or repaired to maintain good functional outcome of the shoulder. The midclavicle is also very close to the brachial plexus and axillary artery; therefore, care must be taken to relieve or prevent compression of the neurovascular bundle. Multiple studies have described the use of vascularized fibula<sup>108–112</sup> and MFC<sup>113,114</sup> VBGs for clavicular reconstruction, the majority of which resulted in good functional outcomes. The MFC flap can be harvested as a periosteal or corticoperiosteal flap, potentially with iliac NVBG, to provide better conformability to the clavicle along with periosteal vascularization.<sup>113</sup> Use of the transverse cervical artery and external jugular vein,<sup>109</sup> as well as the thoracoacromial<sup>113</sup> vessels, as recipient vessels has been documented. Vascularized fibula epiphyseal transfer has been reported to reconstruct proximal humerus defects in children,<sup>115,116</sup> while other reports in the adult population have shown stabilization of the acromioclavicular joint via fibular bone transfer.<sup>111,117</sup>

### Humerus

VBG reconstruction is especially advantageous for AVN of the humeral head, following osteogenic tumor resection and/or radiation treatment, and after infection or trauma. In the literature, the fibula is the most common donor site for humeral VBG reconstruction; however, MFC use has been documented as well.<sup>118,119</sup> A recent systematic review evaluating 56 articles found that the humerus was the most common recipient site (57.3%) of FVFG following osteogenic tumor resection.<sup>120</sup>

Reports describing VBG reconstruction of the humerus following osteogenic tumor resection are plentiful in both the adult<sup>121,122</sup> and pediatric populations. In the pediatric population, humeral bone reconstruction following tumor resection and radiation treatment has been primarily performed using FVFGs.<sup>6,123,124</sup> The brachial artery and basilic

vein are commonly used as the recipient vessels. Important care must be taken to preserve joint stability—both proximal and distal humerus. Shoulder arthrodesis using K-wires may also be used.<sup>3</sup> Increasing weight bearing on the reconstructed extremity has shown appropriate hypertrophy of the VBG when a fibular donor site is utilized.<sup>123,125</sup> Incidentally, the most common complications reported are delayed union, fibular graft fracture, nerve palsies, and infection. Reoperation may be necessary for fixation of the graft fracture, addition of autogenous bone grafting, and irrigation and debridement for infection.<sup>122</sup> Slipped fibular epiphysis at the recipient site has also been reported as a complication in the pediatric population.<sup>123</sup>

### Forearm (radius and ulna)

The FVFG is most commonly employed for forearm reconstruction due to conformability to the radius and ulna, high union rates (85–89%), and rapid maturation of the graft leading to early load-bearing activity.<sup>25</sup> Furthermore, a recent review of 56 studies in which UE postoncologic defects were reconstructed with the FVFG displayed significantly higher patient satisfaction than amputation, and scores were maintained in long-term follow-up studies of pediatric reconstruction.<sup>120</sup>

Another reconstructive option for long bone nonunion is the free MFC flap. In a retrospective cohort comparing 10 vascularized MFC flaps against 10 traditional cancellous grafts, it was found that healing was 10% higher in the MFC group and occurred in 3.2 months as opposed to 8.6 months in the traditional group.<sup>126</sup> Henry<sup>127</sup> found that this graft can be applied with 100% healed success rate at an average of 6.8 weeks despite the included patients having a mean 3.7 prior surgeries over the 24 months preceding the MFC flap.

### Carpus

Scaphoid or lunate nonunion, Preiser's (scaphoid osteonecrosis not due to nonunion or prior fracture) and Kienböck's disease (lunate AVN) have multiple viable treatment options with follow-up studies present in the literature for direct comparison. Scaphoid nonunions can occur in approximately 5 to 15% of scaphoid fractures and increases to 30% in proximal pole fractures due to the retrograde perfusion of the scaphoid.<sup>37,128,129</sup> Pedicled VBGs from the volar and distal radius have been successfully used to treat scaphoid nonunions. Dorsally based distal radius VBG tends to be best used for proximal scaphoid nonunions and/or AVN of proximal pole, whereas volar VBGs tend to be employed for waist fracture nonunions and humpback deformities.<sup>41</sup> Outcome studies of scaphoid nonunions reconstructed with pedicled VBGs from the distal radius (dorsal/volar) demonstrate union rates of 27 to 100%.<sup>35</sup> Currently, the most commonly used pedicled VBGs with high union rates are the 1,2-ICSRA, the 4,5-ECA graft, and the volar radial graft.<sup>26,27,44,49</sup> Options for humpback deformities include volar pedicled VBGs or free VBGs such as the MFC flap or the iliac crest flap.<sup>66</sup> Use of the free MFC flap has been described for wrist fusion to treat extensive chronic osteomyelitis of the carpus.<sup>130</sup>

### Metacarpals and Phalanges

Defects of the metacarpals and phalanges can be reconstructed with various pedicled VBGs and free VBG tissue transfers. Pedicled VBGs are from surrounding metacarpals and can be composite, such as the reverse dorsal metacarpal osteocutaneous flap if bone and soft tissue is required.<sup>50</sup> Metacarpal periosteal flaps may reduce risk of adhesions between bone and tendons and retain the general skeletal contour of the metacarpal.<sup>50</sup> For thumb reconstruction, the osteocutaneous radial forearm flap may be employed. Limited case series have reported good clinical outcomes in patients with traumatic thumb defects who underwent pedicled osteocutaneous radial forearm flap reconstruction, with bony union achieved at 2–3 months.<sup>106,131</sup> Free VBG donor site options include the first metatarsal and toe phalanges.

Compromised joints of the wrist and hand can also be treated with pedicled and free VBGs.<sup>50</sup> If wrist fusion is desired, pedicled VBGs from the distal radius may facilitate union.<sup>132</sup> Reconstruction of the distal radius articular surface has been done with free vascularized osteochondral grafts from the third metatarsal base.<sup>133</sup> Free or pedicled VBGs of the metacarpophalangeal (MCP) joint, proximal interphalangeal (PIP) joint, and distal interphalangeal (DIP) joint, from the fingers or toes, have been used to reconstruct MCP and PIP joints in the hand. Advantages of vascularized joint transfers include expeditious bone healing, stability, cartilage preservation, growth potential, and option for composite tissue transfers.<sup>50</sup> Reportedly, these transfers can result in mobility at more than 45 degrees at the MCP and 42 degrees at the PIP joints.<sup>135–137</sup>

### Conclusion

While the existing literature demonstrates the utility of VBGs for UE reconstruction, significant gaps remain in the knowledge of VBGs due to a paucity of high-powered comparative studies with long-term follow-up data. Thus, clinical decision making tends to be driven by surgeon preference and personal expertise. Future large cohort comparative studies with long-term follow-up are warranted to facilitate evidence-based guidelines to promote optimal patient outcomes.

#### Authors' Contributions

J.H.K., A.G.C., M.D.R., and P.J.D. contributed to conceptualization, writing-review & editing: all authors. A.G.C., M.D.R., and P.J.D. wrote original draft. J.H.K supervised the study. All authors A.G.C., M.D.R., P.J.D., J.H.K. contributed to the creation of the manuscript and meet the criteria for authorship.

#### Funding

None.

#### Patient Consent

Written consents for clinical photographs were obtained from patients.

**Conflict of Interest**

The corresponding author, J.H.K., is on the Scientific Advisory Board of Mesh Suture, Inc., and is a Consultant for Checkpoint Surgical, Inc., Neuraptive Therapeutics, Inc., and EDGe Surgical, Inc. Authors A.G.C., M.D.R., P.J.D. have no disclosures.

**References**

- Huntington TW. VI. case of bone transference: use of a segment of fibula to supply a defect in the tibia. *Ann Surg* 1905;41(02): 249–251
- Taylor GI, Miller GD, Ham FJ. The free vascularized bone graft. A clinical extension of microvascular techniques. *Plast Reconstr Surg* 1975;55(05):533–544
- Repo JP, Sommarhem A, Roine RP, Sintonen H, Halonen T, Tukiainen E. Free vascularized fibular graft is reliable in upper extremity long-bone reconstruction with good long-term outcomes. *J Reconstr Microsurg* 2016;32(07):513–519
- Barrera-Ochoa SS, Soldado F, Rodriguez-Baeza A, et al. Vascularized humeral periosteal flap to treat lateral humeral condyle nonunion: an anatomical study and report of two successfully-treated pediatric cases. *Microsurgery* 2019;39(02):156–159
- Hilven PH, Bayliss L, Cosker T, et al. The vascularised fibular graft for limb salvage after bone tumour surgery: a multicentre study. *Bone Joint J* 2015;97-B(06):853–861
- Inoue K, Suenaga N, Oizumi N, Tanaka Y, Minami A. A vascularized scapular graft for juvenile osteonecrosis of the humeral head. *J Shoulder Elbow Surg* 2012;21(04):e9–e13
- Fillingham Y, Jacobs J. Bone grafts and their substitutes. *Bone Joint J* 2016;98-B(1, Suppl A):6–9
- Karalashvili L, Kakabadze A, Uhrny M, Vyshnevskaya H, Ediberidze K, Kakabadze Z. Bone grafts for reconstruction of bone defects. (Review) *Georgian Med News* 2018;•••(282):44–49
- Martin WB, Sicard R, Namin SM, Ganey T. Methods of cryoprotectant preservation: allogeneic cellular bone grafts and potential effects. *BioMed Res Int* 2019;2019:5025398
- Roberts TT, Rosenbaum AJ. Bone grafts, bone substitutes and orthobiologics: the bridge between basic science and clinical advancements in fracture healing. *Organogenesis* 2012;8(04): 114–124
- Azi ML, Aprato A, Santi I, Kfuri M Jr, Masse A, Joeris A. Autologous bone graft in the treatment of post-traumatic bone defects: a systematic review and meta-analysis. *BMC Musculoskelet Disord* 2016;17(01):465
- Myeroff C, Archdeacon M. Autogenous bone graft: donor sites and techniques. *J Bone Joint Surg Am* 2011;93(23):2227–2236
- Ashman O, Phillips AM. Treatment of non-unions with bone defects: which option and why? *Injury* 2013;44(Suppl 1):S43–S45
- Klifto CS, Gandhi SD, Sapienza A. Bone graft options in upper-extremity surgery. *J Hand Surg Am* 2018;43(08):755–761.e2
- Allsopp BJ, Hunter-Smith DJ, Rozen WM. Vascularized versus nonvascularized bone grafts: what is the evidence? *Clin Orthop Relat Res* 2016;474(05):1319–1327
- Hovius SER, de Jong T. Bone grafts for scaphoid nonunion: an overview. *Hand Surg* 2015;20(02):222–227
- Merrell GA, Wolfe SW, Slade JF III. Treatment of scaphoid nonunions: quantitative meta-analysis of the literature. *J Hand Surg Am* 2002;27(04):685–691
- Munk B, Larsen CF. Bone grafting the scaphoid nonunion: a systematic review of 147 publications including 5,246 cases of scaphoid nonunion. *Acta Orthop Scand* 2004;75(05): 618–629
- Scholz AO, Gehrman S, Glombitza M, et al. Reconstruction of septic diaphyseal bone defects with the induced membrane technique. *Injury* 2015;46(Suppl 4):S121–S124
- Masquelet AC, Fitoussi F, Begue T, Muller GP. [Reconstruction of the long bones by the induced membrane and spongy autograft]. *Ann Chir Plast Esthet* 2000;45(03):346–353
- Karger C, Kishi T, Schneider L, Fitoussi F, Masquelet A-C. French Society of Orthopaedic Surgery and Traumatology (SoFCOT) Treatment of posttraumatic bone defects by the induced membrane technique. *Orthop Traumatol Surg Res* 2012;98(01): 97–102
- Pelissier P, Bollecker V, Martin D, Baudet J. [Foot reconstruction with the “bi-Masquelet” procedure]. *Ann Chir Plast Esthet* 2002; 47(04):304–307
- Petrella G, Tosi D, Pantaleoni F, Adani R. Vascularized bone grafts for post-traumatic defects in the upper extremity. *Arch Plast Surg* 2021;48(01):84–90
- Malizos KN, Zalavras CG, Soucacos PN, Beris AE, Urbaniak JR. Free vascularized fibular grafts for reconstruction of skeletal defects. *J Am Acad Orthop Surg* 2004;12(05):360–369
- Houdek MT, Wagner ER, Wyles CC, Nanos GP III, Moran SL. New options for vascularized bone reconstruction in the upper extremity. *Semin Plast Surg* 2015;29(01):20–29
- Karaismailoglu B, Fatih Guven M, Erenler M, Botanlioglu H. The use of pedicled vascularized bone grafts in the treatment of scaphoid nonunion: clinical results, graft options and indications. *EFORT Open Rev* 2020;5(01):1–8
- Zaidenberg C, Siebert JW, Angrigiani C. A new vascularized bone graft for scaphoid nonunion. *J Hand Surg Am* 1991;16(03): 474–478
- Alluri RK, Yin C, Iorio ML, Leland H, Mack WJ, Patel K. A critical appraisal of vascularized bone grafting for scaphoid nonunion. *J Wrist Surg* 2017;6(03):251–257
- Sheetz KK, Bishop AT, Berger RA. The arterial blood supply of the distal radius and ulna and its potential use in vascularized pedicled bone grafts. *J Hand Surg Am* 1995;20(06):902–914
- Waitayawinyu T, Robertson C, Chin SH, Schlenker JD, Pettrone S, Trumble TE. The detailed anatomy of the 1,2 intercompartmental supraretinacular artery for vascularized bone grafting of scaphoid nonunions. *J Hand Surg Am* 2008;33(02):168–174
- Chang MA, Bishop AT, Moran SL, Shin AY. The outcomes and complications of 1,2-intercompartmental supraretinacular artery pedicled vascularized bone grafting of scaphoid nonunions. *J Hand Surg Am* 2006;31(03):387–396
- Steinmann SP, Bishop AT, Berger RA. Use of the 1,2 intercompartmental supraretinacular artery as a vascularized pedicle bone graft for difficult scaphoid nonunion. *J Hand Surg Am* 2002;27(03):391–401
- Waitayawinyu T, McCallister WV, Katolik LI, Schlenker JD, Trumble TE. Outcome after vascularized bone grafting of scaphoid nonunions with avascular necrosis. *J Hand Surg Am* 2009;34(03):387–394
- Kawamura K, Chung KC. Treatment of scaphoid fractures and nonunions. *J Hand Surg Am* 2008;33(06):988–997
- Straw RG, Davis TRC, Dias JJ. Scaphoid nonunion: treatment with a pedicled vascularized bone graft based on the 1,2 intercompartmental supraretinacular branch of the radial artery. *J Hand Surg [Br]* 2002;27(05):413
- Boyer MI, von Schroeder HP, Axelrod TS. Scaphoid nonunion with avascular necrosis of the proximal pole. Treatment with a vascularized bone graft from the dorsum of the distal radius. *J Hand Surg [Br]* 1998;23(05):686–690
- Woon Tan JS, Tu YK. 2,3 intercompartmental supraretinacular artery pedicled vascularized bone graft for scaphoid nonunions. *Tech Hand Up Extrem Surg* 2013;17(02):62–67
- Moran SL, Cooney WP, Berger RA, Bishop AT, Shin AY. The use of the 4 + 5 extensor compartmental vascularized bone graft for the treatment of Kienboeck’s disease. *J Hand Surg Am* 2005;30(01):50–58
- Ye X, Feng J-T, Yin H-W, Qiu Y-Q, Shen Y-D, Xu W-D. Use of 4+5 extensor compartmental vascularized bone graft and K-wire

- fixation for treating stage II-III Kienböck's disease. *Hand Surg Rehabil* 2020;39(03):207–213
- 40 Özalp T, Öz Ç, Kale G, Erkan S. Scaphoid nonunion treated with vascularized bone graft from dorsal radius. *Injury* 2015;46 (Suppl 2):S47–S52
  - 41 Sotereanos DG, Darlis NA, Dailiana ZH, Sarris IK, Malizos KN. A capsular-based vascularized distal radius graft for proximal pole scaphoid pseudarthrosis. *J Hand Surg Am* 2006;31(04):580–587
  - 42 Kuhlmann JN, Mimoun M, Boabighi A, Baux S. Vascularized bone graft pedicled on the volar carpal artery for non-union of the scaphoid. *J Hand Surg [Br]* 1987;12(02):203–210
  - 43 Mathoulin C, Haerle M. Vascularized bone graft from the palmar carpal artery for treatment of scaphoid nonunion. *J Hand Surg [Br]* 1998;23(03):318–323
  - 44 Dailiana ZH, Malizos KN, Zachos V, Varitimidis SE, Hantes M, Karantanas A. Vascularized bone grafts from the palmar radius for the treatment of waist nonunions of the scaphoid. *J Hand Surg Am* 2006;31(03):397–404
  - 45 Malizos KN, Zachos V, Dailiana ZH, et al. Scaphoid nonunions: management with vascularized bone grafts from the distal radius: a clinical and functional outcome study. *Plast Reconstr Surg* 2007;119(05):1513–1525
  - 46 Mathoulin C, Sallen V, Haerle M. Revascularisation of the lunate in Kienböck's disease by a vascularized bone graft harvested from the volar aspect of the radius: results after a minimum of five years follow-up. *Rev Chir Orthop Repar Appar* 2007;93:141
  - 47 Kawai H, Yamamoto K. Pronator quadratus pedicled bone graft for old scaphoid fractures. *J Bone Joint Surg Br* 1988;70(05):829–831
  - 48 Noaman HH, Shiha AE, Ibrahim AKH. Functional outcomes of nonunion scaphoid fracture treated by pronator quadratus pedicled bone graft. *Ann Plast Surg* 2011;66(01):47–52
  - 49 Lee SK, Park JS, Choy WS. Scaphoid fracture nonunion treated with pronator quadratus pedicled vascularized bone graft and headless compression screw. *Ann Plast Surg* 2015;74(06):665–671
  - 50 Malizos KN, Dailiana ZH, Innocenti M, Mathoulin CL, Mattar R Jr, Sauerbier M. Vascularized bone grafts for upper limb reconstruction: defects at the distal radius, wrist, and hand. *J Hand Surg Am* 2010;35(10):1710–1718
  - 51 Saffar P. [Replacement of the semilunar bone by the pisiform. Description of a new technique for the treatment of Kienböck's disease]. *Ann Chir Main* 1982;1(03):276–279
  - 52 Tan Z, Xiang Z, Huang F, Yang Z, Xiao C, Duan X. Long-term results of vascularized os pisiform transfer for advanced Kienböck disease after follow-up for at least 15 years: a case series. *Medicine (Baltimore)* 2018;97(48):e13229
  - 53 Pierer G, Steffen J, Hoflehner H. The vascular blood supply of the second metacarpal bone: anatomic basis for a new vascularized bone graft in hand surgery. An anatomical study in cadavers. *Surg Radiol Anat* 1992;14(02):103–112
  - 54 Brunelli F, Mathoulin C, Saffar P. [Description of a vascularized bone graft taken from the head of the 2nd metacarpal bone]. *Ann Chir Main Memb Super* 1992;11(01):40–45
  - 55 Khan K, Riaz M, Small JO. The use of the second dorsal metacarpal artery for vascularized bone graft. An anatomical study. *J Hand Surg [Br]* 1998;23(03):308–310
  - 56 Pistré V, Réau AF, Pélissier P, Martin D, Baudet J. [Vascularized bone pedicle grafts of the hand and wrist: literature review and new donor sites]. *Chir Main* 2001;20(04):263–271
  - 57 Santa-Comba A, Amarante J, Silva A, Rodrigues J. Reverse dorsal metacarpal osteocutaneous flap. *Br J Plast Surg* 1997;50(07):555–558
  - 58 Bengoechea-Beeby MP, Cepeda-Uña J, Abascal-Zuloaga A. Vascularized bone graft from the index metacarpal for Kienböck's disease: a case report. *J Hand Surg Am* 2001;26(03):437–443
  - 59 Innocenti M, Delcroix L, Romano GF. Epiphyseal transplant: harvesting technique of the proximal fibula based on the anterior tibial artery. *Microsurgery* 2005;25(04):284–292
  - 60 Innocenti M, Mori F, Raffaini M, Lucattelli E, Innocenti A. Mandibular ramus and condyle reconstruction with vascularized proximal fibular epiphyseal transfer in the pediatric patient: a case report. *Microsurgery* 2020;40(07):818–822
  - 61 Bumbasirevic M, Stevanovic M, Bumbasirevic V, Lesic A, Atkinson HDE. Free vascularised fibular grafts in orthopaedics. *Int Orthop* 2014;38(06):1277–1282
  - 62 Abou-Foul AK, Borumandi F. Anatomical variants of lower limb vasculature and implications for free fibula flap: systematic review and critical analysis. *Microsurgery* 2016;36(02):165–172
  - 63 Korompilias AV, Paschos NK, Lykissas MG, Kostas-Agnantis I, Vekris MD, Beris AE. Recent updates of surgical techniques and applications of free vascularized fibular graft in extremity and trunk reconstruction. *Microsurgery* 2011;31(03):171–175
  - 64 Liu S, Tao S, Tan J, Hu X, Liu H, Li Z. Long-term follow-up of fibular graft for the reconstruction of bone defects. *Medicine (Baltimore)* 2018;97(40):e12605
  - 65 Capanna R, Bufalini C, Campanacci M. A new technique for reconstructions of large metadiaphyseal bone defects. *Orthop Traumatol* 1993;2:159–177
  - 66 Jones DB Jr, Bürger H, Bishop AT, Shin AY. Treatment of scaphoid waist nonunions with an avascular proximal pole and carpal collapse. Surgical technique. *J Bone Joint Surg Am* 2009;91 (Suppl 2):169–183
  - 67 Tonoli C, Bechara AHS, Rossanez R, Belangero WD, Livani B. Use of the vascularized iliac-crest flap in musculoskeletal lesions. *BioMed Res Int* 2013;2013:237146
  - 68 Harpf C, Gabl M, Reinhart C, et al. Small free vascularized iliac crest bone grafts in reconstruction of the scaphoid bone: a retrospective study in 60 cases. *Plast Reconstr Surg* 2001;108 (03):664–674
  - 69 Sakai K, Doi K, Kawai S. Free vascularized thin corticoperiosteal graft. *Plast Reconstr Surg* 1991;87(02):290–298
  - 70 Oh C, Pulos N, Bishop AT, Shin AY. Intraoperative anatomy of the vascular supply to the medial femoral condyle. *J Plast Reconstr Aesthet Surg* 2019;72(09):1503–1508
  - 71 Yamamoto H, Jones DB Jr, Moran SL, Bishop AT, Shin AY. The arterial anatomy of the medial femoral condyle and its clinical implications. *J Hand Surg Eur Vol* 2010;35(07):569–574
  - 72 Ziegler T, Kamolz L-P, Vasilyeva A, Schintler M, Neuwirth M, Parvizi D. Descending genicular artery. Branching patterns and measuring parameters: a systematic review and meta-analysis of several anatomical studies. *J Plast Reconstr Aesthet Surg* 2018;71(07):967–975
  - 73 Iorio ML, Masden DL, Higgins JP. Cutaneous angiosome territory of the medial femoral condyle osteocutaneous flap. *J Hand Surg Am* 2012;37(05):1033–1041
  - 74 Hsu C-C, Tseng J, Lin Y-T. Chimeric medial femoral condyle osteocutaneous flap for reconstruction of multiple metacarpal defects. *J Hand Surg Am* 2018;43(08):781.e1–781.e9
  - 75 Bürger HK, Windhofer C, Gaggli AJ, Higgins JP. Vascularized medial femoral trochlea osteocartilaginous flap reconstruction of proximal pole scaphoid nonunions. *J Hand Surg Am* 2013;38 (04):690–700
  - 76 Higgins JP, Bürger HK. Osteochondral flaps from the distal femur: expanding applications, harvest sites, and indications. *J Reconstr Microsurg* 2014;30(07):483–490
  - 77 Higgins JP, Bürger HK. Medial femoral trochlea osteochondral flap: applications for scaphoid and lunate reconstruction. *Clin Plast Surg* 2020;47(04):491–499
  - 78 Hugon S, Koninckx A, Barbier O. Vascularized osteochondral graft from the medial femoral trochlea: anatomical study and clinical perspectives. *Surg Radiol Anat* 2010;32(09):817–825
  - 79 Källicke T, Bürger H, Müller EJ. [A new vascularized cartilage-bone-graft for scaphoid nonunion with avascular necrosis of the proximal pole. Description of a new type of surgical procedure]. *Unfallchirurg* 2008;111(03):201–205

- 80 Boghossian E, Stewart DA. The medial metaphyseal periosteal artery (MMPA): an alternate pedicle for the medial femoral trochlea flap. *J Hand Surg Am* 2021;46(11):1032.e1-1032.e3
- 81 Hill JR, Heckmann N, McKnight B, White EA, Ghiassi A, Patel BA. Medial femoral trochlea osteochondral graft: a quantitative anatomic comparison to the proximal pole of the scaphoid. *J Wrist Surg* 2020;9(04):283-288
- 82 Shin JJ, Haro M, Yanke AB, et al. Topographic analysis of the capitellum and distal femoral condyle: finding the best match for treating osteochondral defects of the humeral capitellum. *Arthroscopy* 2015;31(05):843-849
- 83 Mehio G, Morsy M, Cayci C, et al. Donor-site morbidity and functional status following medial femoral condyle flap harvest. *Plast Reconstr Surg* 2018;142(05):734e-741e
- 84 Rao SS, Sexton CC, Higgins JP. Medial femoral condyle flap donor-site morbidity: a radiographic assessment. *Plast Reconstr Surg* 2013;131(03):357e-362e
- 85 Son JH, Giladi AM, Higgins JP. Iatrogenic femur fracture following medial femoral condyle flap harvest eventually requiring total knee arthroplasty in one patient. *J Hand Surg Eur Vol* 2019;44(03):320-321
- 86 Parvizi D, Vasilyeva A, Wurzer P, et al. Anatomy of the vascularized lateral femoral condyle flap. *Plast Reconstr Surg* 2016;137(06):1024e-1032e
- 87 Wong VW, Bürger HK, Iorio ML, Higgins JP. Lateral femoral condyle flap: an alternative source of vascularized bone from the distal femur. *J Hand Surg Am* 2015;40(10):1972-1980
- 88 Higgins JP, Bürger HK. The use of osteochondral flaps in the treatment of carpal disorders. *J Hand Surg Eur Vol* 2018;43(01):48-56
- 89 Windhofer CM, Anoshina M, Ivusits P, Bürger HP. The free vascularized lateral femoral trochlea osteochondral graft: a reliable alternative for Stage III Kienböck's disease. *J Hand Surg Eur Vol* 2021;46(10):1032-1041
- 90 Kawamura K, Kawate K, Yajima H, Kobata Y, Takakura Y. Vascularized scapular grafting for treatment of osteonecrosis of the humeral head. *J Reconstr Microsurg* 2008;24(08):559-564
- 91 Swartz WM, Banis JC, Newton ED, Ramasastry SS, Jones NF, Acland R. The osteocutaneous scapular flap for mandibular and maxillary reconstruction. *Plast Reconstr Surg* 1986;77(04):530-545
- 92 Elia R, Di Taranto G, Amorosi V, et al. The versatility of the thoracodorsal artery based composite flaps with vascularized rib and a systematic review of the literature. *J Surg Oncol* 2019;120(03):527-539
- 93 Sia WT, Xu GG, Puhaindran ME, Tan BK, Cheng MHW, Chew WYC. Reconstruction of extensive soft-tissue defects with concomitant bone defects in the lower extremity with the latissimus dorsi-serratus anterior-rib free flap. *J Reconstr Microsurg* 2015;31(06):407-413
- 94 Werner CML, Favre P, van Lenthe HG, Dumont CE. Pedicled vascularized rib transfer for reconstruction of clavicle nonunions with bony defects: anatomical and biomechanical considerations. *Plast Reconstr Surg* 2007;120(01):173-180
- 95 Guelinckx PJ, Sinsel NK. The "Eve" procedure: the transfer of vascularized seventh rib, fascia, cartilage, and serratus muscle to reconstruct difficult defects. *Plast Reconstr Surg* 1996;97(03):527-535
- 96 Thomas WO, Harris CN, Moline S, Harper LL, Parker JA. Versatility of the microvascular serratus anterior muscle vascularized rib flap (SARIB) for multifaceted requirement reconstructions. *Ann Plast Surg* 1998;40(01):23-27
- 97 Shiokawa I, Minabe T, Momosawa A, Mashiko T. Muscular pedicled lateral chest composite flap—a new nonmicrosurgical option for forearm salvage. *Plast Reconstr Surg Glob Open* 2015;2(12):e267
- 98 Spiker AM, Humbyrd CJ, Osgood GM, Yang SC, Deune EG. Reconstruction of ulnar defect with vascularized rib graft: a case report. *Microsurgery* 2017;37(02):160-164
- 99 Georgescu AV, Ignatiadis I, Ileana M, Irina C, Filip A, Olariu R. Long-term results after muscle-rib flap transfer for reconstruction of composite limb defects. *Microsurgery* 2011;31(03):218-222
- 100 Hennerbichler A, Etzer C, Gruber S, Brenner E, Papp C, Gaber O. Lateral arm flap: analysis of its anatomy and modification using a vascularized fragment of the distal humerus. *Clin Anat* 2003;16(03):204-214
- 101 Haas F, Rappal T, Koch H, Pittler P, Scharnagl E. Free osteocutaneous lateral arm flap: anatomy and clinical applications. *Microsurgery* 2003;23(02):87-95
- 102 Windhofer C, Michlits W, Karlbauer A, Papp C. Treatment of segmental bone and soft-tissue defects of the forearm with the free osteocutaneous lateral arm flap. *J Trauma* 2011;70(05):1286-1290
- 103 Okada M, Takamatsu K, Oebisu N, Nakamura H. Reversed lateral upper arm flap with a vascularised fragment of the humerus for reconstruction of ulna shaft fracture after resection of malignant tumour: a case report. *J Plast Reconstr Aesthet Surg* 2011 Oct;64(10):1373-1376
- 104 Matev I. The osteocutaneous pedicle forearm flap. *J Hand Surg [Br]* 1985;10(02):179-182
- 105 Biemer E, Stock W. Total thumb reconstruction: a one-stage reconstruction using an osteo-cutaneous forearm flap. *Br J Plast Surg* 1983;36(01):52-55
- 106 Chacha B, Soin K, Tan KC. One stage reconstruction of intercalated defect of the thumb using the osteocutaneous radial forearm flap. *J Hand Surg [Br]* 1987;12(01):86-92
- 107 Yajima H, Tamai S, Ono H, Kizaki K. Vascularized bone grafts to the upper extremities. *Plast Reconstr Surg* 1998;101(03):727-735, discussion 736-737
- 108 Timmons MJ, Missotten FE, Poole MD, Davies DM. Complications of radial forearm flap donor sites. *Br J Plast Surg* 1986;39(02):176-178
- 109 Momberger NG, Smith J, Coleman DA. Vascularized fibular grafts for salvage reconstruction of clavicle nonunion. *J Shoulder Elbow Surg* 2000;9(05):389-394
- 110 Arenas-Miquelez A, Karargyris O, Olariu R, Zumstein M. Free vascularized fibular graft for reconstruction of the lateral clavicle: a case report and review of the literature. *JBJS Case Connect* 2019;9(04):e0330
- 111 Abarca J, Valle P, Valenti P. Clavicular reconstruction with free fibula flap: a report of four cases and review of the literature. *Injury* 2013;44(03):283-287
- 112 Taylor GI, Seneviratne S, Jones I, White D, Mah E, Shayan R. Free vascularized fibula flap reconstruction of the clavicle combined with biceps tendon repair of the conoid ligament and customized plate stabilization of the acromioclavicular joint. *Plast Reconstr Surg* 2009;123(03):113e-115e
- 113 Lenoir H, Williams T, Kerfant N, Robert M, Le Nen D. Free vascularized fibular graft as a salvage procedure for large clavicular defect: a two cases report. *Orthop Traumatol Surg Res* 2013;99(07):859-863
- 114 Jaloux C, Bettex Q, Levadoux M, et al. Free vascularized medial femoral condyle corticoperiosteal flap with non-vascularized iliac crest graft for the treatment of recalcitrant clavicle non-union. *J Plast Reconstr Aesthet Surg* 2020;73(07):1232-1238
- 115 Deng AD, Innocenti M, Arora R, Gabl M, Tang JB. Vascularized small-bone transfers for fracture nonunion and bony defects. *Clin Plast Surg* 2020;47(04):501-520
- 116 Medrykowski F, Barbary S, Gibert N, Lascombes P, Dautel G. Vascularized proximal fibular epiphyseal transfer: two cases. *Orthop Traumatol Surg Res* 2012;98(06):728-732
- 117 Innocenti M, Delcroix L, Romano GF, Capanna R. Vascularized epiphyseal transplant. *Orthop Clin North Am* 2007;38(01):95-101, vii viii.

- 118 Ye L, Taylor GI. A 10-year follow-up of a free vascularized fibula flap clavicle reconstruction in an adult. *Plast Reconstr Surg Glob Open* 2017;5(04):e1317
- 119 Kazmers NH, Thibaudeau S, Gerety P, Lambi AG, Levin LS. Versatility of the medial femoral condyle flap for extremity reconstruction and identification of risk factors for nonunion, delayed time to union, and complications. *Ann Plast Surg* 2018;80(04):364–372
- 120 Quintero JI, Childs D, Moreno R. The medial femoral condyle free flap: an excellent option for difficult cases: case series. *SAGE Open Med Case Rep* 2020;8:X20933763
- 121 Landau MJ, Badash I, Yin C, Alluri RK, Patel KM. Free vascularized fibula grafting in the operative treatment of malignant bone tumors of the upper extremity: A systematic review of outcomes and complications. *J Surg Oncol* 2018;117(07):1432–1439
- 122 Bilgin SS. Reconstruction of proximal humeral defects with shoulder arthrodesis using free vascularized fibular graft. *J Bone Joint Surg Am* 2012;94(13):e94
- 123 Claxton MR, Shirley MB, Bakri K, Rose PS, Moran SL, Houdek MT. Utility of the free vascularized fibula flap to reconstruct oncologic defects in the upper extremity. *Anticancer Res* 2020;40(05):2751–2755
- 124 Stevenson JD, Doxey R, Abudu A, et al. Vascularized fibular epiphyseal transfer for proximal humeral reconstruction in children with a primary sarcoma of bone. *Bone Joint J* 2018;100-B(04):535–541
- 125 Kurlander DE, Shue S, Schwarz GS, Ghaznavi AM. Vascularized fibula epiphysis transfer for pediatric extremity reconstruction: a systematic review and meta-analysis. *Ann Plast Surg* 2019;82(03):344–351
- 126 Gan AWT, Puhaindran ME, Pho RWH. The reconstruction of large bone defects in the upper limb. *Injury* 2013;44(03):313–317
- 127 Ciclamini D, Tos P, Guzzini M, Soldati A, Crosio A, Battiston B. The medial femoral condyle free corticoperiosteal flap versus traditional bone graft for treatment of nonunions of long bones: a retrospective comparative cohort study. *Injury* 2019;50(Suppl 5):S54–S58
- 128 Henry M. Vascularized medial femoral condyle bone graft for resistant nonunion of the distal radius. *J Hand Surg Asian Pac Vol* 2017;22(01):23–28
- 129 Amadio PC, Moran SL. Fractures of the carpal bone. In: Green DP, editor. *Operative hand surgery*. 5th ed. Philadelphia: Churchill Livingstone; 2005:711–779
- 130 Pao VS, Chang J. Scaphoid nonunion: diagnosis and treatment. *Plast Reconstr Surg* 2003;112(06):1666–1676, quiz 1677, discussion 1678–1679
- 131 Mattos D, Ko JH, Iorio ML. Wrist arthrodesis with the medial femoral condyle flap: Outcomes of vascularized bone grafting for osteomyelitis. *Microsurgery* 2019;39(01):32–38
- 132 Yajima H, Tamai S, Yamauchi T, Mizumoto S. Osteocutaneous radial forearm flap for hand reconstruction. *J Hand Surg Am* 1999;24(03):594–603
- 133 Dailiana ZH, Malizos KN, Urbaniak JR. Vascularized periosteal flaps of distal forearm and hand. *J Trauma* 2005;58(01):76–82
- 134 Del Piñal F, García-Bernal FJ, Delgado J, Sanmartín M, Regalado J. Reconstruction of the distal radius facet by a free vascularized osteochondral autograft: anatomic study and report of a patient. *J Hand Surg Am* 2005;30(06):1200–1210
- 135 Smith PJ, Goodacre TE. Free vascularised toe joint transfer for reconstruction of the metacarpo-phalangeal joint. *J Hand Surg [Br]* 1990;15(02):262–267
- 136 Foucher G, Lenoble E, Smith D. Free and island vascularized joint transfer for proximal interphalangeal reconstruction: a series of 27 cases. *J Hand Surg Am* 1994;19(01):8–16
- 137 Tsai TM, Lim BH. Free vascularized transfer of the metatarsophalangeal and proximal interphalangeal joints of the second toe for reconstruction of the metacarpophalangeal joints of the thumb and index finger using a single vascular pedicle. *Plast Reconstr Surg* 1996;98(06):1080–1086