



Using Virtual Reality to Teach Sinus Anatomy

Kei Hosoya^{1,2} Taro Komachi^{1,2} Maki Sugimoto³ Ayaho Yoshino^{1,2} Junko Kuya^{1,2} Kimihiro Okubo¹

¹ Department of Head and Neck and Sensory Organ Science, Graduate School of Medicine, Nippon Medical School, Tokyo, Japan

² Department of Otolaryngology, Nippon Medical School Chiba Hokusoh Hospital, Chiba, Japan

³ Innovation Lab, Teikyo University Okinaga Research Institute, Tokyo, Japan

Address for correspondence Kei Hosoya, Department of Head and Neck and Sensory Organ Science, Graduate School of Medicine, Nippon Medical School, 1-1-5 Sendagi, Bunkyo-ku, Tokyo 113-8603, Japan (e-mail: s00-073@nms.ac.jp).

Int J Pract Otolaryngol 2022;5:e45–e50.

Abstract

Anatomy education is a crucial part of the curriculum for medical students, and it is essential for surgeons to perform safe surgery. The anatomy of the sinus cavity is complicated and cannot be easily understood through cadaver dissection practice and reading of surgical anatomy textbooks. Therefore, the development of methods to effectively teach the anatomy of such complex structures is essential for performing safe medical procedures. This study aimed to investigate whether the use of virtual reality (VR) in an educational course on paranasal sinus anatomy could contribute to the understanding and learning efficiency of dissection of the complex sinus anatomy. We devised a system to observe the paranasal sinuses in the VR space by polygonizing the shape of the sinus cavity using computed tomography images of the sinuses. Medical students moved around the VR space and viewed the sinuses from different angles using the VR system; notably, this is impossible in a conventional anatomy laboratory. A questionnaire was administered to 27 medical students (15 men and 12 women; mean age, 24.9 years) to evaluate their understanding of the sinus anatomy and the number of times they had experienced VR and used VR systems. We found that more than 70% of the students had never used VR before, but they could easily use it even if they were unfamiliar with the operation of the VR system, and the learning process was enjoyable and efficient. Thus, the VR application could be a useful tool for educating medical students.

Keywords

- ▶ medical education
- ▶ virtual reality
- ▶ anatomy
- ▶ sinus

Introduction

Developing an adequate understanding of anatomy is the main goal of medical education; thus, anatomy is an important subject in the medical school curriculum. Clinicians require the knowledge of anatomy as a foundation to acquire clinical competence; moreover, anatomy is essential for surgeons to perform safe surgery. However, in recent years, the time devoted to anatomy education has become insuffi-

cient owing to ethical issues, high costs, time constraints, and other factors.¹ Anatomy education requires constant review and analysis to determine the most appropriate education tools and approaches for the learning process.²

The cadaver dissection-based approach has been the principal teaching method in anatomy education for more than 400 years.³ Moreover, the practice of anatomy serves as a bridge toward clinical training and provides hands-on experience of surgical procedures. However, owing to the

received
April 26, 2022
accepted
September 14, 2022

DOI <https://doi.org/10.1055/s-0042-1759820>.
ISSN 2569-1783.

© 2022. The Author(s).

This is an open access article published by Thieme under the terms of the Creative Commons Attribution-NonDerivative-NonCommercial-License, permitting copying and reproduction so long as the original work is given appropriate credit. Contents may not be used for commercial purposes, or adapted, remixed, transformed or built upon. (<https://creativecommons.org/licenses/by-nc-nd/4.0/>)

Georg Thieme Verlag KG, Rüdigerstraße 14, 70469 Stuttgart, Germany

limited availability of resources for anatomy courses, many medical schools have excluded costly and time-consuming cadaver-based anatomy training and have increasingly adopted alternative teaching methods, such as dissections, medical imaging, and multimedia resources.⁴ Given that computed tomography (CT), magnetic resonance imaging, and ultrasonography are now available to visualize the internal structures of the human body in two and three dimensions, students can link basic anatomical knowledge to such images to better understand its clinical relevance.⁵ These imaging techniques are of great importance because they can increase students' understanding of spatial relationships between anatomical structures, the efficiency of learning anatomy, and interest in anatomy.⁶ Zuckerman et al reported that the use of CT images in an endoscopic sinus surgery training course effectively increased the surgeons' comfort levels and unification of paranasal sinuses.⁷ As paranasal sinuses have complex three-dimensional structures that differ according to individual cases,⁸ understanding of these structures is not easy for medical students and less-experienced doctors.

Virtual reality (VR) technology for creating environments that are not real and do not really exist but stimulate users' senses to create essentially the same feeling as the real ones has emerged as a result of technological innovations in recent years.⁹ Moreover, VR spaces can provide visual experiences like never before, such as immersive experiences of walking around in a remote location in another country or in a virtual world.⁹ The areas of applications of VR based on these characteristics include medical education, clinical practice, and amusement.¹⁰ This technology enables students to visualize, dissect, and interact with simulated objects in artificial three-dimensional spaces.¹¹

Therefore, we developed a system to three-dimensionally display the anatomy of paranasal sinuses using VR with the expectation that the combined use of CT and VR images of paranasal sinuses may facilitate a deeper understanding of the anatomy. This study aimed to determine whether the use

of VR in a training course on paranasal sinus anatomy facilitates the assimilation of course-taught knowledge and helps improve the ability to interpret related images.

Materials and Methods

Overall, 27 fourth- and fifth-year medical students (15 men and 12 women; mean age, 24.9 years) who completed clinical training at the Department of Otolaryngology, Nippon Medical School Chiba Hokusoh Hospital, participated in this study. The participants were first taught and provided explanations about the human anatomy using paranasal sinus CT images. Subsequently, VR was used for teaching and explaining about the anatomy (►Fig. 1). The participants filled out a questionnaire based on a five-point scale and entered free descriptions of their evaluation of the courses using CT images alone and the combination of CT and VR images in terms of the comprehensibility of spatial relationships of the paranasal sinuses, impression of VR use, and learning (►Table 1). For the eyestrain and visually induced motion sickness items, 4 points were given to the rightmost response ("very tired" or "felt very sick"), and 0 were given to the leftmost response. For other items, 4 were given to the leftmost response ("understood very well"), and 0 were given to the rightmost response.

The study protocol was approved by the Ethical Review Board of Nippon Medical School Chiba Hokusoh Hospital (approval number: 709). All participants provided informed consent for participation in this study.

We prepared three-dimensional images as follows. Radiopacity levels in CT images were processed in terms of gray scale intensity data. DICOM files of paranasal sinus CT (Scenaria, Hitachi Medical Corporation, Japan) images with a slice thickness of 0.625 mm were processed using image processing software OsiriX (version 10.0, Pixmeo SARL, Switzerland) to extract CT values for the paranasal sinuses (►Fig. 2). The three-dimensional surface rendering function was used to export the surface data as polygon files.¹² When

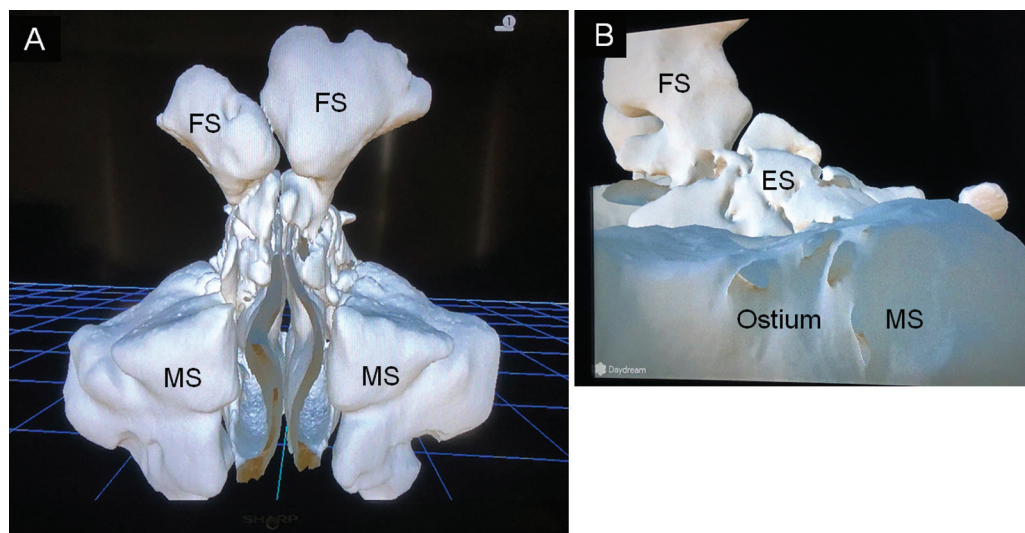


Fig. 1 Paranasal sinuses floating in virtual reality space. (A) Observing paranasal sinuses from the front. (B) Observing paranasal sinuses after entering a maxillary sinus from the left side. FS, frontal sinus; MS, maxillary sinus; ES, ethmoid sinus.

Table 1 Questionnaire survey

For each question, please circle the option applicable to you	
(1) Level of understanding of paranasal sinus anatomy	
With CT images	Understood (very/fairly/neither/fairly/very) Not understood
With both CT and VR images	Understood (very/fairly/neither/fairly/very) Not understood
(2) VR	
Used VR	(≥50 times/≥10 times/5–9 times/ 1–4 times/never before)
Operation was	Easy (very/fairly/neither/fairly/very) Difficult
Eyes were	Not tired (very/fairly/neither/fairly/very) Tired
While viewing the images, I felt	Not sick (very/fairly/neither/fairly/very) Sick
(3) Learning	
Learning was	Enjoyable (very/fairly/neither/fairly/very) Not enjoyable
Learning was	Efficient (very/fairly/neither/fairly/very) Inefficient
(4) Please leave your opinions or suggestions for further improvements	

Abbreviations: CT, computed tomography; VR, virtual reality.

the interior of the paranasal sinuses was extracted, the air outside the face, which has the same CT value as that of the interior of the paranasal sinuses, was extracted simultaneously. All parts other than the paranasal sinuses were extracted using the three-dimensional sculpturing software Meshmixer (Autodesk, Inc., USA). The resulting data were converted into images available for three-dimensional viewing on VR using the Holoeyes XR application (Holoeyes, Japan).¹³ The VR images were observed using the Mirage Solo with Daydream (Lenovo Japan, Japan) VR headsets.

Graphical representations in the figures present the values in terms of mean ± standard deviation. The Mann-Whitney U-test was used for analyzing the levels of understanding of the anatomy (Prism 8 statistical software), and *p*-value of <0.05 was considered significant.

Results

The mean scores for the understanding of the anatomy using CT images alone and the combination of CT and VR images were 2.2 and 3.6, respectively; these scores were significantly different (►Fig. 3, *p* < 0.001). Notably, 70.4% (19) and 25.9% (7) of participants reported using VR for the first time and one to four times previously, respectively. Thus, more than 95% of participants had no or little experience of using VR. The mean score for the operability was 3.1, with 74.1% (20) of participants reporting that they could use the VR tool without any difficulty. Regarding eyestrain, 51.8% (14) participants experienced no eyestrain,

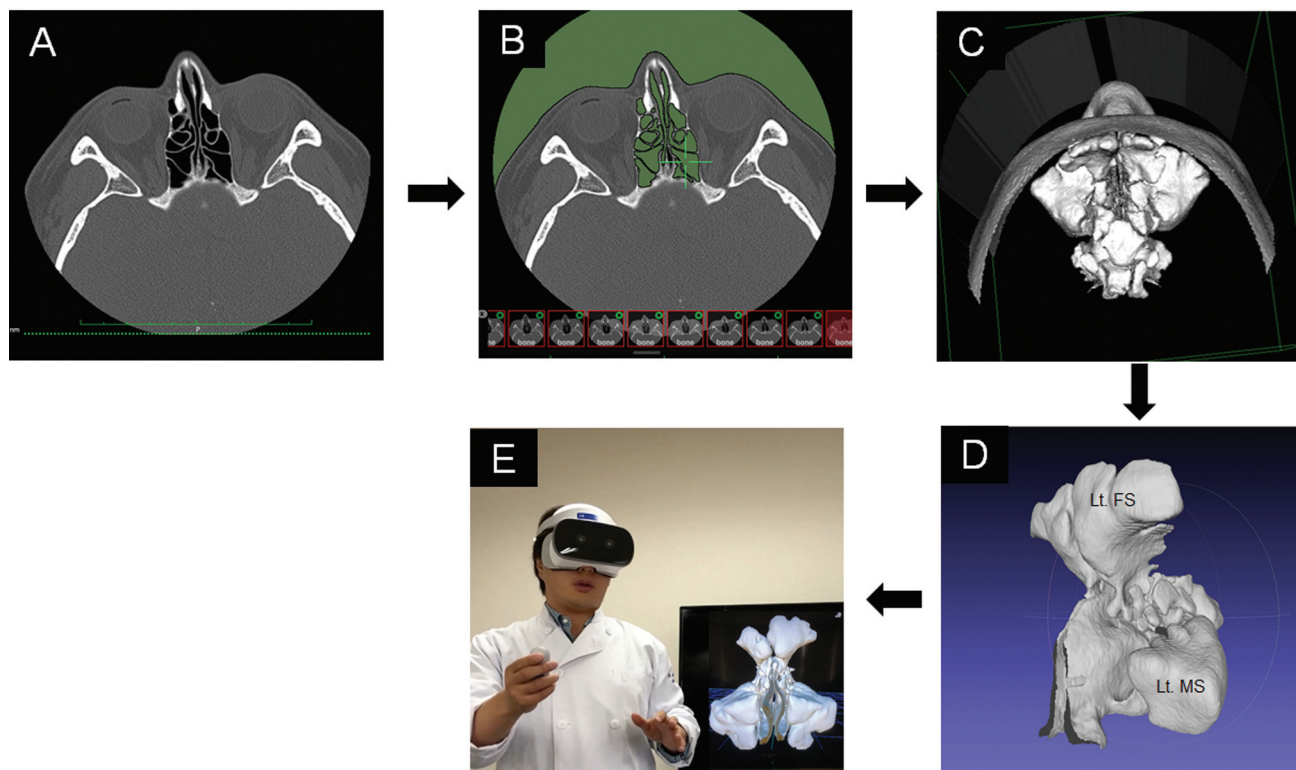


Fig. 2 Data creation method. (A) A CT image visualized using OsiriX. (B) Extraction of areas with a CT value of -1000 (air) (green). (C) Drawing the surface with a CT value of -1000 (surface rendering). (D) Removal of irrelevant parts using the Meshmixer. (E) Visualizing the sinus model on a VR headset using the Holoeyes XR application. CT, computed tomography; VR, virtual reality; Lt, left; FS, frontal sinus; MS, maxillary sinus.

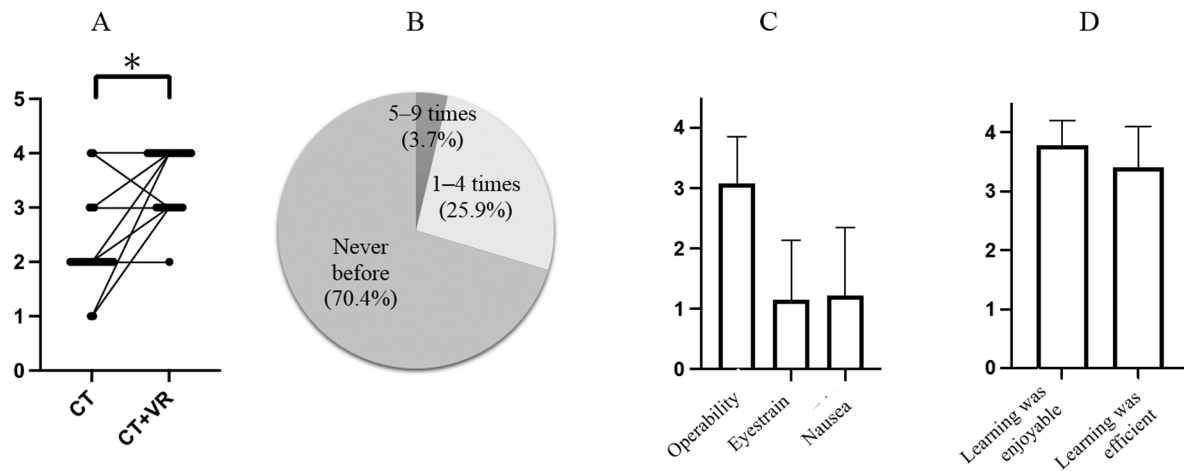


Fig. 3 Questionnaire responses. (A) The understanding level of the sinus anatomy was increased by the combined use of CT and VR ($p < 0.001$). (B) Overall, 96.3% of the participants used VR for ≤ 4 times. (C) Scores for VR operability, eyestrain, and nausea were 3.1 ± 0.8 , 1.1 ± 1.0 , and 1.2 ± 1.2 , respectively. (D) In the evaluation of VR-based learning, mean scores for enjoyment and efficiency were 3.8 ± 0.4 and 3.4 ± 0.7 , respectively. *Mann–Whitney U-test. CT, computed tomography; VR, virtual reality.

whereas 3.7% (1) experienced mild eyestrain. Regarding visually induced motion sickness, the mean score was 1.2, with 0% (0) and 14.8% (4) of participants reporting that they felt very and fairly sick, respectively, while viewing images. All participants felt that learning was enjoyable; of these, 88.9% reported that learning was efficient. The free descriptions of participants included the following: “It was very easy to understand because I could touch and rotate (sinuses) as well as remove a cavity”; “Understandability may be even better if there was a version with paranasal sinuses only and a version including other parts”; “It would be even better if the anatomy of blood vessels and nerves can be seen”; “It was enjoyable”; “Three-dimensional structures were easily understood”; and “It would be great if I can use this for my learning in the future.”

Discussion

The perceived understanding of paranasal sinus anatomy after learning with the combination of CT and VR images was significantly higher than that after learning with CT images alone. Notably, even participants who were unfamiliar with VR handling could operate it easily, and they found VR-based learning enjoyable and efficient. However, some participants experienced VR motion sickness.

Furthermore, even surgeons who perform endoscopic sinus surgery cannot easily obtain three-dimensional images of paranasal sinuses. These surgeons believe that the reconstruction and visualization of three-dimensional anatomical structures is time-consuming as it requires extensive experience in interpreting CT images and performing surgeries. Therefore, it is important to pay attention to the paranasal sinuses in anatomical practice. However, the cadaver dissection-based training is disadvantageous given that it is costly and time-consuming. Because CT images can improve understanding of spatial positional relationships, they are useful as teaching materials to facilitate detailed under-

standing of the complex structures varying in size and surrounded by bones, such as paranasal sinuses.¹⁴ In the present study, the additional use of VR images improved participants’ perceived levels of understanding of the spatial positional relationships of the paranasal sinuses. Notably, VR allows users to visualize and dissect objects in an artificial three-dimensional space.¹¹ The development of VR systems for anatomy education has advanced recently,¹⁵ and some studies have reported that the VR applications are useful and cost-effective in anatomy education and that students favor the use of virtual anatomy.^{16–18} In the present study, the Holoeyes system with three-dimensional organ polygon models was used for VR.¹² The use of polygon models allowed users to have immersive learning experiences, wherein they could move freely in the VR space, thereby facilitating their understanding of the paranasal sinus structures. Such experiences may have helped participants improve spatial recognition skills as VR images were effective in providing understanding of the shape and size of the paranasal sinuses, which cannot be learned with images on flat monitors. Spatial recognition ability has not been a major topic of interest in previous educational systems,¹⁹ but it is considered an important skill that should be improved during anatomy²⁰ and surgical training.¹²

A key distinctive feature of VR is the enjoyment it offers to its users. Creativity is stimulated by this enjoyment and humor as the brain is relaxed and free.²¹ Enjoyable learning has been reported to improve motivation and concentration as well as promote the absorption and retention of the acquired knowledge.²² In the present study, all participants found that VR-based learning was enjoyable, as evident by the comment “VR was enjoyable” among free descriptions. Maresky et al reported that 90.5% of the participants in a study on VR-based heart anatomy learning agreed with the statement “I learn more than I enjoy.”²³ Enjoying learning and learning through one’s own efforts is a key element for successful problem-oriented

learning in medical education.²⁴ Thus, VR may be an excellent tool for medical education.

In the present study, 3.7 and 14.8% of participants experienced eyestrain and VR sickness, respectively. VR headsets demonstrate a three-dimensional image based on binocular disparity by displaying a two-dimensional image separately for each eye (right or left).²⁵ If the depth is too large, eyestrain may occur due to over-convergence. VR sickness belongs to motion sickness, in which spatial perception is disturbed, and nausea, vomiting, and dizziness occur because of discrepancies in vestibular information important for spatial recognition, audiovisual information, and depth perception information.^{9,26} The incidence of symptoms can be reduced by instructing users to avoid long-term use and rapid movement.

Lower capital expenditure for VR equipments, such as goggles, and advances in application development, such as simplified conversion of CT-derived point cloud data into polygon files, which are cross-sectional surface models, underlie recent rapid advances in VR-based medical education. In the present study, the time and cost of processing/creating data was approximately 5 hours and tens of thousands of yen, respectively. The latest Holoeyes XR application (as of April 1, 2022) allows users to rotate three-dimensional model images with their hands and attach/detach extra sinus structures, as mentioned by participants in their comments.¹³ Furthermore, VR-based learning has become increasingly simpler and more accessible.

This study has several limitations. First, images obtained from patients with sinusitis cannot be used. CT images of paranasal sinuses without inflammatory findings are suitable for extracting sinus structures as accurately as possible for VR image creation. Therefore, the use of VR images based on normal paranasal sinuses is more appropriate for educating medical students and less-experienced doctors than the combined use of VR and preoperative/intraoperative sinus CT images of patients with chronic sinusitis. Second, only subjective means were used to assess improved understanding of the anatomy. As a result, there was no objective evaluation, for example, an evaluation based on test score changes before and after VR use. Third, the sample size was small. Further studies involving doctors in postgraduate clinical training and less-experienced otolaryngologists in addition to medical students are needed. In the future, other useful applications might be included to review and test the anatomical nomenclature in VR.

Conclusion

The use of VR to learn the anatomy of the paranasal sinuses imparted a three-dimensional experience in the traditional learning of two-dimensional information, allowing users to learn and perceive improvements in their understanding in an enjoyable and efficient way. This learning method can strengthen spatial recognition ability, which is important for understanding anatomy and surgery, and it has the potential to become a useful educational tool for medical students.

Informed Consent

Informed consent was obtained from all participants prior to the study.

Conflict of Interest

M.S. is the CEO of Holoeyes Inc. M.S. receives research funding from Riverfield Inc. All other authors declare no conflict of interest.

References

- 1 Lockwood AM, Roberts AM. The anatomy demonstrator of the future: an examination of the role of the medically-qualified anatomy demonstrator in the context of tomorrow's doctors and modernizing medical careers. *Clin Anat* 2007;20(04):455-459
- 2 Moxham BJ, Plaisant O. Perception of medical students towards the clinical relevance of anatomy. *Clin Anat* 2007;20(05):560-564
- 3 Azer SA, Eizenberg N. Do we need dissection in an integrated problem-based learning medical course? Perceptions of first- and second-year students. *Surg Radiol Anat* 2007;29(02):173-180
- 4 Estai M, Bunt S. Best teaching practices in anatomy education: a critical review. *Ann Anat* 2016;208:151-157
- 5 Gunderman RB, Wilson PK. Viewpoint: exploring the human interior: the roles of cadaver dissection and radiologic imaging in teaching anatomy. *Acad Med* 2005;80(08):745-749
- 6 Pabst R. Anatomy curriculum for medical students: what can be learned for future curricula from evaluations and questionnaires completed by students, anatomists and clinicians in different countries? *Ann Anat* 2009;191(06):541-546
- 7 Zuckerman JD, Wise SK, Rogers GA, Senior BA, Schlosser RJ, DelGaudio JM. The utility of cadaver dissection in endoscopic sinus surgery training courses. *Am J Rhinol Allergy* 2009;23(02):218-224
- 8 Al-Abri R, Bhargava D, Al-Bassam W, Al-Badaai Y, Sawhney S. Clinically significant anatomical variants of the paranasal sinuses. *Oman Med J* 2014;29(02):110-113
- 9 Ujike H, Watanabe H. Visually induced motion sickness in virtual reality environments and corresponding countermeasures. *Neuro-Ophthalmol Jpn* 2019;36:22-29
- 10 Narita W. Introduction of XR (VR, AR, MR) in spine surgery. *Orthop Surg Traumatol* 2021;64:1371-1379
- 11 Trelease RB. Anatomical informatics: millennial perspectives on a newer frontier. *Anat Rec* 2002;269(05):224-235
- 12 Sugimoto M. The spatial off-the-job surgical training using 3D organ model, stereoscopic imaging, and online virtual/augmented/mixed reality. *Clin Surg* 2020;75:442-449
- 13 Holoeyes Inc. Accessed December 6, 2022 at: <https://holoeyes.jp/>
- 14 Reeves RE, Aschenbrenner JE, Wordinger RJ, Roque RS, Sheedlo HJ. Improved dissection efficiency in the human gross anatomy laboratory by the integration of computers and modern technology. *Clin Anat* 2004;17(04):337-344
- 15 Aouam D, Zenati-Henda N, Benbelkacem S, Hamitouche C. An interactive VR system for anatomy training. In: *Mixed Reality and Three-Dimensional Computer Graphics*. IntechOpen; 2020
- 16 Falah J, Khan S, Alfalah T, et al. Virtual reality medical training system for anatomy education. In: *2014 Science and Information Conference*. IEEE; 2014:752-758
- 17 McNulty JA, Sonntag B, Sinacore JM. Evaluation of computer-aided instruction in a gross anatomy course: a six-year study. *Anat Sci Educ* 2009;2(01):2-8
- 18 Nicholson DT, Chalk C, Funnell WRJ, Daniel SJ. Can virtual reality improve anatomy education? A randomised controlled study of a computer-generated three-dimensional anatomical ear model. *Med Educ* 2006;40(11):1081-1087

- 19 Hegarty M. Spatial thinking in undergraduate science education. *Spat Cogn Comput* 2014;14:142–167
- 20 Kumalasari L, Yusuf Hilmi A, Priyandoko D. The application of multiple intelligence approach to the learning of human circulatory system. *J Phys Conf Ser* 2017;909:012066
- 21 Lucardie D. The impact of fun and enjoyment on adult's learning. *Procedia Soc Behav Sci* 2014;142:439–446
- 22 Light R. The social nature of games: Australian preservice primary Teachers' first experiences of teaching games for understanding. *Eur Phys Educ Rev* 2002;8:286–304
- 23 Maresky HS, Oikonomou A, Ali I, Ditkofsky N, Pakkal M, Ballyk B. Virtual reality and cardiac anatomy: exploring immersive three-dimensional cardiac imaging, a pilot study in undergraduate medical anatomy education. *Clin Anat* 2019;32(02): 238–243
- 24 Neville AJ. Problem-based learning and medical education forty years on. A review of its effects on knowledge and clinical performance. *Med Princ Pract* 2009;18(01):1–9
- 25 Hara N, Orikasa S. Influence of virtual reality (VR) environment on attitude-control and binocular vision function: 3D-related vision fatigue and disorder. *J Eye* 2019;36:867–876
- 26 Bando T. Biomedical influences possibly caused by experiences in virtual reality in relation to the visual and autonomic nervous functions. *Neuro-Ophthalmol Jpn* 2019;36:5–11