

Cold snare polypectomy for non-pedunculated colon polyps greater than 1 cm



Authors

Cyrus Piraka¹, Ahmed Saeed¹, Akbar K. Waljee^{2,3}, Ajish Pillai⁴, Ryan Stidham³, B. Joseph Elmunzer⁵

Institutions

- 1 Division of Gastroenterology, Henry Ford Hospital, Detroit, Michigan, United States
- 2 VA Center for Clinical Management Research, VA Ann Arbor Health Care System, Ann Arbor, Michigan, United States
- 3 Department of Internal Medicine, Division of Gastroenterology and Hepatology, University of Michigan Health System, Ann Arbor, Michigan, United States
- 4 Division of Gastroenterology, College of Medicine, Drexel University, Philadelphia, Pennsylvania, United States
- 5 Division of Gastroenterology and Hepatology, Medical University of South Carolina, Charleston, South Carolina, United States

Bibliography

DOI <http://dx.doi.org/10.1055/s-0043-101696> |
Endoscopy International Open 2017; 05: E184–E189
© Georg Thieme Verlag KG Stuttgart · New York
ISSN 2364-3722

Corresponding author

Cyrus Piraka, MD, FASGE, Division of Gastroenterology, Henry Ford Hospital, 2799 West Grand Boulevard, K7, Detroit, MI United States 48202, Office: 313.916.8632
Phone: +1-313-812-9491
Fax: +1-313-916-5960
cpiraka1@hfhs.org

ABSTRACT

Background and study aims Colonic polyps > 1 cm in size are commonly managed using hot polypectomy techniques. The most frequent adverse events (delayed bleeding, post-polypectomy syndrome, and perforation) are related to electrocautery-induced injury. We hypothesized that cold resection of large polyps may have similar efficacy and improved safety compared to hot polypectomy. Our aims were to evaluate efficacy and safety of piecemeal cold snare resection of colonic polyps > 1 cm.

Patients and methods Patients undergoing lift and piecemeal cold snare polypectomy of non-pedunculated colon polyps > 1 cm from October 2013 to September 2015 were identified retrospectively. Efficacy was defined by the absence of residual adenomatous tissue at endoscopic follow-up. Adverse events (AEs), including post-procedural bleeding, bowel perforation, or post-procedural pain requiring hospitalization were assessed by chart review and telephone follow-up.

Results Seventy-three patients underwent piecemeal cold snare polypectomy for 94 colon polyps > 1 cm with 56 of 73 patients completing follow-up on 72 polyps. Residual or recurrent adenoma was found in 7 cases (9.7%). Median polyp size was significantly greater in those with residual/recurrent adenoma (37.1 vs. 19.1 mm, $P < .0001$). There were no AEs among all 73 patients enrolled.

Conclusions Piecemeal cold snare resection of colon polyps > 1 cm is feasible, safe and efficacious when compared to published hot polypectomy data. Additional observational and randomized comparative effectiveness studies are necessary to demonstrate comparable adenoma eradication and improved safety advantage over existing hot snare polypectomy techniques.

Introduction

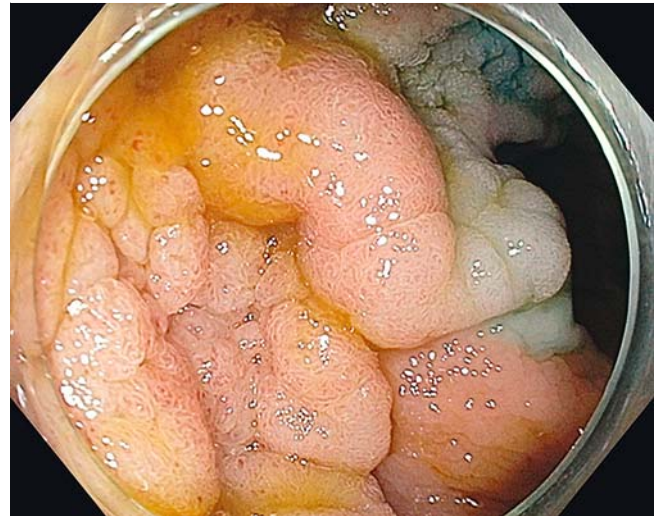The most common approach to management of colonic polyps > 1 cm in size is *en bloc* or piecemeal resection using electrocautery current delivered through a polypectomy snare (hot polypectomy) [1]. The traditional rationale for hot polypectomy includes facilitation of transection through thick tissue, prevention of bleeding by instant vascular coagulation, and thermal ablation of residual unresected dysplastic tissue. However, the most frequent adverse events (AEs) of hot polypectomy – including delayed bleeding, post-polypectomy syndrome, and perforation – are all related to electrocautery-induced injury. The purported mechanism of delayed bleeding is sloughing of the post-cautery coagulum, and post-polypectomy syndrome and perforation result from thermal injury to and transection of the muscularis propria. These AEs are very unlikely to occur when electrocautery is not used during snare transection.

Recognizing that it is possible to remove pieces of tissue 1 cm or larger *en bloc* with a cold snare, particularly with the assistance of submucosal lifting, we hypothesized that endoscopic mucosal resection of larger polyps may also be feasible without cautery, and that this technique is equally effective to and potentially safer than traditional hot polypectomy. In retrospective fashion, we previously reported the feasibility and safety of resecting polyps > 1 cm using cold snare piecemeal resection after submucosal lift in 30 patients with duodenal or colonic adenomas [2]. The aim of this study was to evaluate the efficacy of piecemeal cold snare resection of colonic polyps > 1 cm, and to further assess the safety of this technique.

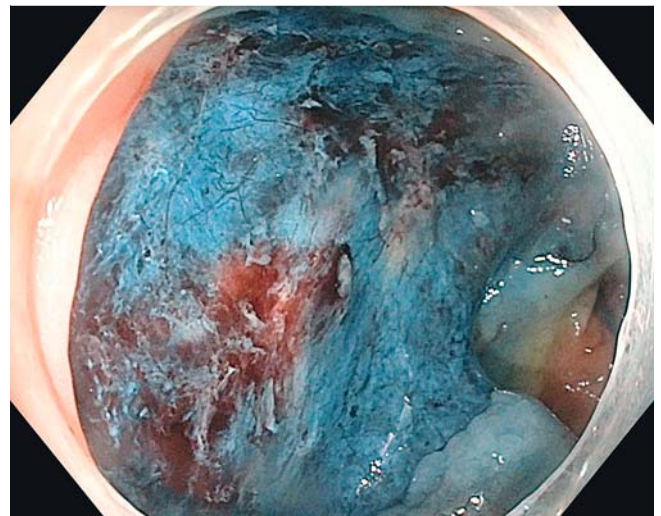Patients and methods

This study was approved by the institutional review board of the Henry Ford Health System. Patients undergoing piecemeal cold snare polypectomy of non-pedunculated colon polyps >1 cm after submucosal lift by a single endoscopist (CP) were identified on retrospective chart review over a 2-year period, from October 2013 to September 2015. These polyps included flat, sessile, and even bulky polypoid lesions, but no polyp with a stalk. Patients were excluded if they received any form of coagulative therapy at the time of polyp resection. All procedures were performed electively in the endoscopy unit at Henry Ford Hospital (HFH) with anesthesia support using a standard adult or pediatric colonoscope (Olympus America, Center Valley, PA, USA). As part of standard complex polypectomy at our institution, all procedures used a short distal attachment cap (Olympus) to deflect intervening folds and stabilize scope position for submucosal lift and resection. All patients underwent submucosal lift with a solution of dilute epinephrine (1:60,000 to 1:200,000) mixed with saline and methylene blue or indigo carmine dye. An Exacto snare (US Endoscopy, Mentor, OH, USA) was most commonly used, with occasional use of the small Captivator II snare (Boston Scientific, MA, USA) and/or a medium Hexagonal snare (Cook Medical, Bloomington, IN, USA). The larger snare was used at times to “etch” the mucosa around the polyp or polyp segment when it was unable to be captured with the smaller snares; the closing of the snare around the margins of the polyp section cuts through the mucosa and creates a lip that can then be gripped with a smaller snare. This was typically followed with piecemeal resection of the etched segment with the smaller cold snare. When it was difficult to cut through a segment, this was most commonly overcome by loosening the snare slightly, lifting the segment towards the center of the lumen, and then reclosing the snare, to release bunched up deeper tissue. Occasionally the piece was let go and resected in two smaller pieces rather than one.

Piecemeal resection was typically initiated at the lateral margin of the polyp with progressive resection of overlapping tissue (transection through the submucosa underlying the prior resection site) until all visible polyp was removed (► Fig.1 and ► Fig.2, ► Video 1). In anticipation of the difficulty of removing large pieces without cautery, the polyp resection was performed by removing smaller individual segments. A high-definition endoscope was used in all cases and narrow-band imaging and near-focus imaging was commonly used to inspect the polypectomy base and margins for residual polyp tissue. Suspected residual adenomatous tissue along margins and polyp base was removed using a cold snare and occasionally a large-capacity forceps. Hemostatic clips were used at the discretion of the endoscopist to treat immediate bleeding. In some cases, mucosa near the resection site was tattooed with SPOT™ (GI Supply, Camp Hill, PA, USA) when future identification for surveillance was anticipated to be challenging. Patients did not undergo any form of thermal therapy, including the use of “hot” forceps or argon plasma coagulation (APC). Histopathology was assessed by the pathology department at HFH. The size, polyp location, morphology, resection technique, to-

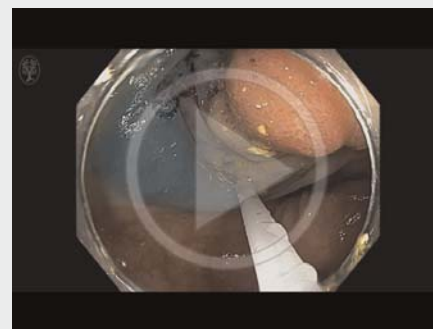

► Fig. 1 Large colon polyp prior to resection.

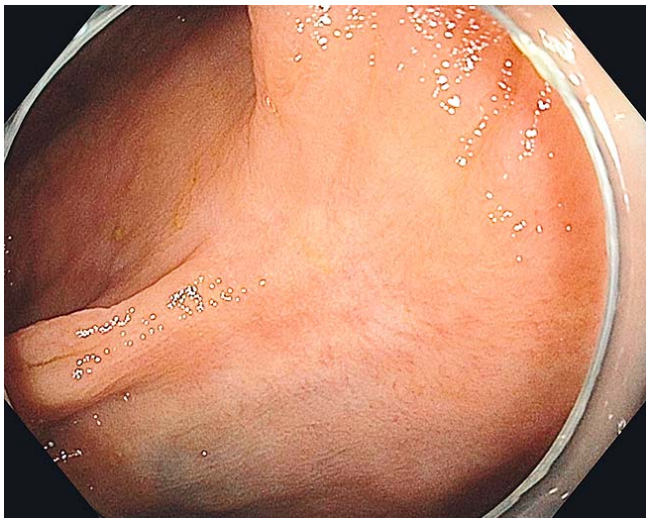


► Fig. 2 Polyp after lifting and cold snare resection.

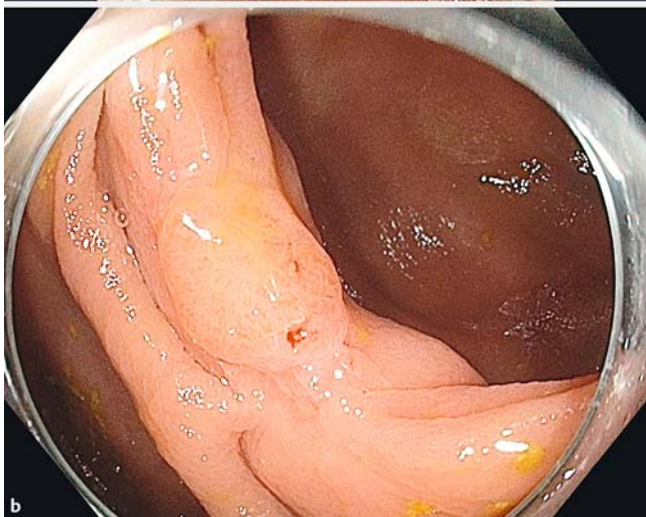
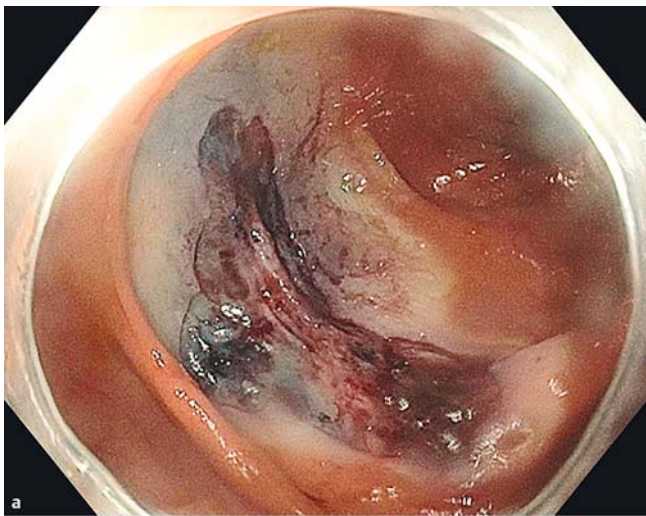
► VIDEO 1



► Video 1: Lift and piecemeal cold snare resection of a large granular laterally spreading polyp.



► Fig. 3 Scar without residual polyp tissue at follow-up.



► Fig. 4 Residual polyp tissue at follow-up. **a** Index colonoscopy and polyp resection. **b** Follow-up showing residual polyp growth.

tal procedure time, and all adjunct therapies (including use of clips or forceps) were recorded at the time of the procedure using Endoworks electronic documentation (Olympus). Pathology results, patient demographics, American Society of Anesthesiologists class scores, and procedure indications were accessed through the EPIC electronic medical record system (EPIC Systems, Verona, WI, USA).

Resection efficacy was defined by the absence of residual adenomatous tissue at endoscopic follow-up between 2 months and 10 months following the index polypectomy (► Fig. 3 and ► Fig. 4). Follow-up was recommended at a 2- to 6-month interval after initial polypectomy, with shorter intervals recommended for larger polyps and those with advanced histology. All patients who underwent follow-up colonoscopy had a visual assessment of the resection site using high-definition white light, narrow-band imaging, and near-focus imaging, and all but 4 had biopsies taken of the polypectomy sites to determine the presence or absence of residual microscopic adenoma.

AEs included immediate or delayed post-procedural bleeding or pain requiring hospitalization, post-polypectomy syndrome, and bowel perforation occurring within 2 weeks of the colonoscopy. Electronic medical records were reviewed for clinical or telephone follow-up discussing post-procedural course. In all cases, an attempt was made to contact patients directly by telephone and asked whether they were hospitalized within 2 weeks following the colonoscopy or had any recollection of complications post-procedure. Polyps were compared by size, stratifying by size greater than 2 cm. Chi-squared, Fisher's exact, and the Student's *t*-tests were performed using SAS 9.4 (SAS, Inc., Cary, NC).

Results

Population and polyp characteristics

Between October 2013 and September 2015, a total of 73 patients underwent lift and piecemeal cold snare polypectomy for 94 colon polyps greater than 1 cm in diameter. Of this total, 34 were male (46.6%) with a median age of 64 years (range 43 to 86 years). Median polyp size was 20 mm (range 12 mm to 60 mm, mean 22.3 mm). Median procedure length was 53 minutes (range from 29–148 minutes). Forty-eight polyps (51.1%) were 2 cm or larger, 21 (22.3%) were 3 cm or larger, and 8 (8.5%) were 4 cm or larger. Twenty-two polyps were removed from the cecum, 31 from the ascending colon, 10 from the hepatic flexure, 15 from the transverse colon, 3 from the descending colon, 10 from the sigmoid colon, and 3 from the rectum. At least 20 (21.3%) of the polyps were known to have been previously partially treated. Thirty-eight of 94 polyps required clean up of areas of adenomatous-appearing tissue with a cold forceps during the polypectomy. Only 1 polypectomy site required placement of a single clip to stop immediate bleeding. There were a total of 50 tubular adenomas (TAs) [3 with high-grade dysplasia (HGD)], 25 tubulovillous adenomas (TVAs) (3 with HGD), 14 hyperplastic polyps, and 5 sessile serrated adenomas (SSAs).

► Table 1 Polypectomy details for patients undergoing follow-up colonoscopy.

	All cases	Polyp <20 mm	Polyp ≥20 mm	P
Number of polyps, n (%)	72	35 (48.6)	37 (51.4)	
Polyps in males (%)	35 (48.6)	18 (51.4)	17 (48.5)	0.642
Median age, yrs (range)	64 (43–84)	64 (48–81)	67 (43–84)	0.558
Polyp location (%)				0.442
Rectum	3 (4.1)	1 (2.8)	2 (5.3)	
Sigmoid	7 (9.5)	3 (8.3)	4 (10.5)	
Descending	3 (4.1)	1 (2.8)	2 (5.2)	
Transverse	17 (23.0)	10 (27.8)	7 (18.4)	
Ascending	24 (32.4)	9 (25.0)	15 (41.7)	
Cecum	18 (25.0)	11 (31.4)	7 (18.9)	
Polyp histology (%)				0.0436
Hyperplastic	12 (16.2)	7 (19.4)	5 (13.1)	
Sessile serrated adenoma	2 (2.7)	1 (2.8)	1 (2.6)	
Tubular adenoma	42 (58.3)	24 (68.6)	18 (47.4)	
Tubulovillous adenoma	16 (23.0)	3 (8.3)	13 (35.1)	
Procedure details				
Forceps use (%)	29 (40.2/20/37)	9 (25)	20 (54.1)	0.008
Hemostatic clip use (%)	1 (1.4)	0	1 (2.6)	n/a
Procedure length, minutes (range)	53.0 (24–106)	51.6 (24–105)	63.9 (29–106)	0.044
Follow-up details				
Time to follow-up, days (range)	160.5 (32–487)	192.8 (32–406)	150.9 (56–487)	0.041
Residual tissue on biopsy (%)	7 (9.7)	0	7 (18.4)	0.012
Adverse event	0	0	0	n/a

Efficacy

At the end of the study data collection period, 56 of the 73 patients had follow-up colonoscopy at 2–10 months from the index colonoscopy (► Table 1). The remainder either failed to undergo follow-up at our institution or were awaiting their planned follow-up colonoscopy. In these 56 patients completing follow-up, there were a total of 72 polyps. Thirty-five of them were resected in 28 male patients (50.0%) with a median age of 63.5 years (range 43–84 years). The median length of procedure was 53.0 minutes (range 24–148 minutes). The median polyp size was 20 mm (range 12–60 mm, mean 22.5 mm); 37 polyps (51.4%) were 20 mm or larger. The majority of polyps (42/72, 58.4%) were from the ascending colon or cecum. Eighteen (25.0%) of the polyps were known to have been previously treated. Most polyps were tubular adenomas (40/72, 55.6%) and most tubulovillous adenomas were 20 mm or larger (12/15, 80.0%). Three polyps had high-grade dysplasia. Forceps cleanup was more often used, and polypectomy was slightly longer, in polyps 20 mm or larger.

Residual or recurrent adenoma was found at the polypectomy site during follow-up examination in 7 cases (9.7%); 2 were TAs and 5 were TVAs, none with high-grade dysplasia. Those with residual or recurrent adenoma detected at follow-up had a median initial polyp size of 30 mm (mean 37.1 ± 13.8 mm, range 20.0–60.0 mm) compared to a median of 18 mm (mean 19.1 ± 8.3 mm, range 12–50 mm) in those without residual adenoma ($P < .0001$). All 7 cases that demonstrated residual adenoma on follow-up colonoscopy were initially 20 mm or larger at the time of initial resection; these measured 20 mm, 25 mm, 2 were 30 mm, 2 were 50 mm, and 1 was 55 mm. Six of the 7 polyps with residual adenoma on follow-up colonoscopy were found in the right colon, and 1 was in the descending colon. Three of these 7 cases had a prior attempt at endoscopic therapy. Fifteen of 18 polyps where prior polypectomy was performed did not have residual polyp detected on follow-up. In 6 of the 7 cases (85.7%) in which residual adenomatous tissue was detected, forceps were used to clean the base and/or margins of the initial polyp resection ($P = 0.018$). Finally, the majority of cases in which residual adenoma was found on follow-up

(71.4%, 5/7) exhibited tubulovillous histology ($P=0.032$); as noted, none of the 3 patients with high-grade dysplasia had residual adenoma on follow-up. Of note, 4 patients did not get biopsy of the resection site scar of 9 polypectomies. But 7 of these were hyperplastic polyps, and 1 case of a resected 25-mm descending colon TA had a biopsy of the site over a year later without residual polyp found then; the last case was an 18-mm TA in the hepatic flexure. Further, there were no cases where residual polyp was found on biopsy that was not suspected endoscopically, and in 4 polypectomy sites, there was a question of residual polyp vs regenerative tissue seen endoscopically, but no residual polyp was found on biopsy.

Safety

Sixty-six of the 73 total patients (90.4%) were also reached by phone to provide AE follow-up (on 87 of 94 polypectomies, 92.6%) in addition to chart review. Of the 73 patients undergoing cold snare polyp resection, only 1 had immediate bleeding treated with placement of a single clip; that patient had a 30-mm ascending colon tubulovillous adenoma that had been previously treated and was one of the cases with residual polyp found on follow-up. There were no perforations, no episodes of post-polypectomy syndrome, and no delayed bleeding events requiring transfusions or repeat procedures. No patient reported any visible bleeding, and no patient required repeat hospitalization, transfusion, or repeat procedures to treat adverse events. No patients developed interval cancer. There were no deaths.

Discussion

In a recently published retrospective case series, we presented data suggesting that piecemeal cold snare polypectomy of non-pedunculated duodenal and colonic polyps ≥ 1 cm is feasible and safe [2]. This study further supports the technical feasibility of this method, and suggests that it is both efficacious and safe.

Notably, the residual or recurrent adenoma rate in this study is in line with published hot polypectomy studies in which recurrence rates range from 2% to 40% [3]. For example, a widely referenced hot polypectomy study including 274 patients similar to ours demonstrated a residual/recurrent adenoma rate of 27% [4]. The 9.7% residual/recurrent adenoma rate in our study compares favorably with this and other studies, although our cases were performed in an era of improved colonoscopy optics and increased awareness of the importance of meticulously inspecting for and removing any possible residual adenoma at the time of polypectomy. Limited published data on this technique also include a study of 30 patients who had cold snare polypectomy on polyps 1 cm or larger, and had a complete resection rate of 80%, although more than half of their patients had APC performed with their polypectomies [5]. In this study, no patient had APC or any adjuvant cautery based treatment of the base or margins and still had an excellent rate of complete resection. Based on this early evidence, concerns about the potential to get inadequately deep specimens appear likely to be unfounded. One recent study [6] assessed the defects created by cold snare for subcentimeter polyps and found that none

contained any residual adenomatous tissue or serrated polyp tissue. Our technique differs from the cold snare resection done in this study in that we use a submucosal lift, but the visual appearance of blue staining of the submucosa is likely the visual correlate of their findings, that 94% of their resection specimen base biopsies contained submucosa.

Risk factors for incomplete resection in our study included large polyp size and attempted prior resection, which has been previously reported in studies using traditional hot snare resection [7]. Villous histology, but not high-grade dysplasia, was also a risk factor for remaining tissue at follow-up, though the sample size is too small to make strong conclusions. Forceps were used in 6 of 7 cases where residual polyp was found at follow-up, predominantly to clean up suspected remaining polyp in the resection base (cold snare was used to extend lateral margins); this reflects the fact that it was difficult to capture segments of the polyp base with a snare, and may be a challenge whether using hot snare or cold.

Another important consideration is that the cold resection technique has the potential to significantly reduce adverse events associated with polypectomy, including delayed bleeding, perforation, and post-polypectomy electrocoagulation syndrome, all of which are due to the use of electrocautery. The incidence of AEs following hot polypectomy ranges between 11.6% [4] and 17% [8]. In contrast, there were no major AEs in our study and only 1 patient required a single hemostatic clip to control immediate observed bleeding. Indeed, in a total of over 100 patients included in our 2 studies, no patients experienced a serious AE. Previously data from Barros et al [9] also reported no AEs in 171 non-pedunculated colon lesions measuring 4 mm to 20 mm that were removed with cold snare (piecemeal or en bloc), and our study has demonstrated that it appears to be safe to perform cold snare polypectomy of even larger polyps.

The efficacy and safety outcomes in this study are highly encouraging, and suggest that electrocautery is not mandatory to achieve adenoma eradication. Given its potential safety advantages, the avoidance of cautery may represent a paradigm shift in polypectomy practice. However, in order for cold polypectomy to have a real impact on clinical practice, the results of this study must be reproduced by other endoscopists in varying practice environments, ideally in the context of multi-center observational studies. Such studies – if they demonstrate favorable outcomes – will ultimately inform the design of methodologically-rigorous randomized trials which may define the exact role of cold snare polypectomy. These studies are important to overcome the limitations of this retrospective study. There is also the potential of skewing efficacy data based on the initial selection of patients for cold snare resection. Furthermore, there is always the potential for late recurrences [10] even with typical cautery-based resection techniques, and the rate is not yet defined with this technique.

Another consideration in deciding on technique is cost. There is the potential for overall cost reduction using this technique. Cold snare may obviate the need for prophylactic clipping that would otherwise have been to reduce the risk of delayed bleeding or perforation. Cost savings per procedure could

be hundreds or even thousands of dollars, depending on the number of clips that would have been required to close a large defect. Additional savings may also be found in the amount of time required to do the procedure, as clipping a defect closed can be time and labor intensive. It is unclear if there is an overall increase in the amount of time it takes to perform the polyp resection cold as compared to hot, although we have found that with more experience, the resection can be performed rather quickly, particularly as you can forego concerns about perforation. There is the potential for increased cost in requiring an additional or earlier surveillance colonoscopy when removing a 10-mm to 20-mm polyp piecemeal rather than en bloc. However, attempted en bloc resection of polyps with hot snare techniques may still be incomplete, and unless the pathologist confirms that the margins are all negative, there may be unrecognized residual polyp remaining. Our data suggest that even when resected piecemeal, these smaller polyps may be confidently removed completely with one cold snare resection, when adding the removal of wide lateral margins; no polyp under 20 mm had residual polyp at follow-up in our study. Future studies need to be done to help define the proper interval for follow-up in this subset of patients. In the interim, endoscopists may consider employing this technique in high risk scenarios, such as in patients who are at very high risk of delayed hemorrhage or those who are very unlikely to tolerate an operation to address perforation.

Conclusions

In conclusion, this study adds further support to our hypothesis that lift and piecemeal cold snare resection of colon polyps > 1 cm is feasible, safe and efficacious. Because piecemeal cold polypectomy represents a significant change to the standard of care for polyp management, additional observational and randomized comparative effectiveness studies are necessary to demonstrate the non-inferiority of this technique for adenoma eradication and its safety advantage over hot snare polypectomy.

Competing interests

Dr. Piraka is on the Speakers Bureau of Boston Scientific Grant support: Dr. Waljee's research is funded by a Career Development Award (CDA 11-217) from the United States (US) Department of Veterans Affairs Health Services Research and Development Service. The contents do not represent the views of the US Department of Veterans Affairs or the US Government.

References

- [1] Conio M, Repici A, Demarquay JF et al. EMR of large sessile colorectal polyps. *Gastrointest Endosc* 2004; 60: 234–241
- [2] Choksi N, Elmunzer BJ, Stidham RW et al. Cold snare piecemeal resection of colonic and duodenal polyps ≥ 1 cm. *Endosc Int Open* 2015; 3: E508–513
- [3] Pohl H, Srivastava A, Bensen SP et al. Incomplete polyp resection during colonoscopy—results of the complete adenoma resection (CARE) study. *Gastroenterology* 2013; 144: 74–80.e1
- [4] Buchner AM, Guarner-Argente C, Ginsberg GG. Outcomes of EMR of defiant colorectal lesions directed to an endoscopy referral center. *Gastrointest Endosc* 2012; 76: 255–263
- [5] Muniraj T, Sahakian A, Ciarleglio MM et al. Cold Snare Polypectomy for Large Sessile Colonic Polyps: A Single-Center Experience. *Gastroenterol Res Practice* 2015: 175959
- [6] Tutticci N, Burgess NG, Pellise M et al. Characterization and significance of protrusions in the mucosal defect after cold snare polypectomy. *Gastrointest Endosc*. 2015; 82: 523–528
- [7] Moss A, Bourke MJ, Williams SJ et al. Endoscopic mucosal resection outcomes and prediction of submucosal cancer from advanced colonic mucosal neoplasia. *Gastroenterol* 2011; 140: 1909–1918
- [8] Knabe M, Pohl J, Gerges C et al. Standardized long-term follow-up after endoscopic resection of large, nonpedunculated colorectal lesions: a prospective two-center study. *Am J Gastroenterol* 2014; 109: 183–189
- [9] Barros RA, Monteverde MJ, Barros RF et al. Safety and efficacy of cold snare resection of non-polypoid colorectal lesions (0-IIa and 0-IIb). *Acta Gastroenterologica Latinoamericana* 2014; 44: 27–32
- [10] Khashab M, Eid E, Rusche M et al. Incidence and predictors of “late” recurrences after endoscopic piecemeal resection of large sessile adenomas. *Gastrointest Endosc* 2009; 70: 344–349