

Use of the over-the-scope-clip (OTSC) in non-variceal upper gastrointestinal bleeding in patients with severe cardiovascular comorbidities: a retrospective study



Authors

Edris Wedi^{1,2}, Daniel von Renteln⁴, Susana Gonzalez³, Olena Tkachenko⁵, Carlo Jung^{1,2}, Sinan Orkut¹, Victor Roth¹, Selin Tumay¹, Juergen Hochberger^{1,6}

Institutions

- 1 Department of Gastroenterology and Gastrointestinal Oncology, University Medical Centre Goettingen, Center of Interdisciplinary Endoscopy, Goettingen, Germany
- 2 Department of Gastroenterology, Nouvel Hôpital Civil, University Hospitals, Strasbourg, France
- 3 Division of Gastroenterology, NYU Langone Medical Center, New York, New York, United States
- 4 Division of Gastroenterology, Centre Hospitalier de l'Université de Montréal (CHUM), Research Centre CHUM (CRCHUM) Montreal, Quebec, Canada
- 5 Division of Reproductive and Developmental Sciences, Oregon National Primate Research Center, Oregon Health & Science University, Beaverton, Oregon, United States
- 6 Division of Gastroenterology, Vivantes Klinikum in Friedrichshain, Teaching Hospital of Charité Humboldt University, Berlin, Germany

submitted 18.11.2016

accepted after revision 13.2.2017

Bibliography

DOI <http://dx.doi.org/10.1055/s-0043-105496> | Endoscopy International Open 2017; 05: E875–E882
© Georg Thieme Verlag KG Stuttgart · New York
ISSN 2364-3722

Corresponding author

Edris Wedi, MD, Department of Gastroenterology and GI Oncology, University Medical Centre Goettingen, Center of Interdisciplinary Endoscopy, Georg-August-University Endoscopy, D-37075 Goettingen, Germany
Fax: +495121901241
edris.wedi@med.uni-goettingen.de

ABSTRACT

Introduction The over-the-scope-clip (OTSC) can potentially overcome limitations of standard clips and achieve more efficient and reliable hemostasis. Data on OTSC use for non-variceal upper gastrointestinal bleeding (NVUGIB) in patients with cardiovascular comorbidities are currently limited.

Patients and methods We prospectively collected and retrospectively analyzed our database from February 2009 to September 2015 from all patients who underwent emergency endoscopy for high-risk NVUGIB in 2 academic centers and were treated with OTSC as first-line (n=81) or second-line therapy (n=19).

Results One hundred patients mean age 72 (range 27–97 years) were included in this study. Fifty-one percent (n=51) had severe cardiovascular co-morbidity (ischemic heart disease, congestive heart failure, hypertension, valvular heart disease, peripheral arterial occlusive disease and atrial fibrillation) and 73% (n=73) were on antiplatelet or/and anticoagulation therapy. The median size of the treated ulcers was 3 cm (range 1–5 cm). In 94% (n=94) primary hemostasis with OTSC was achieved. Clinical long-term success during a mean 6-month follow-up without rebleeding was 86% (n=86).

Conclusions In this cohort OTSC was demonstrated to be a safe and effective first- or second-line treatment for NVUGIB in high-risk patients with cardiovascular disease and complex, large ulcers.

Meeting presentations: Annual Meeting of the German Society of Endoscopy (DEGBV) in Mannheim, Germany, March 17th–19th, 2016 and DDW 2016 in San Diego, United States

Introduction

Severe non-variceal upper gastrointestinal bleeding (NVUGIB) is a common clinical problem with high rates of morbidity and mortality. NVUGIB is associated with a mortality rate between

5% and 10% [1]. Despite advances in pharmaceutical and endoscopic therapy, severe NVUGIB, especially in patients receiving anticoagulants, remains challenging. Classic clipping devices, so-called through-the-scope (TTS) clips, have their limitations for treating complex lesions and lesions with large vessels. Furthermore, an aging patient population with a high prevalence

► **Table 1** Forrest classification and anatomic location of bleeding.

Anatomic Location	Forrest Ia	Forrest Ib	Forrest IIa	Forrest IIb	Forrest IIc
Esophagus	2	2	7		1
Fundus		1			
Greater curvature	2		4	1	
Lesser curvature			3	1	
Angulus	2		1		
Antrum	2	4	4	2	
Pyloric canal	1	1	2		
Duodenal bulb	8	1	12		1
Second Duodenum	11	3	18	1	1
Gastro-Jejunal Anastomosis			1		
	28	12	52	5	3

of cardiovascular comorbidity has led to increases in the incidence of NVUGIB in patients older than age 70 years [2–4]. A high comorbidity rate has also been identified as an independent risk factor for complications and mortality after NVUGIB [5].

The over-the-scope-clip system (OTSC; OVESCO Endoscopy AG, Tuebingen, Germany) is a larger clip compared to standard TTS clips. This novel endoscopic tool, which allows for mucosal approximation of larger areas, can capture deeper tissue layers than TTS clip systems [6]. The clip consists of super-elastic Nitinol and has the shape of a bear trap. It applies a high-pressure closure up to 8 to 9 Newton on the tissue and allows at the same time sufficient tissue circulation [7]. The device has already been evaluated in numerous studies for its application for gastrointestinal perforations and fistulas [8,9]. However, available data on OTSC for treatment of gastrointestinal bleeding are limited to case series [10–13]. The aim of our study was to investigate the efficacy of OTSC treatment in preventing NVUGIB rebleeding in a patient cohort with cardiovascular comorbidity or/and active anticoagulation. A part of this study has already been published recently in a descriptive study dealing with different areas of application of the OTSC [13]. To the best of our knowledge this study is the largest cohort treated with OTSC for NVUGIB in patients with cardiovascular comorbidities published to date.

Patients and methods

A total of 100 patients (mean age 72 [27–97] years, female 28%, male 72%) were treated between February 2009 and September 2015 at 2 academic medical centers (St. Bernward Hospital, Hildesheim, Germany; University Hospital of Strasbourg, France). For this observational 2-center study, data were collected prospectively and analysis was performed retrospectively. The cohort included patients after failure of a standard primary hemostatic method (injection, clip application or embolization) and lesions identified as high-risk, defined as lesion size ≥ 1 cm

and visible vessel ≥ 0.5 mm that were primarily treated with OTSC (► **Table 1**).

All study procedures were performed at each center by 2 experienced endoscopists. In cases of active bleeding the OTSC was applied using a double-channel gastroscope (EG530D, Fujifilm, Tokyo, Japan) in combination with an endoscopic water jet (Endo-Technik, Solingen, Germany). All interventions were performed under either general anaesthesia or under midazolam/propofol sedation, depending on the clinical situation (► **Table 2**).

The primary outcome was defined as successful initial hemostasis with no recurrent bleeding within 30 subsequent days. Early rebleeding was defined as hematemesis, melena, shock (systolic pressure <90 mmHg or heartbeat >110 /min) or loss of hemoglobin more than 2 g/dL within 24 hours. Delayed bleeding was defined as any hematemesis, melena, shock (systolic pressure <90 mmHg or heartbeat >110 /min) or loss of hemoglobin more than 2 g/dL occurring within 30 days after OTSC placement leading to hospital admission and/or another endoscopic intervention.

Follow-up endoscopy was performed in cases with signs of rebleeding. A “second-look endoscopy” was not performed if initial clip placement and hemostasis was deemed successful. Secondary outcomes were reintervention and complication rates, mortality, comorbidities, age, number of OTSC clips or additional hemostatic interventions required (such as other endoscopic methods, radiological embolization or surgery), patient percentage receiving anticoagulation or/and antiplatelet therapy before, during and after OTSC treatment. The study was approved by the institutional review board (IRB) of all institutions.

Results

Comorbidities in the patient cohort included cardiovascular disease in 51% ($n=51$) of the cases, kidney disease 20% ($n=20$), former or recent malignancy 23% ($n=23$), respiratory dis-

► **Table 2** Comorbidities in the patient collective.

Comorbidites ¹	Specific comorbidites ²	n
Cardiovascular disease 51%	Ischemic heart disease	21
	Congestive heart failure	22
	Hypertension	49
	Valvular heart disease	2
	Peripheral arterial occlusive disease PAOD	6
	Atrial fibrillation	25
Renal disease 20%	Acute renal failure	10
	Chronic renal failure	12
	History of transplantation	2
Pulmonary disease 16%	Obstructive/restrictive airway disease	17
	Pulmonary embolism	3
	Pulmonary hypertension	1
	Pneumonia	6
Hepatic disease 6%	Acute hepatic failure	3
	Cirrhosis	2
	Metastatic hepatic disease	1
Others	Malignancy	23
	Diabetes mellitus	26
	Osteoporosis	5
	Depression	5
	Nicotine abuse	12
	Alcoholic disease	9

¹ Absolute numbers of comorbidities

² Patients often had more than one comorbidity.

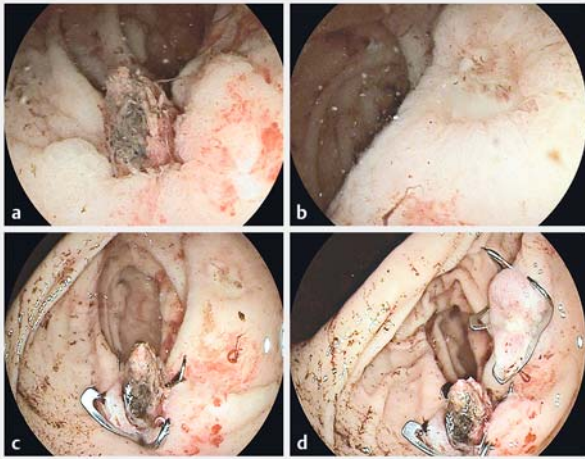
ease 16% (n=16), liver disease 6% (n=6) and diabetes mellitus 26% (n=26) (► **Table 2**). The patients in 85% of the cases were classified as ASA 3 to 5 (ASA 3: 40%, ASA 4: 40% and ASA 5: 5%).

In 79% (n=79) of cases acute NVUGIB was related to peptic ulcer disease (gastric ulcer 25% [n=25] and duodenal ulcer 54% [n=54]) (► **Table 1**) (► **Fig. 1**), in 7% (n=7) the bleeding arose from a malignant ulcer, in 8% (n=8) from a Mallory Weiss Lesion, in 3% (n=3) from an erosive gastritis, and in 2% (n=3) from dieulafoy lesions (► **Fig. 2**) and in 1% (n=1) after gastric polypectomy. During the initial endoscopy, Forrest Ia lesions were encountered in 28% (n=28) of cases, Forrest Ib in 12% (n=12), Forrest IIa in 52% (n=52), Forrest IIb in 5% (n=5) and Forrest IIc in 3% (n=3) (► **Table 1**). In total 57 ulcers were treated in the pyloric canal, duodenal bulb or second duodenum. The median size of the ulcers found during initial endoscopy was 3 cm (range 1–5 cm). In 81% (n=81) of patients OTSC was used as first-line therapy and in 19% (n=19) OTSC was used after failure of another endoscopic haemostatic intervention 13% (n=13) standard hemoclips, 2% (n=2) adrenalin injection + hemoclip and 4% (n=4) surgical sutures). Sixty-seven percent

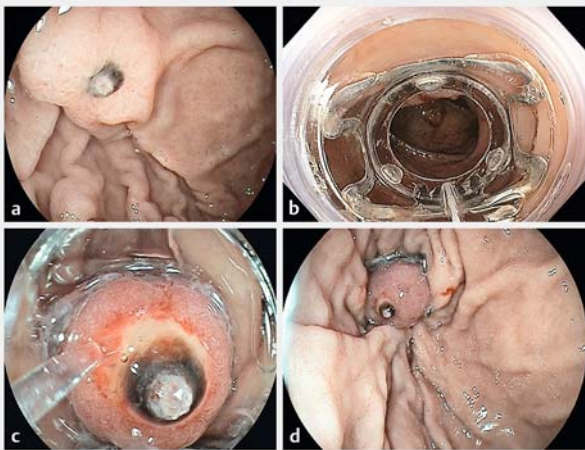
of patients presented initially as outpatients at the emergency room with signs of upper gastrointestinal bleeding (hematemesis, melena, coffee ground vomiting and hematochezia) and 33% (n=33) of patients developed an NVUGIB during hospitalization.

Seventy-three percent of patients were receiving anticoagulants or antiplatelet therapy at the time of the initial gastrointestinal bleeding event (► **Table 3**). The anticoagulant and antiplatelet therapy was reintroduced in 61% (n=61) of patients within 24 to 48 hours after endoscopic treatment.

Overall initial hemostasis was achieved in 94% (n=94) patients. The primary endpoint with successful initial hemostasis and no early (≤ 24 h) or delayed (≤ 30 days) re-bleeding was achieved in 86% (n=86) of patients. Mean number of OTSCs placed on the initial endoscopic exam was 1 (range: 1–3). Long-term hemostasis (6 months) in the patient cohort was achieved in 86% (n=86) of cases. In our study the OTSC was still in place after a follow-up between 1 to 6 months in 65% (n=65) of patients.



► Fig. 1 A 57-year-old patient who had a pulmonary embolism 1 week before presenting a severe upper gastrointestinal bleeding due to 2 antral ulcers (Forrest IIa and Forrest III) (a, b). The patient was anticoagulated with Enoxaparin $2 \times 10\,000$ UI. The Forrest IIa Ulcer had a size of 1.5×1.8 cm with a visible vessel and coagulum. This was treated successfully with a 17.5-mm traumatic OTSC (a–c). A second Forrest III ulcer 1×1.2 cm was also treated with a 17.5-mm traumatic OTSC (b–d).



► Fig. 2 A 63-year-old patient who had a myocardial infarction in 2011 with stenting and was receiving antiplatelet therapy with aspirin 75 mg. He presented with epigastric pain and hematemesis. Emergency endoscopy revealed a Dieulafoy ulcer in the fundus with a large visible vessel (2.5–3 mm) (a). The lesion was treated after suction of the vessel into the OTSC effectively with a 17.5 traumatic OTSC (c–d).

Overall initial failure of OTSC placement and early/late re-bleeding after ≤ 24 hours or ≤ 30 days occurred in 14 patients. Subsequent executions describe each group in detail.

► Table 3 Anticoagulation and antiplatelet therapy in the patient cohort.

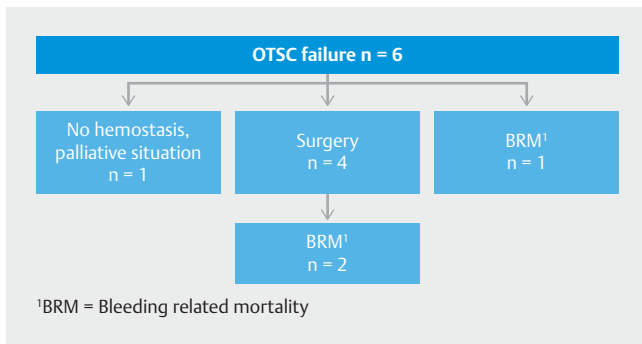
Anticoagulation and antiplatelet therapy	n
Antiplatelet therapy	
▪ Aspirin 75–100 mg	25
▪ Clopidogrel 75 mg	3
Anticoagulation	
▪ Heparin 10 000–15 000 UI/d	19
▪ Warfarin	9
Anticoagulation + antiplatelet therapy	
▪ Aspirin 75–100 mg + Warfarin	3
▪ Aspirin 75–100 mg + Heparin 5000–7000 IU/2–3 \times /d	3
▪ Clopidogrel 75 mg + Warfarin	1
Dual antiplatelet therapy	
▪ Aspirin 75–100 mg + Clopidogrel 75 mg	8
Others	
▪ Aspirin 75 mg + Clopidogrel 75 mg + Warfarin	1
▪ Rivaroxaban 20 mg	1
No anticoagulation or antiplatelet therapy	27

Initial failure of OTSC placement

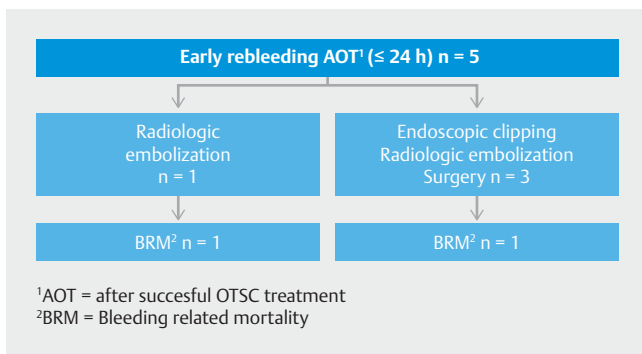
Initial OTSC placement failed in 6 patients due to inability to visualize the bleeding vessel and place the OTSC clip appropriately (► Fig. 3). Five of these patients presented with a severe Forrest Ia bleeding, 4 of these lesions were located in the posterior wall of the duodenal bulb and 1 was located in the gastric body. In 1 case the OTSC could not be placed due to obstructing tumor at the pylorus and despite attempted balloon dilatation the OTSC could not be advanced to the bleeding site, which was located at the anterior wall of the duodenal bulb. Four patients received surgical treatment after failed OTSC treatment and 2 patients subsequently died despite surgical intervention. One patient died due to hemorrhagic shock during endoscopy (► Fig. 3).

Early rebleeding after initial successful OTSC application

In the early re-bleeding group (≤ 24 h, $n = 5$), 2 patients died due to hemorrhagic shock, 1 patient died despite radiologic embolization (► Fig. 4). The other 3 patients survived after additional therapy; 1 was treated with endoscopic clipping, 1 was treated with radiologic embolization and 1 received a surgical suture. All lesions in this group were Forrest Ia lesions. Two lesions were located in the gastric antrum and 3 lesions in the posterior-inferior duodenal wall.



► **Fig. 3** Study outcome failure group. Initial endoscopic hemostasis with the OTSC failed in 6 patients. In 4 a surgical treatment was performed, 2 patients died despite surgical treatment. One patient died due to hemorrhagic shock. In 1 patient no further treatment was desired because of a palliative situation.

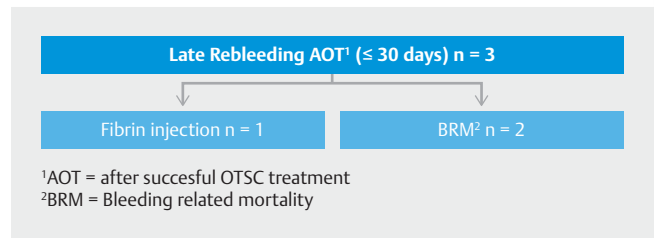


► **Fig. 4** Study outcome in the early rebleeding group. Early rebleeding (≤ 24 hours) after an initial treatment occurred in 5 patients. In this group 2 patients died due to hemorrhagic shock, 1 despite radiologic embolization. Two other patients survived after additional therapy (1x endoscopic clipping, 1x radiologic embolization and 1 x surgical treatment). All lesions in the early rebleeding group were Forrest Ia. lesions.

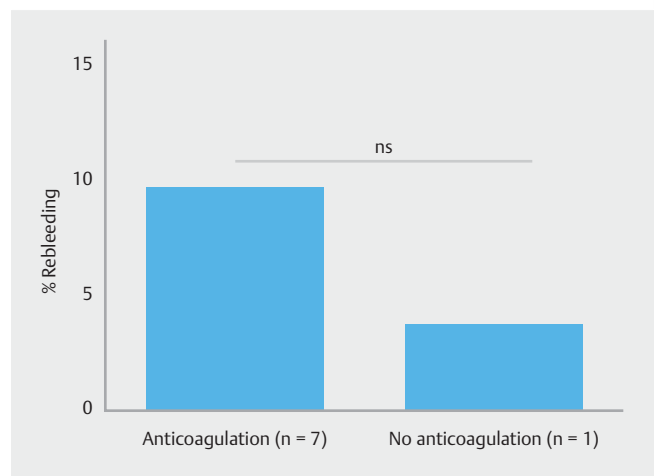
Late rebleeding after initial successful OTSC application

In the late rebleeding group (≤ 30 days, $n=3$), 1 patient died due to hemorrhagic shock after 3 days (► **Fig. 5**). A second patient rebled after 4 days of initial hemostasis with the OTSC and underwent salvage surgery with an uneventful course after surgery (► **Fig. 5**). The third patient presented with a recurrent bleed after 48 hours with oozing bleeding in between the OTSC teeth. This was treated by using beriplast (Beriplast P Combi-Set, CSL Behring, Germany) fibrin injection. Overall 8 patients presented with early ($n=5$) or late rebleeding ($n=3$). Seven of these patients were receiving anticoagulants (► **Fig. 6**).

Overall mortality in this cohort was 19%. In the following section 3 different groups were identified and analyzed referring to mortality.



► **Fig. 5** Study outcome late rebleeding group. Three patients presented with late rebleeding (≤ 30 days). In this group 2 patients died due to hemorrhagic shock. The third patient had a rebleeding on day 4 with oozing bleeding in between the OTSC teeth; that was treated by using fibrin glue.



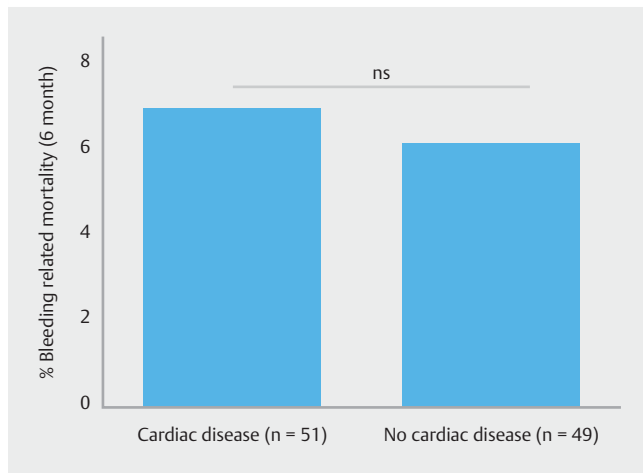
► **Fig. 6** Rebleeding in anticoagulated patients.

Mortality due to unsuccessful initial OTSC application

Mortality was 3% ($n=3$) due to failure of achieving hemostasis with OTSC at initial endoscopy. In this group, 1 death occurred due to failure to control the initial bleeding of a Forrest Ia lesion. Two patients continued bleeding after initial OTSC application from the gastroduodenal artery (F1a duodenal ulcer) and salvage surgery also proved unsuccessful (► **Fig. 3**).

Mortality after initial successful OTSC application and rebleeding

Four patients died after hemostasis was achieved during an initial endoscopy with OTSC placement. All 2 developed early rebleeding and hemorrhagic shock ≤ 24 hours after initial hemostatic endoscopy therapy (► **Fig. 4**). One patient was a 90-year-old patient with a Forrest IIb bleeding ulcer who had an ischemic stroke at the time of the bleeding episode and died in that context. One patient underwent successful radiologic embolization after initial OTSC hemostasis and rebleeding (F1a duodenal ulcer) and died from the effects of hemorrhagic shock. He had metastatic malignant disease from an unknown primary tumor, which was unknown at the time of hemorrhagic shock. Two patients died after late rebleeding (48 hours and 72



► **Fig. 7** Bleeding-related mortality in cardiac and non-cardiac patients.

hours) due to massive rebleeding, after initial successful OTSC application.

Mortality from non-GIB sources/co-morbidities

Twelve patients died from causes not related to bleeding; 3 due to respiratory insufficiency and 5 due to multiorgan failure, 2 due to acute heart failure, and 2 due to MRSA sepsis. No early or delayed complications from OTSC use were encountered in this group. The bleeding event in these patients could be effectively treated with the OTSC clip.

Statistics

Statistical analysis was performed using GraphPad Prism6 (GraphPad Software, Inc., La Jolla, USA). Multiple linear regression with two independent variables was used for each pair of independent variables for correlation analysis. Correlations are described using Pearson correlation coefficient (r) and P value (P). For group comparisons, a t -test was used. A P value <0.05 was considered significant. We analysed patient data in order to determine if there was any correlation between patient/bleeding characteristics and important treatment outcomes, such as success of therapy or mortality rates.

Statistical results

Bleeding from duodenal lesions constituted the most frequent location in the study population ($P<0.05$). Both bleeding-caused and all-cause mortality had weak positive correlation with patient age ($r=0.22$, $p=0.028$ and $r=0.21$, $P=0.028$, respectively). Bleeding-caused mortality further positively correlated with Forrest Type Ia bleeding ($r=0.37$, $P=0.0001$). There was no positive correlation with other Forrest Types.

We analyzed whether presence of renal disease alone or in combination with cardiovascular disease would affect mortality rate or surgical outcome. There was no significant difference for any of the parameters analyzed between different groups of patients, probably due to low numbers.

We further analyzed the data according to presence/absence of cardiovascular disease (CVD) in patients. There was a significant difference in therapy success ($P=0.0028$) within the cohort of patients with Type IIa bleeding between those who had CVD comorbidity versus those without. In 88% of patients with CVD, the primary intervention was successful, while the rest of these patients required retreatment. Comparison of patients with CVD versus patients without CVD revealed no significant difference in bleeding related mortality (CVD: 7.84% vs. no CVD: 6.12%; not significant, ► **Fig. 7**).

Discussion

Non-variceal upper gastrointestinal bleeding (NVUGIB) continues to be associated with high morbidity and mortality. Therefore, early and successful endoscopic treatment of NVUGIB remains key to prevent subsequent salvage surgery or mortality [14]. In the last decade, there has been great improvement in the endoscopic treatment of NVUGIB. However, the risk of rebleeding remains high at around 20%, with mortality rates between 10% and 36% [15–17]. For patients receiving antiplatelet therapy or with cardiovascular comorbidities the rebleeding and mortality risk is significantly increased [18, 19]. Under current clinical standards, NVUGIB is managed endoscopically by using epinephrine injection with a second hemostatic method such as electrocautery, or hemoclip application [19, 20]. Often, multiple hemoclips are required due to their limitation in grasping sufficient tissue. The OTSC has the potential to overcome the limitations of standard TTS clips. However, experience with use of OTSC for treatment of NVUGIB is still limited to small case series and it is for this reason that we conducted this study [8, 9, 21–23].

Our study confirms that by using OTSC in a large cohort of high-risk patients, initial hemostasis can be achieved in 94% and long-term hemostasis in 86% without rebleeding. The cohort we studied was high-risk for different reasons. First of all, 85% ($n=85$) were classified as ASA 3 to ASA 5 according to the definition of the American Society of Anesthesiologists. These are patients with severe systemic disease (40%, ASA 3), severe systemic disease that is a constant threat of life (40%, ASA 4) and moribund individuals who are not expected to survive without an operation (5%, ASA 5) [24]. In addition, 51% ($n=51$) had CVD. A recently published systemic meta-analysis showed that the mortality rate in patients with NVUGIB with CVD was 13.3% versus 6.9% without CVD. In comparison to these data, in our study, the mortality rate was significantly lower at 7.84% in patients with CVD compared to published data [5].

It is generally known that major predictors for rebleeding after hemostatic therapy are large ulcer size and ulcer location. In a systematic review of prospective clinical trials, Elmunzer and colleagues identified large ulcers (>1 cm) and ulcer location in the posterior duodenum as significant predictors of rebleeding [25]. They described the rebleeding risk out of 5 studies in patients with ulcer size >1 cm and >2 cm as between 14.8% and 42.0% [25]. In our study ulcer size averaged 3 cm (range 1–5 cm) and a significant number of the ulcers were located in the pylorus, duodenal bulb or second duodenum

(► **Table 1**). In comparison to the data presented by Elmunzer et al., the rebleeding rate in our study was distinctly reduced to 8%. It seems that high-risk patients with complex and large peptic ulcer bleeding benefit from OTSC treatment, due to the larger clip size and higher compression force on the tissue. In an in vitro model, Naegel et al. showed increased hemodynamic pressure on bleeding vessels after application of OTSC in comparison to standard clip systems and their results support the superiority of OTSC for large, complex ulcers [23]. Furthermore 92% (n=92) of the treated ulcers in this study were classified as Forrest Ia (28%), Ib (12%) and IIb (52%) ulcers and on that account identified as lesions at high risk lesions for persistent bleeding or rebleeding. The recently published ESGE guidelines for diagnosis and management of non-variceal upper gastrointestinal bleeding recommend that Forrest Ia, Ib and IIa peptic ulcers should receive endoscopic hemostasis and support this procedure [27].

Preliminary clinical data published so far are promising. Manno et al. published 40 cases in which they used OTSC as first-line therapy in NVUGIB with technical success and hemostasis in 100% of the cases [28]. Another study from Manta et al. reported on about 30 patients with bleeding lesions who were treated, with primary hemostasis achieved in 97%, and they concluded that the macroclip is a safe and effective option when conventional treatments have failed [11]. Two smaller case series reported clinical success rates between 78% and 100% [10, 12]. Our results are close to those in the published case series.

In our experience a potential benefit of the OTSC system is that after efficient application on the bleeding site and because of a higher compression force on the tissue up to 8–9 Newton, antiplatelet therapy and anticoagulants can be resumed rapidly. In the studied cohort, those medications were restarted within 24 to 48 hours, which could be one reason why the rate of bleeding-related mortality was almost halved in cardiac patients in comparison to published data, but that remains a hypothesis which needs to be evaluated in controlled prospective trials.

On the other hand, 8 patients presented with early (n=5; ≤ 24 hours) or late rebleeding (n=3; ≤ 30 days) after initial successful hemostasis with OTSC, and 7 of 8 were receiving anticoagulants or antiplatelet therapy (► **Fig. 6**). In those 8 patients anticoagulation or antiplatelet therapy was the main predictor of rebleeding. Use of anticoagulation will likely increase in the future due to a progressively aging society and increased numbers of patients at high risk for thromboembolism or stroke who might benefit from anticoagulation [3, 29]. Managing such patients remains challenging with regard to when anticoagulation needs to be discontinued. Improved endoscopic treatment of NVUGIB in anticoagulated patients might be achieved by new devices such as the OTSC that allow for better tissue apposition and compression of bleeding vessels. However, the OTSC system might come with potential limitations and disadvantages. In the case of active bleeding, the scope must be removed to load the device. In rare cases, the bleeding site is lost during this maneuver. Furthermore, the plastic cap with the loaded OTSC can make it difficult to intubate the

esophagus or traverse any luminal stenosis, as we have seen in 1 patient with a malignant pyloric stenosis. It is also challenging to target lesions that are situated in the posterior-inferior duodenal wall. Our data demonstrated that failure of initial hemostasis fails or rebleeding after hemostatic treatment, is associated with significantly higher morbidity and mortality (► **Fig. 3**).

Another limitation of our study lies in its retrospective design. Furthermore, the bi-centric retrospective design might have resulted in some selection bias. The number of patients included in this study also was limited. Despite these limitations we present the largest cohort published to date on OTSC treatment for NVUGIB in patients with cardiovascular comorbidity and/or under active anticoagulation.

Conclusion

In conclusion, this study demonstrates that OTSC is an efficient first-line or second-line treatment for high-risk patients with severe NVUGIB and for treatment of recurrent NVUGIB in complex, large ulcers. The OTSC allowed for successful short- and long-term hemostasis in a high-risk patient group. Further prospective and ideally comparative studies are required to evaluate OTSC in comparison with other endoscopic modalities for NVUGIB.

Acknowledgments

This project was supported by the “Endo-Verein Erlangen,” a registered non-profit training organization.

Competing interests

None

References

- [1] Barkun AN, Bardou M, Kuipers EJ et al. International consensus recommendations on the management of patients with nonvariceal upper gastrointestinal bleeding. *Annals of internal medicine* 2010; 152: 101–113
- [2] Bakkevold KE. Time trends in incidence of peptic ulcer bleeding and associated risk factors in Norway 1985-2008. *Clin Exp Gastroenterol* 2010; 3: 71–77
- [3] Loperfido S, Baldo V, Piovesana E et al. Changing trends in acute upper-GI bleeding: a population-based study. *Gastrointest Endosc* 2009; 70: 212–224
- [4] Kang JY, Elders A, Majeed A et al. Recent trends in hospital admissions and mortality rates for peptic ulcer in Scotland 1982-2002. *Alimentary Pharmacol Ther* 2006; 24: 65–79
- [5] Leontiadis GI, Molloy-Bland M, Moayyedi P et al. Effect of comorbidity on mortality in patients with peptic ulcer bleeding: systematic review and meta-analysis. *Am J Gastroenterol* 2013; 108: 331–345; quiz 346
- [6] von Renteln D, Vassiliou MC, Rothstein RI. Randomized controlled trial comparing endoscopic clips and over-the-scope clips for closure of natural orifice transluminal endoscopic surgery gastrotomies. *Endoscopy* 2009; 41: 1056–1061

- [7] Kirschniak A, Kratt T, Stuker D et al. A new endoscopic over-the-scope clip system for treatment of lesions and bleeding in the GI tract: first clinical experiences. *Gastrointest Endosc* 2007; 66: 162–167
- [8] Haito-Chavez Y, Law JK, Kratt T et al. International multicenter experience with an over-the-scope clipping device for endoscopic management of GI defects (with video). *Gastrointest Endosc* 2014; 80: 610–622
- [9] Baron TH, Song LM, Ross A et al. Use of an over-the-scope clipping device: multicenter retrospective results of the first U.S. experience (with videos). *Gastrointest Endosc* 2012; 76: 202–208
- [10] Chan SM, Chiu PW, Teoh AY et al. Use of the Over-The-Scope Clip for treatment of refractory upper gastrointestinal bleeding: a case series. *Endoscopy* 2014; 46: 428–431
- [11] Manta R, Galloro G, Mangiavillano B et al. Over-the-scope clip (OTSC) represents an effective endoscopic treatment for acute GI bleeding after failure of conventional techniques. *Surg Endosc* 2013; 27: 3162–3164
- [12] Skinner M, Gutierrez JP, Neumann H et al. Over-the-scope clip placement is effective rescue therapy for severe acute upper gastrointestinal bleeding. *Endoscop Int Open* 2014; 2: E37–40
- [13] Wedi E, Gonzalez S, Menke D et al. One hundred and one over-the-scope-clip applications for severe gastrointestinal bleeding, leaks and fistulas. *World J Gastroenterol* 2016; 22: 1844–1853
- [14] Kyaw M, Tse Y, Ang D et al. Embolization versus surgery for peptic ulcer bleeding after failed endoscopic hemostasis: a meta-analysis. *Endoscop Int Open* 2014; 2: E6–E14
- [15] Lewis JD, Bilker WB, Brensinger C et al. Hospitalization and mortality rates from peptic ulcer disease and GI bleeding in the 1990s: relationship to sales of nonsteroidal anti-inflammatory drugs and acid suppression medications. *The Am J Gastroenterol* 2002; 97: 2540–2549
- [16] Martins NB, Wassef W. Upper gastrointestinal bleeding. *Curr Opin Gastroenterol* 2006; 22: 612–619
- [17] Esrailian E, Gralnek IM. Nonvariceal upper gastrointestinal bleeding: epidemiology and diagnosis. *Gastroenterol Clin North Am* 2005; 34: 589–605
- [18] Lanas A, Wu P, Medin J et al. Low doses of acetylsalicylic acid increase risk of gastrointestinal bleeding in a meta-analysis. *Clin Gastroenterol Hepatol* 2011; 9: 762–768, e766
- [19] Laine L, Jensen DM. Management of patients with ulcer bleeding. *Am J Gastroenterol* 2012; 107: 345–360; quiz 361
- [20] Gralnek IM, Barkun AN, Bardou M. Management of acute bleeding from a peptic ulcer. *N Engl J Med* 2008; 359: 928–937
- [21] Sung JJ, Tsoi KK, Lai LH et al. Endoscopic clipping versus injection and thermo-coagulation in the treatment of non-variceal upper gastrointestinal bleeding: a meta-analysis. *Gut* 2007; 56: 1364–1373
- [22] Albert JG, Friedrich-Rust M, Woeste G et al. Benefit of a clipping device in use in intestinal bleeding and intestinal leakage. *Gastrointest Endosc* 2011; 74: 389–397
- [23] Naegel A, Bolz J, Zopf Y et al. Hemodynamic efficacy of the over-the-scope clip in an established porcine cadaveric model for spurting bleeding. *Gastrointest Endosc* 2012; 75: 152–159
- [24] Hackett NJ, De Oliveira GS, Jain UK et al. ASA class is a reliable independent predictor of medical complications and mortality following surgery. *Int J Surg* 2015; 18: 184–190
- [25] Elmunzer BJ, Young SD, Inadomi JM et al. Systematic review of the predictors of recurrent hemorrhage after endoscopic hemostatic therapy for bleeding peptic ulcers. *Am J Gastroenterol* 2008; 103: 2625–2632; quiz 2633
- [26] Crooks CJ, West J, Card TR. Comorbidities affect risk of nonvariceal upper gastrointestinal bleeding. *Gastroenterol* 2013; 144: 1384–1393, e1381–1382; quiz e1318–1389
- [27] Gralnek IM, Dumonceau JM, Kuipers EJ et al. Diagnosis and management of nonvariceal upper gastrointestinal hemorrhage: European Society of Gastrointestinal Endoscopy (ESGE) Guideline. *Endoscopy* 2015; 47: a1–a46
- [28] Manno M, Mangiafico S, Caruso A et al. First-line endoscopic treatment with OTSC in patients with high-risk non-variceal upper gastrointestinal bleeding: preliminary experience in 40 cases. *Surg Endosc* 2016; 30: 2026–2029
- [29] Hippisley-Cox J, Coupland C. Predicting risk of upper gastrointestinal bleed and intracranial bleed with anticoagulants: cohort study to derive and validate the Qbleed scores. *BMJ* 2014; 349: g4606
- [30] Voermans RP, Le Moine O, von Renteln D et al. Efficacy of endoscopic closure of acute perforations of the gastrointestinal tract. *Clin Gastroenterol Hepatol* 2012; 10: 603–608