



# Spontaneous Cervicothoracic Extradural Hematoma with Rare Presentation in Pediatric Patient with Stroke-Like Features in Association with COVID-19, Presenting as Management Dilemma

Vikas Chandra Jha<sup>1</sup> Shahnawaz Alam<sup>1</sup> Neeraj Jha<sup>1</sup>

<sup>1</sup>Department of Neurosurgery, All India Institute of Medical Sciences, Patna, Bihar, India

AJNS 2023;18:196–200.

Address for correspondence Vikas Chandra Jha, MCH, FINR, Department of Neurosurgery, All India Institute of Medical Sciences, Patna, 801507, Bihar, India  
(e-mail: id-drvikaschandrajha@aiimspatna.org).

## Abstract

Presentation of cervico-thoracic extradural hematoma in pediatric age is rare with stroke-like features. Its association with COVID-19 in the active stage of the disease had not been reported and its management presents a management dilemma as COVID-19 with stroke-like features.

A 14-year-old boy was referred to our institute with complaints of sudden-onset upper and middle back pain, associated with loss of sensation below the middle of the back, sudden progressive weakness of both lower limbs (power 0/5) and upper limbs (power grade-2/5), and incontinence of urine, following bouts of vomiting 12 days back. There was no history of trauma, bleeding diathesis, etc. Blood investigation was suggestive of leukocytosis, and RT-PCR test for COVID-19 was positive with raised D-dimer, serum ferritin, and C-reactive protein. MRI spine was suggestive of cervicothoracic extradural hematoma extending from C5-D3 level and compressing the spinal cord. The patient refused surgical decompression and was managed conservatively, following which he improved with power grade in limbs to 4/5.

## Keywords

- ▶ spontaneous cervical epidural hematoma
- ▶ pediatric patient
- ▶ stroke
- ▶ COVID-19

Surgical decompression is the treatment of choice but the patient can sometimes improve on medical management. Association of COVID-19 with spontaneous cervicothoracic extradural hematoma had not been reported earlier in the active stage, but its role in inducing vasculopathy and increased chances of bleeding at the uncommon site had been reported in the literature, and it may precipitate such cervical epidural hematoma.

## Introduction

Patients presenting with sudden spontaneous onset of quadriplegia and neck pain with diminished spontaneous

response suggests more toward stroke and early evaluation with computed tomography (CT) angiography gives an initial hint of lesion outside the cranium. Early CT angiography may help the clinician to avoid starting

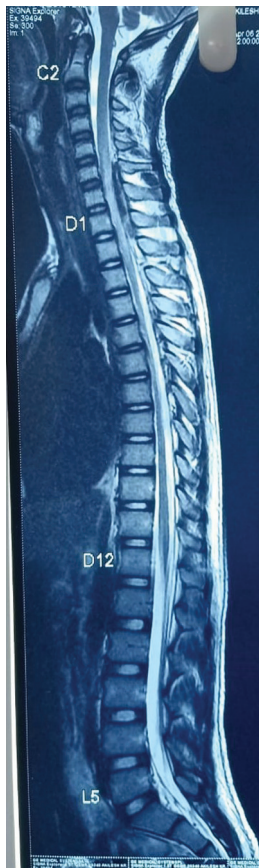article published online  
March 31, 2023

DOI <https://doi.org/10.1055/s-0043-1768249>.  
ISSN 2248-9614.

© 2023. Asian Congress of Neurological Surgeons. All rights reserved.

This is an open access article published by Thieme under the terms of the Creative Commons Attribution-NonDerivative-NonCommercial-License, permitting copying and reproduction so long as the original work is given appropriate credit. Contents may not be used for commercial purposes, or adapted, remixed, transformed or built upon. (<https://creativecommons.org/licenses/by-nc-nd/4.0/>)

Thieme Medical and Scientific Publishers Pvt. Ltd., A-12, 2nd Floor, Sector 2, Noida-201301 UP, India



**Fig. 1** T2 Sagittal sequence of the whole spine suggesting extradural hematoma extending from C5-T2.

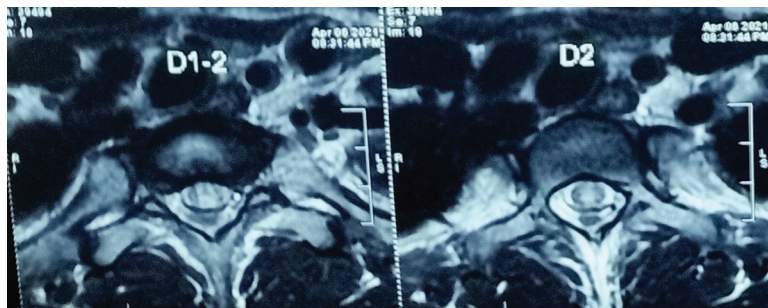
anticoagulants, which may have a catastrophic effect on patients if he harbors pathologies such as epidural hematoma (EDH) in the spine, which is rare and may manifest with such symptoms.<sup>1–3</sup> There are very few case reports of epidural hematoma presenting with features suggesting stroke, especially in pediatric patients.<sup>4</sup> The association of patients with COVID-19 is challenging as it needs starting low molecular weight heparin to avoid thromboembolic complications and presently, we did not find such patients reported in the literature. We tried to review the literature of patients with such illnesses specially and treatment options utilized and challenges we faced in the management of our patients.

## Case Details

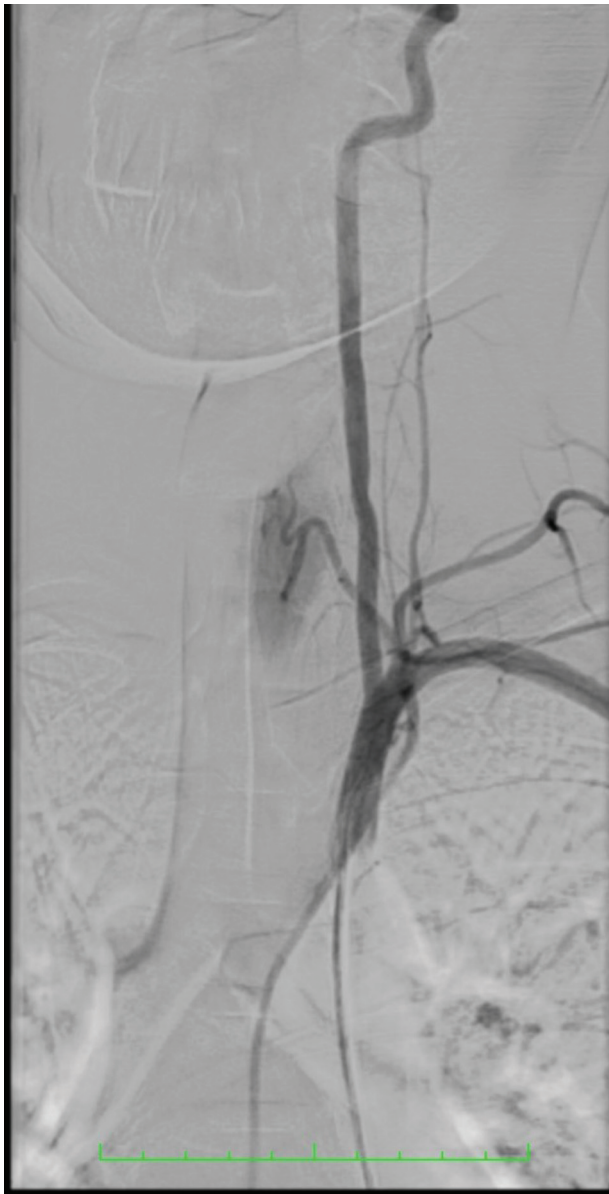
An 11-year-old boy was referred to our institute with complaints of sudden-onset upper and middle back pain, associated with loss of sensation below the middle of the back, sudden progressive weakness of both lower limbs and hands, and incontinence of urine, following bouts of vomiting 12 days ago. He denied any history of trauma or surgery, respiratory or gastrointestinal symptoms, or any drug intake, before the onset of these symptoms but having intermittent fever and occasional respiratory difficulty when he felt short of breaths for the last 7 days. No past or family history was suggestive of blood dyscrasias or coagulopathy. Cerebrospinal fluid (CSF) analysis was done before referral and was unremarkable, except for mild lymphocytosis (total count: 8 cells/mm<sup>3</sup>, 80% lymphocytes) and mildly elevated protein (52 mg/dL, ref. range 10–40 mg/dL); he had received steroid treatment for suspected Guillain–Barre syndrome but had no improvement. On admission to our hospital, serum D-dimer was 3 µg/mL, serum ferritin 1 µg/mL, and C-reactive protein 12 mg/L. COVID antigen test done at admission at our hospital was negative but RT-PCR test was positive.

Neurological examination revealed bilateral lower limb weakness (power: grade 0), power in upper limbs 2/5 with weakness of bilateral handgrip of 70 to 80%, and 50% sensory loss below T4. Non-contrast CT of the cervical and thoracic spine did not reveal any abnormality and CT head was normal. An MRI obtained subsequently showed a T1-hyper and T2-hypointense extradural lesion, extending from the level of C5–6 to D2–3 intervertebral disc spaces (–Figs. 1 and 2), suggestive of an epidural hematoma, with compression of the underlying spinal cord. Routine blood investigations and coagulation profiles were normal. To rule out vascular malformation, a spinal angiogram was obtained, which was unremarkable (–Fig. 3).

Supportive treatment for COVID-19 was started. He was treated with oxygen by mask, low molecular weight heparin, tab azithromycin, injection remdesivir and other supportive treatment with adequate dose regimen for COVID treatment and the patient was stabilized. An early surgical evacuation was planned, but the patient and next-of-kin did not consent for the same, so the patient was kept on conservative management with strict bed rest, supportive treatment, and rigorous physiotherapy. He was found to be COVID-19



**Fig. 2** Axial T2 showing extra dural hematoma compressing the spinal cord.

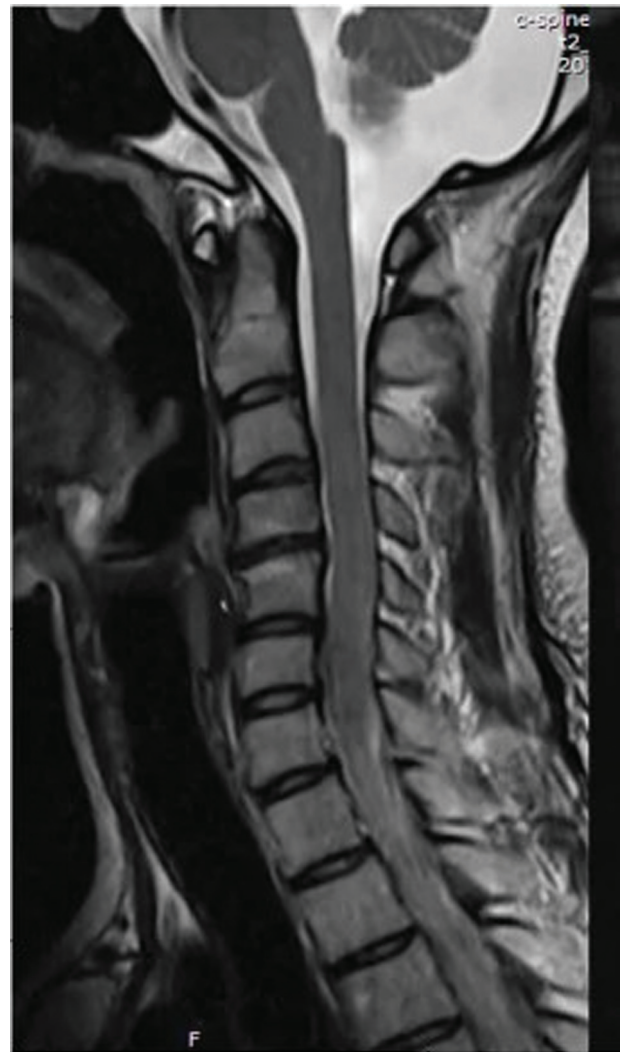

**Fig. 3** DSA cervical spine suggest no arteriovenous malformation.

negative on reverse transcriptase-polymerase chain reaction (RT-PCR) after 12 days of supportive treatment. At the last follow-up (at 6 months), he had almost complete pain relief, improved sensory perception, and a slight improvement in the handgrip (50%) with power in the limbs 4/5 and MRI cervical spine showing almost complete resolution of cervical EDH (► Fig. 4).

## Discussion

The patient in the present study was an 11-year old boy. This entity had been detected in all age groups with an incidence of 0.1 per 100,000 population but its presence in the pediatric population is rare and nearly 35 cases had been reported.<sup>1-3</sup> Next, 40% of the reported spinal EDH is spontaneous in origin and the most common site is the cervicothoracic junction followed by the thoracic region.<sup>4</sup>



**Fig. 4** Follow-up sagittal T2 MRI suggesting almost complete resolution of extradural cervical hematoma.

Different theories of its development have been suggested. One of them suggests that such bleeding is through the epidural venous plexus. These venous plexus lacks sphincters and sudden pressure changes transmitted through the abdominal and thoracic cavity may be a precipitating factor for rupture of this plexus.<sup>4-6</sup> In the present patient, repeated bouts of vomiting and cough may have caused a sudden rise in the intravascular pressure in these epidural venous channels. Another study suggested that this epidural bleeding is due to a rupture in the arterial arcade around the upper cervical vertebrae. As per their proposition, the intra-arterial pressure is more than the intrathecal pressure and venous pressure is less than the intravenous pressure, resulting in rapid bleeding through the artery, which may be the major cause of bleeding.<sup>7</sup> In this patient, both the propositions can hold good as the etiology for bleeding.

Our patient presented with sudden severe neck pain, upper back pain, and weakness in the bilateral upper and lower limb, suggesting features resembling stroke, such type of clinical presentation had been reported by Tiryaki et al, where his patient had similar manifestations but the patient

had increased international normalized ratio (INR), prothrombin time (PT), activated partial thromboplastin time (aPTT). However, in our case, the patient was not having deranged coagulation profile neither there was any history suggestive of taking anticoagulants.<sup>7</sup> SCEDH on the backdrop of COVID-19 infection has been reported by Lim et al, where his patient, a 79-year-old elderly female, developed stroke-like features 2.5 months after recovering from COVID-19.<sup>8</sup> While presenting for SCEDH patients in the study by Lin et al, neither RT-PCR positivity nor any serological marker was present that could be suggestive of systemic inflammatory response syndrome.<sup>8</sup> Our patient on the contrary had 1 month of indolent course of fever, dyspnea and he was RT-PCR positive for COVID-19 together with raised C-reactive protein, D-dimer, and ferritin level, and HRCT suggestive of bilateral lobar ground glass appearance. The patient in the present study had bouts of recurrent vomiting, followed by features of sudden pain in the upper back and neck with limb weakness. The probable suggestive mechanism for this may be due to a sudden rise in arteriolar or venules of the cervical spine, which had been affected by COVID vasculopathy adding in the sudden precipitation of this event.

COVID-19 is a SARS-CoV-2 syndrome that can involve all the organs, including the circulatory system involving arteries, arterioles, veins, venules, and capillaries.<sup>9–11</sup> They affect the integrity of the vascular lining as well as cause vasculitis-like features. Pinto et al have documented COVID-19-associated vasculopathy in the brain and reversal of the motor weakness of right upper limbs and bilateral lower limbs in his patients by plasma exchange therapy, which was suggested due to the reversal of autoimmune vasculopathy.<sup>10</sup>

Vonck et al in their study on neurological manifestations and neuroinvasive mechanisms of the severe acute respiratory syndrome coronavirus type 2 reported 36% involvement of CNS and PNS, of which 5% have cerebrovascular pathology.<sup>11</sup>

In the present scenario, starting anticoagulant in the form of low molecular weight heparin and steroid was imperative with fresh frozen plasma transfusion and keeping a close watch on any further deterioration; meanwhile, he refused for surgery and was conservatively managed and discharged once he was maintaining saturation near 96 to 98% without O<sub>2</sub> supplementation and RT-PCR negative. On follow-up at 3 months, the power in lower limbs was improving on treatment and at last follow-up, the power in bilateral lower limbs were 4/5 and in the upper limbs 4 +/5 with mild grip weakness. Such improvement in symptoms on conservative management had been reported by Rasck et al in 24% of patients with spinal epidural hematoma and 48% of patients who were surgically treated.<sup>12</sup> Improvement in symptoms depends upon the severity of weakness as well duration since the onset of features to treat. The slow improvement over 3 months suggests that a patient presenting with a similar situation can improve even if he does not undergo laminectomy and decompression.

## Conclusion

Patients with spontaneous cervicothoracic extradural hematoma may mimic stroke and the patient should undergo

radiological investigation as MRI/CT head and cervical spine to rule out stroke before starting anticoagulant as it can cause cerebral hemorrhage. Surgical decompression on anticoagulants is the treatment of choice but the patient can improve sometimes on medical management. The association of COVID-19 with spontaneous cervicothoracic extradural hematoma had not been reported earlier in the active stage but its role in inducing vasculopathy and increased chances of bleeding at the uncommon site had been reported in the literature and in the present patient, although it appears to be by chance but its role in precipitating such events cannot be ignored.

## Consent

The patient's relatives' consent was taken at the time of admission to use his data for teaching and research purposes.

## Authors' Contributions

Conceptualization, clinical work, data collection, data analysis, manuscript drafting and revision were done by VCJ. Data collection and analysis were done by VCJ, NJ, and MSA. Data analysis and manuscript supervision were done by VCJ, MSA, and NJ. All the authors have read and approved the final version of manuscript. This manuscript has neither been presented as whole or part in any conference or scientific meeting. This article is neither published nor under consideration for publication anywhere else.

## Funding

None.

## Conflict of Interest

None declared.

## References

- 1 Salehpour F, Mirzaei F, Kazemzadeh M, Alavi SAN. Spontaneous epidural hematoma of cervical Spine. *Int J Spine Surg* 2018;12(01):26–29
- 2 Poonai N, Rieder MJ, Ranger A. Spontaneous spinal epidural hematoma in an 11-month-old girl. *Pediatr Neurosurg* 2007;43(02):121–124
- 3 Tailor J, Dunn IF, Smith E. Conservative treatment of spontaneous spinal epidural hematoma associated with oral anticoagulant therapy in a child. *Childs Nerv Syst* 2006;22(12):1643–1645
- 4 Liu Z, Jiao Q, Xu J, Wang X, Li S, You C. Spontaneous spinal epidural hematoma: analysis of 23 cases. *Surg Neurol* 2008;69(03):253–260, discussion 260
- 5 Güzel A, Simşek O, Karasalihoğlu S, et al. Spontaneous spinal epidural hematoma after seizure: a case report. *Clin Pediatr (Phila)* 2007;46(03):263–265
- 6 Beatty RM, Winston KR. Spontaneous cervical epidural hematoma. A consideration of etiology. *J Neurosurg* 1984;61(01):143–148
- 7 Tiryaki M, Basaran R, Aydin SO, Efendioglu M, Balkuv E, Balak N. Spontaneous cervical epidural hematoma with hemiparesis mimicking cerebral stroke. *Case Rep Emerg Med* 2014;2014:210146. Doi: 10.1155/2014/210146
- 8 Lim SW, Wong E. Spontaneous epidural hematoma of the cervical spine in an elderly woman with recent COVID-19 infection: a case report. *Am J Case Rep* 2020;21:e926784

- 9 Becker RC. COVID-19-associated vasculitis and vasculopathy. *J Thromb Thrombolysis* 2020;50(03):499–511. Doi: 10.1007/s11239-020-02230-4
- 10 Pinto AA, Carroll LS, Nar V, Varatharaj A, Galea I. CNS inflammatory vasculopathy with antimyelin oligodendrocyte glycoprotein antibodies in COVID-19. *Neurol Neuroimmunol Neuroinflamm* 2020;7(05):e813
- 11 Vonck K, Garrez I, De Herdt V, et al. Neurological manifestations and neuro-invasive mechanisms of the severe acute respiratory syndrome coronavirus type 2. *Eur J Neurol* 2020;27(08):1578–1587. Doi: 10.1111/ene.14329
- 12 Raasck K, Habis AA, Aoude A, et al. Spontaneous spinal epidural hematoma management: a case series and literature review. *Spinal Cord Ser Cases* 2017;3:16043. Doi: 10.1038/scsandc.2016.43