

Early Muscle MRI Findings in a Pediatric Case of Emery-Dreifuss Muscular Dystrophy Type 1

Chiara Panicucci¹ Sara Casalini¹ Monica Traverso² Noemi Brolatti² Serena Baratto¹
Lizzia Raffaghello¹ Marina Pedemonte² Luca Doglio³ Maria Derchi⁴ Giorgio Tasca⁵
Beatrice M. Damasio⁶ Chiara Fiorillo^{2,7} Claudio Bruno^{1,7}

¹Center of Translational and Experimental Myology, IRCCS Istituto Giannina Gaslini, Genova, Italy

²Pediatric Neurology and Muscle Disease Unit, IRCCS Istituto Giannina Gaslini, Genova, Italy

³Physical Medicine and Rehabilitation Unit, IRCCS Istituto Giannina Gaslini, Genova, Italy

⁴Cardiology Unit, IRCCS Istituto Giannina Gaslini, Genova, Italy

⁵Neurology Unit, IRCCS Fondazione Policlinico Universitario A. Gemelli, Rome, Italy

⁶Radiology Department, IRCCS Istituto Giannina Gaslini, Genova, Italy

Address for correspondence Claudio Bruno, MD, PhD, Center of Translational and Experimental Myology, IRCCS Istituto Giannina Gaslini, Via G. Gaslini, 5 I-16147 Genova, Italy (e-mail: claudiobruno@gaslini.org).

⁷Department of Neuroscience, Rehabilitation, Ophthalmology, Genetics, Maternal and Child Health - DINO GMI, University of Genova, Genova, Italy

Neuropediatrics 2023;54:426–429.

Abstract

Emery-Dreifuss muscular dystrophy (EDMD) is a rare disease characterized by early contractures, progressive muscle weakness, and cardiac abnormalities. Different subtypes of EDMD have been described, with the two most common forms represented by the X-linked EDMD1, caused by mutations in the *EMD* gene encoding emerin, and the autosomal EDMD2, due to mutations in the *LMNA* gene encoding lamin A/C. A clear definition of the magnetic resonance imaging (MRI) pattern in the two forms, and especially in the rarer EDMD1, is still lacking, although a preferential involvement of the medial head of the gastrocnemius has been suggested in EDMD2. We report a 13-year-old boy with mild limb girdle muscle weakness, elbow and ankle contractures, with absence of emerin at muscle biopsy, carrying a hemizygous frameshift mutation on the *EMD* gene (c.153dupC/p.Ser52Glufs*9) of maternal inheritance. Minor cardiac rhythm abnormalities were detected at 24-hour Holter electrocardiogram and required β -blocker therapy. MRI scan of the thighs showed a mild diffuse involvement, while tibialis anterior, extensor digitorum longus, peroneus longus, and medial gastrocnemius were the most affected muscles in the leg. We also provide a review of the muscular MRI data in EDMD patients and highlight the relative heterogeneity of the MRI patterns found in EDMDs, suggesting that muscle MRI should be studied in larger EDMD cohorts to better define disease patterns and to cover the wide disease spectrum.

Keywords

- ▶ Emery-Dreifuss muscular dystrophy
- ▶ muscle MRI
- ▶ weakness
- ▶ emerin
- ▶ contractures

Introduction

Emery-Dreifuss muscular dystrophy (EDMD) is a rare clinical entity characterized by the triad of early contractures, pro-

gressive muscle weakness and atrophy, and cardiac abnormalities.¹ Contractures, most prominently involving neck extension, elbow flexion, and heel cord tightening, frequently develop in the first decade of life, before muscle weakness.

received

December 19, 2022

accepted after revision

April 18, 2023

article published online

May 31, 2023

© 2023, Thieme. All rights reserved.

Georg Thieme Verlag KG,

Rüdigerstraße 14,

70469 Stuttgart, Germany

DOI <https://doi.org/>

10.1055/s-0043-1768989.

ISSN 0174-304X.

The latter usually presents in the second or third decade, with a “humero-peroneal” pattern, affecting proximal arms and distal leg muscles. Cardiac complications, namely, atrial standstill, supraventricular tachycardia (SVT), multifocal atrial arrhythmia, and dilated cardiomyopathy in a minority of patients, develop independently from the neuromuscular findings, do not correlate with the extent of skeletal muscle involvement,² and often lead to permanent pacemaker or implantable cardioverter-defibrillator (ICD) implantation.^{3,4}

Different subtypes of EDMD have been described according to the mutated gene and inheritance.⁵ The most frequent forms are the X-linked EDMD1, due to mutations in the emerin (*EMD*) gene, and the autosomal dominant (AD) EDMD2 associated to defects on the lamin A/C (*LMNA*) gene; the EDMD3 subtype, very rare, is also due to *LMNA* defects, with an autosomal recessive inheritance. Other rare AD forms are the EDMD4 and EDMD5 associated to mutations in the spectrin repeat containing nuclear envelope protein (*SYNE1* and *SYNE2*), respectively. The EDMD6 is an X-linked subtype due to mutations in the four and a half LIM domains 1 (*FHL*) gene, while the AD EDMD7 is associated to the transmembrane protein 43 (*TMEM43*) gene. Titin (*TTN*) mutations have been also associated to a EDMD phenotype in few reports.^{6,7}

The two main EDMD subtypes, resulting from mutations in *EMD* and *LMNA*, show clinical overlap, although some peculiar features are recognizable. EDMD2 is usually characterized by a more severe progression of muscular weakness,^{1,5} and in EDMD1 the onset of muscular symptoms usually precedes cardiac complications. Muscle biopsy is also helpful in identifying the absence of emerin expression in the nuclei of EDMD1 patients, although it is not able to characterize EDMD2 subjects by immunohistochemistry since lamin A/C is normally expressed in these patients.¹

Muscle magnetic resonance imaging (MRI) has also been suggested to help discriminating between the two forms. Specifically, MRI pattern involvement of gastrocnemius was indicated as a possible disease marker, with early studies suggesting that EDMD2 subjects show medial gastrocnemius involvement and sparing of the lateral head, at variance with EDMD1 patients.⁸ However, later studies have reported EDMD1 patients with medial gastrocnemius involvement.^{5,9}

Here, we report a EDMD1 13-year-old boy with minor cardiac rhythm abnormalities and a peculiar MRI which not entirely recapitulates what have been reported in previous MRI series, highlighting the need for muscle MRI studies on larger EDMDs cohorts to better define a possible disease pattern.

Case Presentation

A 13-year-old child came to our attention because Achilles tendon contractures noted few years before. He was born at term, after an uneventful pregnancy, from nonconsanguineous parents. Family history was positive for an uncle on maternal side (→Fig. 1A, subject II-6) who suffered from elbows contractures, mild muscular weakness, and cardiac rhythm abnormalities from his youth, leading to an ICD implantation at 50 years of age. Moreover, an aunt (→Fig. 1A, subject II-3) and the grandmother (→Fig. 1A, subject I-2), both on maternal side, developed respectively a cardiac arrhythmia, requiring ablation of the abnormal electrical pathway, and heart failure in their adult age.

He showed normal cognitive and motor development. Neurological examination showed elbow and Achilles tendon contractures, mild pelvic girdle weakness with waddling

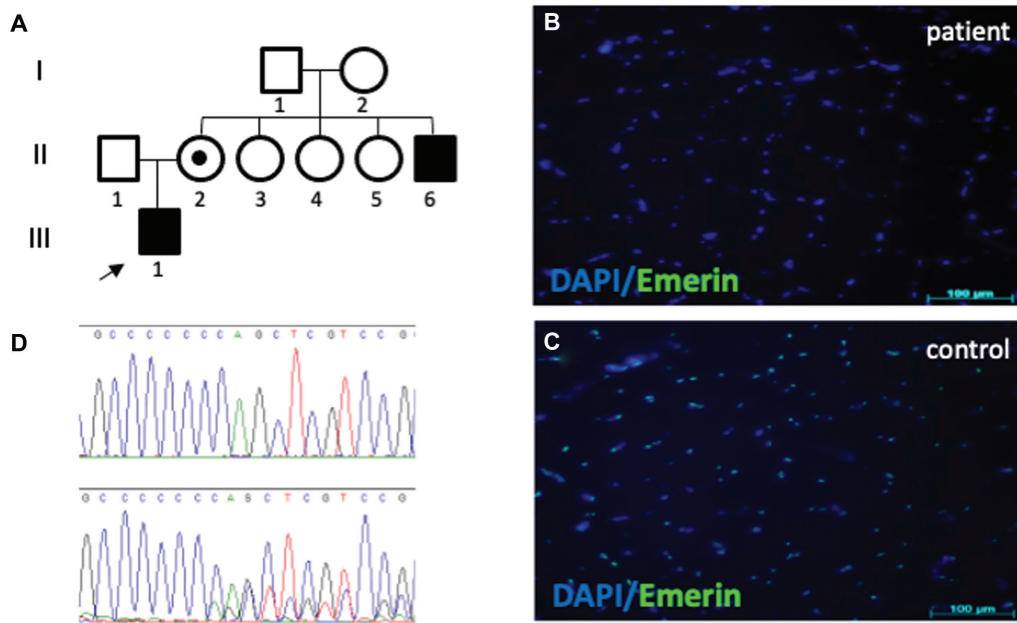


Fig. 1 Family pedigree, showing the proband, subject III-1, the affected uncle, subject II-6, and the mother carrier, subject II-2 (A). Quadriceps muscle biopsy revealed absence of nuclear emerin expression by immunofluorescence study in patient’s sample (B) compared with the positive control (C). Deoxyribonucleic acid (DNA) sequence electropherograms showing nucleotide mutations in the subject (upper panel) and the mother (lower panel) (D).

This document was downloaded for personal use only. Unauthorized distribution is strictly prohibited.

gait, associated with mild distal hypotrophy of lower limbs, and reduced deep tendon reflexes. Heel ambulation was not possible, and he presented a mild scoliosis. No neck extensor muscles contractions were noted. At the 6-minute walk test he walked 409 m, and he scored 28/34 at the North Star Ambulatory Assessment scale. An initial restrictive respiratory disorder was documented by pulmonary function tests as the forced vital capacity measured 2.7 l (76%), and the forced expiratory volume in the 1st second 2.4 l (83%).

Quadriceps muscle biopsy performed at 13 years showed mild dystrophic changes consisting of mild fiber size variability, and a few necrotic fibers. ATPase pH 9.4 displayed good fibrillar type differentiation, with predominance of type II fibers without overt fiber grouping. Nuclear emerin expression by immunofluorescence study was absent in patient's sample (►Fig. 1B, C).

Direct sequencing of the *EMD* gene displayed a hemizygous frameshift mutation (c.153dupC/p.Ser52Glufs*9) previously reported¹⁰ (►Fig. 1D). The mother resulted a carrier of the variant (►Fig. 1A, subject II-2). Considered uncle clinical history, he was also tested showing the same mutation (►Fig. 1A, subject II-6).

At 13 years of age a 24-hour Holter electrocardiogram monitoring showed SVT requiring β -blocker therapy, while echocardiography was unremarkable.

Whole body muscle MRI showed tongue involvement (►Fig. 2A), fatty infiltration of paraspinal muscles at the lumbar level but not at the thoracic level (►Fig. 2B, C). Thigh muscles showed a mild diffuse involvement (►Fig. 2D), while in the lower leg the anterolateral compartment (tibialis anterior, extensor digitorum longus, peroneus longus) and medial gastrocnemius were mostly affected, the latter with a subfascial rim of fatty replacement, with sparing of the lateral gastrocnemius (►Fig. 2E). Soleus was affected to a lesser extent, more prominently in the distal part (►Fig. 2E).

The family of patient gave the consent for research studies on muscle specimens and for publication of this report and accompanying images. All procedures were performed in accordance with the ethical standards as stated in the Declaration of Helsinki.

Discussion

We report a pediatric case of EDMD1 presenting with joint contractures and mild lower limb muscle weakness, due to a frameshift mutation in the *EMD* gene.

Neuromuscular findings and age of onset were similar to those reported,^{1,11} with joint contractures emerging before muscle weakness. Muscle's biopsy results were consistent with previous data, displaying unspecific mild dystrophic changes,¹ with the anti-emerin antibody showing absence of staining of the nuclear membrane at the immunofluorescence study.

Conversely, muscle MRI pattern did not entirely recapitulate previous reports. MRI studies on EDMD1 are limited (summarized in ►Supplementary Fig. S1, available online only), and pediatric MRI data are scarce. The first MRI study on genetically determined EDMDs aimed to detect a specific

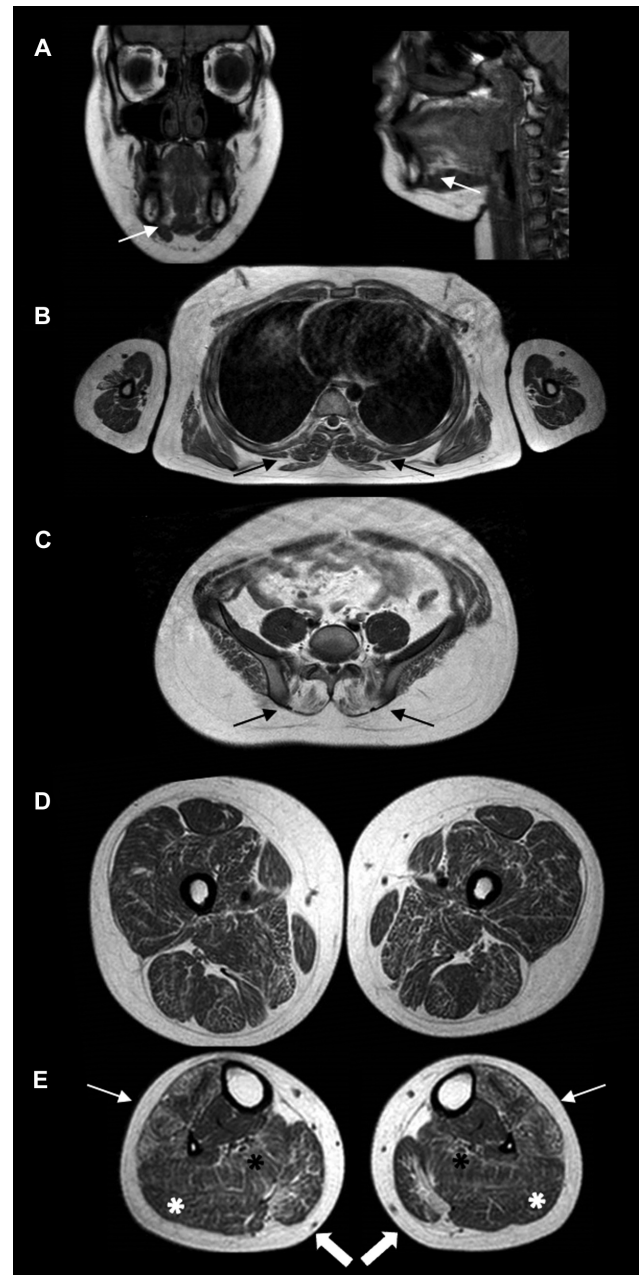

Fig. 2 Representative images of T1-weighted whole body muscle magnetic resonance imaging (MRI) scans at 13 years of age are shown. Cranial scans displayed fatty substitution of the tongue (white arrow) (A). Paraspinal muscles were spared at the thoracic level (black arrows) (B) while involved at the lumbar one (black arrows) (C). Thigh scans showed a mild diffuse involvement (D); in the lower leg, the anterolateral compartment (tibialis anterior, extensor digitorum longus, peroneus longus) (white arrows) and medial gastrocnemius were mostly affected (white thick arrows), the latter with a subfascial rim of fatty replacement, with sparing of the lateral gastrocnemius (white asterisk). Soleus was affected to a lesser extent, more prominently in the distal part (black asterisk) (E).

pattern to discriminate between EDMD1 and EDMD2 in a cohort of pediatric and adult patients (7 EDMD1 and 11 EDMD2). The authors reported a preferential involvement of the medial head of the gastrocnemius in EDMD2 patients, not present in the EDMD1 subjects.⁸

Another study, on a larger cohort of adult EDMDs (10 EDMD1 and 32 EDMD2), concluded that peroneus muscle involvement, more frequently affected in patients with mutations in the *EMD* gene (88% of EDMD1 patients, compared with the 40% of the EDMD2), could be useful to orientate the diagnosis between the two forms.¹² This work also carefully described muscular fatty replacement through several body regions, highlighting that the paravertebral muscles were involved in all EDMD subtypes, and the glutei muscles were mildly infiltrated in 80% of all EDMD patients. In the thigh area the semimembranosus and the long head of the biceps femoris muscles were the most frequently involved muscles, while rectus femoris, gracilis, and sartorius were relatively spared, without differences between EDMD1 and EDMD2 patients. Of note, they found that muscular fatty substitution was symmetrical through all the body regions.

Interestingly, tongue involvement was first reported in a 65-year-old EDMD1 patient manifesting with adult onset axial weakness, camptocormia, and minimal joint contractures.⁹

A recent study reported MRI data in 6 adolescent to adult EDMD1 patients, with 3 of those displaying selective fatty degeneration of the soleus and medial head of gastrocnemius in their early stage of the disease,⁵ while another study described for the first time edema-like abnormalities detected by short tau inversion recovery sequences affecting the vasti, hamstrings, and gastrocnemius muscles in a 22-year-old EDMD1 patient, suggesting that these edema-like changes may be a marker of early muscle pathology in EDMD1.¹³

Our patient diverged from the original description of the pediatric cases⁸ by the absence of sparing of medial gastrocnemius, while confirming the involvement of the peroneus and the sparing of rectus femoris and gracilis.^{5,9,12} Therefore, we confirm that the presence of anterolateral leg compartment involvement should raise the suspicion of mutations in *EMD* rather than in *LMNA* in a patient with a suggestive phenotype.

Conclusion

In conclusion, with this report and the revision of the muscle MRI data available, we underline the relative variability of the MRI patterns in EDMD and the partial overlap between the different forms, opening the way for further, large cohort studies in these diseases to better define the whole disease spectrum of involvement.

Authors' Contributions

C.P.: acquisition of data, conception, and drafting of the manuscript; S.C., N.B., M.P., L.D., M.D., and B.M.D.:

acquisition of data; M.T., S.B., and L.R.: experimental procedures; G.T.: discussion and revision of the manuscript; C.F.: discussion and revision the manuscript; C.B.: conception, drafting, and revision of the manuscript. All authors read, revised, and approved the final manuscript.

Funding

None.

Conflict of Interest

G.T., C.F., and C.B. are part of the European Reference Network (ERN) for neuromuscular diseases (Euro-NMD).

References

- Heller SA, Shih R, Kalra R, Kang PB. Emery-Dreifuss muscular dystrophy. *Muscle Nerve* 2020;61(04):436–448
- Marchel M, Madej-Pilarczyk A, Tymiąska A, et al. Echocardiographic features of cardiomyopathy in Emery-Dreifuss muscular dystrophy. *Cardiol Res Pract* 2021;2021:8812044
- Wang S, Peng D. Cardiac involvement in Emery-Dreifuss muscular dystrophy and related management strategies. *Int Heart J* 2019;60(01):12–18
- Groh WJ, Bhakta D, Tomaselli GF, et al. 2022 HRS expert consensus statement on evaluation and management of arrhythmic risk in neuromuscular disorders. *Heart Rhythm* 2022;19(10):e61–e120
- Yunisova G, Ceylaner S, Oflazer P, Deymeer F, Parman YG, Durmus H. Clinical and genetic characteristics of Emery-Dreifuss muscular dystrophy patients from Turkey: 30 years longitudinal follow-up study. *Neuromuscul Disord* 2022;32(09):718–727
- Chauveau C, Bonnemann CG, Julien C, et al. Recessive TTN truncating mutations define novel forms of core myopathy with heart disease. *Hum Mol Genet* 2014;23(04):980–991
- De Cid R, Ben Yaou R, Roudaut C, et al. A new titinopathy: childhood-juvenile onset Emery-Dreifuss-like phenotype without cardiomyopathy. *Neurology* 2015;85(24):2126–2135
- Mercuri E, Counsell S, Allsop J, et al. Selective muscle involvement on magnetic resonance imaging in autosomal dominant Emery-Dreifuss muscular dystrophy. *Neuropediatrics* 2002;33(01):10–14
- Brisset M, Ben Yaou R, Carlier RY, et al. X-linked Emery-Dreifuss muscular dystrophy manifesting with adult onset axial weakness, camptocormia, and minimal joint contractures. *Neuromuscul Disord* 2019;29(09):678–683
- Ura S, Hayashi YK, Goto K, et al. Limb-girdle muscular dystrophy due to emerin gene mutations. *Arch Neurol* 2007;64(07):1038–1041
- Helbling-Leclerc A, Bonne G, Schwartz K. Emery-Dreifuss muscular dystrophy. *Eur J Hum Genet* 2002;10(03):157–161
- Díaz-Manera J, Alejaldre A, González L, et al. Muscle imaging in muscle dystrophies produced by mutations in the *EMD* and *LMNA* genes. *Neuromuscul Disord* 2016;26(01):33–40
- Pinto MJ, Fromes Y, Ackermann-Bonan I, et al. Muscle MRI as a diagnostic challenge in Emery-Dreifuss muscular dystrophy. *J Neuromuscul Dis* 2022;9(05):649–654