


Multidirectional Nystagmus as the Presenting Sign of Brain Tumor with Hydrocephalus

Tommaso Bellini¹  Laura Siri² Elisa De Grandis^{2,3} Clelia Formigoni³ Domenico Tortora⁴
Emanuela Piccotti¹

¹Pediatric Emergency Room and Emergency Medicine, IRCCS Istituto Giannina Gaslini, Genoa, Italy

²Neuropsychiatry Unit, Gaslini Children Hospital, IRCCS Istituto Giannina Gaslini, Genoa, Italy

³Department of Neuroscience, Rehabilitation, Ophthalmology, Genetics, Maternal and Child Health (DINOGMI), University of Genoa, Italy

⁴Neuroradiology Unit, Gaslini Children Hospital, IRCCS Istituto Giannina Gaslini, Genoa, Italy

Address for correspondence Tommaso Bellini, MD, Pediatric Emergency Room and Emergency Medicine Unit, IRCCS Istituto Giannina Gaslini, Via G. Gaslini 5, 16147 Genoa, Italy (e-mail: tommasobellini@gaslini.org).

Neuropediatrics 2023;54:439–440.

A previously healthy 11-year-old boy was admitted to our Emergency Room for a 1-month history of intermittent diplopia. The main clinical signs were right-beating horizontal nystagmus with a vertical component in the upward gaze (► **Video 1**) and bilateral papilledema; he did not suffer headache, vomit, bradycardia, or any additional cerebellar signs such as ataxia, dysmetria, dysdiadochokinesis, or tremor. Brain magnetic resonance showed a large, disseminated, bulky mass involving the fourth ventricle and the mesencephalic aqueduct with cerebrospinal fluid dissemination along the lateral ventricles and the spinal cord, causing decompensating hydrocephalus and intracranial hypertension (► **Fig. 1**). The subsequent biopsy confirmed the histological diagnosis of medulloblastoma and its inoperability due to dissemination.

patients affected present with signs and symptoms of cerebellar dysfunction and increased intracranial pressure that may cause cranial nerve deficits, and the diagnosis is often delayed by many months after the first symptoms appear.¹

Interestingly, our patient reported only intermittent diplopia and the physical examination showed only horizontal/vertical nystagmus with no other neurological signs, emphasizing the importance of maintaining high clinical suspicion and the need for a detailed and prompt evaluation for the earliest possible diagnosis, even if the patient presents only subtle symptoms as diplopia.^{2,3}

Funding

None.

Conflict of Interest

None declared.

References

- 1 Kronenbuerger M, Olivi A, Zee DS. Pearls & oysters: positional vertigo and vertical nystagmus in medulloblastoma: a picture is worth a thousand words. *Neurology* 2018;90(04):e352–e354
- 2 Gadgil N, Edmond J, Stormes K, Lam S, Shah V. Visual complications of pediatric posterior fossa tumors: analysis of outcomes. *Pediatr Neurol* 2019;92:48–54
- 3 Kotecha M, Gotecha S, Chugh A, Punia P. Neuroophthalmic manifestations of intracranial tumours in children. *Case Rep Ophthalmol Med* 2021;2021:7793382

Video 1

Neurological examination with multidirection nystagmus with vertical component in the upward gaze. Online content including video sequences viewable at: <https://www.thieme-connect.com/products/ejournals/html/10.1055/s-0043-1772462>.

Medulloblastoma is the most common malignant brain tumor in childhood and occurs primarily in the cerebellum;

received

April 13, 2023

accepted after revision

July 3, 2023

article published online

September 4, 2023

© 2023, Thieme. All rights reserved.

Georg Thieme Verlag KG,

Rüdigerstraße 14,

70469 Stuttgart, Germany

DOI <https://doi.org/>

10.1055/s-0043-1772462.

ISSN 0174-304X.

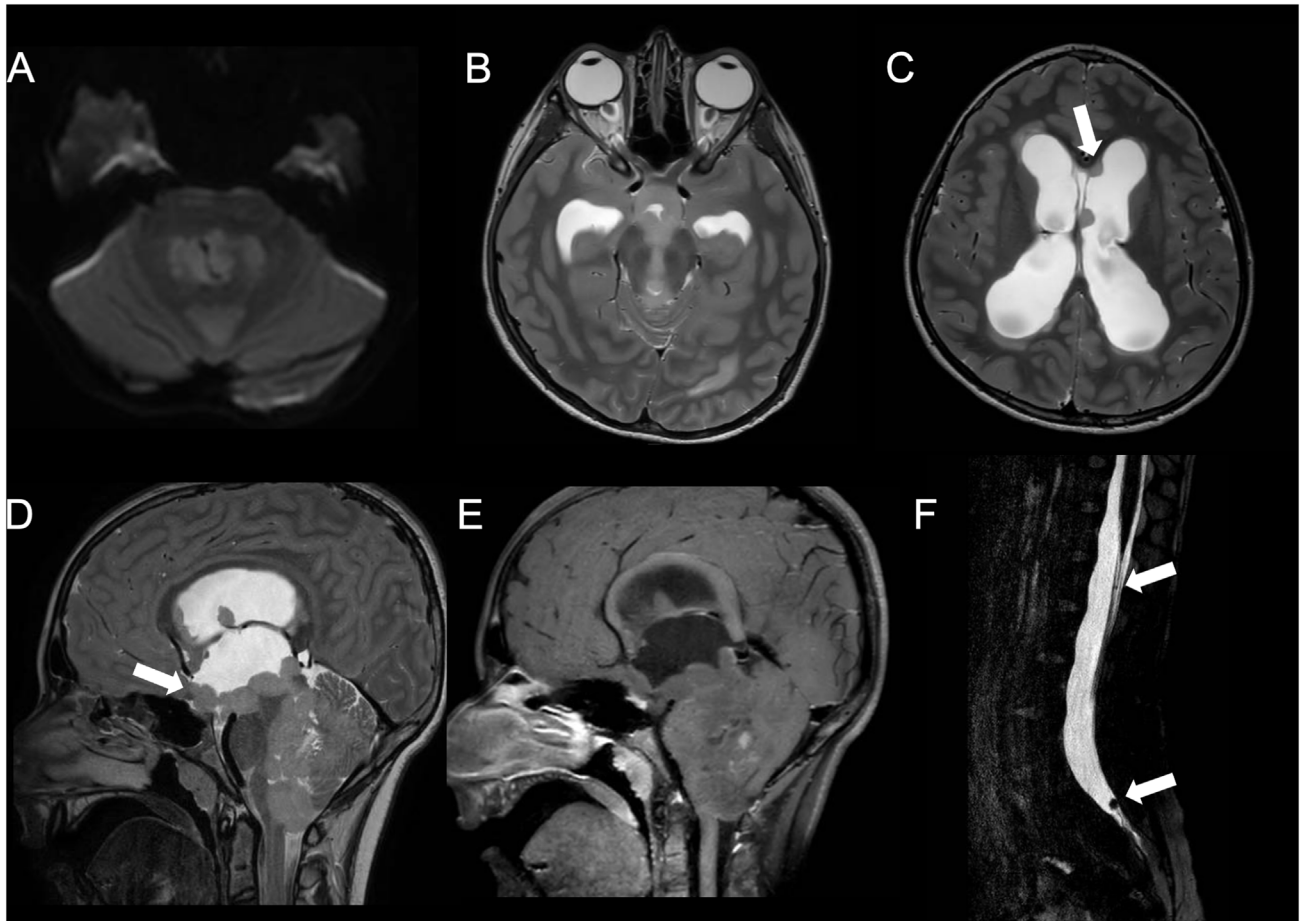


Fig. 1 Magnetic resonance (MR) images of an 11-year-old boy with medulloblastoma. Axial (A) diffusion-weighted imaging (DWI) and (B,C) T2-weighted images, (D) sagittal T2-weighted and (E) T1-postcontrast images, and (F) spinal sagittal T2-DRIVE images show a bulky mass lesion in the fourth ventricle and mesencephalic aqueduct with nodular dissemination in lateral ventricles and in the spinal cord (*arrows*). Lesions determined supratentorial hydrocephalus.