



# Primary Extraskelatal Falcine Myxoid Chondrosarcoma —A Case Report and Review of Literature

Rajasekhar Narayanan<sup>1</sup> Renjith T. Venugopal<sup>1</sup> Suresh Kumar K. L.<sup>1</sup> Jose P. B.<sup>1</sup> Anjana Bahuleyan<sup>2</sup>  
Reshmi C. P.<sup>3</sup> Thomas Varghese<sup>1</sup> Marthanda A. Pillai<sup>1</sup>

<sup>1</sup> Department of Neurosurgery, Ananthapuri Hospitals and Research Institute, Thiruvananthapuram, Kerala, India

<sup>2</sup> Department of Pathology, Ananthapuri Hospitals and Research Institute, Thiruvananthapuram, Kerala, India

<sup>3</sup> Department of Radiodiagnosis, Ananthapuri Hospitals and Research Institute, Thiruvananthapuram, Kerala, India

**Address for correspondence** Marthanda A. Pillai, MS, FRCS, Department of Neurosurgery, Ananthapuri Hospitals and Research Institute, Chacka, NH Bypass, Thiruvananthapuram, Kerala, 695024, India (e-mail: dramp2014@gmail.com).

AJNS

## Abstract

Intracranial chondrosarcomas are rare malignant lesions. Both skull base and dural-based extraosseous chondrosarcomas have been reported to occur intracranially. Dural-based chondrosarcomas arising from the falx cerebri are rare lesions with only 19 cases reported till date. Although conventional, mesenchymal, and myxoid variants of chondrosarcomas have been reported intracranially, myxoid variant are the rarest with only 17 cases reported till date, among which only 2 were falcine. We are reporting the third case of falcine myxoid chondrosarcoma in a 32-year-old man who presented with seizures and subtle lower limb weakness. Radiological findings were suggestive of an atypical meningioma in the falcine region. Macroscopically total resection of the tumor was done. Histopathological examination confirmed myxoid chondrosarcoma, grade 1. Postoperative period was uneventful, and the patient remains asymptomatic 34 months after the surgery without the application of any adjuvant therapy. Falcine myxoid chondrosarcomas are extremely rare lesions with variable aggressiveness as suggested by the three cases reported till now including the present case.

## Keywords

- ▶ chondrosarcoma
- ▶ dural based
- ▶ extraskelatal
- ▶ falcine
- ▶ intracranial
- ▶ myxoid

## Introduction

Chondrosarcoma, the second most common primary malignancy of bone, is well known to arise from extraskelatal sites also. Central nervous system involvement manifesting as skull base chondrosarcomas and extraosseous (nonskull-based or dural-based) chondrosarcomas has been described.<sup>1,2</sup> Extraosseous chondrosarcomas, although rare, have been reported to arise from multiple sites including brain parenchyma, falx and parasagittal region, posterior fossa, cerebellum, pineal region, and

ventricles.<sup>2</sup> Falcine chondrosarcomas are uncommon lesions, with only 19 cases reported in the literature till date.<sup>3</sup> Among intracranial chondrosarcomas, myxoid type is the least frequently reported. Only 17 cases of primary extraskelatal intracranial myxoid chondrosarcomas have been reported till date among which only 2 were falcine.<sup>4,5</sup> We describe another example of this tumor and illustrate the surgical details along with morphological features and review of literature. Our report adds observational data to the literature, and this uncommon entity should be borne in mind, even in the falcine location.

DOI <https://doi.org/10.1055/s-0043-1772764>.  
ISSN 2248-9614.

© 2024. Asian Congress of Neurological Surgeons. All rights reserved.

This is an open access article published by Thieme under the terms of the Creative Commons Attribution-NonDerivative-NonCommercial-License, permitting copying and reproduction so long as the original work is given appropriate credit. Contents may not be used for commercial purposes, or adapted, remixed, transformed or built upon. (<https://creativecommons.org/licenses/by-nc-nd/4.0/>)

Thieme Medical and Scientific Publishers Pvt. Ltd., A-12, 2nd Floor, Sector 2, Noida-201301 UP, India

## Case Report

### History and Examination

A 32-year-old male without any known comorbidities presented with history of a single episode of generalized tonic-clonic seizures. There was no history of similar episode in the past or any history of trauma, fever, headache, nausea, vomiting, and limb weakness.

On clinical examination, patient was conscious, oriented to time, place, and person; *Mini-mental state examination (MMSE)* score was 30/30; and had no other focal neurological deficits except for subtle ankle dorsiflexion and plantar flexion weakness on the left side manifested as difficulty in walking on toes and heels.

Plantar was equivocal on left side. On admission, patient was started on antiepileptic medications, and baseline investigations were done which turned out to be within normal limits.

Contrast-enhanced magnetic resonance imaging (MRI) of the brain was done which showed well-defined extra-axial lesion of size 5.5 × 4.8 cm attached to the right side of falx cerebri with compression of underlying brain parenchyma, features consistent with an atypical meningioma. No gliosis or parenchymal edema was noted. The lesion was closely abutting superior sagittal sinus without infiltration or thrombosis. The lesion was hypointense on T1-weighted imaging and brightly hyperintense on T2-weighted imaging with mild contrast enhancement (►Fig. 1A–E). There was mild inferior displacement of right lateral ventricle with midline shift of 8 mm toward left side. There was no diffusion restriction or susceptibility-weighted imaging blooming. Minimal transtentorial herniation was seen on right side without compression of midbrain. MR angiogram of the brain was normal.

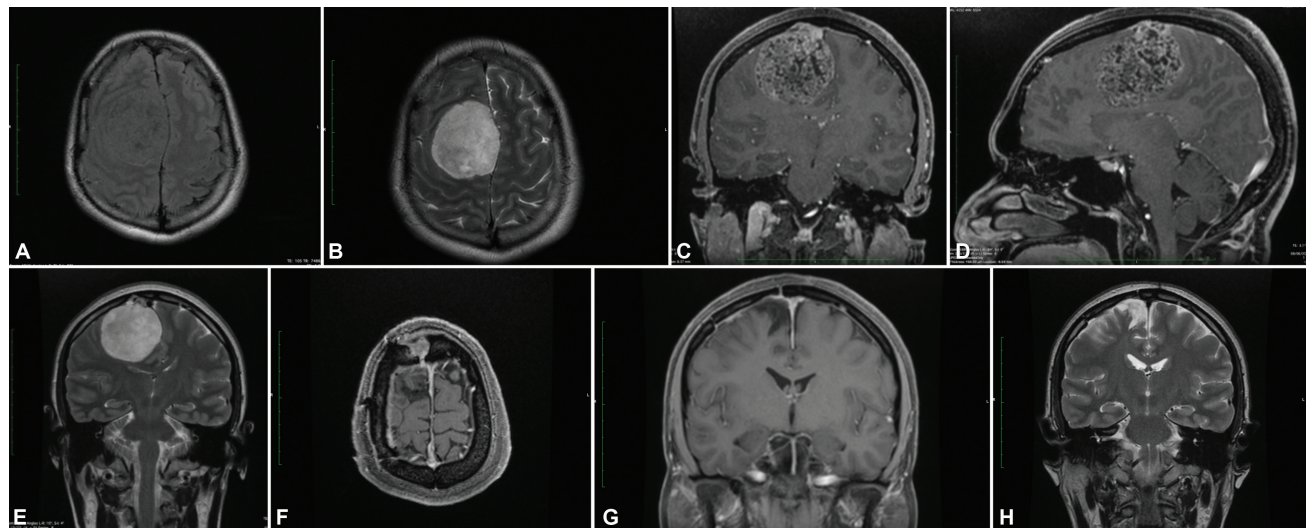
### Management

Right frontoparietal craniotomy and macroscopically total excision of the tumor were done. Intraoperatively, the tumor

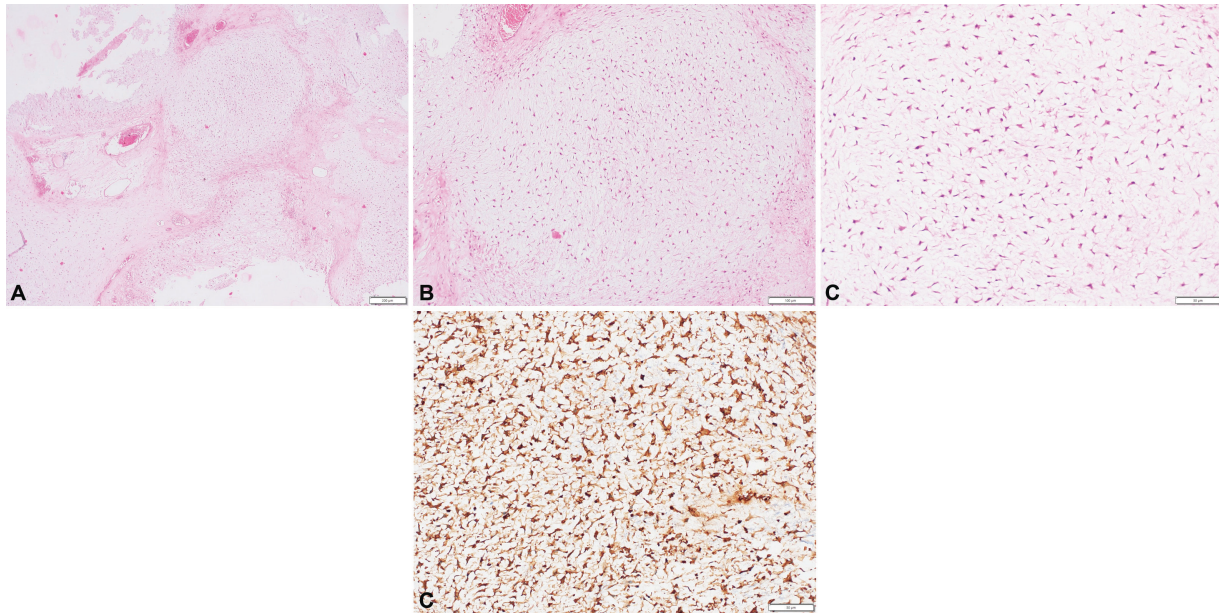
was firm, moderately vascular with calcification. The tumor was adhered to the falx. However, there was a good plane of cleavage with adjacent brain parenchyma. Histopathological examination showed myxoid chondrosarcoma, grade 1. Microscopy showed a tumor composed predominantly of lobules of fibrocartilaginous tissue with extensive myxoid changes (►Fig. 2A). Within these cartilaginous islands, uniform cells with eosinophilic to vacuolated cytoplasm were scattered (►Fig. 2B). These cells demonstrated low to intermediate grade nuclear atypia (►Fig. 2C). Few randomly distributed thin-walled blood vessels were seen. The mitotic activity was low, and no areas of necrosis were evident. The tumor cells were diffusely and strongly immunoreactive for S-100 (►Fig. 2D) and negative for cytokeratin.

### Postoperative Course and Follow-up

Postoperative period was uneventful, and the patient was discharged on postoperative day 9 without any neurological deficits. Follow-up MRI of the brain at 1 year showed no residual lesion (►Fig. 1F–H). In view of the histopathological diagnosis of myxoid chondrosarcoma, computed tomography (CT) of the chest and bone scan were done as part of metastatic work-up which were normal. Adjuvant treatment in the form of radiotherapy or chemotherapy was deferred due to two reasons. At first, this patient underwent macroscopically complete removal of the tumor, follow-up MRI of the brain showed no residual lesion, and the patient was clinically asymptomatic for any progressive disease. Second, the meagre number of reported cases of myxoid chondrosarcoma and the incongruity in the management of these cases makes a generalization regarding need for adjuvant treatment difficult. The patient remains asymptomatic after 34 months and is on regular follow-up. Further follow-up of the patient is planned with routine follow-up neurological examinations and a contrast-enhanced MRI after 1 year or earlier if symptomatic.



**Fig. 1** Pre-op T2-weighted FLAIR axial (A), pre-op T2-weighted axial (B), pre-op gadolinium-enhanced T1-weighted coronal (C), pre-op gadolinium-enhanced T1-weighted sagittal (D), pre-op T2-weighted coronal (E), 1-year post-op gadolinium-enhanced T1-weighted axial (F), 1-year post-op gadolinium-enhanced T1-weighted coronal (G), and 1-year post-op T2-weighted coronal (H) MRI. FLAIR, fluid-attenuated inversion recovery; MRI, magnetic resonance imaging; post-op, postoperative; pre-op, preoperative.



**Fig. 2** Photomicrograph of pathologic specimen—(A) Microscopy shows tumor composed of predominantly of lobules of fibrocartilaginous tissue with extensive myxoid changes (H&E stain,  $\times 100$ ). (B) Scattered uniform cells with eosinophilic to vacuolated cytoplasm within the cartilaginous islands (H&E stain,  $\times 400$ ). (C) Cells demonstrating low to intermediate grade nuclear atypia (H&E stain,  $\times 400$ ). (D) IHC staining: tumor cells found diffusely and strongly immunoreactive for S-100 ( $\times 400$ ). H&E, hematoxylin and eosin; IHC, immunohistochemistry.

## Discussion

Primary intracranial chondrosarcoma is an extremely rare malignant tumor of the central nervous system, which accounts for less than 0.15% of all primary intracranial tumors and 6% of skull base tumors.<sup>6</sup> Seventy-five percent of intracranial chondrosarcomas arise from the skull base, predominantly along the clivus, sellar and parasellar region, petrous temporal bone, petro-occipital, spheno-occipital, and sphenopetrosal synchondroses.<sup>1,7</sup> The rarer nonskull-based chondrosarcomas arise predominantly from the meningeal layers along the falcine and parasagittal region, cerebral and cerebellar parenchyma, ventricle, and choroid plexus.

On histology, chondrosarcomas are classified into the conventional, dedifferentiated, clear cell, and mesenchymal types. Conventional chondrosarcomas are further subclassified into hyaline, myxoid, and mixed types depending on the cytoarchitecture. Clear cell or dedifferentiated types have not been reported intracranially, making conventional or classic, mesenchymal, and myxoid types the primary types of chondrosarcoma seen intracranially. Reviewing the literature reveals that conventional chondrosarcomas are associated with the best prognosis, mesenchymal chondrosarcomas the worst, whereas myxoid type has an intermediate prognosis, among the chondrosarcomas.<sup>5,8</sup>

The World Health Organization histological grading system of chondrosarcomas, which consists of three categories: grade I (well differentiated), grade II (moderately differentiated), and grade III (poorly differentiated) is primarily helpful in determining the prognosis. Grades I and II chondrosarcomas have good prognosis, whereas grade III chondrosarcomas are associated with a high recurrence rate and metastasis.<sup>6</sup>

The proposed hypotheses regarding the origin of chondrosarcomas include (1) embryonal chondrocyte cell rests, (2) primitive pluripotent mesenchymal cells, and (3) metaplastic mature fibroblasts. The origin of skull base chondrosarcomas has been postulated to be from the embryonal cartilage cell nests within the endochondral ossification sites of the skull base. The origin of nonskull base or dural chondrosarcomas can be attributed to be the metaplastic fibroblasts and pluripotent mesenchymal cells located along the meninges and choroid plexus, and the leptomeningeal sheath of perforating vessels.

Conventional, mesenchymal, and myxoid types have been reported among both skull base and nonskull base chondrosarcomas. The most common histological type reported in the skull base is the conventional type,<sup>1</sup> whereas mesenchymal chondrosarcoma is the most common type (nearly 62%) reported in nonskull base locations.<sup>9</sup>

Skull base chondrosarcomas have a strong tendency for local recurrence due to the difficulty in complete resection. However, no recurrences have been reported to date in dural-based classical chondrosarcomas.<sup>10</sup> However, about 50% of the mesenchymal and nearly all the myxoid variants showed recurrence.<sup>1</sup>

In a review of literature done by Omezine et al<sup>3</sup> in 2018, only 19 cases of falcine chondrosarcoma have been reported among which 11 (57.9%) were low-grade chondrosarcoma, 6 cases (31.6%) were mesenchymal, and 2 (10.5%) were of the myxoid type. A review of literature by Qin et al<sup>11</sup> in 2017 reported 13 cases of primary extraskelletal myxoid chondrosarcomas. We identified four more nonskull-based myxoid chondrosarcomas in the literature and encountered the third case of falcine myxoid chondrosarcoma at our institute (► **Table 1**). Radiologically, conventional, mesenchymal, and myxoid chondrosarcomas have similar characteristics, making histopathological

**Table 1** Reported cases of primary intracranial extraskelatal myxoid chondrosarcoma

Case	Author/year/reference	Age (y)/sex	Location	Size	Surgery	Adjuvant therapy	Follow-up
1	Scott et al (1976) <sup>12</sup>	39/M	Fourth ventricle	NR	STR	NR	13 d, death (ventriculitis)
2	Smith and Davidson (1981) <sup>13</sup>	12/M	Left cerebellar hemisphere	3.5 × 1.0 × 0.5 cm	GTR	NR	13 mo, no recurrence, alive
3	Salcman et al (1992) <sup>5</sup>	28/F	Left parafalcine	7 × 5 × 4 cm	GTR (twice)	<sup>125</sup> I brachytherapy	12 mo, recurrence, alive
4	Sato et al (1993) <sup>14</sup>	43/F	Pineal region	NR	STR	RT, CT	36 mo, recurrence, death
5	Sala (1998) <sup>15</sup>	55/F	Posterior cranial fossa	NR	GTR (five times)	NR	7 y, recurrence, death
6	González-Lois et al (2002) <sup>16</sup>	17/F	Right frontotemporal cortical	2 × 3 × 2 cm	GTR	RT (local)	19 mo, recurrence, alive
7	Chaskis et al (2002) <sup>17</sup>	69/F	Right frontal lobe	NR	GTR	NR	1 mo, no recurrence, death (septic shock)
8	Im et al (2003) <sup>18</sup>	43/M	Left parietal cortex	2 cm	GTR	RT (photon beam)	3 y, no recurrence, alive
9	O'Brien et al (2008) <sup>19</sup>	26/F	CPA	2.5 cm	STR	RT (proton therapy)	12 mo, no recurrence, alive
10	Sorimachi et al (2008) <sup>7</sup>	37/F	Pineal region	NR	STR, GTR	NR	7 mo, no recurrence, alive
11	Dulou et al (2012) <sup>20</sup>	70/F	Left frontal lobe	NR	GTR	RT, CT	10 mo, recurrence, death
12	Norby et al (2012) <sup>21</sup>	12/F	Left parietal cortex	6.5 × 5.0 × 7.0 cm	GTR	NR	NR
13	Park et al (2012) <sup>22</sup>	21/F	Right thalamus	32 × 63 × 48 mm	GTR	RT	6 mo, no recurrence, alive
14	Qin et al (2017) <sup>11</sup>	41/F	Left cerebellum	3 × 3 × 3 cm	STR	RT, CT	19 mo, no recurrence, alive
15	Akakin et al (2018) <sup>4</sup>	35/F	Left falcine	NR	GTR (thrice)	GKRS	9 mo, recurrence, alive
16	Hong et al (2021) <sup>23</sup>	36/M	Fourth ventricle	1.6 cm	GTR	RT	3 mo, no recurrence, alive
17	Selvaraj et al (2021) <sup>24</sup>	27/M	Right lateral ventricle	3.5 × 3.7 × 3.6 cm	GTR	RT	29 mo, no recurrence, alive
18	Present case	32/M	Right falcine	5.5 × 4.8 cm	GTR	None	34 mo, no recurrence, alive

Abbreviations: CPA, cerebellopontine angle; CT, chemotherapy; F, female; GKRS, Gamma Knife radiosurgery; GTR, gross total resection; M, male; NR, not reported; RT, radiotherapy; STR, subtotal resection.

examination the key to diagnose the particular type of chondrosarcoma. On CT scans, falcine chondrosarcomas appear as iso- or hyperdense masses with variable enhancement patterns.<sup>10</sup> Lesser amount of calcification is seen in falcine chondrosarcomas compared with skull base lesions. These tumors are hypointense on T1-weighted MRI and hyperintense on T2-weighted MRI.<sup>10</sup> Cartilaginous component in the tumor tissue appears hypointense on T1-weighted MRI. A honeycomb pattern of variable contrast enhancement has been described, whereas dural tail sign is rarely present. On angiography, these lesions are relatively avascular. Peritumoral edema is minimal. Intracranial chondrosarcomas of the myxoid type are composed of chondroblast-like cells in an abundant myxoid matrix. On immunohistochemistry, they express vimentin (89%), epithelial membrane antigen (28%), and synaptophysin S-100 (17%) and no immunoreactivity for cytokeratin.<sup>11</sup>

Intracranial myxoid chondrosarcoma arising from the falx was first reported by Salzman et al<sup>5</sup> in 1992. The patient was a 28-year-old, 30 weeks pregnant woman who presented with hemiparesis, slowed speech, and severe headache. They operated the patient and the tumor recurred 10 months after the surgery. They reoperated the patient, and also implanted multiple radioactive I<sup>125</sup> seeds into the tumor cavity, and the patient became asymptomatic since then. The second case of falcine myxoid chondrosarcoma was reported by Akakin et al<sup>4</sup> in a 35-year-old woman who presented with hemiparesis of 1 week duration. The authors performed en bloc resection of the tumor. Two months postoperatively, the patient had recurrence which was reoperated. months after the first surgery, again there was recurrence which was managed with Gamma Knife radiosurgery (GKRS). One more recurrence was observed after 9 months of the initial surgery which was managed with surgery and GKRS. The authors observed that myxoid chondrosarcoma may be more aggressive in the falcine location but is difficult to generalize in view of the rarity of the tumor.

In the present case, our patient was a 32-year-old man presented with seizures and subtle lower limb weakness. Macroscopically total resection was done. The patient is asymptomatic even after 34 months of surgery. Various investigators have noted that pathological type, previous treatment (surgery or radiotherapy), extent of tumor resection, use of adjuvant postoperative radiotherapy as determinants of prognosis in chondrosarcomas in general.<sup>6</sup> Although meticulous surgical resection followed by postoperative radiotherapy has been reported to provide the best long-term outcomes in intracranial chondrosarcomas, the paucity of literature regarding myxoid chondrosarcomas make the role of adjuvant therapy questionable in nonskull-based myxoid chondrosarcomas.

## Conclusion

Primary intracranial myxoid chondrosarcomas are very rare malignant tumors. We are reporting the third case of falcine myxoid chondrosarcoma which appears to have an excellent prognosis when compared with the previous two reported

cases. Radiologically falcine chondrosarcomas mimic meningiomas; as also the characterization as classic, mesenchymal, or myxoid type depends on histopathology. Maximal safe surgical resection is the mainstay of treatment. The role of adjuvant therapy in nonskull-based chondrosarcoma needs further investigation. This case report is limited by the short follow-up period.

## Ethical Approval

This work has been approved by the Institutional Review Board of Ananthapuri Hospitals and Research Institute.

## Authors' Contribution

All authors contributed to the study conception and design. Material preparation and data collection were performed by R.N. The final draft of the manuscript was written by R.N. and M.P.A., and all authors commented on previous versions of the manuscript. All authors read and approved the final manuscript.

## Conflict of Interest

None declared.

## Acknowledgments

The authors thank Dr. Kirti Gupta, MD, professor, Department of Histopathology, Postgraduate Institute of Medical Education and Research, Chandigarh for her contribution to this study.

## References

- 1 Korten AG, ter Berg HJ, Spincemaille GH, van der Laan RT, Van de Wel AM. Intracranial chondrosarcoma: review of the literature and report of 15 cases. *J Neurol Neurosurg Psychiatry* 1998;65(01):88–92
- 2 Güneş M, Günaldi O, Tuğcu B, Tanriverdi O, Güler AK, Cöllüoğlu B. Intracranial chondrosarcoma: a case report and review of the literature. *Minim Invasive Neurosurg* 2009;52(5-6):238–241
- 3 Omezine S, Bouali S, Taallah M, Zehani A, Kallel J, Jemel H. Distinguishing falcine chondrosarcomas from their mimics and management. *World Neurosurg* 2018;118:279–283
- 4 Akakin A, Urgan K, Ekşi MŞ, et al. Falcine myxoid chondrosarcoma: a rare aggressive case. *Asian J Neurosurg* 2018;13(01):68–71
- 5 Salzman M, Scholtz H, Kristt D, Numaguchi Y. Extraskelatal myxoid chondrosarcoma of the falx. *Neurosurgery* 1992;31(02):344–348
- 6 Bloch OG, Jian BJ, Yang I, et al. Cranial chondrosarcoma and recurrence. *Skull Base* 2010;20(03):149–156
- 7 Sorimachi T, Sasaki O, Nakazato S, Koike T, Shibuya H. Myxoid chondrosarcoma in the pineal region. *J Neurosurg* 2008;109(05):904–907
- 8 Chen F, Chen B, Wang H, Xu W, Li W, Chen D. Intracranial nonskull-based chondrosarcoma arising from the sagittal sinus: a case report and review of the literature. *World Neurosurg* 2018;120:234–239
- 9 Krishnan SS, Panigrahi M, Varma D, Madigubba S. Falcine and parasagittal intracranial chondrosarcomas of the classical variant: report of two cases with review of literature. *Neurol India* 2011;59(03):451–454
- 10 Yang YW, Liu S, Wang X, Mao Q. A giant falcine chondrosarcoma: case report and literature review. *Neurol India* 2014;62(02):214–216

- 11 Qin Y, Zhang HB, Ke CS, et al. Primary extraskelatal myxoid chondrosarcoma in cerebellum: a case report with literature review. *Medicine (Baltimore)* 2017;96(47):e8684
- 12 Scott RM, Dickersin R, Wolpert SM, Twitchell T. Myxochondrosarcoma of the fourth ventricle. Case report. *J Neurosurg* 1976;44(03):386–389
- 13 Smith TW, Davidson RI. Primary meningeal myxochondrosarcoma presenting as a cerebellar mass: case report. *Neurosurgery* 1981;8(05):577–581
- 14 Sato K, Kubota T, Yoshida K, Murata H. Intracranial extraskelatal myxoid chondrosarcoma with special reference to lamellar inclusions in the rough endoplasmic reticulum. *Acta Neuropathol* 1993;86(05):525–528
- 15 Sala F, Talacchi A, Beltramello A, Iuzzolino P, Bricolo A. Intracranial myxoid chondrosarcoma with early intradural growth. *J Neurosurg Sci* 1998;42(03):159–163
- 16 González-Lois C, Cuevas C, Abdullah O, Ricoy JR. Intracranial extraskelatal myxoid chondrosarcoma: case report and review of the literature. *Acta Neurochir (Wien)* 2002;144(07):735–740
- 17 Chaskis C, Michotte A, Goossens A, Stadnik T, Koerts G, D'Haens J. Primary intracerebral myxoid chondrosarcoma. Case illustration. *J Neurosurg* 2002;97(01):228
- 18 Im SH, Kim DG, Park IA, Chi JG. Primary intracranial myxoid chondrosarcoma: report of a case and review of the literature. *J Korean Med Sci* 2003;18(02):301–307
- 19 O'Brien J, Thornton J, Cawley D, et al. Extraskelatal myxoid chondrosarcoma of the cerebellopontine angle presenting during pregnancy. *Br J Neurosurg* 2008;22(03):429–432
- 20 Dulou R, Chargari C, Dagain A, et al. Primary intracranial extraskelatal myxoid chondrosarcoma. *Neurol Neurochir Pol* 2012;46(01):76–81
- 21 Norby K, Qaiser R, McKinney A IV, Lam CH. A 12-year-old girl with an extraosseous chondrosarcoma. *J Neurol Res* 2012;2:176–179
- 22 Park JH, Kim MJ, Kim CJ, Kim JH. Intracranial extraskelatal myxoid chondrosarcoma: case report and literature review. *J Korean Neurosurg Soc* 2012;52(03):246–249
- 23 Hong YG, Yoo J, Kim SH, Chang JH. Intracranial extraskelatal myxoid chondrosarcoma in fourth ventricle. *Brain Tumor Res Treat* 2021;9(02):75–80
- 24 Selvaraj VK, Gudipudi DK, Khera R, Murthy S. Primary intracranial extra-skelatal myxoid chondrosarcoma of right lateral ventricle with EWSR1 gene fusion: a case report and review of literature. *Ecancelmedscience* 2021;15:1257