





Modulation of Small-Intestine Morphology in Mice by a Novel Supplement Containing *Silybum marianum*, Yeast β -Glucan, Prebiotics, and Minerals

Ricardo Aparecido Baptista Nucci^{1,2}  Victor Abou Nehmi-Filho^{3,4} Marta Ferreira Bastos⁵
Jéssica Alves de Freitas^{3,4} José Pinhata Otoch^{3,4} Ana Flávia Marçal Pessoa^{3,4,6}  Wilson Jacob-Filho^{1,2}

¹ Department of Pathology, University of São Paulo Medical School, São Paulo, SP, Brazil

² Laboratory of Medical Investigation in Aging (LIM-66), Division of Geriatrics, University of São Paulo Medical School, São Paulo, SP, Brazil

³ Research and Development of Efeom Nutrition S/A, São Paulo, SP, Brazil

⁴ Department of Surgery, Natural Products and Derivatives Laboratory (LIM-26), University of São Paulo Medical School, São Paulo, SP, Brazil

Address for correspondence Ricardo Aparecido Baptista Nucci, Department of Pathology, University of São Paulo Medical School, Av. Dr. Arnaldo, 455, 01246-903 São Paulo, Brazil (e-mail: nucci.ricardo.ab@gmail.com).

⁵ Postgraduate Program in Aging Sciences, São Judas Tadeu University, São Paulo, Brazil

⁶ Brazilian Academic Consortium for Integrative Health (CABSIN), Natural Products Committee, São Paulo, SP, Brazil

J Health Allied Sci^{NU}

Abstract

Silymarin, derived from *Silybum marianum*, has recently demonstrated its potential to improve health in conditions such as obesity and metabolic disturbances. Understanding the impact of nutraceuticals on intestinal morphology is crucial for developing supplements that promote a higher quality of life. Therefore, this study aimed to investigate the effects of nutraceutical supplementation with silymarin on the morphology of the small intestine. Sixty-day-old adult male C57BL/6 mice were divided into two groups: one receiving a standard chow (control) and the other receiving a novel silymarin supplement (experimental). Following the experimental period, the animals were euthanized, and fragments of the small intestine were collected for histochemical analysis using Masson's trichrome and periodic acid-Schiff with Alcian blue staining techniques. Our results revealed an increase in the number of villi per analyzed field in the experimental group, accompanied by a decrease in basic mucin, crypt depth, mucosal thickness, and villus spacing. In conclusion, this novel nutraceutical supplementation may play a crucial role in modulating small intestine morphology and enhancing absorption capacity.

Keywords

- ▶ intestine
- ▶ mice
- ▶ morphology
- ▶ Silymarin
- ▶ supplementation

Introduction

The investigation of natural compounds for nonpharmacological interventions aimed at promoting health has gained momentum in the pursuit of an extended lifespan coupled with an

improved quality of life.¹ Notably, numerous studies have demonstrated the potential of nutraceuticals as effective therapeutic approaches for the prevention and management of various inflammatory and metabolic disorders, including but not limited to obesity, steatosis, and type-2 diabetes mellitus.²⁻⁴

DOI <https://doi.org/10.1055/s-0043-1773807>.
ISSN 2582-4287.

© 2023. The Author(s).

This is an open access article published by Thieme under the terms of the Creative Commons Attribution License, permitting unrestricted use, distribution, and reproduction so long as the original work is properly cited. (<https://creativecommons.org/licenses/by/4.0/>)

Thieme Medical and Scientific Publishers Pvt. Ltd., A-12, 2nd Floor, Sector 2, Noida-201301 UP, India

Silymarin (*Silybum marianum*) exerts hepatoprotective effects through various mechanisms, including antioxidant activity and stabilization of the hepatocellular membrane.⁵ Furthermore, silymarin has demonstrated the ability to decrease plasma cholesterol and low-density lipoprotein levels in hyperlipidemic animals.⁶ Moreover, experimental studies have reported that specific flavonoids present in silymarin, such as silibinin, exhibit inhibitory effects on renal toxicity induced by cisplatin.⁷

Silymarin and its flavonoid constituents, particularly silibinin, have demonstrated emerging potential in the inhibition of tumor growth.⁸ A recent study revealed a significant dose-dependent reduction in viability and migration of gastric cancer cells following silymarin administration.⁹ Furthermore, silibinin has exhibited strong inhibitory effects on various epithelium-derived cancers, including prostate, colorectal, bladder, and lung cancer.^{10,11}

Understanding the effects of phytochemicals on intestinal morphology is of paramount importance to elaborate supplements for a better quality of life in a variety of health conditions.¹² Thus, this study aimed to analyze the effects of a nutraceutical supplementation with silymarin on small intestine morphology.

Materials and Methods

Study Design

All experimental procedures were conducted in strict accordance with the National Institutes of Health guidelines, and the research protocol received approval from the Ethics Committee of the University of São Paulo Medical School (FMUSP) under protocol number 1810/2022. Sixty-day-old adult male C57BL/6 mice were procured from the Central Vivarium of Mice at FMUSP. The mice were housed in a temperature-controlled room maintained at $(24 \pm 2)^\circ\text{C}$, following a 12-hour light/12-hour dark cycle. The mice were divided into two groups ($n = 5$ per group): control and experimental. Both groups received a standard nonfat diet containing 3.54 kcal/g for a duration of 10 weeks. Following this initial period, the control group continued to receive the standard nonfat diet, while the experimental group received the supplementation for an additional 4 weeks (28 consecutive days). This treatment duration was chosen to assess the long-term effects of supplementation, as previously reported.² At the end of the experimental period, the animals were euthanized with an overdose of ketamine and xylazine, and fragments of the small intestine were collected for further analysis.

Supplement Composition

The supplement formulation (Patent number: BR 10 2020 016156 3) utilized in this study consisted of zinc (Zn), selenium (Se), magnesium (Mg), fructooligosaccharides (FOS), galactooligosaccharides (GOS), 1,3/1,6- β -glycosidic bonds yeast β -glucans (*Saccharomyces cerevisiae*), and *Silybum marianum* extract. The mineral percentages were calculated based on dietary reference values,²⁻⁴ and the final product was diluted in mineral water with carboxymethyl cellulose as the emulsifier.

Histochemical Techniques

Small intestine fragments were fixed in 4% formaldehyde for 24 hours and subsequently embedded in paraffin for histochemical staining techniques. Tissue sections were subjected to Masson's trichrome staining to evaluate morphological structures and collagen deposition.¹³ In addition, slides were stained using periodic acid-Schiff with Alcian blue to visualize intestinal glycoproteins (mucins), as previously described.¹⁴ For image capture, approximately five images per animal were obtained using a desktop microscope (Leica Microsystems DMC 2900, SP, Brazil) equipped with AxioVision software (Carl Zeiss, White Plains, New York, United States).

Quantitative Analysis

Morphological parameters were assessed using ImageJ software (National Institutes of Health, United States) to analyze both structure density (%) and numerical quantity. The color deconvolution tool in ImageJ was employed to unmix the brightfield images into channels representing the absorbance of individual dyes.^{15,16} After channel splitting, the images were converted to grayscale to measure the area fraction of stained structures in contrast to the white background. This quantitative analysis allowed for the evaluation of the following parameters: acid mucin (Alcian blue), basic mucin (periodic acid-Schiff), and collagen deposition (Masson's trichrome staining). Moreover, the numerical quantity of villi per field was determined using the cell counter tool in ImageJ on sections stained with Masson's trichrome. Morphometric analysis (**►Fig. 1**) was performed on approximately five fields per animal, using AxioVision software (Carl Zeiss, United States), to measure the following parameters (approximately 5 structures per field for each parameter) on Masson's trichrome staining (μm): crypt depth, mucosal thickness, villus length, and villus spacing.¹⁷

Statistical Analysis

We conducted unpaired Student's *t*-test to examine the difference between the groups and data were expressed as mean \pm standard error. The statistical analyses were performed using GraphPad Prism 5.0 software (GraphPad Prism, Inc., San Diego, California, United States). The alpha level was set at the 0.05 level, and all tests were two-tailed.

Results

In **►Fig. 2**, we can see the quantitative analysis, as well as the representative images for each group. Regarding morphometric analysis, animals submitted to the supplementation had a significant decrease of crypt depth (71.61 ± 2.09 vs. $64.08 \pm 1.03\mu\text{m}$), mucosal thickness (446.5 ± 11.6 vs. $321.2 \pm 7.314\mu\text{m}$), villus length (330.7 ± 11.56 vs. $210.2 \pm 6.78\mu\text{m}$), and villus spacing (109.3 ± 4.78 vs. $22.2 \pm 0.73\mu\text{m}$). In contrast, we observed a significant increase of villus per field (10.5 ± 1.25 vs. 20.1 ± 1.19 villus/field). However, color deconvolution did not show significant difference in collagen deposit or acid mucins between the groups. On the other hand, basic mucin was decreased in the experimental group (2.84 ± 0.23 vs. $1.87 \pm 0.17\%$).

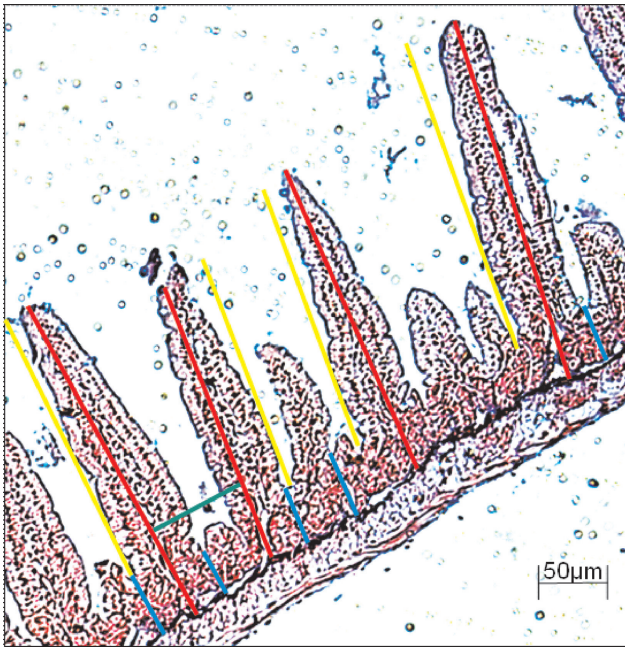


Fig. 1 Schematic representation of measurements of intestinal morphology parameters. The vertical red lines correspond to mucosal thickness, yellow lines indicate villus length, blue lines indicate crypt depth and horizontal green lines demonstrate how villus spacing was determined.

Discussion

Our study aimed to investigate the effects of a novel nutraceutical supplementation on the components of the small intestine in mice. We observed an increase in the number of villi per field, suggesting an enlargement of the absorption area. This result was accompanied by a reduction in villus spacing, length, crypt depth, and mucosal thickness.

Previous research has shown that only a fraction of orally administered silymarin is absorbed from the gastrointestinal tract, as it undergoes extensive enterohepatic circulation.¹⁸ However, an experimental study in mice demonstrated that flavonoids from silymarin, in both free and conjugated forms, exhibited good distribution in various examined tissues.¹⁹ The observed phenomenon in our study can be partially explained by the formulation of the supplement. Silymarin has low permeability across intestinal epithelial cells, low aqueous solubility, and is rapidly excreted in bile and urine, resulting in low bioavailability. Experimental studies often combine its supplementation with compounds such as phospholipids,²⁰ liposomes,²¹ and β -cyclodextrins²² to enhance its bioavailability.

Dietary minerals can be absorbed through the epithelial cells lining the gastrointestinal tract, enabling transcellular mineral transport even at low concentrations in the intestinal lumen.²³ Therefore, mineral conjugates are utilized to enhance gastrointestinal absorption. Prebiotics, which promote the growth of beneficial bacteria in the gastrointestinal tract, have been shown to enhance the absorption capacity when combined with minerals.²⁴ Furthermore, the addition

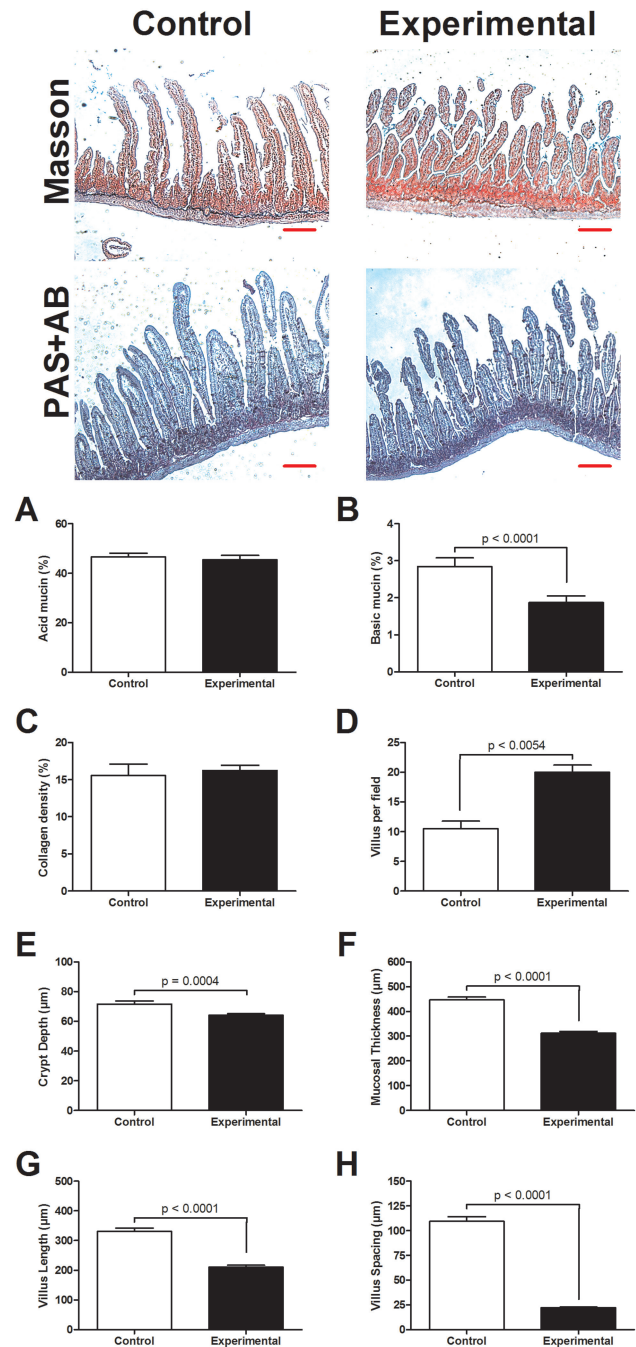


Fig. 2 Quantitative analysis between the groups. (A) Acid mucins (%); (B) basic mucins (%); (C) collagen density (%); (D) quantity of villus per field; (E) crypt depth (μm); (F) mucosal thickness (μm); (G) villus length (μm); (H) villus spacing (μm). Representative images are shown above for both Masson's trichrome and periodic acid-Schiff with Alcian blue (PAS + AB). Scale bar = $50\mu\text{m}$.

of β -glucan, a dietary fiber found in various sources including yeast, has demonstrated antioxidant activity and glucose control due to its bioavailability.²⁵

However, it is important to consider the limitations of our study. We solely employed histochemical techniques to elucidate our findings, and the bioavailability of silymarin was not directly measured in the experimental

group. Despite the limitation posed by a modest sample size, our group's prior investigations have demonstrated compelling outcomes of this nutraceutical in preclinical models of obesity and type 2 diabetes, utilizing an identical sample size.²⁻⁴ These earlier studies yielded statistically significant results, thus providing a strong foundation for the current study's rationale and potential implications. However, it is crucial to acknowledge the necessity for larger sample sizes in future research to further validate and consolidate these findings, ensuring greater generalizability and robustness of the conclusions drawn. Notwithstanding these limitations, our study boasts several noteworthy strengths. We introduced a novel nutraceutical supplementation that potentially modulates small intestine morphology, thereby increasing absorption capacity. Future investigations utilizing immunohistochemical and molecular techniques may further elucidate the underlying pathways involved in villus genesis and the effects of each individual compound within this nutraceutical on the gastrointestinal system.

In conclusion, the combination of silymarin, prebiotics, yeast β -glucan, and minerals in a dietary supplementation regimen may play a crucial role in shaping small intestine morphology and enhancing absorption capacity. Thus, silymarin's role in shaping small intestine morphology and its combination with other compounds for improved bioavailability are noteworthy, offering implications for the nutraceutical industry.

Authors' Contributions

R.A.B.N. was involved in formal analysis, investigation, and writing—original draft. V.A.N.-F. helped in investigation, resources, and writing—review and editing. M.F.B. and J.A.de F. contributed to methodology, validation, writing—review and editing. J.P.O. helped in data curation, visualization, writing—review and editing. A.F.M.P. was involved in conceptualization, resources, writing—review and editing. W.J.-F. helped in conceptualization, resources, supervision, writing—original draft.

Data Availability Statement

The authors confirm that the data supporting the findings of this study are available within the article.

Ethical Publication Statement

The authors confirm that they have read the journal's position and issues involved in the ethical publication and affirm that this report is consistent with those guidelines.

Conflicts of Interest

None declared.

Acknowledgments

This work was supported by Efeom Nutrition S.A. The funder was not involved in the study design, collection, analysis, interpretation of data, the writing of this article, or the decision to submit it for publication. All authors declare no other competing interests.

References

- Nucci RAB, Filho VAN, Jacob-Filho W, Otoch JP, Pessoa AFM. Role of nutritional supplements on gut-muscle axis across age: a mini-review. *Cell Physiol Biochem* 2023;57(03):161–168
- Nehmi VA, Murata GM, Moraes RCM, et al. A novel supplement with yeast β -glucan, prebiotic, minerals and *Silybum marianum* synergistically modulates metabolic and inflammatory pathways and improves steatosis in obese mice. *J Integr Med* 2021;19(05):439–450
- Santamarina AB, Moraes RCM, Nehmi Filho V, et al. The symbiotic effect of a new nutraceutical with yeast β -glucan, prebiotics, minerals, and *Silybum marianum* (Silymarin) for recovering metabolic homeostasis via *Pgc-1 α* , *Il-6*, and *Il-10* gene expression in a type-2 diabetes obesity model. *Antioxidants* 2022;11(03):447
- Nehmi-Filho V, Santamarina AB, de Freitas JA, et al. Novel nutraceutical supplements with yeast β -glucan, prebiotics, minerals, and *Silybum marianum* (silymarin) ameliorate obesity-related metabolic and clinical parameters: a double-blind randomized trial. *Front Endocrinol (Lausanne)* 2023;13:1089938
- Vargas-Mendoza N, Madrigal-Santillán E, Morales-González A, et al. Hepatoprotective effect of silymarin. *World J Hepatol* 2014;6(03):144–149
- Sobolová L, Skottová N, Večeřa R, Urbánek K. Effect of silymarin and its polyphenolic fraction on cholesterol absorption in rats. *Pharmacol Res* 2006;53(02):104–112
- Ninsontia C, Pongjit K, Chaotham C, Chanvorachote P. Silymarin selectively protects human renal cells from cisplatin-induced cell death. *Pharm Biol* 2011;49(10):1082–1090
- Zhang Y, Li Q, Ge Y, et al. Silibinin triggers apoptosis and cell-cycle arrest of SGC7901 cells. *Phytother Res* 2013;27(03):397–403
- Kim SH, Choo GS, Yoo ES, et al. Silymarin induces inhibition of growth and apoptosis through modulation of the MAPK signaling pathway in AGS human gastric cancer cells. *Oncol Rep* 2019;42(05):1904–1914
- Singh RP, Sharma G, Dhanalakshmi S, Agarwal C, Agarwal R. Suppression of advanced human prostate tumor growth in athymic mice by silibinin feeding is associated with reduced cell proliferation, increased apoptosis, and inhibition of angiogenesis. *Cancer Epidemiol Biomarkers Prev* 2003;12(09):933–939
- Li R, Yu J, Wang C. Silibinin promotes the apoptosis of gastric cancer BGC823 cells through caspase pathway. *J Balkan Union Oncol* 2017;22(05):1148–1153
- Fallah M, Davoodvandi A, Nikmanzar S, et al. Silymarin (milk thistle extract) as a therapeutic agent in gastrointestinal cancer. *Biomed Pharmacother* 2021;142:112024
- Goldner J. A modification of the Masson trichrome technique for routine laboratory purposes. *Am J Pathol* 1938;14(02):237–243
- Yamabayashi S. Periodic acid-Schiff-Alcian blue: a method for the differential staining of glycoproteins. *Histochem J* 1987;19(10-11):565–571
- Landini G, Martinelli G, Piccinini F. Colour deconvolution: stain unmixing in histological imaging. *Bioinformatics* 2021;37(10):1485–1487
- Nucci RAB, Jacob-Filho W, de Souza RR, Maifirino LBM. Color deconvolution as a simple and rapid tool in quantitative biomedical research. *J health Allied Sci NU* 2023. Doi: 10.1055/s-0043-1768067
- Todorov H, Kollar B, Bayer F, et al. α -Linolenic acid-rich diet influences microbiota composition and villus morphology of the mouse small intestine. *Nutrients* 2020;12(03):732
- Wu JW, Lin LC, Tsai TH. Drug-drug interactions of silymarin on the perspective of pharmacokinetics. *J Ethnopharmacol* 2009;121(02):185–193
- Zhao J, Agarwal R. Tissue distribution of silibinin, the major active constituent of silymarin, in mice and its association with enhancement of phase II enzymes: implications in cancer chemoprevention. *Carcinogenesis* 1999;20(11):2101–2108

- 20 Yanyu X, Yunmei S, Zhipeng C, Qineng P. The preparation of silybin-phospholipid complex and the study on its pharmacokinetics in rats. *Int J Pharm* 2006;307(01):77–82
- 21 Maheshwari H, Agarwal R, Patil C, Katare OP. Preparation and pharmacological evaluation of silibinin liposomes. *Arzneimittelforschung* 2003;53(06):420–427
- 22 Arcari M, Brambilla A, Brandt A, et al. [A new inclusion complex of silibinin and beta-cyclodextrins: in vitro dissolution kinetics and in vivo absorption in comparison with traditional formulations]. *Boll Chim Farm* 1992;131(05):205–209
- 23 Goff JP. Invited review: mineral absorption mechanisms, mineral interactions that affect acid-base and antioxidant status, and diet considerations to improve mineral status. *J Dairy Sci* 2018;101(04):2763–2813
- 24 Karakan T, Tuohy KM, Janssen-van Solingen G. Low-dose lactulose as a prebiotic for improved gut health and enhanced mineral absorption. *Front Nutr* 2021;8:672925
- 25 Bacha U, Nasir M, Iqbal S, Anjum AA. Nutraceutical, anti-inflammatory, and immune modulatory effects of β -glucan isolated from yeast. *BioMed Res Int* 2017;2017:8972678