Article published online: 2023-09-27

Original Article

Evaluation and Clinicopathological Correlation of ALDH1 in Colorectal Adenoma with Low-/High-Grade Dysplasia and Carcinoma.

Himanshi Bhanu[1] Ruchi Mittal[1,2] Urmila Senapati[1]

[1] Department of Pathology, Kalinga Institute of Medical Sciences, Patia, Bhubaneswar, Odisha, India
[2] Department of Histopathology, Bagchi-Sri Shankara Cancer Centre and Research Institute, Bhubaneswar, Odisha, India

Address for correspondence Ruchi Mittal, MD, DNB, PDF, Professor, Head of the Department of Histopathology, Bagchi-Sri Shankara Cancer Centre and Research Institute, Bhubaneswar 752054, Odisha, India (e-mail: dr.rmittal@gmail.com).

South Asian J Cancer

Abstract

Ruchi Mittal

Colorectal carcinoma (CRC) stands as one of the most prevalent malignant neoplasms, carrying significant morbidity and mortality implications. Within colorectal carcinogenesis, cancer stem cells are recognized as key contributors, infusing tumors with aggressive traits, including chemoresistance. A group of enzymes known as ALDH1 exhibits stem cell properties, potentially playing a role in colorectal neoplasms. This study aims to evaluate ALDH1 expression in colonic neoplasms and its correlation with clinicopathological parameters. The research encompasses 50 consecutive cases, involving CRC (30) and colorectal adenoma (20), gathered prospectively from September 2019 to August 2021, as well as archived cases from January 2018 to August 2019. Histological examination was conducted on CRC cases to assess tumor type, grade, lymphovascular invasion, perineural invasion, mitosis, and necrosis, while colorectal adenomas were subjected to histological grading. ALDH1 immunohistochemistry was performed on both CRC and adenoma specimens. Statistical analysis utilized SPSS 20 software, employing the chi-squared test and Fischer's exact test. A higher count of adenoma cases displayed positive staining ($p = 0.0005$) and greater expression ($p = 0.036$) in comparison to carcinoma cases. The other clinicopathological parameters didn't demonstrate notable associations. Adenomas with low-grade dysplasia exhibited a higher frequency of positive ALDH1 staining and expression than those with high-grade dysplasia. In malignant cases, a higher proportion of positive staining was observed in lower-stage disease compared to higher-stage disease. The heightened staining and expression outcomes of ALDH1 in adenomas versus carcinomas, as well as their presence in lower-stage carcinomas, suggest the potential acquisition of novel mutations and the proliferation of distinct clonal stem cell subsets during disease progression. The absence of ALDH1 in adenoma/carcinoma could indicate a poorer prognosis and an increased likelihood of disease progression to a higher stage. Comprehensive multi-institutional and validation studies are needed to enhance our understanding of ALDH1's role in colorectal oncogenesis, as well as its viability as a targeted or personalized therapy option.

Keywords

- cancer stem cell
- ALDH1
- colorectal cancer
- adenoma
- clinicopathological
- stage
- dysplasia

DOI https://doi.org/10.1055/s-0043-1774402 ISSN 2278-330X

How to cite this article: Bhanu H, Mittal R, Senapati U. Evaluation and Clinicopathological Correlation of ALDH1 in Colorectal Adenoma with Low-/High-Grade Dysplasia and Carcinoma. South Asian J Cancer 2023;00(00):00–00

Thieme Medical and Scientific Publishers Pvt. Ltd., A-12, 2nd Floor, Sector 2, Noida-201301 UP, India

Introduction

Cancer is a major public health problem worldwide that poses much more significant impact on low- and middle-income countries because of the paucity of screening services, health care access, resources, and advanced stage at presentation.[1,2] Colorectal carcinoma (CRC) ranks third in terms of incidence and second in terms of mortality, globally.[2] In India, there is a consistent rise in the incidence of CRC ranging from 20 to 124% per year.[3] The incidence of CRC is currently 15.2 per 100,000 population in India, making it the seventh most common cancer as of year 2021.[4]

Cancer stem cell hypothesis has been postulated to play a significant role in the development of CRC and has gathered significant attention. Better understanding of this hypothesis may prepare the oncologists to deliver personalized therapy to CRC patients,[5] which has prompted an extensive cancer stem cell research. The tumor cells themselves are heterogenous in morphology, metabolism, and proliferation rate. Stem cells are a very small population of cells among these tumor cells with the properties of self-renewal, therapeutic resistance, and most importantly cancer recurrence, which is achieved by their pluripotent nature and thus they form the most important target for targeted and personalized therapy.[6,7] Several stem cell markers have been studied in CRCs including CD44, CD133, EpCAM, and ALDH1.[5,8] Aldehyde dehydrogenases are a group of critically important class of nicotinamide adenine dinucleotide phosphate–positive (NADP+) dependent enzymes that help by catalyzing the conversion of various endogenous and exogenous aldehydes to their corresponding carboxylic acid through oxidation, thus protecting them against oxidative stress and acting as a detoxifying enzyme. They also help in biosynthesis of molecules like retinoic acid, γ-aminobutyric acid, and betaine, which help in maintaining homeostasis of the cells[9–13] and are primarily located within the cytoplasm of the cells.[13] ALDH1 has been studied as a stem cell marker in various organs like the lung,[14,15] breast,[16,17] and ovary.[18,19] Various studies on the expression of ALDH1 in CRC have shown variable results.[9,20–30] Colorectal adenoma has been established as a precursor to CRC[31] and according to the most popular theory of colorectal pathogenesis, that is the adenoma-carcinoma sequence, CRCs are thought to develop from preformed adenomatous polyps.[32] A literature search revealed only two studies that have explained an increased expression of ALDH1 and its isoform like ALDH1A1 when the pathology progresses from adenoma to carcinoma.[31,32]

With this background, we intend to study the staining and expression of ALDH1 in CRCs as well as in adenomas in an Indian cohort of patients and to understand its role as a potential therapeutic target. To the best of our knowledge, this is the first such study in the Indian population.

Materials and Methods

The present study was an ambispective study, conducted in the Department of Pathology of a tertiary health care center for patients who attended the Surgical Oncology clinics during the period from September 2019 to August 2021. Archived blocks for CRC cases were also retrieved from the Department of Surgical Pathology from the year January 2018 to August 2019. Our study comprised 30 cases of CRC and 20 cases of adenoma. Demographic data included age and gender of the patients. The site of the tumors was also recorded. Histopathology evaluation included tumor type, grade, lymphovascular invasion (LVI), perineural invasion (PNI), T stage, lymph node status, and pathological stage. The type of dysplasia was also noted for adenoma cases along with correlation of age in adenoma with low-/high-grade dysplasia.

Immunohistochemical evaluation: The evaluation of ALDH1was done by the secondary labeling technique on formalin-fixed paraffin-embedded tissue sections (4–5 µm thick) mounted on poly-L-lysine-coated slides. The monoclonal antibody used was ALDH1 (clone: EP168). Kidney sections were used as positive control. For negative control, the addition of primary antibody was skipped.

ALDH1 evaluation of staining: The assessment of staining of ALDH1 was done by two senior pathologists independently along with a resident. In the cases where the observations differed, consensus was reached by observing the cases together. The staining for ALDH1 in adenomas, carcinomas, and in adjacent uninvolved epithelium was evaluated. The cytoplasmic expression of ALDH1 was recorded. The intensity and percentage of staining was performed as explained previously.[8] For evaluation of staining, we divided our cases into two groups by adding the intensity and percentage score; a cumulative score of 0 to 2 was recorded as negative staining and a score of 3 to 7 was recorded as positive staining. Multiplication of intensity and percentage score helped in obtaining low (<100) and high (>100) expression data.

Statistical analysis: Analysis was performed with SPSS 20 software. To check the association between two categorical variables, chi-squared test and Fisher's exact test were used. For all statistical tests, a *p*-value less than 0.05 was considered significant.

Observations and Results

Clinicopathological Parameters in Carcinoma Cases

Our study population comprised 50 consecutive colorectal neoplasms, which included 30 cases of CRC and 20 cases of colorectal adenoma. As tabulated in ►Table 1, out of 30 cases of CRC, 17 were males and 13 were females. The male-to-female ratio was 1.3:1. The age of our patients with CRC ranged between 29 and 85 years; the average age was 62.7 ± 12.5 years. The size of the tumor ranged from 2.5 to 10 cm, with an average size of 5 cm. The left colon was more commonly involved. The majority of the cases belonged to stage III disease (60%).

ALDH1 Staining and Expression in Carcinomas and Correlation with the Clinicopathological Parameters

Out of the total CRCs cases, 26.7% showed positive staining (►Fig. 1a, b) and 20% showed high expression with ALDH1.

Table 1 ALDH1 staining and expression: correlation with clinicopathological parameters

Variables	Staining		*p*-value	Expression		*p*-value
	Negative, *N* (%)	Positive, *N* (%)		<100 (low), *N* (%)	>100 (high), *N* (%)	
Age (y)						
≤60 (*N* = 13)	9 (69.2)	4 (30.8)	0.340	9 (69.3)	4 (30.7)	0.121
>60 (*N* = 17)	13 (76.5)	4 (23.5)		15 (88.2)	2 (11.8)	
Gender						
M (*N* = 17)	14 (82.4)	3 (17.6)	0.119	15 (88.3)	2 (11.7)	0.121
F (*N* = 13)	8 (61.5)	5 (38.5)		9 (69.2)	4 (30.8)	
Tumor size						
≤5cm (*N* = 19)	14 (73.7)	5 (26.3)	0.954	15 (78.9)	4 (21.1)	0.850
>5cm (*N* = 11)	8 (72.7)	3 (27.3)		9 (81.8)	2 (18.2)	
Tumor site						
Left colon (*N* = 16)	12 (75)	4 (25)	0.236	14 (87.5)	2 (12.5)	0.096
Right colon (*N* = 11)	9 (81.8)	2 (18.2)		9 (81.8)	2 (18.2)	
Rectum (*N* = 3)	1 (33.3)	2 (66.7)		1 (33.3)	2 (66.7)	
Histological grade						
I (*N* = 21)	16 (76.2)	5 (23.8)	0.241	18 (85.7)	3 (14.3)	0.103
II (*N* = 8)	6 (75)	2 (25)		6 (75)	2 (25)	
III (*N* = 1)	0 (0)	1 (100)		0 (0)	1 (100)	
AJCC stage						
I (*N* = 4)	2 (50)	2 (50)	0.520	3 (75)	1 (25)	0.819
II (*N* = 8)	6 (75)	2 (25)		7 (87.5)	1 (12.5)	
III (*N* = 18)	14 (77.8)	4 (22.2)		14 (77.8)	4 (22.2)	
LVI						
Present (*N* = 16)	11 (68.7)	5 (31.3)	0.544	12 (75)	4 (25)	0.464
Absent (*N* = 14)	11 (78.6)	3 (21.4)		12 (85.7)	2 (14.3)	
PNI						
Present (*N* = 9)	7 (77.8)	2 (22.2)	0.719	7 (77.8)	2 (22.2)	0.842
Absent (*N* = 21)	15 (71.4)	6 (28.6)		17 (80.9)	4 (19.1)	
LN metastasis						
Present (*N* = 18)	14 (77.8)	4 (22.2)	0.500	14 (77.8)	4 (22.2)	0.709
Absent (*N* = 12)	8 (66.7)	4 (33.3)		10 (83.3)	2 (16.7)	
Mitosis (/10 hpf)						
≤30 (*N* = 16)	12 (75)	4 (25)	0.825	13 (81.2)	3 (18.8)	0.855
>30 (*N* = 14)	10 (71.4)	4 (28.6)		11 (78.6)	3 (21.4)	
Necrosis						
Present (*N* = 20)	14 (70)	6 (30)	0.556	15 (75)	5 (25)	0.333
Absent (*N* = 10)	8 (80)	2 (20)		9 (90)	1 (10)	

Abbreviations: AJCC, American Joint Committee on Cancer; hpf, high power field; LN, lymph node; LVI, lymphovascular invasion; PNI, perineural invasion.

The majority of the cases either were negative or demonstrated low expression. As tabulated in ►Table 1, there was no statistical significance between various clinicopathological parameters and ALDH-1 in CRCs. Cases with a higher stage including stages II and III predominantly showed the absence of ALDH1 staining.

Staining and Expression of ALDH1 in Adenoma and Its Correlation with Carcinoma

Our study included 20 cases of adenomas, of which 13 were low grade and 7 were high grade. The age range of patients with adenomas was 24 to 84 years, with a mean age of 58 years. Five of 7 (71%) patients with high-grade dysplasia

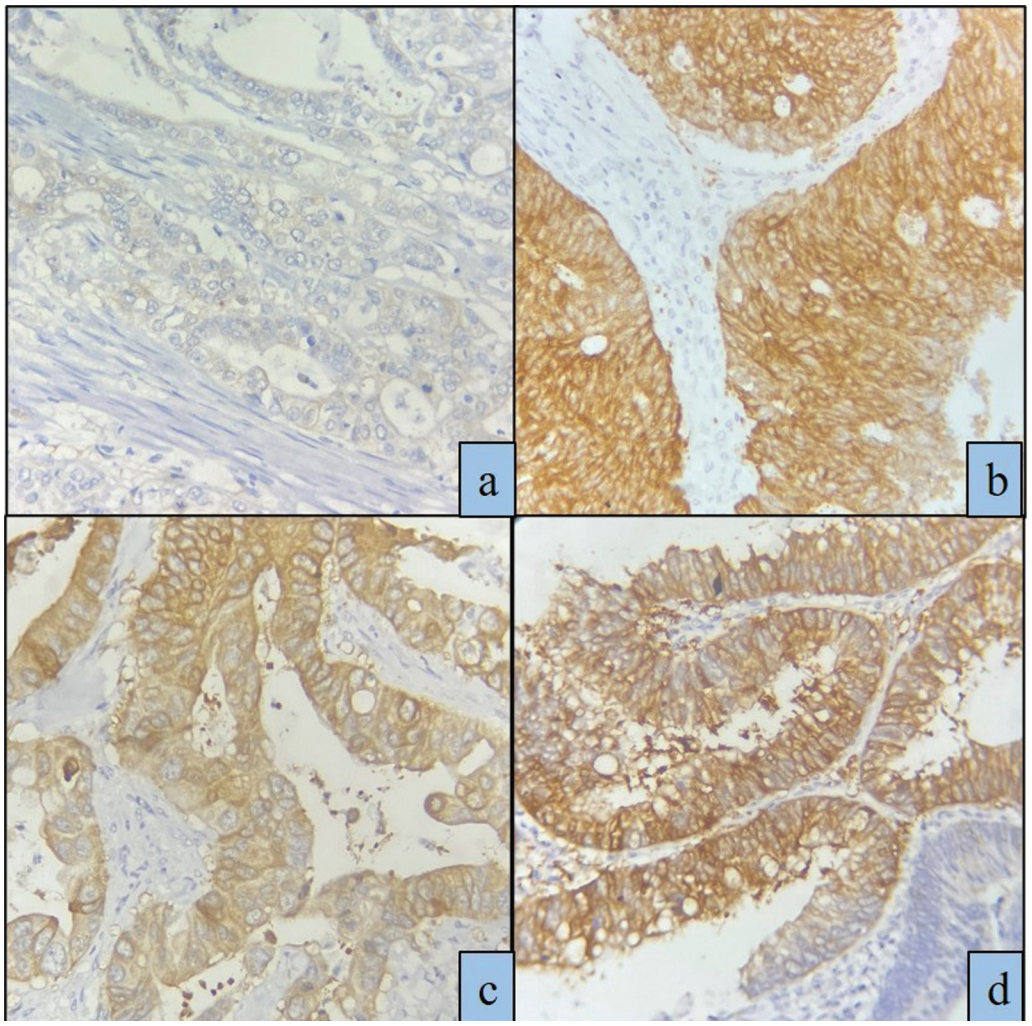

Fig. 1 Staining and expression of ALDH1. (**a**) Mild intensity and low expression in a case of colorectal carcinoma (ALDH1; 20X). (**b**) Strong intensity and high expression in a case of carcinoma (ALDH1; 40X). (**c**) Moderate intensity and high expression in a case of adenoma (ALDH1; 40X). (**d**) Strong intensity and high expression in a case of adenoma (ALDH1; 40X).

were younger than 58 years. Staining and expression of ALDH1 in adenoma did not show any association with the age of the patient (►**Table 2**).

As depicted in ►**Table 3**, adenomas showed positive staining in 75% cases (►**Fig. 1c, d**). A higher number of adenomas with low-grade dysplasia (66.7%) were positive for ALDH1 as compared to those with high-grade dysplasia (33.3%). Adenomas more frequently showed low expression (55%); high expression, when present, was noted more frequently in adenomas with low-grade dysplasia as compared to adenomas with high-grade dysplasia (55.6 vs. 45%).

When we compare these results with CRC, carcinomas were positive in only 26.7% cases. This difference was highly statistically significant ($p = 0.0005$). Similarly, 45% adenomas showed high expression as compared to 20% cases of carcinoma with high expression and this difference was also statistically significant ($p = 0.036$)

Staining of Adjacent Uninvolved Epithelium

Adjacent uninvolved mucosa was included in 20 of the 30 CRC cases. The uninvolved mucosa showed absent to minimal staining of ALDH1 in the surface epithelium and the

Table 2 Staining and expression of ALDH1 in Adenoma with low/high-grade dysplasia and correlation with age

Age	ALDH1					
	Staining			Expression		
	Positive	Negative	*p*-value	High	Low	*p*-value
≤58	7 (70%)	3 (30%)	0.60	4 (40%)	6 (60%)	0.65
>58	8 (80%)	2 (20%)		5 (50%)	5 (50%)	

Table 3 Comparison of staining of ALDH1 between adenoma and carcinoma

Diagnosis	Negative staining, *N* (%)		Positive staining, *N* (%)		*p*-value	Low expression, *N* (%)		High expression, *N* (%)		*p*-value
Adenoma (*N* = 20)	5 (25%)		15 (75%)		0.0005	11 (55%)		9 (45%)		0.036
	3 LGD	2 HGD	10 LGD	5 HGD		8 LGD	3 HGD	5 LGD	4 HGD	
Carcinoma (*N* = 30)	22 (73.3%)		8 (26.7%)			24 (80%)		6 (20%)		
Total	27		23			35		15		

Abbreviations: HGD, high-grade dysplasia; LGD, low-grade dysplasia.

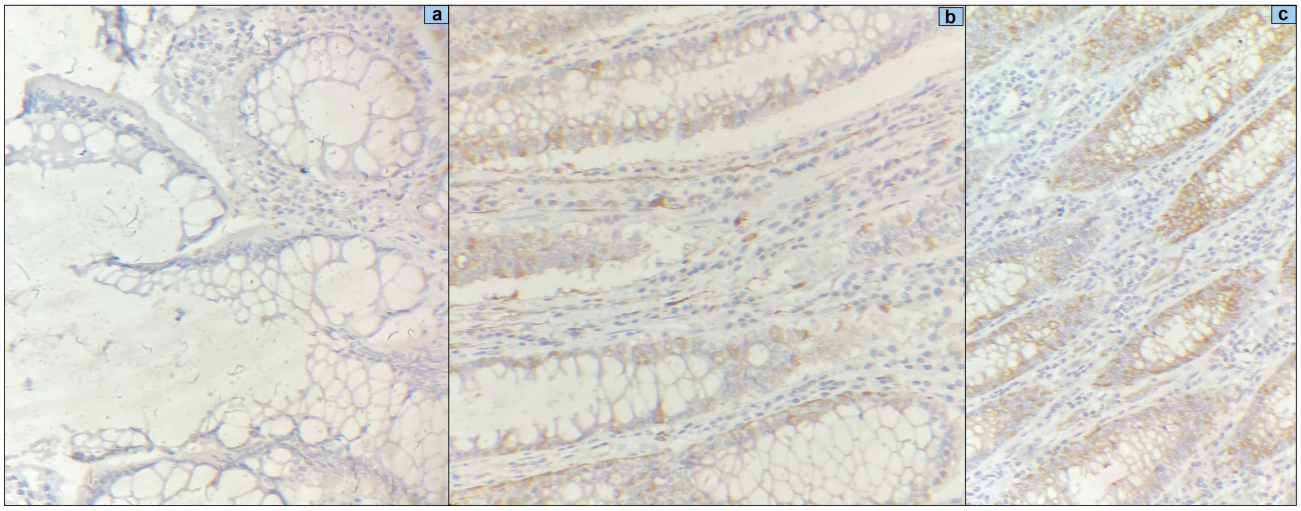

Fig. 2 Staining of ALDH1 in adjacent uninvolved epithelium. (**a**) Surface epithelium and the superficial crypts show absence of staining (40X). (**b**) Staining of moderate intensity is noted in few cells in the middle portion of the crypts (40X). (**c**) Staining of strong intensity in most of the cells in the deeper crypts (40X).

superficial crypts in contrast, adenomas showed the presence of staining up to the surface. The intensity and proportion of staining increased in the deeper crypts and was maximum at the base of the crypts (►**Fig. 2**). Positive staining was seen in 55% of cases.

Discussion

CRC is one of the leading causes of morbidity and mortality in the world.[28,33] Although, there has been significant improvement in its diagnosis and subsequent treatment, the majority of the patients still experience poor prognosis, which is attributable to drug resistance, metastasis, and recurrence.[30,34] It is postulated that cancer stem cells are responsible for its development, metastasis, drug resistance, and recurrence. Therefore, multiple studies have been performed to identify specific cancer stem cells that can be targeted to improve the prognosis of the affected patients.[30,33,35–37] In spite of many studies from different countries over the years, controversies still exist in identification of CRC biomarkers.[18,28,30,38,39] A literature search yielded few studies that analyzed the role of ALDH1 in CRC with variable results. However, to the best of the authors' knowledge, there has been no study from India, and only a few studies have included colorectal adenoma. Therefore, we studied the role of ALDH1, an emerging cancer stem cell marker in colorectal neoplasms including colorectal adenoma.

In our study, most of the carcinoma cases showed negative staining (73.3%) and low expression (80%) with ALDH1. Rezaee et al[30] and Kim et al[24] also reported similar results, unlike the studies by Hou et al,[22] Holah et al,[26] and Mohamed et al,[27] which showed high expression in about 60 to 70% of cases.

As mentioned in ►**Table 2**, our study did not observe significant association of ALDH1 staining and expression with any of the clinicopathological parameters. In the age group of ≤60 years, there was positive staining in 30.8% cases compared to 23.5% cases in patients older than 60 years. A higher expression of ALDH1 was also noted in patients ≤60 years. Rezaee et al[30] and Holah et al[26] also observed high expression in the cases belonging to the younger age group. However, their results were also not statistically significant.

In our study, we observed that most cases in the rectum showed positive staining and higher expression (66.7; 66.7) respectively, followed by the left colon (25%; 12.5%) and the right colon (18.2%; 18.2%). These findings were similar to the study conducted by Mohamed et al[27] and Li et al[10]; they also observed that ALDH1 expression was highest in the cases located in the rectum. Although their results were also similar to our study, the difference did not reach statistical significance in their studies.

Our study showed that the cases with a higher stage had negative staining or low expression. Only 22.2% cases of stage III showed positive stain compared to 25% of stage II cases and 50% of stage I cases. This result was similar to the study conducted by Kim et al.[29]

Out of the 30 carcinoma cases studied, adjacent uninvolved epithelium was identified in 20 cases, of which 11 cases (55%) showed patchy positive staining. The intensity of staining was mild and moderate in 27.3% each and strong in 45.4% of the positive cases. To the best of the authors' knowledge, a search of the English literature yielded only one study by Zhu et al that demonstrated ALDH1 expression in adjacent uninvolved epithelium in 6.9% cases only.[25]

Also, in our study 75% adenoma showed positive staining as compared to 26.7% cases of CRC. This difference was highly statistically significant ($p = 0.0005$); similarly, the expression of ALDH1 was higher in low-grade adenomas as compared to high-grade adenomas and carcinoma. This difference was also again statistically significant ($p = 0.036$). Variable results of ALDHA1 expression in adenoma subsets have also been explained in a study that included adenomas and subsequent development of metachronous adenomas postulating ALDHA1 as a putative biomarker in colorectal neoplasia.[31] To the best of authors' knowledge, only one study has explained the expression of ALDH1 in adenomas and carcinomas, but unlike our study, their study observed higher staining and expression in carcinomas compared to adenomas.[32]

Conclusion

Most of the cases of CRC showed negative staining and/or low expression with ALDH1 with none of the clinicopathological parameters showing statistically significant correlation with staining and expression. We also observed low expression in higher stage carcinomas. Interestingly, staining and expression were found to be highly statistically significant in adenomas, with increased chances of staining and expression in adenomas as compared to carcinoma. Thus, its absence not only suggests the role of alternate stem cells or other genetic events in neoplastic progression but perhaps also suggests better clinical outcome in patients who are positive for ALDH1. Larger studies might help validate our results and possibly help in the identification of ALDH1 as an important predictive biomarker. Negative staining and expression in a significant number of cases of CRC might suggest that it is not an ideal and reliable CRC stem cell marker and perhaps also not suitable for targeted therapy. However, multi-institutional studies with a larger number of cases are needed for further validation of our results.

Ethics Statement

Informed consent was taken from all the patients. The study adhered to the Declarations of Helsinki. The study was approved by the Institutional Ethics Committee (-KIIT/KIMS/IEC/98/2019).

Funding

None.

Conflict of Interest

None declared.

Acknowledgments

The authors would like to express their appreciation to the histotechnicians for their valuable technical assistance.

References

1 Siegel RL, Miller KD, Fuchs HE, Jemal A. Cancer statistics, 2022. CA Cancer J Clin 2022;72(01):7–33
2 Deo SVS, Kumar S, Bhoriwal S, et al. Colorectal cancers in low- and middle-income countries-demographic pattern and clinical profile of 970 patients treated at a tertiary care cancer center in India. JCO Glob Oncol 2021;7:1110–1115
3 Patel A, Hande V. Rising colorectal cancer in young adults: a warning for all! Let us adopt a healthy lifestyle and colorectal cancer screening. Indian J Cancer 2022;59(03):307–309
4 CROCODILE study group. Catastrophic expenditure and treatment attrition in patients seeking comprehensive colorectal cancer treatment in India: a prospective multicentre study. Lancet Reg Health Southeast Asia 2022;6:1–11
5 Ebrahimi N, Afshinpour M, Fakhr SS, et al. Cancer stem cells in colorectal cancer: Signaling pathways involved in stemness and therapy resistance. Crit Rev Oncol Hematol 2023;182:103920
6 Fulawka L, Donizy P, Halon A. Cancer stem cells: the current status of an old concept: literature review and clinical approaches. Biol Res 2014;47(01):66
7 Portney BA, Arad M, Gupta A, et al. ZSCAN4 facilitates chromatin remodeling and promotes the cancer stem cell phenotype. Oncogene 2020;39(26):4970–4982
8 Bhanu H, Mittal R, Raman S. Evaluation and clinicopathological correlation of CD44 in colorectal adenoma with low/high-grade dysplasia and carcinoma. Clin Cancer Investig J 2022;11(06):9–15
9 Vassalli G. Aldehyde dehydrogenases: not just markers, but functional regulators of stem cells. Stem Cells Int 2019;2019:3904645
10 Li H, Jiang Y, Pei F, et al. Aldehyde dehydragenase 1 and nodal as significant prognostic markers in colorectal cancer. Pathol Oncol Res 2016;22(01):121–127
11 Bettinardi V, Picchio M, Di Muzio N, Gilardi MC. Motion management in positron emission tomography/computed tomography for radiation treatment planning. Semin Nucl Med 2012;42(05):289–307
12 Kiefer FW, Orasanu G, Nallamshetty S, et al. Retinaldehyde dehydrogenase 1 coordinates hepatic gluconeogenesis and lipid metabolism. Endocrinology 2012;153(07):3089–3099
13 Tomita H, Tanaka K, Tanaka T, Hara A. Aldehyde dehydrogenase 1A1 in stem cells and cancer. Oncotarget 2016;7(10):11018–11032
14 Wei D, Peng JJ, Gao H, Zhang T, Tan Y, Hu YH. ALDH1 expression and the prognosis of lung cancer: a systematic review and meta-analysis. Heart Lung Circ 2015;24(08):780–788
15 Koh YW, Han JH, Haam S, Jung J. ALDH1 expression correlates with an epithelial-like phenotype and favorable prognosis in lung adenocarcinoma: a study based on immunohistochemistry and mRNA expression data. J Cancer Res Clin Oncol 2019;145(06):1427–1436
16 Zheng R, Wang J, Wu Q, et al. Expression of ALDH1 and TGFβ2 in benign and malignant breast tumors and their prognostic implications. Int J Clin Exp Pathol 2014;7(07):4173–4183
17 Xing P, Dong H, Liu Q, et al. ALDH1 expression and vasculogenic mimicry are positively associated with poor prognosis in patients with breast cancer. Cell Physiol Biochem 2018;49(03):961–970
18 Huang R, Li X, Holm R, Trope CG, Nesland JM, Suo Z. The expression of aldehyde dehydrogenase 1 (ALDH1) in ovarian carcinomas and its clinicopathological associations: a retrospective study. BMC Cancer 2015;15:502
19 Fischer AK, Pham DL, Bösmüller H, et al. Comprehensive in situ analysis of ALDH1 and SOX2 reveals increased expression of stem

cell markers in high-grade serous carcinomas compared to low-grade serous carcinomas and atypical proliferative serous tumors. Virchows Arch 2019;475(04):479–488
20 Huang EH, Hynes MJ, Zhang T, et al. Aldehyde dehydrogenase 1 is a marker for normal and malignant human colonic stem cells (SC) and tracks SC overpopulation during colon tumorigenesis. Cancer Res 2009;69(08):3382–3389
21 Lugli A, Iezzi G, Hostettler I, et al. Prognostic impact of the expression of putative cancer stem cell markers CD133, CD166, CD44s, EpCAM, and ALDH1 in colorectal cancer. Br J Cancer 2010; 103(03):382–390
22 Hou Y, Liu YY, Zhao XK. Expression of aldehyde dehydrogenase 1 in colon cancer. Asian Pac J Trop Med 2013;6(07):574–577
23 Zhou F, Mu YD, Liang J, Liu ZX, Chen HS, Zhang JF. Expression and prognostic value of tumor stem cell markers ALDH1 and CD133 in colorectal carcinoma. Oncol Lett 2014;7(02):507–512
24 Kim YH, Kim G, Kwon CI, Kim JW, Park PW, Hahm KB. TWIST1 and SNAI1 as markers of poor prognosis in human colorectal cancer are associated with the expression of ALDH1 and TGF-β1. Oncol Rep 2014;31(03):1380–1388
25 Zhu B, Wang Y, Wang X, et al. Evaluation of the correlation of MACC1, CD44, Twist1, and KiSS-1 in the metastasis and prognosis for colon carcinoma. Diagn Pathol 2018;13(01):45
26 Holah NS, Aiad HA, Asaad NY, Elkhouly EA, Lasheen AG. Evaluation of the role of ALDH1 as cancer stem cell marker in colorectal carcinoma: an immunohistochemical study. J Clin Diagn Res 2017;11(01):EC17–EC23
27 Mohamed SY, Kaf RM, Ahmed MM, Elwan A, Ashour HR, Ibrahim A. The prognostic value of cancer stem cell markers (Notch1, ALDH1, and CD44) in primary colorectal carcinoma. J Gastrointest Cancer 2019;50(04):824–837
28 Vishnubalaji R, Manikandan M, Fahad M, et al. Molecular profiling of ALDH1^{+} colorectal cancer stem cells reveals preferential activation of MAPK, FAK, and oxidative stress pro-survival signalling pathways. Oncotarget 2018;9(17):13551–13564
29 Kim BH, Oh HK, Kim DW, Kang SB, Choi Y, Shin E. Clinical implications of cancer stem cell markers and ABC transporters as a predictor of prognosis in colorectal cancer patients. Anticancer Res 2020;40(08):4481–4489
30 Rezaee M, Gheytanchi E, Madjd Z, Mehrazma M. Clinicopathological significance of tumor stem cell markers ALDH1 and CD133 in colorectal carcinoma. Iran J Pathol 2021;16(01):40–50
31 Bartley AN, Parikh N, Hsu CH, et al. Colorectal adenoma stem-like cell populations: associations with adenoma characteristics and metachronous colorectal neoplasia. Cancer Prev Res (Phila) 2013; 6(11):1162–1170
32 Cui G, Xu G, Zhu L, et al. Temporal and spatial changes of cells positive for stem-like markers in different compartments and stages of human colorectal adenoma-carcinoma sequence. Oncotarget 2017;8(28):45311–45322
33 O'Dwyer D, Ralton LD, O'Shea A, Murray GI. The proteomics of colorectal cancer: identification of a protein signature associated with prognosis. PLoS One 2011;6(11):e27718
34 Galizia G, Gemei M, Del Vecchio L, et al. Combined CD133/CD44 expression as a prognostic indicator of disease-free survival in patients with colorectal cancer. Arch Surg 2012;147(01):18–24
35 Goossens-Beumer IJ, Zeestraten EC, Benard A, et al. Clinical prognostic value of combined analysis of Aldh1, Survivin, and EpCAM expression in colorectal cancer. Br J Cancer 2014;110(12):2935–2944
36 Sedaghat S, Gheytanchi E, Asgari M, Roudi R, Keymoosi H, Madjd Z. Expression of cancer stem cell markers OCT4 and CD133 in transitional cell carcinomas. Appl Immunohistochem Mol Morphol 2017;25(03):196–202
37 Camp RL, Charette LA, Rimm DL. Validation of tissue microarray technology in breast carcinoma. Lab Invest 2000;80(12):1943–1949
38 Cherciu I, Bărbălan A, Pirici D, Mărgăritescu C, Săftoiu A. Stem cells, colorectal cancer and cancer stem cell markers correlations. Curr Health Sci J 2014;40(03):153–161
39 Clevers H. The cancer stem cell: premises, promises and challenges. Nat Med 2011;17(03):313–319

