



A Rare Case of Fetal Hydrocolpos Secondary to Low Vaginal Atresia

Athira Rajamma¹ Megha Venkataraman²

¹Department of Obstetrics and Gynaecology, Khoula Hospital, Muscat, Oman

²Fetal Medicine Unit, Obstetrics and Gynaecology, Khoula Hospital, Muscat, Oman

Address for correspondence Athira Rajamma, DNB, Obstetrics and Gynaecology, Part 2 MRCOG, Medical Officer, Obstetrics and Gynaecology, Qurum Towers, Building Number 1011, Flat 110, Qurum, Muscat (e-mail: athira.ralu@gmail.com).

J Fetal Med 2023;10:120–123.

Abstract

Female urogenital anomalies are often difficult to evaluate by ultrasonography, especially in late gestation. We report a case of fetal hydrocolpos detected by a fetal medicine scan at 33 weeks of gestation. Antenatal ultrasound by the fetal medicine unit showed a singleton fetus with a huge retrovesical cystic mass extending from the mid-abdomen to the perineum. Bilateral hydronephrosis was noted. Postnatal ultrasound showed the findings of a markedly dilated vagina containing thick echogenic fluid that was extended up to the umbilical level displacing the urinary bladder upwards and anteriorly and rectum posteriorly, suggesting hydrocolpos. Bilateral hydronephrosis was also noted. Postnatal examination of the neonate showed a distended abdomen with a well-defined mass arising from the pelvis extended to the umbilicus. External genitalia were of a normal female. There were no other dysmorphic features. Hydrocolpos was secondary to low vaginal atresia. Aspiration of the mass was performed on the first postnatal day.

Keywords

- ▶ huge
- ▶ hydrocolpos
- ▶ hydronephrosis
- ▶ perineum
- ▶ rectum
- ▶ retrovesical
- ▶ vaginal atresia

Introduction

A 27-year-old G2A1 presented to our clinic for regular antenatal care at 24 weeks with no risk factors. A routine ultrasound examination revealed subjectively reduced liquor. However, further study after 4 weeks showed normal liquor and mild renal pelvis dilatation. Follow-up ultrasound by the fetal medicine unit at 33 weeks revealed a huge retrovesical homogenous cystic mass of 7.5 cm × 4 cm extending from the mid-abdomen to the perineum between the urinary bladder and rectum. The external genitalia were of a typical female (▶ Fig. 1A and B). There was bilateral renal pelvicalyceal (13 and 14 mm—UTD A2-3) and ureteric dilatation (▶ Fig. 2A and B). Hydrometrocolpos/hydrocolpos with secondary renal dilatation due to the mass were sus-

pected. The baby was delivered by an elective caesarean section at 38 weeks for a breech presentation. Postnatal examination of the neonate showed distended abdomen with a well-defined mass arising from the pelvis extending up to the umbilicus. External genitalia were of a normal female. There were no other dysmorphic features. Hydrocolpos secondary to vaginal atresia was confirmed after birth by ultrasound (which showed a thick echogenic fluid collection of 9 cm × 6 cm × 4 cm in the vagina) magnetic resonance imaging (MRI), laparoscopy, and cystovaginoscopy (▶ Fig. 3A–F). It was drained by an ultrasound-guided trans-abdominal pigtail insertion into the lower abdomen under local anesthesia. A free flow of milky white fluid was established. The baby was followed up regularly with the pediatric surgery team and showed improvement in clinical

article published online
October 13, 2023

DOI <https://doi.org/10.1055/s-0043-1774754>.
ISSN 2348-1153.

© 2023. Society of Fetal Medicine. All rights reserved.

This is an open access article published by Thieme under the terms of the Creative Commons Attribution-NonDerivative-NonCommercial-License, permitting copying and reproduction so long as the original work is given appropriate credit. Contents may not be used for commercial purposes, or adapted, remixed, transformed or built upon. (<https://creativecommons.org/licenses/by-nc-nd/4.0/>)

Thieme Medical and Scientific Publishers Pvt. Ltd., A-12, 2nd Floor, Sector 2, Noida-201301 UP, India

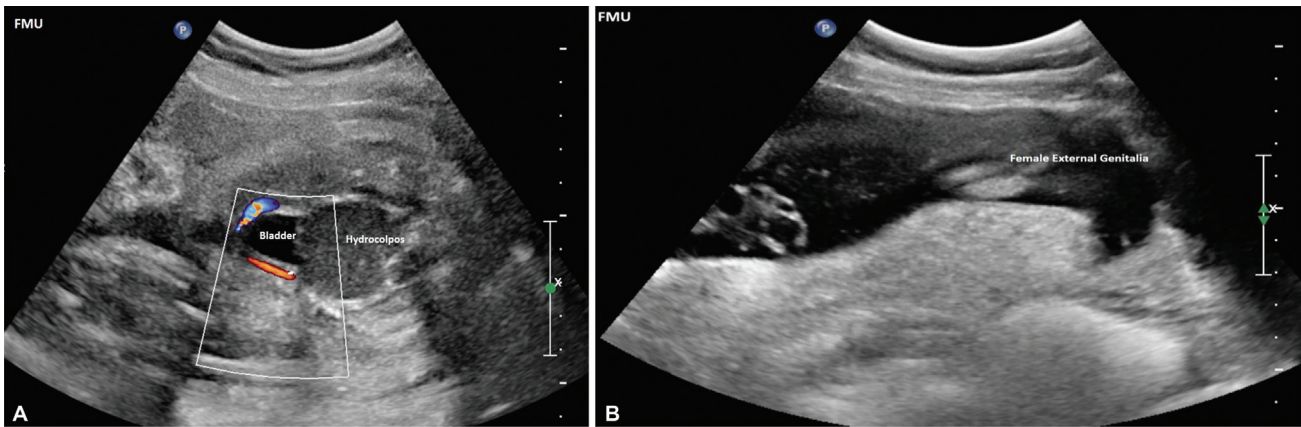


Fig. 1 (A) Antenatal fetal medicine unit (FMU) scan at 33 weeks of gestation showing a well-defined mass of 7.5 cm × 4 cm between the bladder and the rectum. (B) Antenatal (FMU) scan at 33 weeks of gestation showing normal female external genitalia.

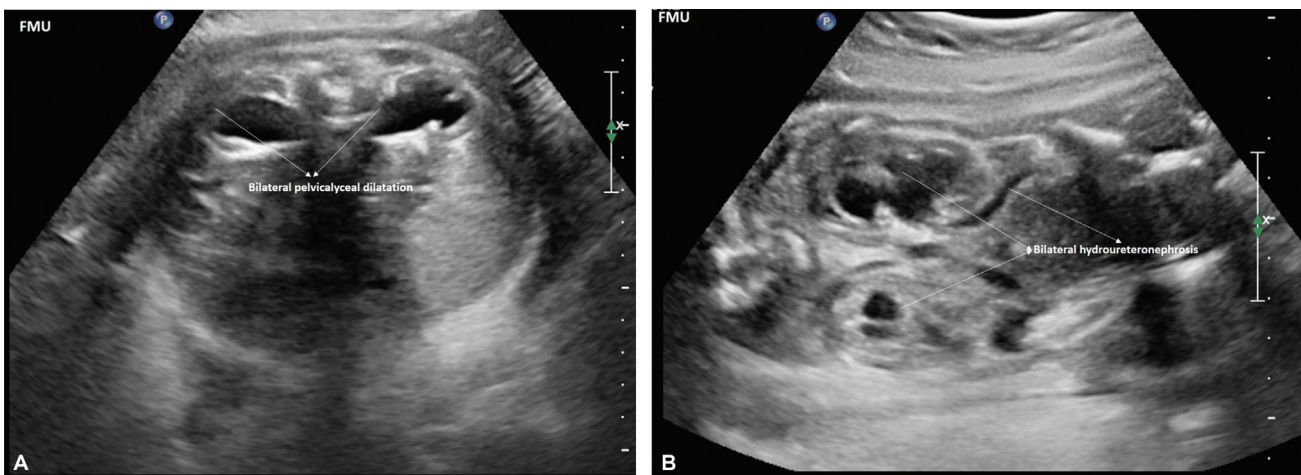


Fig. 2 (A) Antenatal fetal medicine unit (FMU) scan at 33 weeks of gestation showing bilateral pelvicalyceal dilatation. (B) Antenatal (FMU) scan at 33 weeks of gestation showing bilateral hydroureteronephrosis.

presentation. Definite surgery has been planned for a later date.

Discussion

Hydrocolpos is a clinical condition in which there is a cystic distension of the vagina with fluid, sometimes it is seen with fluid accumulation in the uterus (hydrometrocolpos) as well in the tubes (hydrosalpinx). It is thought to arise from accumulation of secretions in the vagina due to excessive stimulation of the fetal cervical mucous glands by maternal estrogen in the presence of an atretic vagina or imperforate hymen.¹ Such congenital obstructions of the female genital tract have been long recognized. Conversely, neonatal hydrometrocolpos is a rare condition despite the fact that imperforate hymen is the most common congenital anomaly of the female genital tract. A few cases of physiological uterine effusions are also been reported recently in literature.²

Vaginal atresia is a congenital anomaly classified under disorders of sex development. It is caused by failure of connection between Müllerian ducts and urogenital sinus

in the first trimester of the early embryonic period. It is a condition in which the lower portion of the vagina is represented merely by fibrous tissue, while the adjacent superior structures (uterus) are well-defined. These congenital disorders usually lead to secondary complications such as hydrocolpos and hydrometrocolpos.³ They are usually diagnosed in the third trimester, probably because maternal hormonal stimulation is insufficient for glandular secretion before this age.^{4,5}

Congenital hydrocolpos is a rare condition with a prevalence of 1:16,000.⁵ Prenatal diagnosis of fetal hydrometrocolpos is uncommon, with only 22 cases reported in the literature and only a few cases of prenatal imaging of this condition available to date. Fluid accumulation in the vagina can cause compression of the adjacent bladder leading to urinary retention and hydronephrosis and even renal damage during infancy. Other secondary complications include gastrointestinal obstruction disorders.¹ With increased severity and vaginal outlet obstruction, hydrocolpos can present as pelvic mass,⁴ like in our case there was fullness in abdomen with a palpable lower abdominal mass. Other than

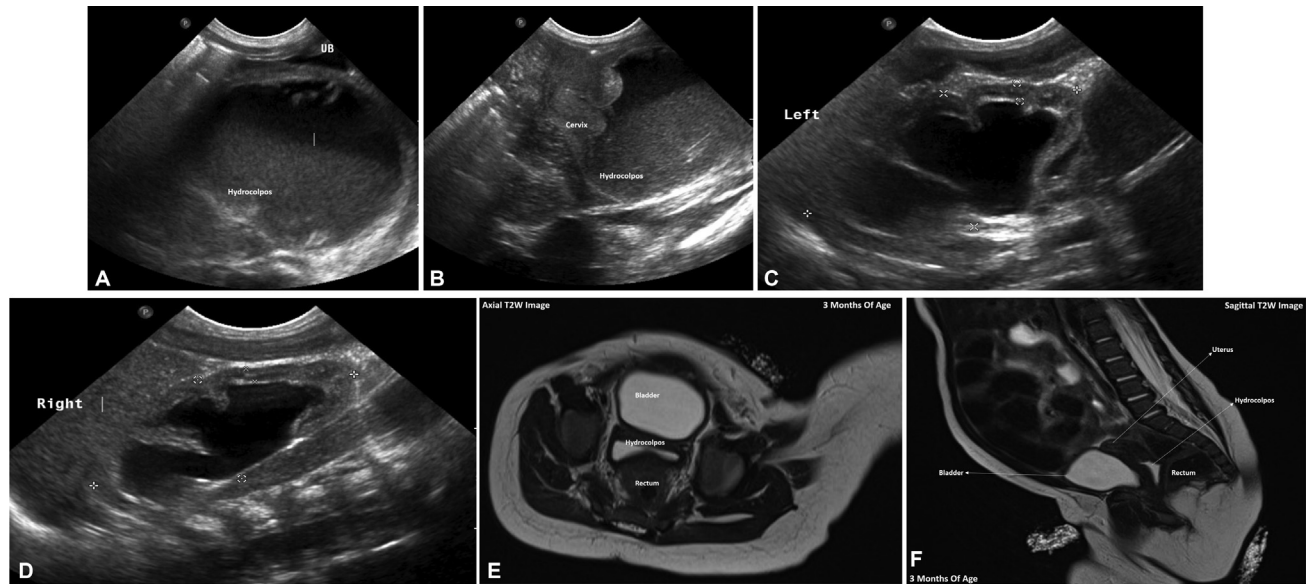


Fig. 3 (A) Postnatal ultrasound of neonate showing markedly dilated vagina containing thick echogenic fluid measuring 9 cm × 6 cm × 4 cm displacing the bladder upward anteriorly. (B) Postnatal ultrasound of neonate showing markedly dilated vagina containing thick echogenic fluid showing in relation with cervix. (C, D) Postnatal ultrasound of neonate showing bilateral pelvic/cecal dilatation. (E) Postnatal follow-up magnetic resonance imaging (MRI) axial T2-weighted (T2W) image of neonate showing residual collection between the bladder and the rectum. (F) Postnatal follow-up magnetic resonance imaging (MRI) sagittal T2W image of neonate showing residual collection between the bladder and the rectum.

vaginal atresia, it could be due to an imperforate hymen, a vaginal septum, or a cloacal malformation

Symptoms of hydrocolpos caused by vaginal atresia can present as a wide range of gastrointestinal and urogenital disorders, which could complicate the diagnosis. These symptoms include nausea, dysuria, polyuria, urinary retention, abdominal pain, acute abdomen, abdominal mass, and abdominal cysts.^{6–9} Our case was identified and managed early; hence, all such complications could be prevented with good urine output and normal renal function.

In addition, other types of abdominal cysts such as ovarian cysts, mesenteric cysts, and meconium cysts should be considered in the differential diagnosis.¹⁰

The first diagnostic approach for hydrocolpos secondary to vaginal atresia is a physical examination of the genitalia for the detection of the membrane in the vaginal opening.¹¹ In the index case, the vagina was in a normal position with no obvious membrane covering it. Ultrasound scan is another diagnostic method that can be used. However, MRI, computed tomography (CT) scan and contrast-enhanced CT scan can be used for differential diagnosis. In such cases, MRI can clearly show the anatomy of the perineum, septate uterus, septate vagina fluid accumulation, and imperforate hymen.^{10,12} Adaletli et al diagnosed hydrocolpos in a fetus by detecting the exact location and extent of a cystic lesion using MRI.³ Consistent with our report, several studies have shown that MRI can be used for accurate and definite diagnosis of hydrocolpos.^{1,6,10} In 2005, Hayashi et al reported a case of hydrometrocolpos secondary to cloacal anomaly by MRI.¹³

Murthy et al reported two newborns with hydrocolpos and hydronephrosis secondary to congenital vaginal atresia.⁴

Moreover, some studies have shown that sepsis is also a serious complication in this group of patients. Some studies have reported infant mortality due to sepsis caused by hydrocolpos.^{14,15}

Treatment of vaginal atresia is more complex. Nowadays, various complex surgical and nonsurgical techniques are used for vaginal reconstruction. Treatment of vaginal atresia can be performed using amnion graft, buccal mucosa graft, skin graft, a sigmoid colon segment, Frank's method of progressive perineal dilatation, and combined techniques such as laparoscopy and balloon vaginoplasty. Disadvantages of these interventions include long recovery time, painful non-surgical treatment, and high complication rate for colon and skin grafting.^{16,17} Cruciate incision or other surgical procedures are used for the treatment of hydrocolpos with the aim to protect the Bartholin's gland.^{18,19}

Conclusion

Hydrocolpos secondary to vaginal atresia is a rare condition that requires a high index of suspicion for diagnosis. It may be suspected prenatally by ultrasonography and confirmed after birth by MRI which can be a useful tool to assess associated anomalies of the genitourinary system. Early diagnosis reduces the incidence of complications such as infection, rupture, and renal failure. Prenatal diagnosis aids in timely intervention and management of congenital fetal malformations.

Note

This article has been presented as e-poster during RCOG virtual world congress 2022.

Authors' Contributions

A.R. and M.V. conceptualized the study. M.V. was involved in methodology and data collection. A.R. helped in writing, original draft preparation, and review and editing. All authors have read and agreed to the published version of the manuscript.

Patient Consent

The identity of the patient is not revealed in the case report and the image is obscured to conceal the identity.

Funding

None.

Conflict of Interest

None declared.

References

- Murthy V, Costalez J, Weiner J, Voos K. Two neonates with congenital hydrocolpos. *Case Rep Pediatr* 2013;2013:692504
- Wang L, Chen L, Li D, Wang B, Yang Z. Characteristics of fetal physiological and pathological uterine effusion observed on prenatal ultrasonography: a case report. *BMC Pregnancy Childbirth* 2022;22(01):405
- Adaletli I, Ozer H, Kurugoglu S, Emir H, Madazli R. Congenital imperforate hymen with hydrocolpos diagnosed using prenatal MRI. *AJR Am J Roentgenol* 2007;189(01):W23-5
- Chantraine F, Tutschek B. Abdominal cysts. In: Copel JA, D'Alton ME, Feltovich H, et al, eds. *Obstetric Imaging: Fetal Diagnosis and Care*. 2nd ed. Philadelphia, PA: Elsevier; 2018:97-105
- Ostadian N, Razi T. A case report of a posterior sagittal vaginoplasty for the treatment of congenital vaginal atresia. *Medical Scientific Journal* 2005;4(02):172-174
- Basaran M, Usal D, Aydemir C. Hymen sparing surgery for imperforate hymen: case reports and review of literature. *J Pediatr Adolesc Gynecol* 2009;22(04):e61-e64
- Ayaz UY, Dilli A, Api A. Ultrasonographic diagnosis of congenital hydrometrocolpos in prenatal and newborn period: a case report. *Med Ultrason* 2011;13(03):234-236
- Sakalkale R, Samarakkody U. Familial occurrence of imperforate hymen. *J Pediatr Adolesc Gynecol* 2005;18(06):427-429
- Aygun C, Ozkaya O, Ayyıldız S, Güngör O, Mutlu B, Küçüködük S. An unusual cause of acute renal failure in a newborn: hydro-metrocolpos. *Pediatr Nephrol* 2006;21(04):572-573
- Gupta M, Bajwa SJS, Gupta M. Diagnostic dilemmas in management of neonatal hydrometrocolpos: a crucial role of magnetic resonance imaging. *Psychiatr Rehabil J* 2014;3(04): 251-254
- Bajwa SJ, Kalra S. Logical empiricism in anesthesia: a step forward in modern day clinical practice. *J Anaesthesiol Clin Pharmacol* 2013;29(02):160-161
- Tseng JJ, Ho JY, Chen WH, Chou MM. Prenatal diagnosis of isolated fetal hydrocolpos secondary to congenital imperforate hymen. *J Chin Med Assoc* 2008;71(06):325-328
- Hayashi S, Sago H, Kashima K, Kitano Y, Kuroda T, Honna T. Prenatal diagnosis of fetal hydrometrocolpos secondary to a cloacal anomaly by magnetic resonance imaging. *Ultrasound Obstet Gynecol* 2005;26:577-579
- Bischoff A, Levitt MA, Breech L, Loudon E, Peña A. Hydrocolpos in cloacal malformations. *J Pediatr Surg* 2010;45(06):1241-1245
- Hammad FT, Upadhyay VA. Neonatal infravesical obstruction in females. *Saudi Med J* 2005;26(10):1630-1633
- Eftekhari T, Ghanbari Z, Foroghifar T, Sheikhhassani S, Haghollahi F. Comparing sexual function in normal women and women having undergone vaginoplasty for Rokitansky syndrome. *J Reprod Infertil* 2010;11(04):269-273
- Garcia-Roig M, Castellan M, Gonzalez J, et al. Sigmoid vaginoplasty with a modified single Monti tube: a pediatric case series. *J Urol* 2014;191(5, suppl):1537-1542
- Ali A, Cetin C, Nedim C, Kazim G, Cemalettin A. Treatment of imperforate hymen by application of Foley catheter. *Eur J Obstet Gynecol Reprod Biol* 2003;106(01):72-75
- Garcia Rodriguez R, Pérez González J, Garcia Delgado R, et al. Fetal hydrometrocolpos and congenital imperforate hymen: prenatal and postnatal imaging features. *J Clin Ultrasound* 2018;46(08): 549-552