



A Rare Occurrence of Solid Gynecological Malignancy Synchronous with Hematological Malignancy: Rare Case and Review of Literature

Rubi Gupta¹ Pariseema Dave¹ Bijal Patel¹ Remi Abdul Shukur¹

¹Department of Gynaecological Oncology, Gujarat Cancer & Research Institute, Ahmedabad, Gujarat, India

Address for correspondence Pariseema Dave, Professor and Head of The Department of Gynaecological Oncology, Gujarat Cancer & Research Institute, Ahmedabad, Gujarat, India (e-mail: pariseema.dave@gcriindia.org).

Ind J Med Paediatr Oncol

Abstract

A synchronous solid and hematological malignancy is an uncommon condition in which a patient develops two or more primary cancers, one of which is a solid malignancy and the other one is a hematological malignancy, within 6 months of primary cancer diagnosis. The most common histology in solid malignancies is gastrointestinal adenocarcinoma, which coexists with the lymphoma subtype diffuse large B-cell lymphoma (DLBCL). Here, we report an extremely rare combination of serous carcinoma of the ovary synchronous with lymphoma of DLBCL subtype. A woman aged 52 years presented with an abdominal mass and abdominal pain for a short duration of 15 days. She was evaluated using clinical, radiological, and biochemical parameters. She was diagnosed with non-Hodgkin lymphoma by tru-cut biopsy from a bony lytic lesion and ovarian cancer by staging laparotomy. R-CHOP (rituximab, cyclophosphamide, doxorubicin hydrochloride, vincristine, and prednisolone) chemotherapy for lymphoma and staging laparotomy for persistent adnexal mass resulted in complete remission of both ovarian cancer and lymphoma. She received paclitaxel and carboplatin-based postoperative chemotherapy as an adjuvant for ovarian cancer.

Keywords

- ▶ synchronous multiple primary malignancies
- ▶ lymphoma
- ▶ serous ovarian cancer

Introduction

Synchronous tumors account for less than 5% of all malignancies. The prevalence of synchronous tumors in one patient ranges between 0.73 and 11.7%.¹ It is an extremely rare form of hematological malignancy. Synchronous tumors are defined as tumors that appear within 6 months of one another. They could be in the same or separate organs.² To define synchronous malignant tumors, consider the following: metastasis should not be present, both tumors must exhibit malignancy criteria, and they must differ pathologically from one another.³ The coexistence of gynecological solid tumors with hematological malignancy is a very rare combination. We report a case of non-Hodgkin lymphoma diffuse large B-cell lymphoma (NHL DLBCL type) with serous

carcinoma of the ovary. To the best of our knowledge, this is the first case of synchronous NHL (DLBCL) and ovarian serous carcinoma in the present literature. The most common and aggressive subtypes of NHL and carcinoma ovary are DLBCL and high-grade serous carcinoma, respectively. Three to four percent of DLBCL had synchronous multiple primary malignancies (MPMs).⁴ We discuss management, prognosis, and the complicated hospital course that resulted in the diagnosis of synchronous primary malignancies.

Case Description

A woman aged 52 years with a history of ischemic heart disease was presented with abdominal pain and abdominal mass for the past 15 days. Per abdomen clinical examination,

DOI <https://doi.org/10.1055/s-0043-1775830>.
ISSN 0971-5851.

© 2023. The Author(s).

This is an open access article published by Thieme under the terms of the Creative Commons Attribution License, permitting unrestricted use, distribution, and reproduction so long as the original work is properly cited. (<https://creativecommons.org/licenses/by/4.0/>)

Thieme Medical and Scientific Publishers Pvt. Ltd., A-12, 2nd Floor, Sector 2, Noida-201301 UP, India

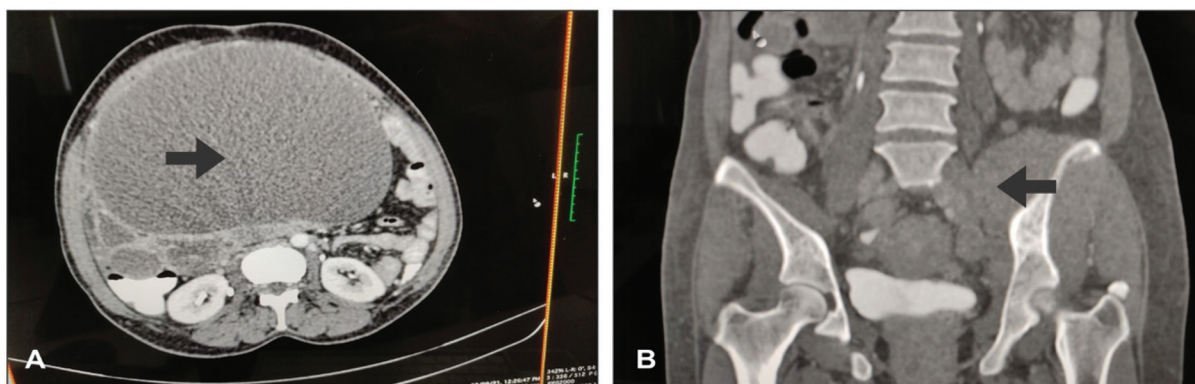


Fig. 1 (A) Cystic adnexal mass. (B) A bony lytic lesion with muscle infiltrates on computed tomography (CT) scan.

radiological imaging, and tumor markers were used to assess her for the same. Clinical findings suggested a smooth, mobile mass of 32 weeks in size. A computed tomography (CT) scan of the abdomen, pelvis, and thorax revealed a solid cystic mass 19 × 20 cm (right), 7 × 8 cm (left) (►Fig. 1B), ascites with omental, muscle, and pleural infiltrates, and a lytic metastatic lesion (50 × 25 mm) at the left iliac bone (►Fig. 1A). CA125 was 944 IU/mL, carcinoembryonic antigen was 17.3 ng/mL, and CA19-9 was 41.9 IU/mL. Due to extensive disease involving the muscle and pleura, the decision for neoadjuvant chemotherapy was made with a plan of ultrasound-guided biopsy from the lesion.

Although an ovarian tissue biopsy was negative for malignancy, ascitic fluid cytology and cell block were suspicious for malignancy. Again, a repeat omental biopsy revealed no evidence of malignancy with borderline epithelial tumor component. A third biopsy from a different suspicious area was recommended to confirm the diagnosis.

This biopsy of a bony lytic lesion with muscle infiltrates showed a monotonous population of large-sized cells arranged in sheets with abundant apoptosis indicating NHL B-cell type, and immunohistochemistry (IHC) panel (positive for LCA, CD-20, BCL-6, and PAX-5 and negative for WT1, CD2, BCL-12, and MUM1) confirmed the diagnosis of diffuse large B-cell lymphoma, germinal center type (►Fig. 2A and B). A bone marrow biopsy revealed no evidence of malignancy and confirmed the primary lymphoma (NHL).

The case was discussed in the tumor board, and it was decided that at first chemotherapy for aggressive hematological malignancy would be administered, followed by an evaluation for ovarian mass presumed borderline epithelial malignancy. She underwent one cycle of cytoreduction CVP (cyclophosphamide, vincristine, prednisolone) followed by six cycles of R-CHOP (rituximab, cyclophosphamide, doxorubicin hydrochloride, vincristine, and prednisolone)

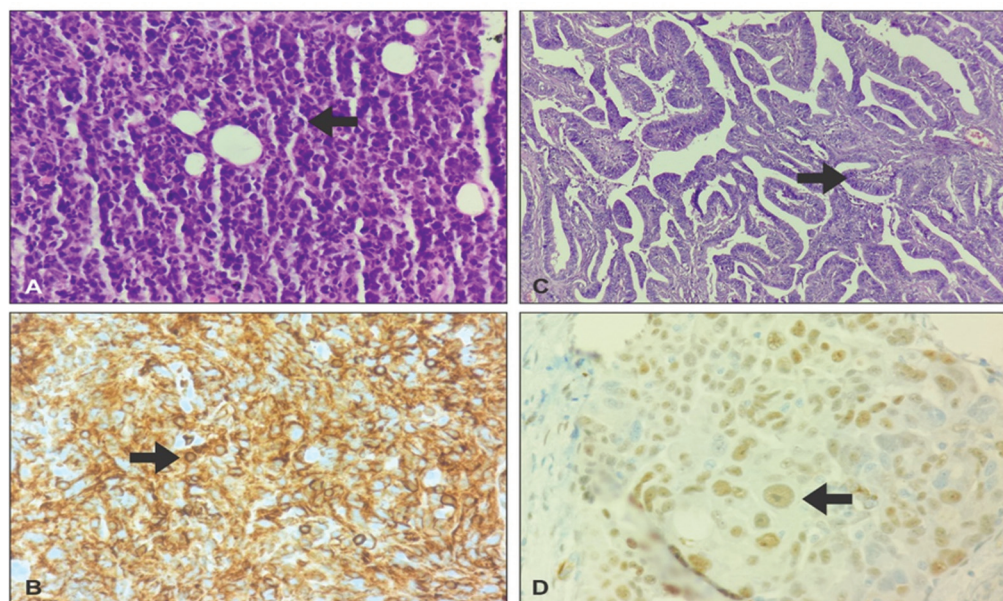


Fig. 2 (A) Hematoxylin and eosin (H&E) staining showing the sheet of atypical large lymphoid cells with hyperchromatic nuclei and eosinophilic cytoplasm with brisk apoptotic and mitotic activity for non-Hodgkin lymphoma (NHL). (B) Immunohistochemistry (IHC) showing membranous CD20 positivity. (C) High-grade (HG) nuclei with papillary architecture on final surgical specimen. (D) WT1 positive on IHC for final surgical specimen.

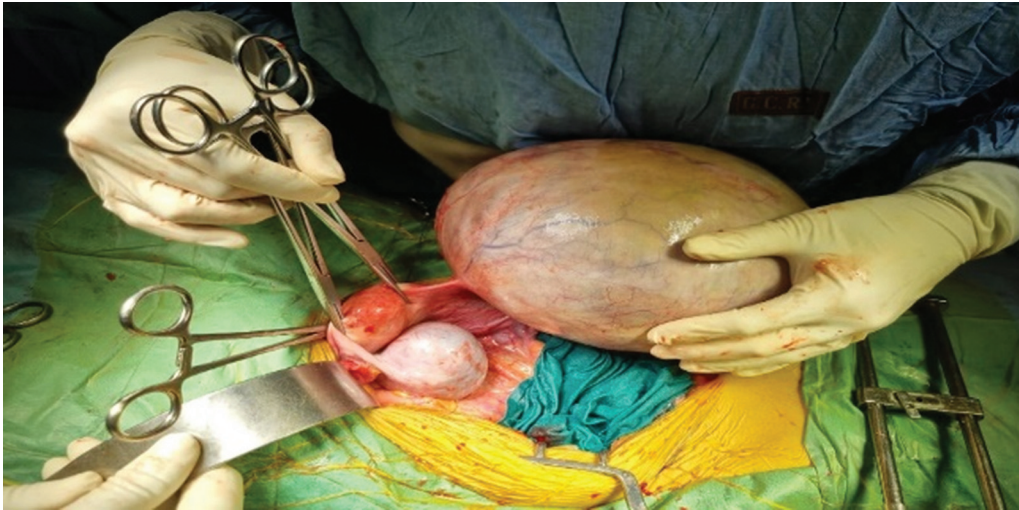


Fig. 3 Intraoperative finding.

regimen chemotherapy. Dose modification (10% dose reduction) was required after the fifth cycle of R-CHOP due to grade 3 thrombocytopenia. The size of the bony lesion reduced on CT evaluation, but the size of the adnexal mass remained unchanged. Positron emission tomography-CT imaging revealed a bilateral adnexal mass with a maximum uptake of 4.0 and no metastatic lesion elsewhere. As a result, she underwent interval cytoreductive surgery, including abdominal hysterectomy, bilateral salpingo-oophorectomy, omentectomy, and deposit removal from the pouch of Douglas as much as possible. It was suboptimal surgery leaving residual tumor at the mesentery and pouch of Douglas. **► Fig. 3** depicts an intraoperative finding (uterus with bilateral ovarian masses, one predominantly cystic, and another predominantly solid).

The final pathology specimen revealed high-grade serous ovarian carcinoma with a 3-cm omental carcinomatous deposit (FIGO stage IIIc). IHC panel confirmed high-grade serous carcinoma of the ovary (positive for WT1, AE1) and no lymphomatous metastasis to the ovary (negative for LCA) (**► Fig. 2C and D**).

She received and well-tolerated six cycles of adjuvant chemotherapy (paclitaxel and carboplatin) without dose modification. The patient received involved-field radiation therapy for residual bony lesions and backache. Complete remission of both lymphoma and ovarian cancer with treatment was achieved. She is on regular follow-up as per guidelines.

Discussion

MPMs are two or more cancers diagnosed at the same time or within 6 months of each other. A solid tumor is a mass of abnormal cells that develops in an organ or tissue, such as the breast, lung, or colon. Hematological cancers, such as leukemia, lymphoma, and myeloma, are cancers that affect the blood cells or the lymphatic system.⁵ Solid malignancy with hematological malignancy can arise in various combi-

nations and locations. The incidence of this synchronous type of malignancy is extremely rare, with only case reports or series available in literature. We also report a case of dual solid and hematological malignancy in one patient, at Gujarat Cancer and Research Institute in Ahmedabad with a very common presentation of a pelvic mass. To the best of our knowledge, this is the first reported case of synchronous NHL (DLBCL) and serous carcinoma of ovary in one patient. The most common location of primary solid malignancy associated with NHL is the gastrointestinal tract (esophagus to rectum), followed by the prostate, lung, and breast.⁶ The synchronous association of solid tumors of ovary with hematological malignancy is one of the rarest forms of MPMs. In our case, diagnosis of DLBCL was made initially, while there was suspicion of second malignancy due positive ascitic fluid cytology for malignancy and borderline surface epithelium malignancy on tru-cut biopsy from adnexal mass. Diagnosis of serous carcinoma of the ovary was confirmed after cytoreductive surgery and final histopathology of surgical specimen. Finally, ovarian serous carcinoma was treated sequentially within 6 months of primary diagnosis of DLBCL.

The pathogenesis of synchronous MPM is not well understood. There are several theories, such as different types of tumors arising from the same precancerous lesion, genetic instability, or a defect in the mismatch repair system.⁷ It has been proposed that lymphomas may cause lymphatic channels to be obliterated, allowing synchronous solid neoplasms to grow.

A rare occurrence of synchronous malignancy can bring distinct diagnostic and treatment issues. Diagnosis of synchronous MPMs can be difficult and challenging. It is unrealistic to get a biopsy for every metastatic lesion, but re-biopsy should be considered for any atypical and uncommon metastatic lesion with keeping in mind the biological behavior of primary malignancy. As in our case, bone and muscle infiltrates were not typical finding for carcinoma ovary. Therefore, the decision to do a repeat biopsy from these muscle infiltrates with lytic

bony lesion was made to look for another malignancy, which subsequently revealed DLBCL.

It is very challenging to choose the best treatment plan when a patient has two different types of cancer. Each type of cancer may need different modalities of treatment. Additionally, treatment of one type of cancer may make the other type worse, so selecting a treatment strategy requires considerable thought. For synchronous lymphoma and ovarian cancer, there is no established treatment plan. Utilizing tumor board discussions, treatment was prioritized and tailored to the patient based on the tumor's aggressiveness and likelihood of responding to primary therapy, ensuring a multidisciplinary team approach. A high level of aggressiveness was present in both the primary (DLBCL and serous carcinoma), which added to the poor prognosis. Because of its aggressive behavior and confirmed diagnosis, lymphoma DLBCL type was treated first with chemotherapy regimen R-CHOP. This regimen includes cyclophosphamide and Adriamycin (doxorubicin) which is also part of CAP (cyclophosphamide, Adriamycin, and platinum) regimen, previously utilized in advanced untreated ovarian cancer.⁸ This cyclophosphamide-containing regimen was also beneficial for response in ovarian cancer when treating hematological malignancy first, which worked as a neoadjuvant for solid ovarian malignancy.

Our success in treating this dual malignancy is proof that multidisciplinary teams can work together effectively to produce positive result. Due to the complexity of this condition and the scarcity of reported cases, research and clinical studies are essential to further understand its underlying mechanisms, optimal diagnostic approaches, and treatment options.

Conclusion

Synchronous solid and hematological malignancy is a rare entity. We should have a high index of suspicion when dealing with such complex situations. We should also consider performing another biopsy if clinical and radiological findings are not typical for primary malignancy. Appropriate selection of chemotherapy regimen that could be useful in both malignancies is necessary as in our case selection of regimen containing cyclophosphamide and Adriamycin. Multidisciplinary coordination and expertise are problem-solving tools.

Patient Consent

During file release, general consent of the file includes that the biological content of the patient could be part of the research. Nondisclosure of a patient's identity, either in the form of name or photograph.

Funding

None.

Conflict of Interest

None declared.

Acknowledgments

We would like to express our deepest gratitude to the medical oncologists who have contributed to managing this case.

References

- 1 Al-Gahmi A, Alhuthali M, Alrehaili M, Baltow B, Tashkandi E. Unusual synchronous association of solid tumors with hematological malignancies in multiple primary cancers: case series and literature review. *Case Rep Oncol* 2021;14(01):352–364
- 2 Cunliffe WJ, Hasleton PS, F Tweedle DE, Schofield PF. Incidence of Synchronous And metachronous carcinoma. *Br J Surg* 1984 Dec; 71(12):941–3. Doi: 10.1002/bjs.18007112101984 vol 71
- 3 Bagri PK, Singh D, Singhal MK, Singh G, Mathur G, Jakhar SL, Beniwal S, Sharma N, Kumar HS, Sharma A, Bardia MR. Double Primary Malignancies: A Clinical & Pathological Analysis Report from a Regional Cancer Institute in India. *Iran J Cancer Prev* 2014 Spring;7(02):66–72. PMID: 25250152; PMCID: PMC4142942
- 4 Yagi Y, Kanemasa Y, Sasaki Y, et al. Synchronous multiple primary tumors in patients with malignant lymphoma: a retrospective study. *BMC Cancer* 2022;22(01):640
- 5 Ismail MM, Abdullatif NA, Al Nagdy N, Al AF. Double Hematological and Solid Malignancy Diagnosed from Bone Marrow Studies: Case Report, Laboratory View. *Journal of Umm Al-Qura University for Medical Sciences* 6(01):2020:4–7
- 6 Parra-Medina R, Rocha F, Castañeda-González JP, Moreno-Lucero P, Veloza L, Romero-Rojas AE. Synchronous or collision solid neoplasms and lymphomas: a systematic review of 308 case reports. *Medicine (Baltimore)* 2022;101(28):e28988
- 7 Cui Y, Liu T, Zhou Y, et al. Five cases report of solid tumor synchronously with hematologic malignancy. *Cancer Res Treat* 2012;44(01):63–68
- 8 Meerpohl HG, Pfeleiderer A, K leine, et al. Chemotherapy for stage III-IV Ovarian Cancer: The CAP- Regimen in previously Untreated Patients. *Onkologie* 1982;5(05):238–241