Article published online: 2024-03-21

Anaplastic Thyroid Carcinoma versus Metastatic SCC: A Diagnostic Dilemma in a Rare Presentation of Post-Radiation Thyroid Swelling

Vrushab Rao[1] Bhooshan Zade[1]

[1] Department of Radiation Oncology, Ruby hall Clinic, Pune, Maharashtra, India

Ind J Med Paediatr Oncol

Address for correspondence Vrushab Rao, MBBS, Junior Resident, 40, Sassoon Road, Pune - 411001, Maharashtra, India (e-mail: raovrushab@gmail.com).

Abstract

A 71-year-old male with type 2 diabetes and hypertension was diagnosed with carcinoma of the pyriform fossa in 2019. The biopsy was reported as a moderately differentiated squamous cell carcinoma, and positron emission tomography-computed tomography (PET-CT) scan showed an fluorodeoxyglucose (FDG)-avid lesion in the pyriform fossa and the aryepiglottic fold with few nodes in level II and level III. The paitent was treated with radical chemoradiotherapy. A follow-up PET-CT scan done in 2022 revealed an FDG-avid soft tissue thickening in the left palatine tonsillar region and an uptake in the thyroid that was reported as not significant. A punch biopsy from the tonsillar fossa lesion revealed squamous cell carcinoma. The lesion was treated as a second primary and treated with radiotherapy with curative intent. The patient was complaining of dysphagia, difficulty in breathing, and weight loss around 6 months after treatment that were addressed medically. There was a significant reduction in size and FDG activity of the ill-defined thickening in the left tonsillar region which was seen in the response-assessment PET done 6 months after RT. A heterogeneously enhancing nodules were seen in both lobes of the thyroid in which the largest one measured 3.5 × 3.1 cm seen in the right lobe. The patient underwent a biopsy from the thyroid that revealed a benign thyroid gland infiltrated by clusters and nests of poorly differentiated malignant cells. The histomorphology was suggestive of a poorly differentiated carcinoma, likely anaplastic carcinoma thyroid, or metastasis of the squamous cell carcinoma. Curative treatment was ruled out in this case due to his comorbidities, pulmonary symptoms, and radiation delivered to the neck.

Keywords
- anaplastic thyroid carcinoma
- medical oncology
- metastatic squamous cell carcinoma
- nuclear medicine
- pathology
- radiation oncology

Case Report

A 71-year-old male with type 2 diabetes and hypertension was diagnosed with carcinoma of the pyriform fossa in 2019. The biopsy reported a moderately differentiated squamous cell carcinoma (SCC), and positron emission tomography-computed tomography (PET-CT) scan showed a lesion in the pyriform fossa and the aryepiglottic fold with few nodes in level II and level III. No other sites showed any pathological uptake. He received concurrent chemoradiotherapy in 2019 with 6 cycles of weekly cisplatin and 33 fractions of radiation. PET-CT scan done in 2021 showed complete response. A follow-up PET-CT scan done in 2022 revealed an fluorodeoxyglucose (FDG)-avid soft tissue thickening in the left palatine tonsillar region and an uptake in the thyroid that was reported as not significant. A punch biopsy from the tonsillar

DOI https://doi.org/10.1055/s-0043-1778109.
ISSN 0971-5851.

© 2024. The Author(s).
This is an open access article published by Thieme under the terms of the Creative Commons Attribution License, permitting unrestricted use, distribution, and reproduction so long as the original work is properly cited. (https://creativecommons.org/licenses/by/4.0/)
Thieme Medical and Scientific Publishers Pvt. Ltd., A-12, 2nd Floor, Sector 2, Noida-201301 UP, India

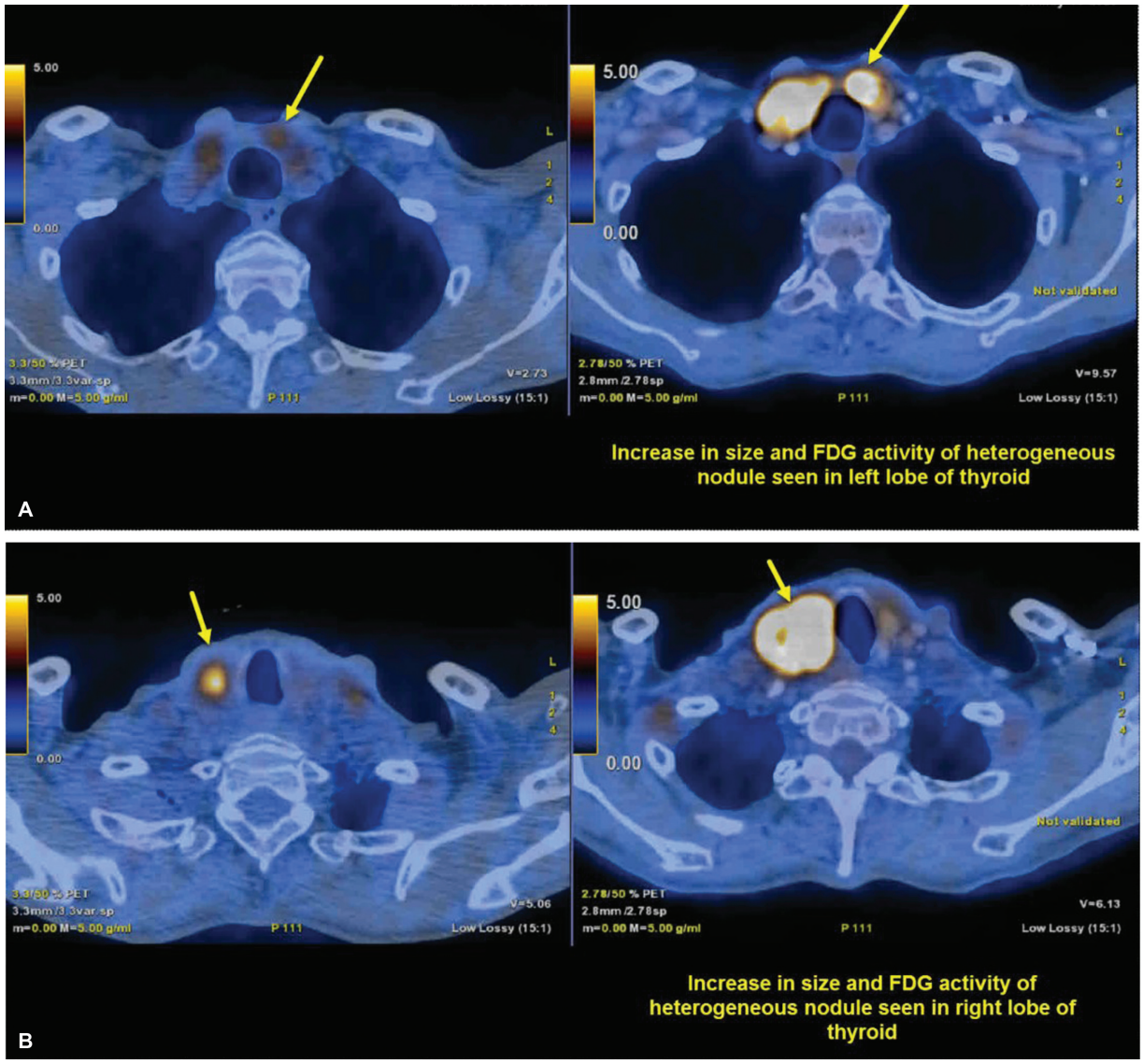

Fig. 1 FDG-avid (SUV max. 15.5) heterogeneously enhancing nodules were seen in both lobes of the thyroid.

fossa lesion revealed SCC. The case was discussed in a multidisciplinary tumor board at our institution. The lesion was concluded to be a second primary and was treated with curative radiotherapy only. He received 66 Gy in 30 fractions. A response assessment PET-CT scan was done 6 months after the completion of radiation. The patient complained of dyshphagia, dyspnea, and weight loss that were addressed medically. There was a significant reduction in the ill-defined thickening in the left tonsillar region. However, FDG-avid (standardized uptake value [SUV] max. 15.5) heterogeneously enhancing nodules were seen in both lobes of the thyroid, the largest being 3.5 × 3.1 cm in the right lobe. The lesion appears to abut the right common carotid artery with the loss of the intervening fat plane and appeared to cause mass effect on trachea. (►**Fig. 1A** and **B**).

The patient underwent a biopsy from the thyroid that revealed a benign thyroid gland infiltrated by clusters and nests of poorly differentiated malignant cells. The histomorphology suggested a poorly differentiated carcinoma, likely anaplastic carcinoma thyroid or metastasis of the SCC. Immunohistochemistry (IHC) was done and the tumor cells expressed P40 (diffuse). The cells were immunonegative for TTF1 and PAX8. PAX8 is positive in only half of the anaplastic thyroid carcinoma. PAX 8 negativity does not rule out primary thyroid carcinoma. However, considering the history of SCC, metastatic SCC is favored over primary anaplastic carcinoma.(►**Fig. 2A**—10X; ►**Fig. 2B**—20X).

Curative treatment was ruled out due to his comorbidities, pulmonary symptoms, and radiation received. The patient was subsequently taken up for tracheostomy followed by palliative care.

Discussion

Anaplastic carcinoma of the thyroid is a rare entity. It accounts for 2 to 3% of all thyroid neoplasms and is associated with a poor prognosis.[1] Most of the thyroid malignancies caused by radiation are papillary thyroid

 © 2024. The Author(s).

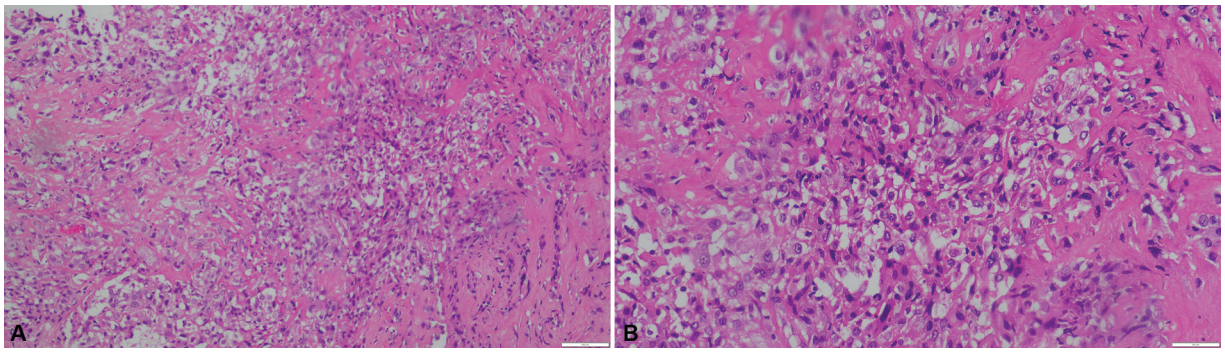

Fig. 2 The patient underwent a biopsy from the thyroid that revealed a benign thyroid gland infiltrated by clusters and nests of poorly differentiated malignant cells. Individual cells are ovoid with moderate clear cytoplasm and high N:C ratio. Areas of necrosis are seen.

cancers. ATC - Anaplastic Thyroid Cancer post head and neck irradiation has limited reporting in the past, mostly in postmortem cases.[2] A diagnostic dilemma, as was in the case of our patient, may occur as SCC with keratinization and/or intercellular bridges is a defining cytological feature of anaplastic thyroid carcinoma that is a characteristic feature of SCC as well. Squamous cells are found in 21% of all ATCs.[3] Cytokeratin and p53 are tumor markers in both ATC and squamous cell head and neck cancers.[3,4] Tumor-specific IHC markers such as PAX8 polyclonal, TTF-1, and thyroglobulin must be included routinely in doubtful cases where treatment in the curative setting is an option. The treatment for ATC and SCC in the recurrent/relapse setting is either surgery or radiotherapy.[5,6] Chemotherapy is seldom useful.

A significant number of ATC cases are reported to have programmed death-ligand 1 (PD-L1) immunopositivity. PD-L1 positivity can be found anywhere between 22 and 94% of the cases, depending on the detection techniques and cutoff levels employed.[7] However, a meta-analysis by Girolami et al was unable to show any association between ATC PD-L1 immunoexpression and survival.[8] BRAF V600E has been reported to have a high incidence in squamous cell cancers of the head and neck in India.[9] Dabrafenib and trametinib have been found to significantly improve the overall survival of anaplastic thyroid carcinoma patients, as well as in head and neck SCC.[10,11] Patients, though, can be offered the option of immunotherapy or targeted therapy when all other lines of management have failed or cannot be offered.

The thyroid uptake was reported as not significant which led to it not being investigated. Retrospectively, however, we believe that any suspicious nodule in the thyroid in patients receiving head and neck radiation must be investigated further. Patients who have received curative doses of radiotherapy must be monitored closely to rule out field cancerization as well as new primary malignant lesions. This would help make the intent of many such cases from palliative to curative if detected on time.

Palliative care includes airway management, nutrition optimization, and pain management, while alleviating other symptoms.[12]

Declaration of Patient Consent

The authors certify that they have obtained all appropriate patient consent forms.

Financial Support

None

The manuscript has been read and approved by all the authors, that the requirements for authorship have been met, and that each author believes that the manuscript represents honest work, if that information is not provided in another form.

Criteria for inclusion of authors—Case management, data collection, proofreading the content.

Data Sharing Statement

All data generated and analyzed during this study are included in this published article. Research data are stored in an institutional repository and will be shared upon request to the corresponding author.

Funding

None.

Conflict of Interest

None declared.

References

1 Limaiem F, Kashyap S, Naing PT, Giwa AO. Anaplastic Thyroid Cancer. 2023. In: StatPearls [Internet]. Treasure Island (FL): StatPearls Publishing; 2023
2 Gétaz EP, Shimaoka K, Rao U. Anaplastic carcinoma of the thyroid following external irradiation. Cancer 1979;43(06):2248–2253
3 Xu B, Fuchs T, Dogan S, et al. Dissecting anaplastic thyroid carcinoma: a comprehensive clinical, histologic, immunophenotypic, and molecular study of 360 cases. Thyroid 2020;30(10):1505–1517
4 Basheeth N, Patil N. Biomarkers in head and neck cancer an update. Indian J Otolaryngol Head Neck Surg 2019;71 (Suppl 1):1002–1011
5 Park JW, Choi SH, Yoon HI, et al. Treatment outcomes of radiotherapy for anaplastic thyroid cancer. Radiat Oncol J 2018;36(02): 103–113
6 Yeh SA. Radiotherapy for head and neck cancer. Semin Plast Surg 2010;24(02):127–136

 © 2024. The Author(s).

7 Xu B, Zhang L, Setoodeh R, et al. Prolonged survival of anaplastic thyroid carcinoma is associated with resectability, low tumor-infiltrating neutrophils/myeloid-derived suppressor cells, and low peripheral neutrophil-to-lymphocyte ratio. Endocrine 2022;76(03):612–619
8 Girolami I, Pantanowitz L, Mete O, et al. Programmed death-ligand 1 (PD-L1) is a potential biomarker of disease-free survival in papillary thyroid carcinoma: a systematic review and meta-analysis of PD-L1 immunoexpression in follicular epithelial derived thyroid carcinoma. Endocr Pathol 2020;31(03):291–300
9 Gauthaman A, Moorthy A. High incidence of BRAF V600 mutation in Indian patients with head and neck cancer. Front Biosci (Elite Ed) 2018;10(03):520–527
10 Chang CF, Yang MH, Lee JH, et al. The impact of BRAF targeting agents in advanced anaplastic thyroid cancer: a multi-institutional retrospective study in Taiwan. Am J Cancer Res 2022;12 (11):5342–5350
11 Uppaluri R, Winkler AE, Lin T, et al. Biomarker and tumor responses of oral cavity squamous cell carcinoma to trametinib: a phase ii neoadjuvant window-of-opportunity clinical trial. Clin Cancer Res 2017;23(09):2186–2194
12 Goyal A, Gupta R, Mehmood S, Deo S, Mishra S, Bhatnagar S. Palliative and end of life care issues of carcinoma thyroid patient. Indian J Palliat Care 2012;18(02):134–137

 © 2024. The Author(s).