Article published online: 2024-01-30



# Total Splenectomy for Splenic Abscess in Pediatric Oncology: A Report of Two Cases

Ramitha R. Bhat[1] Vasudeva Bhat K[1] Vinay Munikoty Venkatesh[1] Archana Melavarige Venkatagiri[1] Shreya Joshi[1] Vijay Kumar[2] Santosh P Prabhu[2] Vishwapriya Godkhindi[3] Atul Thobbi[1] Chandana Pai[1]

[1] Division of Pediatric Hematology and Oncology, Manipal Comprehensive Cancer Care centre, Kasturba Medical College, Manipal, Manipal Academy of Higher Education, Karnataka, India
[2] Department of Pediatric Surgery, Kasturba Medical College, Manipal, Manipal Academy of Higher Education, Karnataka, India
[3] Department of Pathology, Kasturba Medical College, Manipal, Manipal Academy of Higher Education, Karnataka, India

**Address for correspondence** Vasudeva Bhat K, MD, DM, Division of Pediatric Hematology and Oncology, Manipal Comprehensive Cancer Care Centre, Kasturba Medical College, Manipal, Manipal Academy of Higher Education, Karnataka, India (e-mail: vasudev.bhat@manipal.edu).

Ind J Med Paediatr Oncol

## Abstract

Splenic abscess is a relatively uncommon condition, especially in pediatric malignancies. The diagnosis of a splenic abscess is a clinical challenge due to low incidence. The condition is fatal if not diagnosed on time. We are reporting two cases with underlying immune suppression secondary to malignancy and multidrug-resistant sepsis with splenic abscesses as the focus. Both children had life-threatening sepsis and required total splenectomy as a life-saving measure. Postsplenectomy course was uneventful with clinical improvement, and chemotherapy was continued. High suspicion is necessary due to nonspecific presentation. The treatment of splenic abscess includes conservative management and percutaneous drainage. Splenectomy is generally not indicated; however, total splenectomy may be required in the setting of multiple splenic abscesses, also to prevent overwhelming infection in an immunocompromised setting.

**Keywords**
- splenic abscess
- pediatric oncology
- Klebsiella
- splenectomy

## Introduction

Splenic abscess is an uncommon but life-threatening condition, especially in a pediatric oncology setting. Diagnosis is a challenge due to its nonspecific clinical picture.[1] The incidence of splenic abscess in children ranges from 0.05 to 0.7%.[2] Most cases of splenic abscess in children occur secondary to immunosuppression. The diagnosis can be made using imaging techniques such as computerized tomography (CT) and ultrasound (USG). Although broad-spectrum antibiotics for adequate duration and/or percutaneous drainage for treatment are sufficient in most cases, multifocal lesions necessitate splenectomy.[3] We are reporting two cases of multidrug-resistant Klebsiella splenic abscess in children with cancer where splenectomy was performed as a life-saving measure.

## Case Report

### Case 1

A 12-year-old girl diagnosed with early combined medullary and central nervous system relapse of precursor- B cell acute lymphoblastic leukemia was undergoing salvage chemotherapy as per the UKALL-R3 protocol.[4] She was planned for consolidation with an allogeneic hematopoietic stem cell transplant with a matched sibling donor.[5]

On day 13 of salvage induction chemotherapy, she developed a fever associated with signs of septic shock. She was managed with intravenous (IV) antibiotics (meropenem and amikacin) and also required inotropic support. Blood culture collected prior to the initiation of IV antibiotics showed growth of Klebsiella pneumonia which was

**DOI** https://doi.org/10.1055/s-0044-1779048.
**ISSN** 0971-5851.

© 2024. The Author(s).
This is an open access article published by Thieme under the terms of the Creative Commons Attribution License, permitting unrestricted use, distribution, and reproduction so long as the original work is properly cited. (https://creativecommons.org/licenses/by/4.0/)
Thieme Medical and Scientific Publishers Pvt. Ltd., A-12, 2nd Floor, Sector 2, Noida-201301 UP, India

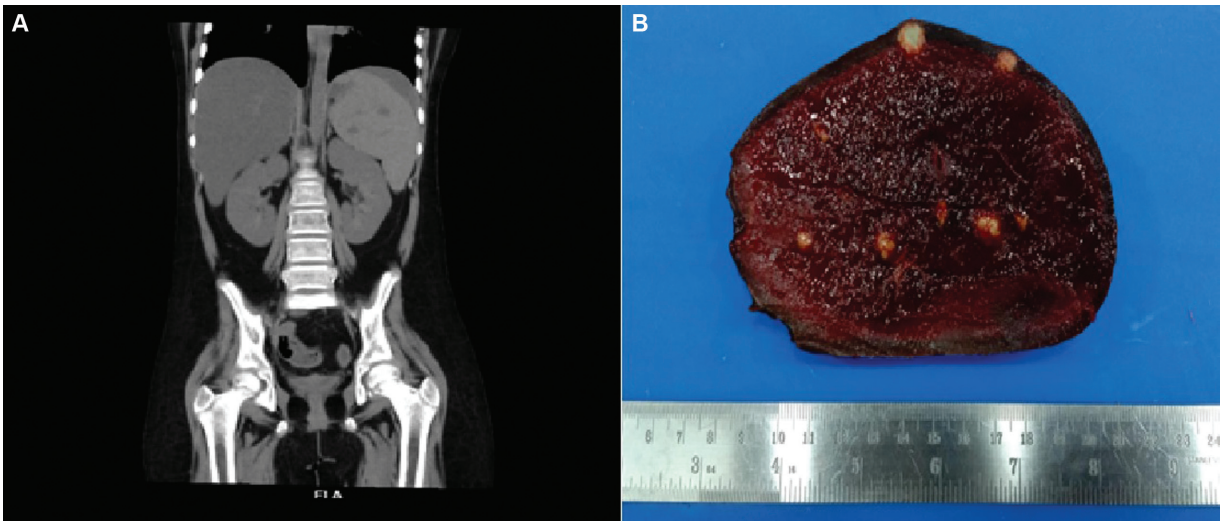


**Fig. 1** (**A** and **B**) CT image of the abdomen in coronal view showing intraparenchymal hypodensities of varying sizes in the spleen and cut section of the spleen specimen showing multiple soft greyish-white nodules suggestive of abscesses.

resistant to all antibiotics including reserved drugs like colistin and Fosfomycin. As per the antibiotic policy of the unit, her antibiotics were escalated to injection (Inj.) aztreonam and Inj. ceftazidime avibactam. Inotropic support and stress doses of steroids were given along with other supportive care measures like blood and blood products. Expecting prolonged postchemotherapy neutropenia and extensively drug-resistant klebsiella sepsis, granulocyte infusions were given on alternate days to combat infection. She subsequently became afebrile and subsequent blood cultures were sterile.

On day 29 of intensive phase chemotherapy, she developed abdominal pain associated with fever. Blood culture showed extensively drug-resistant (XDR) Klebsiella growth. Opinion from infectious disease department was taken, and she was restarted on Inj. aztreonam, Inj. ceftazidime avibactam and Inj polymyxin were added. USG abdomen showed splenomegaly with multiple scattered hypoechoic tiny nodules. With a high suspicion of fungal infection in an immunocompromised child, antifungal (amphotericin B) was added. However, no improvement in symptoms was noted and blood culture again showed growth for Klebsiella pneumonia with similar antibiotic sensitivity. CT abdomen confirmed splenomegaly with multiple intraparenchymal hypodensities of varying size (►**Fig. 1A**). With splenic foci as likely source for Klebsiella, emergency splenectomy was planned for the removal of source of infection.

Postsplenectomy, her fever spikes subsided and blood cultures came sterile. Pus culture sent from splenic tissue showed growth of Klebsiella with the same sensitivity. She was continued on chemotherapy and was planned for matched sibling donor allogenic stem cell transplant with total body irradiation (TBI)-based conditioning.

### Case 2

A 6-year-old girl with Stage IV Burkitt's lymphoma on inter-B NHL protocol (chemotherapy + rituximab)[6] presented with complaints of high-grade fever spikes and septic shock post-second maintenance phase of chemotherapy. She was started on infusion carbapenem and colistin as per unit protocol; however, blood culture revealed Klebsiella species resistant to all antibiotics including reserved drugs like colistin and fosfomycin. Her antibiotics were escalated to IV ceftazidime avibactam and aztreonam. Fever persisted despite giving reserved antibiotics and started developing abdominal pain in left flank. CT abdomen revealed splenic abscesses, and hence, an emergency splenectomy was performed for source control (►**Fig. 2A**).

Postsplenectomy, child had an uneventful course with clinical improvement and subsequent blood cultures became sterile. Pus swab from excised spleen showed the same growth and sensitivity pattern. She was continued on chemotherapy. Currently, she has finished treatment and is on follow-up for 9 months and doing well.

Approval from the ethical committee was taken. Written informed consent was obtained from the parents for the publication. The specimen of spleen on cut section in both cases revealed multiple soft greyish-white nodules suggestive of abscesses as shown in the image (►**Figs. 1B** and **2B**). Microscopy confirmed multiple abscess cavity with necro-inflammatory debris. Periodic acid–Schiff stain did not highlight any fungal elements.

## Discussion

Splenic abscess is defined as an infectious suppurative process associated with macroscopic filling defect either in the parenchyma of the spleen or the subcapsular space.[7] Splenic abscess is a rare life-threatening disease in children usually seen in immunocompromised patients due to the phagocytic immune functions of the spleen.[8] Common predisposing factors in the literature include leukemia, malnutrition, sickle cell anemia, infection, and immunosuppression.[9]

 © 2024. The Author(s).

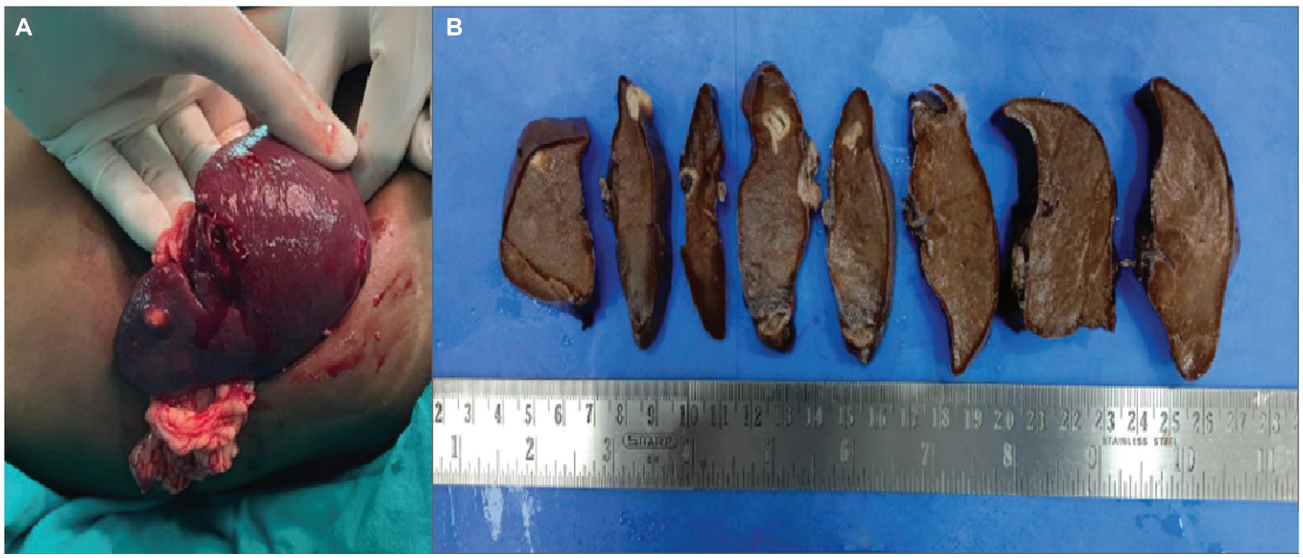


**Fig. 2** (**A** and **B**) Intraoperative finding of spleen near the lower pole and cut section of the spleen specimen showing multiple soft greyish-white nodules surrounded by congested splenic parenchyma largest measuring 1.8 × 1.5cm suggestive of abscesses.

Splenic abscesses can be bacterial, fungal, or granulomatous.[10] Most common organisms isolated from splenic abscesses include *Staphylococcus*, *Streptococcus*, *Salmonella*, and *E. coli*. As per the literature, gram-negative organisms are more common than gram positive.[11]

Diagnosis can be delayed in children due to nonspecific symptoms, especially in immunocompromised conditions. In most cases of febrile neutropenia, detectable foci of infection cannot be identified and usually there are no localizing symptoms.[12] However, fever, left quadrant pain, and leucocytosis, which form the triad of splenic abscess,[13] leucocytosis may be absent in immunocompromised patients.[3] In our patients, fever and positive blood culture could have masked the diagnosis of splenic abscess. Persistent fever not responding to appropriate antibiotics and persistent culture positivity led us to look for deeper sites of infection. A high index of suspicion is needed for timely diagnosis. One should look and relook for other sources of infection in such conditions.

Broad-spectrum antibiotics for adequate duration is the treatment of choice in immunocompetent children.[14] For larger abscesses, antibiotics alone may not be sufficient, and drainage may be required in addition.[3] Percutaneous drainage is possible in unilocular or bilocular collections. Multilocular abscesses, ill-defined cavities, septations, and necrotic debris are unlikely to respond to percutaneous drainage.[15]

Bacterial and fungal infections are major clinical challenges in patients with prolonged severe neutropenia secondary to intensive chemotherapy. Functional white blood cells are essential to combat infection. In a leukemic child, there is neutropenia and/or neutrophil dysfunction. The role of granulocyte transfusions in neutropenic patients with infection is very well known. In case 1, due to persistent neutropenia and extensive drug-resistant organisms in blood culture, granulocytes were transfused on an alternate day basis from day 3 after first positive culture until neutrophil count recovery. A median dose of granulocyte was $2.1 \times 10^{10}$/bag (range:1.12 $- 3.4 \times 10^{10}$). A total of three units of granulocytes were transfused. No granulocyte infusion was done in case 2.

Fungal splenic abscess is a very well-known complication during therapy in hematolymphoid malignancies.[16,17] However, case reports on bacterial splenic abscess are very few.[3,7,12] Chiang et al reported 29 cases of splenic abscess, 5 of which were pediatric patients. Fungal splenic abscess was noted in 28% cases, compared to bacterial abscesses which were 19%. The success rate of 75% with antibiotics alone was documented in the study; however, the abscess was solitary in 21 cases (72%).[7] In our cases, as the abscess was multilocular and failed to respond to IV antibiotics, splenectomy was required.

Splenectomy plays a critical therapeutic role as a definitive treatment for abscesses of the spleen.[18] The procedure is generally avoided due to the important immunological functions of the spleen.[19] Partial splenectomy can be done if the abscess is in the lower pole. In the immunocompromised child when multiple abscess is present, total splenectomy is required to prevent overwhelming infection and recurrence. The role of splenectomy in splenic abscess in immunocompromised children has been discussed in the literature. Ferraioli et al discussed a series of 16 cases of splenic abscess where two patients with leukemia required splenectomy as response to IV antibiotics was poor.[20] Another case report by Olcay et al showed successful management of splenic abscess with splenectomy in a 14-year-old boy with acute myeloid leukemia.[12] Management of splenic abscess in immunocompromised children was discussed by Smith et al who opined that splenectomy should be the choice for the treatment of splenic abscess in immunocompromised children and in patients with multiple splenic abscesses due to difficulty in eradicating the infection from the reticuloendothelial cells of the spleen, which are not well penetrated by systemic antibiotics.[21] Ng et al also

 © 2024. The Author(s).

suggested splenectomy for multiple abscesses as the safe and effective treatment choice.[22] Dissemination to other organs including the brain and kidneys is a known risk and sometimes progresses to chronic discharging sinuses into a hollow organ with high mortality rate.[3] In our patients, repeated culture growing drug resistant gram-negative sepsis not responding to any antibiotics, worsening clinical condition and plan for future TBI as a pre-HSCT conditioning in case 1, splenectomy was considered before deciding to go for total splenectomy for removal of infective source and as a life-saving measure. In both cases, the postsplenectomy significant improvement in the clinical condition with the clearance of XDR infection was noted and chemotherapy could be continued. With timely intervention, the risk of rupture and dissemination leading to mortality was prevented. Delay in chemotherapy administration is known to cause high risk of relapse. In our cases, we were able to prevent further delay in chemotherapy due to infection, and remission was achieved.

Overwhelming postsplenectomy infection secondary to splenectomy is a well-known complication in splenectomized patients. Both our patients were on intensive chemotherapy, and splenectomy was performed on an emergent indication; hence, presplenectomy vaccination was not done. Postsplenectomy, penicillin prophylaxis was continued in both cases, and in case 2, after 1 year of completion of chemotherapy (+ Rituximab), vaccination including capsulated organisms was given and since then the child has been doing well.

Primary splenic abscess is a rare manifestation in children with cancer. A high index of suspicion coupled with timely diagnosis will lead to choosing the best modality of therapy. Wait and watch policy in an immunocompetent individual may not be suitable.

### Declaration by Authors

The manuscript has been read and approved by all the authors, the requirements for authorship have been met, and the manuscript represents honest work.

V.B.K. and V.M.V. conceived of the presented idea. R.R.B. and S.J. collected the case details and did the literature search. A.M.V., V.K., S.P., and V.G. contributed to the manuscript design and figures. All authors discussed the results and contributed to the final manuscript.

### Declaration of the Patient Consent

The authors certify that they have obtained all appropriate patient consent forms.

### Funding

None.

### Conflict of Interest

None declared.

### Acknowledgment

None

## References

1 Sreekar H, Saraf V, Pangi AC, Sreeharsha H, Reddy R, Kamat G. A retrospective study of 75 cases of splenic abscess. Indian J Surg 2011;73(06):398–402
2 Faruque AV, Qazi SH, Arshad M, Anwar N. Isolated splenic abscess in children, role of splenic preservation. Pediatr Surg Int 2013;29 (08):787–790
3 Abiola A, Hassan S, Ameh EA. Primary splenic abscess in children. J Pediatr Surg Case Rep 2020;60:101552
4 Parker C, Waters R, Leighton C, et al. Effect of mitoxantrone on outcome of children with first relapse of acute lymphoblastic leukaemia (ALL R3): an open-label randomised trial. Lancet 2010; 376(9757):2009–2017
5 Hunger SP, Raetz EA. How I treat relapsed acute lymphoblastic leukemia in the pediatric population. Blood 2020;136(16): 1803–1812
6 Minard-Colin V, Aupérin A, Pillon M, et al; European Intergroup for Childhood Non-Hodgkin Lymphoma. ; Children's Oncology Group. Rituximab for high-risk, mature B-cell non-Hodgkin's lymphoma in children. N Engl J Med 2020;382(23):2207–2219
7 Chiang IS, Lin TJ, Chiang IC, Tsai MS. Splenic abscesses: review of 29 cases. Kaohsiung J Med Sci 2003;19(10):510–515
8 Gupta S, Singh O, Hastir A, Shukla S, Mathur RK. Splenic abscesses: reports of two cases with review of the literature. Ann Trop Med Public Health 2012;5(03):273
9 Rattan KN, Kadian YS, Saroha V, Jindal N. Splenic abscess in children: a report of three patients. Afr J Paediatr Surg 2009;6 (02):106–109
10 Ooi LL, Leong SS. Splenic abscesses from 1987 to 1995. Am J Surg 1997;174(01):87–93
11 Lee MC, Lee CM. Splenic abscess: an uncommon entity with potentially lifethreatening evolution. Can J Infect Dis Med Microbiol 2018;2018:8610657
12 Olcay L, Dingil G, Yildirim E, Dilek G, Dirim E. Splenic abscesses in therapy-resistant acute myeloblastic leukemia presenting as recurrent febrile neutropenia and unresolved splenomegaly. Turk J Pediatr 2007;49(03):315–318
13 Choudhury SR, Debnath PR, Jain P, et al. Conservative management of isolated splenic abscess in children. J Pediatr Surg 2010; 45(02):372–375
14 Aroor S, Kanaparthi S, Mundkur SC, Shashidhara S, Konda KC. Splenic abscess: conservative management in children. SAJCH 2019;13(01):49–50
15 Lotfollahzadeh S, Mathew G, Zemaitis MR. Splenic abscess. In: StatPearls. Treasure Island (FL): StatPearls Publishing; 2021
16 Marmon LM, Vinocur CD, Wimmer RS, et al. Fungal splenic abscesses: management in childhood leukemia. Pediatr Surg Int 1990;5:118–120
17 Grois N, Mostbeck G, Scherrer R, et al. Hepatic and splenic abscesses—a common complication of intensive chemotherapy of acute myeloid leukemia (AML). A prospective study. Ann Hematol 1991;63(01):33–38
18 Chun CH, Raff MJ, Contreras L, et al. Splenic abscess. Medicine (Baltimore) 1980;59(01):50–65
19 Keidl CM, Chusid MJ. Splenic abscesses in childhood. Pediatr Infect Dis J 1989;8(06):368–373
20 Ferraioli G, Brunetti E, Gulizia R, Mariani G, Marone P, Filice C. Management of splenic abscess: report on 16 cases from a single center. Int J Infect Dis 2009;13(04):524–530
21 Smith MD Jr, Nio M, Camel JE, Sato JK, Atkinson JB. Management of splenic abscess in immunocompromised children. J Pediatr Surg 1993;28(06):823–826
22 Ng KK, Lee TY, Wan YL, et al. Splenic abscess: diagnosis and management. Hepatogastroenterology 2002;49(44):567–571

 © 2024. The Author(s).