



Quantitative Measurement and Analysis of the Radial Peripapillary and Central Macular Microvasculature Density in Early Open-Angle Glaucoma Using OCT Angiography

Majdi Abdulhamid Abdala¹ Suliman Mohamed Masoud¹ Nadia Abdelsalam Geilani²

¹ Department of Ophthalmology, Faculty of Medicine, University of Benghazi, Benghazi, Libya

² Department of Ophthalmology, Benghazi Eye Hospital, Benghazi, Libya

Address for correspondence Majdi Abdulhamid Abdala, MD, MRCS, FICO, Department of Ophthalmology, Faculty of Medicine, University of Benghazi, Benghazi, Libya (e-mail: majdi.abdala@uob.edu.ly).

Libyan Int Medical Univ J

Abstract

Background Glaucoma is a prevalent cause of visual impairment, and early detection is critical to prevent progressive vision loss. Optical coherence tomography angiography (OCT-A) enables visualization of retinal and optic nerve microvasculature and holds promise for early glaucoma detection.

Aims This study aims to assess microvasculature density alterations in glaucoma using OCT-A.

Methods An observational cross-sectional case-control study was conducted at Benghazi Eye Hospital in Libya from December 2022 to August 2023. It included 160 eyes of 126 patients diagnosed with primary open-angle glaucoma and 120 eyes of 96 control subjects. OCT-A was performed using the Swept-Source OCT DRI Triton. Vessel density measurements were obtained from OCT-A images using new built-in software within the device. The data presented as mean \pm standard deviation and percentages were analyzed using SPSS. The statistical significance of the differences between different groups was determined using independent *t*-tests, and the level of significance was set at *p*-value less than 0.05.

Results OCT-A demonstrated significantly reduced microvasculature density in glaucoma eyes across all optic nerve sectors including the inferior (29.0%), superior (25.2%), central (23.5%), nasal (9.9%), and temporal sectors (9.3%; $p < 0.02$). Moreover, glaucoma patients exhibited a significant reduction in vessel density in the superior macula (17% reduction), the temporal (15.7%), nasal (12.9%), and inferior sectors (12.6%) ($p < 0.002$). No statistical difference was seen with vessel density of the central sector (0.49%, $p > 0.05$).

Conclusion OCT-A demonstrated significant reductions in microvasculature density in glaucoma patients compared with healthy controls. These findings support the association between glaucoma and vascular changes. Additionally, the TOPCON Swept-Source OCT DRI Triton new software shows promise as a valuable tool for early detection and monitoring of glaucoma-related vascular changes.

Keywords

- ▶ early detection
- ▶ glaucoma
- ▶ microvasculature density
- ▶ optical coherence tomography angiography
- ▶ TOPCON Swept-Source OCT DRI Triton

DOI <https://doi.org/10.1055/s-0044-1779669>.
ISSN 2519-139X.

© 2024. The Author(s).

This is an open access article published by Thieme under the terms of the Creative Commons Attribution License, permitting unrestricted use, distribution, and reproduction so long as the original work is properly cited. (<https://creativecommons.org/licenses/by/4.0/>)

Thieme Medical and Scientific Publishers Pvt. Ltd., A-12, 2nd Floor, Sector 2, Noida-201301 UP, India

ملخص المقال باللغة العربية

القياس والتحليل الكمي لكثافة الأوعية الدموية الدقيقة الشعاعية والمركزية البقعية في الجلوكوما المبكرة المفتوحة الزاوية باستخدام تصوير الأوعية المقطعية بالتماس البصري

المؤلفون: مجدي عبدالله، سليمان مسعود، نادية جيلاني، قسم العيون، كلية الطب، جامعة بنغازي، بنغازي، ليبيا.

المؤلف المسؤول: مجدي عبدالله، البريد الإلكتروني: majdi.abdala@uob.edu.ly

الخلفية: تعتبر الجلوكوما سبب شائع لضعف البصر، والكشف المبكر عنها أمر بالغ الأهمية لمنع فقدان البصر التدريجي. يمكن تصوير الأوعية المقطعية بالتماس البصري (OCT-A) من رؤية الأوعية الدموية الدقيقة في شبكية العين والعصب البصري وبيشر بالكشف المبكر عن الجلوكوما.

الأهداف: تهدف هذه الدراسة إلى تقييم التغيرات في كثافة الأوعية الدموية الدقيقة في الجلوكوما باستخدام تصوير الأوعية المقطعية بالتماس البصري.

الطرق: أجريت دراسة رصدية مقطعية للحالات والشواهد في مستشفى بنغازي للعيون في ليبيا في الفترة من ديسمبر 2022 إلى أغسطس 2023. وتضمنت 160 عيناً لـ 126 مريضاً تم تشخيص إصابتهم بالجلوكوما الأولية مفتوحة الزاوية، و120 عيناً لـ 96 شخصاً معافين. تم إجراء تصوير الأوعية المقطعية بالتماس البصري باستخدام Swept-Source OCT DRI Triton. تم الحصول على قياسات كثافة الأوعية باستخدام برنامج مدمج جديد داخل جهاز صور الأوعية المقطعية بالتماس البصري. تم تحليل البيانات المقدمة بحساب المتوسط والنسب المئوية باستخدام برنامج SPSS. تم تحديد الأهمية الإحصائية للاختلاف بين المجموعات المختلفة باستخدام اختبار الطالب التام، وتم تحديد مستوى الأهمية عند $P < 0.05$.

النتائج: أظهر تصوير الأوعية المقطعية بالتماس البصري انخفاضاً ملحوظاً في كثافة الأوعية الدموية الدقيقة في عيون الجلوكوما في جميع قطاعات العصب البصري بما في ذلك القطاعات السفلية (29.0٪)، والعلوية (25.2٪)، والوسطى (23.5٪)، والأنتفية (9.9٪) والصدغية (9.3٪) ($P < 0.02$). علاوة على ذلك، أظهر مرضى الجلوكوما انخفاضاً كبيراً في كثافة الأوعية الدموية في البقعة العلوية (انخفاض بنسبة 17٪)، والصدغية (15.7٪)، والأنتفية (12.9٪)، والقطاعات السفلية (12.6٪) ($P < 0.002$). ولم يشاهد أي فرق إحصائي في كثافة الأوعية الدموية للقطاع المركزي (0.49٪، $p > 0.05$).

الاستنتاج: أظهر تصوير الأوعية المقطعية بالتماس البصري انخفاضاً كبيراً في كثافة الأوعية الدموية الدقيقة لدى مرضى الجلوكوما مقارنة بالأصحاء. تدعم هذه النتائج العلاقة بين الجلوكوما والتغيرات الوعائية. بالإضافة إلى ذلك، يظهر برنامج TOPCON Swept-Source OCT DRI Triton الجديد كأداة قيمة وأداة للكشف المبكر عن التغيرات الوعائية المرتبطة بالجلوكوما ومراقبتها.

الكلمات الدالة: الكشف المبكر، الجلوكوما، كثافة الأوعية الدموية الدقيقة، التصوير المقطعي التوافقي البصري، تصوير الأوعية.

Introduction

Glaucoma, a leading cause of blindness, affects millions of people worldwide and its prevalence is anticipated to rise further by the year 2040. Open-angle glaucoma accounts for most of the cases and is marked by retinal ganglion cell (RGC) death, changes to the optic nerve, and visual field loss.^{1,2} Elevated intraocular pressure (IOP) is thought to be the leading risk factor for glaucoma, though some patients experience progressive loss of visual field despite having low IOP levels, which challenges the traditional “mechanical” theory. A vascular theory proposes impaired ocular blood flow and ischemia contributes to optic nerve injury.^{3,4} However, the precise link between microvascular changes and neural tissue loss in glaucoma remains unclear. Early detection and treatment are crucial to prevent vision loss as damage is irreversible.⁵ Optical coherence tomography (OCT), a noninvasive imaging tool, is widely used for diagnosing and tracking glaucoma progression by examining the retinal nerve fiber layer and RGCs layer structure. However, OCT has limited sensitivity for early glaucoma and only moderately correlates with visual field loss.^{6,7} New imaging is needed to study microvasculature changes that may precede structural damage in glaucoma and is required to document blood flow impairment's role.³ Despite fluorescein angiography, indocyanine green angiography, scanning laser ophthalmoscopy, and laser Doppler flowmetry evaluating ocular blood flow changes, their efficacy is limited.⁸⁻¹¹ These technologies have not provided a comprehensive understanding due to the inability to observe microvasculature within specific layers and provide quantitative measurements of vessel density and blood flow.³ Peripapillary vessel density refers to blood vessels surrounding the optic disc, these vessels supply nutrients and oxygen to RGCs damaged in glaucoma, changes in this vessel density may

precede structural damage and visual field loss.¹² The macula contains a high concentration of RGCs and these cells rely on the regional capillaries to meet their high metabolic demands. Glaucoma primarily damages RGCs axons, making the macula ideal for early detection of the disease.¹³ These findings highlight the importance of understanding peripapillary and macular vessel density in glaucoma pathogenesis and the potential of advanced imaging for early diagnosis and monitoring. Recent studies suggest OCT-A as a promising noninvasive imaging modality for early glaucoma detection.¹⁴ OCT-A visualizes retinal blood flow creating high-resolution three-dimensional (3D) images of the microvasculature.¹⁵ It detects changes in peripapillary vessel density, potentially preceding structural damage and visual field loss.¹⁶ OCT-A can reveal vascular abnormalities in early glaucoma detection offers more reliable vessel density measurements than other imaging methods,¹⁷⁻¹⁹ and may be more sensitive than conventional OCT.²⁰⁻²² This study aims to use OCT-A for the evaluation of the peripapillary and central macular vessel density, with a specific emphasis on its utility in early glaucoma detection and its capacity to elucidate the involvement of vascular irregularities in the pathogenesis of the disease.

Methods

This is an observational cross-sectional case-control study that was conducted from December 2022 to August 2023 at the Benghazi Eye Hospital. The study included a total of 126 patients diagnosed with primary open-angle glaucoma (POAG) with 160 eyes included in the study. The study also included 96 control subjects representing a total of 120 eyes. The selection of patients involved a combination of both eyes and single eyes, based on predetermined criteria.

Ethical Principles

Informed consent was obtained from all subjects before being enrolled in this study. The investigator explained to each patient the nature of the study, its purpose, the procedure involved, the expected duration, the potential risks, and any discomfort that may be caused by the study. Each patient was informed that participation is voluntary and that he or she may withdraw from the study at any time and without giving reasons. The withdrawal will not affect the subsequent medical or conservative treatment or relationship with the treating doctor. All procedures conformed to the guidelines of the Declaration of Helsinki and approved by the Ethics Committee in the Benghazi Teaching Ophthalmology Hospital.

Inclusion Criteria

Inclusion criteria for glaucoma and the control groups included best-corrected visual acuity of 6/12 (0.5) or better on the Snellen chart, the refractive error between -3.00 and $+3.00$ diopters. Participants who did not have any media opacities that could affect the quality of OCT images were also included. To be considered as having glaucoma, patients must meet the following diagnostic criteria: display signs of typical glaucomatous optic disc damage like neuroretina rim thinning, optic disc cupping, and have abnormally thin retinal nerve fiber layer, exhibit visual field defects consistent with glaucoma that have been confirmed by at least two visual field tests, have open angles on gonioscopy, and have no history of other ocular or systemic diseases that could cause nonglaucomatous optic nerve damage. This study only included patients with mild stage POAG eyes, as determined by their visual field mean deviation scores ($MD > -6.0$ dB) and according to the Hodapp rating scale Parrish-Anderson of the severity of defects in the visual field test.²³

For the healthy subjects (control group), subjects included were those with IOP less than or equal to 21 mm Hg, with no glaucomatous optic nerve damage or visual field defects, and with no family history of glaucoma.

Exclusion Criteria

Patients with presence of any media opacities that prevented good quality OCT scans, or any retinal or neurological disease other than glaucoma, which may alter vision or visual field, eyes with a history of trauma or inflammation, and patients with ocular retinopathies and all forms of secondary open-angle glaucoma were also excluded.

A complete ophthalmic history and ophthalmological examination were done for each subject which comprised:

- Best corrected visual acuity.
- Anterior segment detailed slit lamp examination (Keeler 25z) and gonioscopy by the triple mirror lens.
- IOP measurement by applanation tonometer (Keeler KAT-T type).
- Posterior segment examination using +90 D Volk lens.

Macular and Peripapillary Vessel Density Analysis by the OCT-A

In this study, OCT-A imaging was performed using Swept-Source OCT DRI Triton (Topcon Corporation, Tokyo,

Japan) with the OCT angiography ratio analysis (OCTARA) algorithm.

The peripapillary and central macular regions were imaged with an acquisition rate of 100,000 A-scans/second and the 3D (3.0×3.0 mm -320×320) scan was performed as Angio scan protocol.

A quantitative assessment of the retinal microvascular flow network was performed using the vessel density measurements obtained from the OCTA images and analyzed by the new software provided by OCT DRI Triton (IMAGENet6 version 1.02.2).²⁴

The vessel density thickness measurement zones in the optic disc were defined as peripapillary Vessels Density (VD) (1—superior, 2—inferior, 3—temporal, 4—nasal) and 5—inside disc VD. However, the macular vessel density thickness measurement zones are defined as parafoveal VD (6—superior, 7—inferior, 8—temporal, 9—nasal) and 10—central foveal avascular zone.

For all macular and optic disc OCT-A scans, the image quality was evaluated. Scans with a signal strength index below 40, a misaligned surface detection algorithm, or a measurement location that was not centered were excluded from the analysis due to poor quality.

Data Analysis

The data were analyzed using SPSS version 23 for Windows software. The results were expressed as mean \pm standard deviation, numbers, and percentages. An independent *t*-test was performed to compare the means of vessel density measurements in the macula and optic disc regions in glaucoma and control groups. A *p*-value less than or equal to 0.05 was considered statistically significant.

Results

The study included 126 patients with POAG (160 eyes) and 96 control subjects (120 eyes) (**Table 1**). The mean age of the glaucoma group was 67.6 ± 5.6 years, and the control group was 66.3 ± 1.4 years. The male/female ratio was 1.46:1 in the control group and 1.42:1 in the glaucoma group. The IOP was 14.2 ± 0.5 mm Hg in the control group and 16.4 ± 1.5 mm Hg in the glaucoma group with a high significant difference between the two groups ($p < 0.001$). The SAP MD was -0.45 ± 1.63 in the control group and -3.42 ± 1.45 in the glaucoma group, showing a highly significant difference between the two groups ($p < 0.001$; **Table 1**).

The microvasculature density values represent the mean percentage of pixels vessels measured with OCT-A (**Fig. 1**). This study showed a significantly lower microvasculature density in the optic nerve area in glaucoma eyes than in normal subject eyes (**Fig. 1**).

In the optic nerve area (**Table 2**), all sectors showed a highly statistically significant lower microvasculature density in eyes with glaucoma compared with controls (inferior sector [28.5%], superior sector [25.2%], central sector [23.5%], nasal sector [9.9%], and the temporal sector [9.3%]; see **Table 2**).

This study also utilized OCT-A to assess vessel density in the central macular region of individuals with glaucoma and

Table 1 Details of demographics and ocular characteristics of the study groups

Variables	Control (120 eyes of 96 subjects)	Glaucoma (160 eyes of 126 patients)	p-Value
Age	66.3 ± 1.4	67.6 ± 5.6	>0.05
Gender (male/female)	57/39	74/52	>0.05
BCVA	0.85 ± 0.17	0.57 ± 0.18	<0.001 ^a
IOP (mm Hg)	14.2 ± 0.5	16.4 ± 1.5	<0.001 ^a
SAP MD	-0.45 ± 1.63	-3.42 ± 1.45	<0.001 ^a

Abbreviations: BCVA, best corrected visual acuity; IOP, intraocular pressure; MD, mean deviation; SAP, standard automated perimetry. ^aStatistically significant using independent t-test.

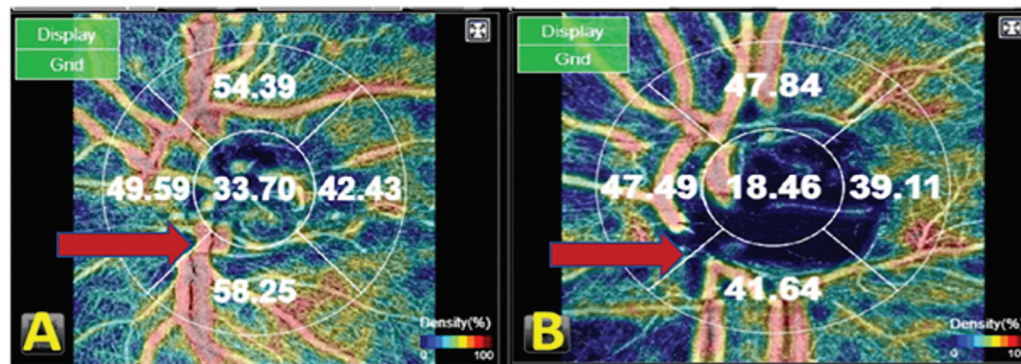


Fig. 1 A significant disparity in optical coherence tomography angiography vessel density percentage is apparent between the optic nerve area of the normal subject (subject A) and the glaucoma patient (subject B). Vascularization defects are noticeable as localized darker zones observed in all sectors, with the most pronounced defects observed in the inferior sector (red arrow).

Table 2 Details OCT-A vessel density (%) in the optic nerve area in glaucoma and normal subject groups

Vessel density (%) in the optic nerve area	Control (120 eyes of 96 subjects)	Glaucoma (160 eyes of 126 patients)	Reduction in microvasculature density (%)	p-Value
Inferior	51.2 ± 8.4	36.6 ± 12.4	28.5	< 0.001 ^a
Superior	56.3 ± 4.2	42.1 ± 5.7	25.2	< 0.001 ^a
Central	36.3 ± 11.8	27.8 ± 5.9	23.4	< 0.001 ^a
Nasal	47.8 ± 10.1	42.9 ± 3.1	10.3	< 0.001 ^a
Temporal	43.1 ± 14.9	39.1 ± 14.9	9.3	<0.02 ^a

Abbreviation: OCT-A, optical coherence tomography angiography. ^aStatistically significant by independent Student’s t-test.

healthy controls (►Fig. 2). The results indicated that the glaucoma group had lower vessel density in all macular regions.

Significant reductions in vessel density were observed in all sectors except for the central sector among the glaucoma group compared with normal subjects (►Table 3). The superior macula area demonstrated the highest reduction of 17.1%, ($p < 0.001$) in microvasculature density among glaucoma eyes relative to normal subjects. Similarly, substantial reductions were observed in temporal (15.7%), nasal (12.9%), and inferior (12.6%) sectors. The only exception was the central sector (0.49%), which was statistically not significant ($p > 0.05$).

Discussion

Glaucoma is a multifactor disease that causes gradual loss of RGCs and retinal nerve layers, visual field damage, and structural changes in the optic nerve. A vascular theory has been proposed, suggesting that impaired regulation of ocular blood flow plays a pivotal role in glaucoma progression.

This study aimed to utilize OCT-A as a precise tool for quantitatively assessing peripapillary and central macular vessel density, with a particular emphasis on its potential utility in the early detection of glaucoma and its role in elucidating vascular irregularities contributing to the

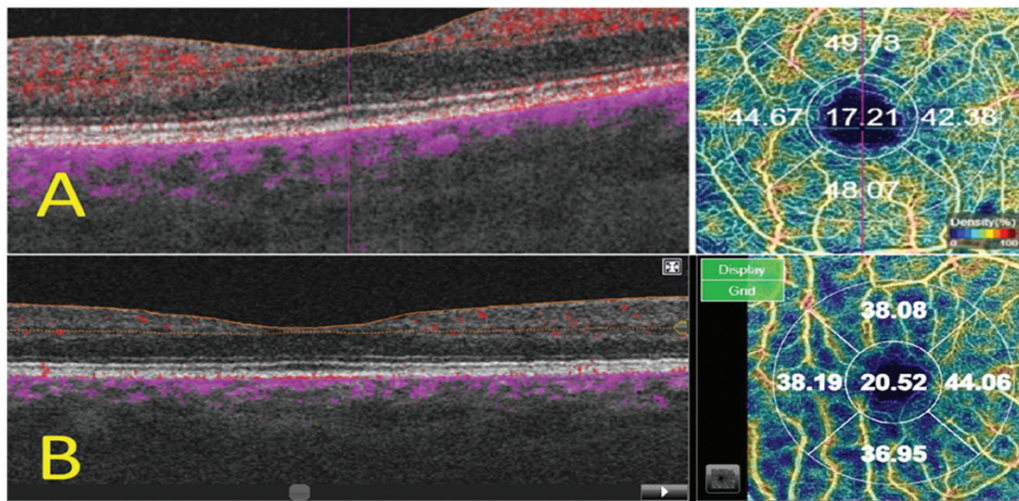


Fig. 2 Different in the optical coherence tomography angiography (OCT-A) vessels density % in the central macular area in normal subject groups A, and glaucoma patient B. Darker zones can be observed across various OCT-A sectors in the glaucoma case, indicating localized abnormalities.

Table 3 Details of OCT-A vessel density (%) in the central macular area in glaucoma and normal subject groups

Vessel density (%) in the central macular area	Control (120 eyes of 96 subjects)	Glaucoma (160 eyes of 126 patients)	Reduction in microvasculature density (%)	p-Value
Superior	47.3 ± 13.7	39.2 ± 4.8	17.1	< 0.001 ^a
Temporal	46.5 ± 8	39.2 ± 3.7	15.7	< 0.001 ^a
Nasal	42.7 ± 8.7	37.2 ± 6.1	12.9	< 0.05 ^a
Inferior	43.6 ± 10.5	38.1 ± 3.2	12.6	< 0.002 ^a
Central	20.2 ± 2.7	20.1 ± 1.3	4.9	>0.05

Abbreviation: OCT-A, optical coherence tomography angiography.

^aStatistically significant by independent Student's t-test.

pathogenesis of this intricate disease. Notably, previous studies primarily utilized the TOPCON Swept-Source OCT DRI Triton for OCTA, with vessel density measurements typically exported and analyzed through customized algorithms or manual software applications.^{25–27} In our study, we utilized the new built-in software within the device, which automatically and precisely calculates and measures the vascular density.

Our findings revealed significant reductions in microvasculature density in all sectors of the optic nerve area of glaucoma patients compared with controls. Our findings are consistent with previous studies examining retinal vessel density differences between glaucoma patients and healthy controls using OCT-A. Jia et al were the first to demonstrate a decrease in peripapillary vessel density in glaucoma.²⁸ Likewise, Lee et al reported significantly lower peripapillary vessel density in patients with POAG compared with controls, with more pronounced changes in the inferior quadrant.²² Similarly, our results revealed significantly lower vessel density in both the superior and inferior quadrants, aligning with the findings of Yarmohammadi et al.¹⁸

Further studies have also observed decreased peripapillary vessel density among glaucoma patients versus controls. Kim

et al and Dutta et al found lower vessel density in glaucoma patients.^{29,30} Kamalipour et al noted that vessel density decreases more prominently in the peripapillary region in early glaucoma preceding structural damage and visual field loss.³¹ Wang et al further established a correlation between peripapillary vessel density and glaucoma severity.³² Additionally, Simsek et al found significantly lower vascular density measurements in primary glaucoma groups compared with controls across all vessel density parameters.³³

However, not all studies have identified vessel density differences between glaucoma and healthy eyes. A few researchers found no significant differences in vessel density between patient populations.^{17,34} These inconsistencies may stem from variability in study populations, OCTA devices employed, and analytical methodologies used to quantify vessel density between studies. Overall, the majority of evidence indicates retinal vessel density is lower in glaucoma compared with healthy eyes.

Our study also utilized OCT-A to assess vessel density in the central macular region and revealed significant reductions in the microvasculature density in the central macular area of glaucoma patients compared with controls. Similar findings of reductions in the microvasculature density

among glaucoma patients compared with healthy controls were reported.^{21,35}

Notably, no significant reduction in vessel density was observed in the central foveal region of glaucoma patients compared with controls (0.49%, $p > 0.05$). This finding is in line with the study conducted by Khallouli et al, as they did not observe any significant difference in foveal vascular density between the control and glaucoma groups, this could be attributed to the existence of the foveal avascular zone, which encompasses the majority of the surface area in that sector.³⁶

Additionally, our study exhibited significant reductions in vessel density in all peripheral sectors of the macula. This finding is in line with the study reported by Lommatzsch et al and Lu et al^{37,38} where they reported significantly lower macular vessel density in glaucomatous eyes with the greatest reduction observed in the peripheral area. On the other hand, Verticchio Vercellin et al³⁹ reported that the macular vessel densities were not significantly lower in the parafoveal superior and inferior quadrant, and perifoveal superior quadrant. Several factors could contribute to the differences observed between our study and the other studies mentioned. Methodological differences, including variations in OCT angiography devices, software algorithms, and image analysis techniques, may account for discrepancies in measured microvasculature density. Additionally, differences in sample characteristics, such as age, disease severity, and treatment status, can influence the outcomes. Glaucoma is a heterogeneous disease, and variations in the proportion of glaucoma subtypes within the study populations may contribute to discrepancies.

This study conducted by Gunasegaran et al,⁴⁰ revealed that the effectiveness of OCT-A macular vessel density as a diagnostic tool for glaucoma identification differs among different racial groups. Furthermore, the study found that this diagnostic method has limited utility in identifying glaucoma in individuals of African origin.

Overall, our findings provide further evidence of the vascular changes associated with glaucoma and highlight the importance of evaluating the peripapillary and central macular regions in assessing glaucoma-related vascular changes. The observed reductions in microvasculature density in the optic nerve and macula of glaucoma patients suggest that microvascular changes may be an early indicator of glaucoma-related damage. The lack of difference observed in the central macula in our study may indicate that this region is less affected in the early stages of glaucoma. However, further studies are needed to establish the clinical significance of these changes and to evaluate the potential of OCT-A as a diagnostic and monitoring tool for glaucoma.

Limitations of the Study

While our study provides valuable insights into the microvasculature density in glaucoma patients, it is important to acknowledge certain limitations. The study design was observational and conducted at a single center, which may limit the generalizability of the findings. The relatively small

sample size, focus on mild POAG, and use of a specific OCT angiography device may also limit the statistical power and external validity of the results. Lastly, the cross-sectional nature of the study limits the ability to establish causality.

Conclusion

Our study demonstrated significant reductions in microvasculature density in glaucoma patients using OCT-A, supporting the association between glaucoma and vascular changes. The TOPCON Swept-Source OCT DRI Triton's new software shows promise for early glaucoma detection and monitoring. Further research is needed to confirm and expand upon the findings.

Funding

None.

Conflict of Interest

None declared.

References

- 1 Quigley HA, Broman AT. The number of people with glaucoma worldwide in 2010 and 2020. *Br J Ophthalmol* 2006;90(03):262–267
- 2 Tham YC, Li X, Wong TY, Quigley HA, Aung T, Cheng CY. Global prevalence of glaucoma and projections of glaucoma burden through 2040: a systematic review and meta-analysis. *Ophthalmology* 2014;121(11):2081–2090
- 3 Flammer J, Mozaffarieh M. What is the present pathogenetic concept of glaucomatous optic neuropathy? *Surv Ophthalmol* 2007;52(Suppl 2):S162–S173
- 4 Harris A, Kagemann L, Ehrlich R, Rospigliosi C, Moore D, Siesky B. Measuring and interpreting ocular blood flow and metabolism in glaucoma. *Can J Ophthalmol* 2008;43(03):328–336
- 5 American Academy of Ophthalmology. Primary Open-Angle Glaucoma Preferred Practice Pattern. San Francisco, CA: American Academy of Ophthalmology; 2021
- 6 Mwanza JC, Durbin MK, Budenz DL, et al. Glaucoma diagnostic accuracy of ganglion cell-inner plexiform layer thickness: comparison with nerve fiber layer and optic nerve head. *Ophthalmology* 2012;119(06):1151–1158
- 7 Hood DC, Anderson SC, Wall M, Raza AS, Kardon RH. A test of a linear model of glaucomatous structure-function loss reveals sources of variability in retinal nerve fiber and visual field measurements. *Invest Ophthalmol Vis Sci* 2009;50(09):4254–4266
- 8 Plange N, Kaup M, Weber A, Remky A, Arend O. Fluorescein filling defects and quantitative morphologic analysis of the optic nerve head in glaucoma. *Arch Ophthalmol* 2004;122(02):195–201
- 9 O'Brart DP, de Souza Lima M, Bartsch DU, Freeman W, Weinreb RN. Indocyanine green angiography of the peripapillary region in glaucomatous eyes by confocal scanning laser ophthalmoscopy. *Am J Ophthalmol* 1997;123(05):657–666
- 10 Rechtman E, Harris A, Kumar R, et al. An update on retinal circulation assessment technologies. *Curr Eye Res* 2003;27(06):329–343
- 11 Nicolela MT, Hnik P, Drance SM. Scanning laser Doppler flowmeter study of retinal and optic disk blood flow in glaucomatous patients. *Am J Ophthalmol* 1996;122(06):775–783
- 12 Hood DC, Raza AS, de Moraes CG, et al. Initial arcuate defects within the central 10 degrees in glaucoma. *Invest Ophthalmol Vis Sci* 2011;52(02):940–946

- 13 Hood DC, Raza AS, de Moraes CG, Liebmann JM, Ritch R. Glaucomatous damage of the macula. *Prog Retin Eye Res* 2013;32:1–21
- 14 Jia Y, Tan O, Tokayer J, et al. Split-spectrum amplitude-decorrelation angiography with optical coherence tomography. *Opt Express* 2012;20(04):4710–4725
- 15 Spaide RF, Klancnik JM Jr, Cooney MJ. Retinal vascular layers imaged by fluorescein angiography and optical coherence tomography angiography. *JAMA Ophthalmol* 2015;133(01):45–50
- 16 Zhang Q, Wang RK, Chen CL, et al. OCT angiography in glaucoma: comparison with conventional noninvasive methods such as OCT and HRT. *Invest Ophthalmol Vis Sci* 2015;56(09):5247–5257
- 17 Müller O, Todorova MG, Schlote T. OCT angiography of the central macular capillary network in glaucoma patients and healthy controls. *Klin Monatsbl Augenheilkd* 2018;235(04):436–444
- 18 Yarmohammadi A, Zangwill LM, Diniz-Filho A, et al. Optical coherence tomography angiography vessel density in healthy, glaucoma suspect, and glaucoma eyes. *Invest Ophthalmol Vis Sci* 2016;57(09):OCT451–OCT459
- 19 Liu L, Jia Y, Takusagawa HL, et al. Optical coherence tomography angiography of the peripapillary retina in glaucoma. *JAMA Ophthalmol* 2015;133(09):1045–1052
- 20 Choi J, Kwon J, Shin JW, Lee J, Lee S, Kook MS. Quantitative optical coherence tomography angiography of macular vascular structure and foveal avascular zone in glaucoma. *PLoS One* 2017;12(09):e0184948
- 21 Rao HL, Pradhan ZS, Weinreb RN, et al. Regional comparisons of optical coherence tomography angiography vessel density in primary open-angle glaucoma. *Am J Ophthalmol* 2016;171:75–83
- 22 Lee EJ, Lee KM, Lee SH, Kim TW. OCT Angiography of the peripapillary retina in primary open-angle glaucoma. *Invest Ophthalmol Vis Sci* 2016;57(14):6265–6270
- 23 Hodapp E, Parrish RK II, Anderson DR. *Clinical Decisions in Glaucoma*. St Louis: The CV Mosby Co; 1993:52–61
- 24 Topcon Triton OCT Accessed January 12, 2023 at: https://topconhealthcare.eu/en_EU/products/triton
- 25 Khayrallah O, Mahjoub A, Ben Abdesslam N, et al. Optical coherence tomography angiography vessel density parameters in primary open-angle glaucoma. *Ann Med Surg (Lond)* 2021;69:102671
- 26 Weindler H, Spitzer MS, Schultheiß M, Kromer R. OCT angiography analysis of retinal vessel density in primary open-angle glaucoma with and without Tafluprost therapy. *BMC Ophthalmol* 2020;20(01):444
- 27 Akil H, Huang AS, Francis BA, Sadda SR, Chopra V. Retinal vessel density from optical coherence tomography angiography to differentiate early glaucoma, pre-perimetric glaucoma and normal eyes. *PLoS One* 2017;12(02):e0170476
- 28 Jia Y, Morrison JC, Tokayer J, et al. Quantitative OCT angiography of optic nerve head blood flow. *Biomed Opt Express* 2012;3(12):3127–3137
- 29 Kim SB, Lee EJ, Han JC, Kee C. Comparison of peripapillary vessel density between preperimetric and perimetric glaucoma evaluated by OCT-angiography. *PLoS One* 2017;12(08):e0184297
- 30 Dutta A, Thulasidas M, Sasidharan A, Pradeep B, Rajesh Prabu V. Comparison of peripapillary capillary plexus using optical coherence tomography angiography and retinal nerve fibre layer analysis using spectral domain optical coherence tomography in glaucoma patients, glaucoma suspects, and healthy subjects. *Indian J Ophthalmol* 2022;70(12):4146–4151
- 31 Kamalipour A, Moghimi S, Jacoba CM, et al. Measurements of OCT angiography complement OCT for diagnosing early primary open-angle glaucoma. *Ophthalmol Glaucoma* 2022;5(03):262–274
- 32 Wang X, Jiang C, Ko T, et al. Correlation between optic disc perfusion and glaucomatous severity in patients with open-angle glaucoma: an optical coherence tomography angiography study. *Graefes Arch Clin Exp Ophthalmol* 2015;253(09):1557–1564
- 33 Simsek M, Oral Y, Inan S, Akdogan M, Cem Sabaner M. Comparison of peripapillary vascular density as measured by optical coherence tomography angiography between various types of open-angle glaucoma. *J Fr Ophtalmol* 2023;x:x
- 34 Hwang JC, Konduru R, Zhang X, et al. Relationship among visual field, blood flow, and neural structure measurements in glaucoma. *Invest Ophthalmol Vis Sci* 2012;53(06):3020–3026
- 35 Hou H, Moghimi S, Zangwill LM, et al. Macula vessel density and thickness in early primary open-angle glaucoma. *Am J Ophthalmol* 2019;199:120–132
- 36 Khallouli A, Oueslati Y, Gouider D, Bouchoucha S, Maalej A, Rannen R. Diagnostic accuracy and relationship between optical coherence tomography angiography vessel density and structural/functional parameters in healthy, preperimetric, and manifest glaucoma eyes. *J Curr Ophthalmol* 2022;34(02):173–179
- 37 Lommatzsch C, Rothaus K, Koch JM, Heinz C, Grisanti S. OCTA vessel density changes in the macular zone in glaucomatous eyes. *Graefes Arch Clin Exp Ophthalmol* 2018;256(08):1499–1508
- 38 Lu P, Xiao H, Liang C, Xu Y, Ye D, Huang J. Quantitative analysis of microvasculature in macular and peripapillary regions in early primary open-angle glaucoma. *Curr Eye Res* 2020;45(05):629–635
- 39 Verticchio Vercellin A, Siesky B, Antman G, et al. Regional vessel density reduction in the macula and optic nerve head of patients with pre-perimetric primary open angle glaucoma. *J Glaucoma* 2023;32(11):930–941
- 40 Gunasegaran G, Moghimi S, Nishida T, et al. Diagnostic ability of optical coherence tomography angiography macular vessel density for glaucoma in individuals of African and European descent. *Invest Ophthalmol Vis Sci* 2023;64(08):4423