



# Mini-Craniotomy for Chronic Subdural Hematoma: A Reliable Surgical Option

Gollapudi Prakash Rao<sup>1</sup> Mohammed Imran<sup>2</sup> Reddycherla Naga Raju<sup>1</sup> Pittala Sandeep<sup>2</sup>  
Kotha Arjun Reddy<sup>3</sup>

<sup>1</sup> Department of Neurosurgery, Gandhi Medical College, Secunderabad, Telangana, India

<sup>2</sup> Department of Neurosurgery, Srikara Hospitals, Hyderabad, Telangana, India

<sup>3</sup> Department of Neurosurgery, Apollo Hospitals, Hyderabad, Telangana, India

**Address for correspondence** Mohammed Imran, MBBS, MS, Mch, Department of Neurosurgery, Srikara Hospitals, Street Number 7, Near RTC X Road, Beside NABARD, Musheerabad, Hyderabad 500020, Telangana, India (e-mail: imrangmc.neuro@gmail.com).

Asian J Neurosurg

## Abstract

**Introduction** Chronic subdural hematoma (SDH) is one of the most common conditions encountered in the neurosurgical practice. Surgical modalities like twist drill craniostomy, burr hole evacuation, mini-craniotomy, and craniotomy are practiced in the management of chronic SDH. Mini-craniotomy without excision of membranes may help to achieve best results with decreased complication rate.

**Materials and Methods** Patients with chronic SDH operated from September 2013 to September 2022 were included in the study. Mini-craniotomy (40–60 mm) was done and cruciate incision was given over the dura. Dura was left wide open by reflecting and suturing the cut edges of the dural leaflets to the craniotomy edge allowing to evacuate subdural space under vision during surgery and to allow any residual collection to drain out freely in the postoperative period. A drain was placed between the inner membrane and the bone flap. Preoperative and postoperative clinical and radiological parameters were recorded. Complications, recurrence, and residual collections were noted.

**Results** Seventy-seven patients were included in the study. Mean age was 57.32 years. Median Glasgow Coma Scale (GCS) at presentation was 13 while median GCS at discharge was 15. Two patients with preexisting comorbidities expired after surgery due to medical causes. No recurrences were noted. Fourteen patients had residual collections which resolved by 6 weeks. Two patients had wound infection. One of these patients later needed a bone flap removal due to osteomyelitis.

**Conclusion** Mini-craniotomy without membranectomy is a good option for complete evacuation of chronic SDH under vision mainly avoiding the complication of membranectomy. It is not associated with increased complications rate. It needs fewer follow-ups as brain expansion can be established radiologically in a short period.

## Keywords

- ▶ chronic subdural hematoma
- ▶ mini craniotomy
- ▶ membranectomy
- ▶ residual collections
- ▶ recurrence

DOI <https://doi.org/10.1055/s-0044-1786703>.  
ISSN 2248-9614.

© 2024. Asian Congress of Neurological Surgeons. All rights reserved.

This is an open access article published by Thieme under the terms of the Creative Commons Attribution-NonDerivative-NonCommercial-License, permitting copying and reproduction so long as the original work is given appropriate credit. Contents may not be used for commercial purposes, or adapted, remixed, transformed or built upon. (<https://creativecommons.org/licenses/by-nc-nd/4.0/>)

Thieme Medical and Scientific Publishers Pvt. Ltd., A-12, 2nd Floor, Sector 2, Noida-201301 UP, India

## Introduction

Chronic subdural hematoma (SDH) is one of the most common conditions encountered in neurosurgical practice. The incidence is estimated to be in the range of 1.72 to 20.6 per 100,000 persons per year<sup>1,2</sup> and is higher in the elderly with 76.5 per 100,000 persons per year in the age group of 70 to 79 years and 127.1 per 100,000 persons per year in the age group > 80 years. The incidence is further expected to increase with increasing life expectancy and increasing use of antiplatelets and anticoagulants.

Surgical modalities such as twist drill craniostomy, burr hole evacuation, mini-craniotomy, and craniotomy have been practiced in the treatment of chronic SDH. Burr hole evacuation is the most commonly practiced procedure according to the recent surveys.<sup>3-6</sup> The literature has abundant data on burr hole evacuation for chronic SDH. Recurrence rate as high as 30% has been reported following burr hole evacuation.<sup>7,8</sup> There is no clear information about asymptomatic radiological residual collections which were observed and at some stage had clinical presentation necessitating surgical intervention in many of these studies involving various treatment modalities in treating chronic SDH.

Meta-analyses evaluating craniotomy are based on a small number of studies and nonrandomized uncontrolled studies. A craniotomy is usually reserved for recurrent cases, that is, recollections after burr hole evacuation or in patients where acute on chronic SDH with thick clot or membranes is visualized on preoperative imaging. Many a time, cases selected for large craniotomies also need membranectomy. Most of the surgical complications in these cases are related to membranectomy. This leads to an important selection bias and it is reflected in the outcomes in the form of increased complications in craniotomies or mini-craniotomy for chronic SDH. Poor outcomes in these studies can be due to selection criteria.

Mini-craniotomy is less extensively studied except for a few publications. In the literature, no distinction is made between craniotomy and mini-craniotomy. Hence, the complications associated with large craniotomy with membranectomy are wrongly attributed to mini-craniotomy.

Mini-craniotomy allows wider access to the subdural cavity and permits thorough evacuation of hematoma. In this report, we present our experience with mini-craniotomy for evacuation of chronic SDHs.

## Materials and Methods

Patients with unilateral chronic SDH who were operated at our institute from September 2013 to September 2022 were included in this study. Bilateral chronic SDH was excluded from the study. Demographic details, clinical, and radiological findings were recorded. After preoperative optimization, informed consent was taken and the patient was taken up for surgery. Consent for participation in the study was obtained. Approval from Institutional Ethics Committee was obtained.

## Operative Technique

The procedure was performed under general anesthesia. The operative site was marked. A linear incision was made extending from the tragus to the midline. Self-retaining retractors were placed. The temporalis muscle was dissected off the bone. A 40–to 60-mm craniotomy was done. After tack-up sutures, a cruciate incision was made over the dura. The dural leaflets along with the adherent outer membrane were reflected and sutured to the craniotomy edge and hemostasis was secured at the edges of the dura. The hematoma was evacuated and any loculations and septate membranes were excised to expose the hidden portions of the subdural cavity under vision. After thorough irrigation and clearance of the hematoma and solid clots, if any, a drain was placed in the subdural space. The bone flap was replaced. Scalp incision was closed in layers (►Fig. 1).

The patient was given adequate hydration and computed tomography (CT) brain was obtained 24 to 48 hours after the procedure. The drain was removed in 24 to 48 hours, that is, after the first CT brain. The patient was mobilized once the follow-up CT brain showed adequate expansion of the brain. As a routine, follow-up CT brain was done 3 to 4 weeks after surgery. In patients with residual collections, CT brain was done at an interval of 3 to 6 weeks till no residual collection is noted. Patients were followed up for 6 months.

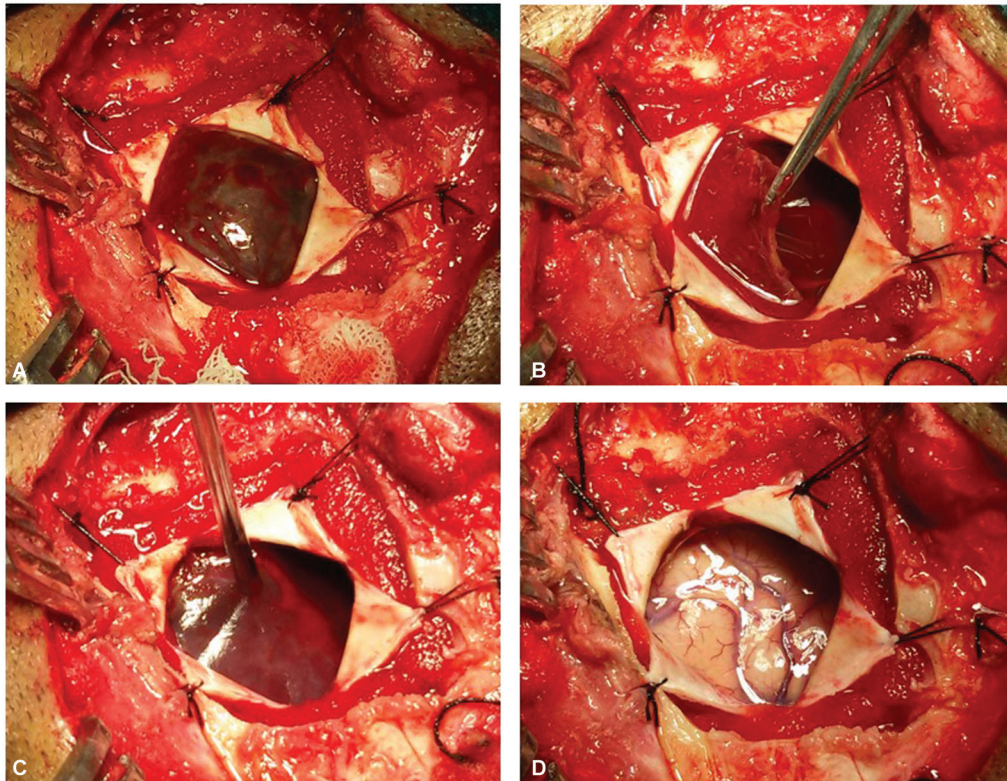
Surgical complications like recurrence, residual collection, wound infection, subdural empyema, intracerebral hemorrhage, pneumocephalus, or intracerebral abscess were recorded. Other related medical complications such as pneumonia, deep venous thrombosis and pulmonary embolism, new onset seizures, and myocardial infarction were recorded. Recurrence was defined as any radiological residual collection with or without clinical symptoms persisting for more than 6 weeks or recollection requiring second surgery due to clinical status at any point during the follow-up. Redo surgery was planned if there was symptomatic or persistent residual collection. Cases with residual collection without symptoms were kept under observation till a complete radiological resolution was noted. Duration of hospital stay, Glasgow Coma Scale (GCS) at discharge, and Markwalder grades were recorded. Death during hospital stay was recorded.

Statistical analysis was done using the Centers for Disease Control and Prevention Epi Info version 7. Continuous variables were described in terms of mean and standard deviation whereas categorical variables were described in terms of frequency and range.

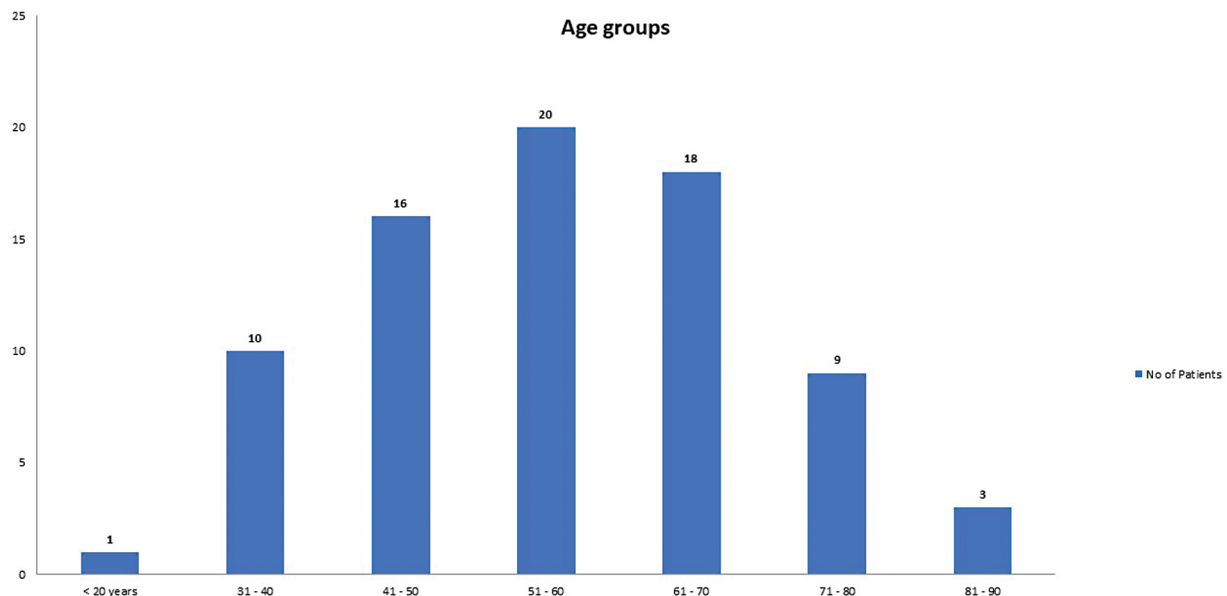
## Results

A total of 82 patients were operated during the study period, among which 5 patients were excluded from the study due to loss to follow-up. Seventy-seven patients were included in the study of which 59 were male and 18 were female. Mean age was 57.32 years with a standard deviation of 13.74 (►Fig. 2).

Headache was the most common presentation ( $n = 31$ ), followed by hemiparesis ( $n = 27$ ) and decreased consciousness ( $n = 24$ ). Vomiting was seen in 24 patients. However, the



**Fig. 1** Intraoperative images. (A) After the mini-craniotomy, the dura is incised and the flaps are reflected and sutured to the pericranium. (B) The visible portion of outer membrane is excised and the hematoma is evacuated exposing the internal membranes. (C) The internal septations are clearly visible now. These are also excised to thoroughly evacuate all the compartments of subdural hematoma (SDH). (D) The entire subdural cavity after evacuation of subdural hematoma is clearly visible.



**Fig. 2** Age groups.

headache was the lone symptom in 6 patients. Ten patients presented in an unconscious state and nine patients presented with seizures (► **Table 1**).

Among the 77 patients, 41 (53.24%) patients had comorbid conditions. Twenty-seven (35.06%) patients had at least one comorbidity and 14 (18.18%) patients had two or more

comorbidities. Hypertension was present in 29 patients. Coronary artery disease was seen in seven patients. Cerebrovascular accident was seen in four patients. Seven patients were diabetic and three patients were epileptic.

A history of trauma was present in 52 (67.53%) patients. Thirty-six (46.75%) patients had chronic alcoholism. Eleven

**Table 1** Clinical features

Presenting Complaints	No. of patients
Headache	31 (40.25%)
Hemiparesis	27 (35.06%)
Decreased consciousness	24 (31.16%)
Vomiting	24 (31.16%)
Unconsciousness	10 (12.98%)
Seizures	9 (11.68%)

(14.28%) patients were on antiplatelets and three (3.89%) patients were on warfarin. One patient was on both antiplatelets and anticoagulants. One patient had coagulopathy due to an unknown cause. All these patients' coagulation parameters were optimized before surgery.

On the preoperative CT brain, homogenous hypodense subdural collection was seen in 21 patients and the homogenous isodense collection was seen in 9 patients. The rest of the patients ( $n = 47$ ) had mixed density or layered collections on the CT scan (→ **Table 2**).

Intraoperatively, thick and well-formed outer membrane was seen in all the cases. Two or more laminar membranes (appearance of a chronic on chronic SDH) were seen in 20 patients and loculations were seen in 13 patients. Acute clots were seen in 15 cases.

Median GCS on presentation was 13 (interquartile range 7–15) while median GCS at discharge was 15. Preoperative and postoperative Markwalder grading is presented in → **Table 3**. Two patients expired during the hospital stay. Both these patients presented in unconscious state and had multiple comorbidities and never improved in the postoperative period (→ **Table 3**).

Mean duration of hospital stay was 7.09 days. No recurrences were noted in the postoperative period. Fourteen patients had residual collections, of which 6 cases resolved in 3 weeks and 8 patients had complete resolution by 6 weeks. All of these patients improved clinically after surgery.

Wound infection was encountered in two patients. Both these patients were managed with antibiotics initially. One of these patients later needed bone flap removal for osteomyelitis.

**Table 2** CT brain findings

CT brain findings	Frequency	Percent
Homogenous hypodense	21	27.27
Homogenous isodense	9	11.69
Layered type (hyperdense fluid sinking down)	13	16.88
Mixed density	15	19.48
Multilayered (chronic on chronic SDH with laminar membranes)	19	24.68

Abbreviations: CT, computed tomography; SDH, subdural hematoma.

**Table 3** Markwalder grades

Markwalder grading	Preoperative	Postoperative
Grade 0	01	50
Grade I	15	20
Grade II	22	2
Grade III	29	2
Grade IV	10	1

## Discussion

Chronic SDH is one of the most common neurosurgical conditions. It is associated with good prognosis when diagnosed early and treated adequately.<sup>9</sup> Surgical evacuation of chronic SDH often provides immediate relief of symptoms in the majority of the patients. While there is uniform agreement on the indication for surgical treatment, there is no consensus on the surgical modalities. Though burr hole evacuation is the most commonly practiced procedure for the evacuation of chronic SDH, it is associated with recurrence rates of up to 30%.<sup>7,8</sup> Recurrence remains the main problem in the management of chronic SDH.

Chronic SDH affects primarily the elderly patients who usually have other comorbid conditions making it riskier to subject them to multiple procedures under anesthesia. It is thought that the first procedure should be definitive and not expectant and should deal effectively with the hematoma so as to avoid recurrences.<sup>10</sup> Some authors have preferred mini-craniotomy to burr holes to reduce the recurrence rates.

Mini-craniotomy allows a large portal of access to the hematoma cavity and permits visualization of the loculations and septate membranes. In a mini-craniotomy, the loculations can be removed and septae can be excised which may not be possible with the burr hole evacuation and twist drill craniostomy. Wider access can help in the evacuation of thick clots more thoroughly under direct vision. In this study, we incised the dura along with the adherent outer membrane in a cruciate pattern and hemostasis was secured at the edges of the membrane and the dura was left wide open by reflecting the cut edges of the dura. During the postoperative period also, the collections can get pushed to the subgaleal



space with cerebral pulsations till the brain gets fully expanded. This enhances the chances of the evacuation of the hematoma fluid which is rich in antifibrinolytic substances.

Local hyperfibrinolysis is thought to be one of the main reasons for recurrence.<sup>11,12</sup> Daily hemorrhage into the hematoma content is estimated to be 10.2% with a range from 2 to 27.2%.<sup>11</sup> The presence of high concentrations of plasminogen activator, fibrin degradation products, kallikrein, bradykinin, platelet-activating factor, interleukin-6, vascular endothelial growth factor, and fibroblast growth factor in the subdural fluid is associated with higher recurrence rate.<sup>13,14</sup> Hence, it is better to evacuate the subdural fluid completely during the procedure and also to allow drainage of the residual fluid out of the subdural space till the fragile vessels in the neomembranes are stabilized. Mini-craniotomy with reflection of the dural leaflets might facilitate effective drainage of fluid both during the procedure and in the postoperative period.<sup>15</sup>

One of the concerns with such procedure is cerebrospinal fluid (CSF) leak. But in this series, we have not encountered any postoperative CSF leak. This could possibly be due to the intact inner membrane and the pia-arachnoid which acts as a barrier to the CSF leak. In other words, the inner membrane, after the expansion of the brain, may act as the dura or as a barrier at the durotomy site to prevent the CSF leak. The inner membrane may get adherent to the durotomy site and may help in forming a dural layer at a later stage. A similar hypothesis was proposed by another author.<sup>15</sup> We had a chance of reopening the craniotomy site to remove an infected bone flap. A well-formed membrane covering the durotomy site was noted indicating the reformation of dura.

This study had no recurrent subdural collections. Despite the higher percentage of cases with inhomogeneous collections, recurrence or rebleed was not seen. Two patients who expired during the study presented in a poor general condition (GCS 3 and Markwalder grade 4) and had expired due to medical causes. Fourteen out of 52 patients had residual collections in the first postoperative scan. All of these collections were resolved by the sixth week without further intervention. The wider dural opening allows residual collections to drain out into the subgaleal space even after the drain is removed, thus facilitating the early expansion of the brain. Two patients had wound infections and one of these patients needed excision of bone flap.

In the previous reports, the distinction between a large craniotomy and a mini-craniotomy was usually not made and the complications associated with large craniotomy and membranectomy were wrongly attributed to mini-craniotomy.<sup>16</sup> Some studies have included any cranial opening > 3 cm<sup>217</sup> or creation of cranial flap<sup>18</sup> as a craniotomy. There is great variation in not only in the size of the craniotomy but also among the techniques of dealing with membranes and the dura. Complete membranectomy, removal of only the outer membrane, and partial removal of the outer membrane are some of the variations. Very few studies mention the details of dural closure. It is usually not mentioned whether the dura is closed in watertight fashion or loosely sutured or left open. In this study, the dural leaflets are reflected so that

the cavity is left open while preserving the dura in case closure is required at a later date. Some of the authors have advocated durectomy along with craniotomy.<sup>15</sup>

Weigel et al, in their systematic review, have stated that selection bias may have distorted the picture of mortality and morbidity associated with a craniotomy. They have noted that the series of primary craniotomies are usually reserved for those patients who were presumed to have a higher risk of recurrence or who had less than satisfactory preoperative performance. Abecassis and Kim<sup>19</sup> made a similar observation. In their review of the literature on craniotomy for chronic SDH, they have noted that there are many limitations to the previous analyses which included a heterogeneous pool of patients, differences in surgical techniques, crossover, selection bias, and lack of randomization. In this study, all radiological types of chronic SDH were included. Meta-analysis Ducruet et al<sup>20</sup> found a higher complication rate in burr hole evacuation (9.3%) compared with craniotomy (3.9%). The mortality rate associated with craniotomy was 12.2% compared with 3.7% with burr hole evacuation. However, in most of these studies, a craniotomy was employed as a second tier treatment for recurrent cases, thus inferring selection bias.

Over the years, there have been fewer articles on craniotomy compared with burr hole evacuation and hence the systematic reviews might have been biased toward the most commonly favored procedure. Lega et al<sup>2</sup> have published a decision analysis wherein 361 patients who underwent craniotomy were included as opposed to 6,222 patients who underwent burr hole evacuation and 1,491 patients who underwent twist drill craniostomy. The meta-analysis by Almenawer et al<sup>18</sup> included 203 studies on burr hole evacuation while only 25 studies were related to craniotomy. All the studies did not differentiate mini-craniotomy from large craniotomy and did not describe the techniques of dealing with membrane.

It is quite evident that the literature is scant and biased against craniotomy. The technique of craniotomy is more variable in technique unlike burr hole evacuation or twist drill craniostomy to study it as a single entity/procedure. Furthermore, it would be unwise to reflect the results of those studies of craniotomy on to mini-craniotomy. The surgical technique used in this study had been uniform without any modification for any individual case. We differed with others mainly in dealing with the membrane which is adherent to the dura, as many of the problems in chronic SDH surgeries, mainly craniotomies, are related with membranectomy.

The concept of mini-craniotomy may not be new but its utility in chronic SDH is definitely not well studied. In fact, there are only a few studies on mini-craniotomy and among them, a case series presented by Van Der Veken et al is a notable one which studied mini-craniotomy as the sole procedure in 129 patients.<sup>16</sup> The recurrence rate in this series was 8.7%. The overall mortality was 13.5% which correlated with comorbidities like arterial hypertension, heart failure, renal failure, cerebrovascular accident, and coagulopathy.

Tanikawa et al<sup>21</sup> published a comparative study of burr hole evacuation ( $n=33$ ) and craniotomy ( $n=16$ ). The authors employed a craniotomy of 40 to 50 mm with wide resection of the outer membrane and intrahematoma membrane. All the patients who underwent craniotomy had better outcomes, while 27 out of 33 patients who underwent burr hole evacuation had better outcomes. The craniotomy group had shorter hospital stay compared with the burr hole group. The authors opined that craniotomy provides a safer and more beneficial opportunity to deal adequately with hematoma, its membranes, and occasional bleeding complications and also allows safer and controlled insertion of subdural drains.

Lee et al<sup>22</sup> compared small craniotomy versus one burr hole and two burr hole evacuations for evacuation of chronic SDH. The small craniotomy group had a statistically significant shorter duration of hospital stay. The rate of complications, revision rate, and complication rate were also better in the small craniotomy group compared with single burr hole and two burr hole methods.

In another article, the authors advocated mini-craniotomy for nonhomogeneous types of chronic SDH and opined that it allows copious and widespread lavage of the subdural space which allows correction of osmotic gradients by eliminating osmotically active subdural blood products. The authors believed that the “mini-craniotomy” concept in the evacuation of chronic SDHs of the elderly is an effective compromise between the “minimally invasive” burr hole and the aggressive, large craniotomy. It offers a fast and effective method that is well tolerated with minimal surgical morbidity, reducing the need for repeat surgery.<sup>23</sup>

In this study, no recurrences were noted. However, two patients expired during the hospital stay and two cases with wound infections were detected of which one required removal of bone flap. This signifies that with a mini-craniotomy and limited or no manipulation of the outer membrane and the interlaminar membranes, we can achieve good results without any added complications. In this procedure, there is no manipulation of the inner membrane and the unexposed portions of the outer membrane, which could potentially lead to injury to the cortical surface, fresh bleeding from the outer membrane, etc. This could be the reason for minimal complications in this series.

Thus, mini-craniotomy is not only effective but also a safe alternative for evacuation of chronic SDH. Further studies are required to establish mini-craniotomy as the standard procedure. It is time now to redefine and standardize the technique and revisit mini-craniotomy as a procedure of choice for evacuation of chronic SDH.

## Conclusion

Mini-craniotomy is a better option for surgical evacuation of chronic SDH as it allows better evacuation of subdural collections and is not associated with increased rate of complications. It needs fewer follow-ups as brain expansion can be established radiologically in short period. Our series might have had better results as there was no manipulation of the inner membrane and the unexposed portion of the

outer membrane and the dura was left wide open. There is a need to see mini-craniotomy as the procedure of choice for evacuation of chronic SDH.

## Funding

None.

## Conflict of Interest

None declared.

## References

- Karibe H, Kameyama M, Kawase M, Hirano T, Kawaguchi T, Tominaga T. Epidemiology of chronic subdural hematomas [Japanese]. *No Shinkei Geka* 2011;39(12):1149–1153
- Lega BC, Danish SF, Malhotra NR, Sonnad SS, Stein SC. Choosing the best operation for chronic subdural hematoma: a decision analysis. *J Neurosurg* 2010;113(03):615–621
- Berghauer Pont LME, Dippel DWJ, Verweij BH, Dirven CMF, Dammers R. Ambivalence among neurologists and neurosurgeons on the treatment of chronic subdural hematoma: a national survey. *Acta Neurol Belg* 2013;113(01):55–59
- Santarius T, Lawton R, Kirkpatrick PJ, Hutchinson PJ. The management of primary chronic subdural haematoma: a questionnaire survey of practice in the United Kingdom and the Republic of Ireland. *Br J Neurosurg* 2008;22(04):529–534
- Avanali R, Bhadrani B, Krishna Kumar P, et al. Chronic subdural hematoma: a questionnaire survey of management practice in India and review of literature. *World Neurosurg* 2016;96:355–361
- Cenic A, Bhandari M, Reddy K. Management of chronic subdural hematoma: a national survey and literature review. *Can J Neurol Sci* 2005;32(04):501–506
- Rohde V, Graf G, Hassler W. Complications of burr-hole craniotomy and closed-system drainage for chronic subdural hematomas: a retrospective analysis of 376 patients. *Neurosurg Rev* 2002;25(1-2):89–94
- Soleman J, Taussky P, Fandino J, Muroi C. Evidence-based treatment of chronic subdural hematoma. In: Sadaka F, ed. *Trauma Brain Inj* [Internet]. Rijeka: InTech; 2014 [cited January 11, 2018]. Ch. 12
- Rovlias A, Theodoropoulos S, Papoutsakis D. Chronic subdural hematoma: Surgical management and outcome in 986 cases: a classification and regression tree approach. *Surg Neurol Int* 2015;6:127
- Beatty RA. Subdural haematomas in the elderly: experience with treatment by trephine craniotomy and not closing the dura or replacing the bone plate. *Br J Neurosurg* 1999;13(01):60–64
- Ito H, Yamamoto S, Komai T, Mizukoshi H. Role of local hyperfibrinolysis in the etiology of chronic subdural hematoma. *J Neurosurg* 1976;45(01):26–31
- Shim YS, Park CO, Hyun DK, Park HC, Yoon SH. What are the causative factors for a slow, progressive enlargement of a chronic subdural hematoma? *Yonsei Med J* 2007;48(02):210–217
- Ito H, Komai T, Yamamoto S. Fibrinolytic enzyme in the lining walls of chronic subdural hematoma. *J Neurosurg* 1978;48(02):197–200
- Alcalá-Cerra G, Young AMH, Moscote-Salazar LR, Paternina-Cacedo A. Efficacy and safety of subdural drains after burr-hole evacuation of chronic subdural hematomas: systematic review and meta-analysis of randomized controlled trials. *World Neurosurg* 2014;82(06):1148–1157
- Mohamed EEH. Chronic subdural haematoma treated by craniotomy, dural resection, outer membranectomy and subgaleal suction drainage. Personal experience in 39 patients. *Br J Neurosurg* 2003; 17(03):244–247
- Van Der Veken J, Duerinckx J, Buyl R, Van Rompaey K, Herregodts P, D'Haens J. Mini-craniotomy as the primary surgical intervention for the treatment of chronic subdural hematoma—a retrospective analysis. *Acta Neurochir (Wien)* 2014;156(05):981–987

- 17 Weigel R, Schmiedek P, Krauss JK. Outcome of contemporary surgery for chronic subdural haematoma: evidence based review. *J Neurol Neurosurg Psychiatry* 2003;74(07):937–943
- 18 Almenawer SA, Farrokhyar F, Hong C, et al. Chronic subdural hematoma management: a systematic review and meta-analysis of 34,829 patients. *Ann Surg* 2014;259(03):449–457
- 19 Abecassis IJ, Kim LJ. Craniotomy for treatment of chronic subdural hematoma. *Neurosurg Clin N Am* 2017;28(02):229–237
- 20 Ducruet AF, Grobelny BT, Zacharia BE, et al. The surgical management of chronic subdural hematoma. *Neurosurg Rev* 2012;35(02):155–169, discussion 169
- 21 Tanikawa M, Mase M, Yamada K, et al. Surgical treatment of chronic subdural hematoma based on intrahematoma membrane structure on MRI. *Acta Neurochir (Wien)* 2001;143(06):613–618, discussion 618–619
- 22 Lee JK, Choi JH, Kim CH, Lee HK, Moon JG. Chronic subdural hematomas : a comparative study of three types of operative procedures. *J Korean Neurosurg Soc* 2009;46(03):210–214
- 23 Al-Jehani H, Petrecca K. The case for mini-craniotomy in the management of chronic subdural hematoma. *Acta Neurochir (Wien)* 2013;155(01):189–190