



Combined Deficit of the Four Lower Cranial Nerves also Known as the Syndrome of Collet-Sicard: A Systematic Review and Meta-analysis

Nathan Beucler^{1,2}

¹Neurosurgery Department, Sainte-Anne Military Teaching Hospital, Toulon, France

²Ecole du Val-de-Grâce, French Military Health Service Academy, Paris, France

Address for correspondence Nathan Beucler, MD, Neurosurgery Department, Sainte-Anne Military Teaching Hospital, 2 Boulevard Sainte-Anne, 83800 Toulon Cedex 9, France (e-mail: nathan.beucler@neurochirurgie.fr).

Asian J Neurosurg

Abstract

Combined deficit of the four lower cranial nerves (CN IX, X, XI, and XII) was originally described by French physicians Collet (1915) and Sicard (1917) during World War I. To date though, this rare neurological clinical picture lacks systematic evidence regarding its epidemiology, clinical presentation, treatment strategies, and outcome. We conducted a systematic review and meta-analysis concerning Collet-Sicard syndrome (CSS) on Medline database in accordance with the Preferred Reporting Items for Systematic Reviews and Meta-Analyses guidelines. The research yielded 84 articles among which 73 individual case reports were eventually retained. Mean age was 53.7 (\pm 16) years old and the male-to-female ratio was 1.8/1. CSS was firstly caused by tumors (38.4%), following by vascular etiologies (28.8%), trauma (16.4%), and infection (6.8%), among others. Temporary enteral nutrition was required for 17 patients (23.3%). The four CN presented significant chances of complete or partial recovery: 52.1% for CN IX ($p < 0.001$), 46.6% for CN X and CN XII ($p < 0.001$), and 39.7% for CN XI ($p = 0.002$). Tumoral causes presented significantly lower chances of favorable CN recovery (7.1%) compared to infection (60%), vascular (52.4%), and trauma (41.7%) ($p < 0.001$). Older age (> 53 years old) was not associated with a dismal CN prognostic ($p = 0.763$). Most patients (71.2%) presented a favorable outcome (Glasgow Outcome Scale score ≥ 4). All the patients who died (6.8%) suffered from skull base tumors. CSS is a rare condition requiring prompt clinical and radiologic diagnostic and multidisciplinary management. Vascular or infectious-related CSS seem to present a rather good prognostic, closely followed by trauma, whereas tumoral-related CSS seem to suffer from a more dismal prognostic.

Keywords

- ▶ anatomy
- ▶ Collet-Sicard
- ▶ skull base
- ▶ skull base trauma
- ▶ skull base tumor
- ▶ systematic review

DOI <https://doi.org/10.1055/s-0044-1787050>.
ISSN 2248-9614.

© 2024. Asian Congress of Neurological Surgeons. All rights reserved.

This is an open access article published by Thieme under the terms of the Creative Commons Attribution-NonDerivative-NonCommercial-License, permitting copying and reproduction so long as the original work is given appropriate credit. Contents may not be used for commercial purposes, or adapted, remixed, transformed or built upon. (<https://creativecommons.org/licenses/by-nc-nd/4.0/>)

Thieme Medical and Scientific Publishers Pvt. Ltd., A-12, 2nd Floor, Sector 2, Noida-201301 UP, India

Introduction

Wartime has always triggered notable surgical progress, such as the creation of the ambulance for the forward triage of wounded soldiers in 1792 by Dominique-Jean Larrey, Chief surgeon in French emperor Napoleon's army. More than one century later during World War I, a soldier suffering from a ballistic head injury in the mastoid region allowed Frédéric-Justin Collet, a French otolaryngologist, to describe the traumatic deficit of the four lower cranial nerves (CNs). The combined palsy of CN IX (glossopharyngeal nerve), CN X (vagus nerve), CN XI (accessory nerve), and CN XII (hypoglossal nerve) was also reported by J. Sicard, a French internist and radiologist, thus coining such clinical picture the Collet-Sicard syndrome (CSS).

CSS clinical manifestations are closely intermingled with the peculiar course of the four lower CN through the jugular and the hypoglossal foramina, and along the major blood vessels of the neck. Timely recognition of this condition in the emergency department is of paramount importance in order to ask for proper imaging of the brain and the neck. To date though, there is a lack of strong evidence regarding the main causes of CSS. Thus, it may be difficult for both the clinician and the radiologist to determine the most cost- and time-effective radiologic exams aiming to discriminate the most frequent etiologies of CSS, and allowing timely medical, surgical, and/or interventional treatment.

Given the very rare occurring of the CSS in clinical practice, this review aims to provide systematic evidence regarding its causes, clinical manifestations, treatment options, and functional prognosis. We hope that this work will be able to support the caregivers in the therapeutic decision making in the event that one day in their career they encounter a patient harboring the CSS.

Materials and Methods

Database Research

We conducted a systematic review on CSS on Medline database (<https://pubmed.ncbi.nlm.nih.gov/>) from inception to 2023 using the advanced search mode with the Medical Subject Headings term "Collet-Sicard" in the title.

Inclusion and Exclusion Criteria

All the English-language articles with individual extractable data concerning a case of CSS were included in the quantitative analysis. The exclusion criteria were articles without English-written text or abstract, articles not directly relevant to the subject, and articles that could not be found despite being indexed in Medline database.

Data Extraction

All the articles included in the quantitative analysis were screened in a systematic manner and the following information was extracted as previously planned: first author and year of publication; age and sex of the patient; mechanism and precise causative disease; deficit of CN IX, X, XI, XII; eventual presence of other CN deficit; diagnostic imaging;

treatment modalities; necessity of enteral nutrition; CN function improvement; and functional outcome according to the Glasgow Outcome Scale (GOS) score.

This study was conducted in accordance with the Preferred Reporting Items for Systematic Reviews and Meta-Analyses.¹

Primary and Secondary Endpoints of the Study

The primary endpoint of the study was to determine the improvement of CN function of patients presenting with CSS according to a three-grade scale: complete recovery (CR), partial recovery (PR), and no recovery. A significant CN function recovery was defined as follows: PR of all the impacted CN, plus CR of at least two impacted CN.

The secondary endpoints were to define the most common causes of CSS syndrome, to provide an overview of the treatment strategies employed, and to assess the functional outcome according to the GOS score.

Statistical Analysis

A meta-analysis of the relevant gathered data was conducted. All statistical analyses were conducted using S software version 4.0.3 (R Core Team [2020], R: A Language and Environment for Statistical Computing, R Foundation for Statistical Computing, Vienna, Austria; <https://www.R-project.org/>). Categorical variables were presented as numbers and percentages, and continuous variables were presented as median and interquartile range. The improvement in CN function was assessed using McNemar chi-square test. Differences in CN function recovery depending on clinical data (age and etiology) were assessed using Fisher's exact test for categorical variables given the small size of this series. A two-sided *p*-value of less than 0.05 was considered to indicate statistical significance.

Results

Database Research

The primary research yielded 83 articles and one article from other sources. Ten articles were excluded after the first screening and one article after reading of the full content, accounting eventually for 73 works.²⁻⁷⁴ The mean age was 53.7 years old (± 16) and the male-to-female ratio was 1.8/1 (**► Table 1**, **► Fig. 1**).

Mechanisms and Etiologies

Tumor was the main etiology for patients suffering from CSS (38.4%, $n = 28/73$), with mainly skull base metastases (17.8%, $n = 13/73$) and paragangliomas (9.6%, $n = 7/73$). Vascular etiologies accounted for 28.8% of the cases (21/73) and were mostly represented by internal carotid artery (ICA) dissection (17.8%, $n = 13/73$) and internal jugular vein (IJV) thrombosis (6.8%, $n = 5/73$). Trauma was involved in 16.4% of the cases ($n = 12/73$), whether it was a fall (8.2%, $n = 6/73$) or a traffic accident (6.8%, $n = 5/73$). Infection accounted for 6.8% of the cases ($n = 5/73$), with notably a few cases (4.1%, $n = 3/73$) of necrotizing external otitis in diabetic patients (**► Table 2**).

Table 1 Medline-based systematic literature review of patients presenting with Collet-Sicard syndrome

Study	Age, sex	Mechanism/disease	Causative lesion	CN deficits	X	XI	XII	Other	Diagnostic imaging	Treatment	Alimentation	CN outcome	X	XI	XII	GOS
1973 Mohanty	♂ 27	Ballistic injury	Direct injury	IX	Yes	Yes	Yes	-	X-ray	Conservative	-	IX	NR	NR	4	
1980 Nagata	♀ 51	Tumor	Breast cancer metastasis	Yes	Yes	Yes	-	-	DSA, PET	Surgery, radiotherapy	-	PR	CR	CR	5	
1988 Hashimoto	♂ 71	Trauma (traffic accident)	Condyle fracture	Yes	Yes	Yes	-	-	CTA	Conservative	NGT	PR	NR	NR	4	
1990 Sehitoglu	♀ 75	Tumor	Hemangiopericytoma	Yes	Yes	Yes	VII	-	CTA	Surgery	-	-	-	-	5	
1991 Wani	♂ 67	Trauma (fall)	Condyle fracture	Yes	Yes	-	VIII	-	X-ray, CT	Conservative	NGT	PR	NR	NR	4	
1992 Prick	♀ 61	Vascular (postoperative)	Ascending pharyngeal artery stroke	Yes	Yes	Yes	-	-	CTA	Conservative	-	CR	CR	CR	5	
1994 Sharma	♂ 35	Trauma (traffic accident)	Condyle fracture	Yes	Yes	Yes	-	-	CT	Surgery	-	PR	-	PR	4	
1995 Comacchio	♀ 83	Tumor	Infected hemangiopericytoma	Yes	Yes	Yes	VII	-	CT	Infection drainage	-	-	-	-	-	
1996 Tappin	♂ 52	Tumor	Multiple myeloma	Yes	Yes	Yes	-	-	-	-	-	-	-	-	1	
1997 Larson	♂ 67	Tumor	Adenocarcinoma metastasis	Yes	Yes	Yes	-	-	MRI	Medical treatment	Gastrostomy	-	-	-	1	
1997 Rees	♂ 43	Vascular	ICA dissection	Yes	Yes	Yes	-	-	DSA	Medical treatment	Gastrostomy	PR	PR	PR	4	
2000 Connolly	♂ 56	Trauma (traffic accident)	C1 Jefferson fracture	Yes	Yes	Yes	-	-	CT	Orthopaedic	-	CR	CR	CR	4	
2000 Heckmann	♀ 44	Vascular	ICA dissection	Yes	Yes	Yes	-	-	DSA	Blood thinner	-	-	-	-	5	
2000 Satoh	♂ 55	Tumor	Prostate carcinoma metastasis	Yes	-	Yes	-	-	MRI	Radiotherapy	-	PR	-	-	4	
2001 Otto	♂ 60	Vascular	IJV thrombosis	Yes	Yes	Yes	-	-	MRI, DSA	Blood thinner	-	CR	CR	CR	5	
2003 Papanouas	♀ 27	Tumor	Glomus paraganglioma	Yes	Yes	Yes	-	-	CT, DSA	-	-	-	-	-	-	
2003 Prashant	♂ 71	Tumor	Prostate carcinoma metastasis	Yes	Yes	Yes	VII	-	CT	Radiotherapy	Gastrostomy	PR	PR	PR	4	
2003 Walker	♂ 54	Vascular	ICA dissection	Yes	Yes	Yes	-	-	MRI	Blood thinner	-	CR	CR	CR	4	
2003 Willy	♀ 62	Postoperative	Emphysema (mass effect)	Yes	Yes	Yes	-	-	CT	Conservative	-	CR	CR	CR	5	
2004 Hsu	♂ 18	Trauma (traffic accident)	C1 Jefferson fracture	Yes	Yes	Yes	-	-	CT	Orthopaedic	-	CR	PR	CR	4	
2005 Garcia-Escrivá	♂ 45	Tumor	XII schwannoma	Yes	Yes	Yes	-	-	MRI	Surgery	-	-	-	-	5	
2005 Shine	♂ 54	Tumor	Prostate carcinoma metastasis	Yes	Yes	Yes	VII, VIII	-	CT, MRI	Radiotherapy	-	PR	CR	PR	1	
2006 Basu	♀ 35	Tumor	Cervical cancer metastasis	Yes	Yes	Yes	-	-	MRI, PET	Radiotherapy	-	CR	CR	CR	5	
2006 Chacon	♂ 53	Tumor	Prostate carcinoma metastasis	Yes	Yes	Yes	-	-	CT, MRI	-	-	-	-	-	-	
2006 Mohr	♀ 35	Vascular	ICA dissection	Yes	Yes	Yes	-	-	MRI	Blood thinner	-	CR	CR	CR	5	
2007 Erol	♂ 31	Trauma (traffic accident)	Condyle fracture	Yes	Yes	Yes	-	-	CT	Orthopaedic	-	CR	PR	NR	4	
2008 Lucato	♂ 54	Vascular	ICA dissection	Yes	Yes	Yes	-	-	CTA	-	-	-	-	-	-	
2009 Battaglia	♂ 57	Vascular	ICA dissection	Yes	Yes	Yes	-	-	MRIA	Blood thinners	-	CR	CR	PR	4	
2009 Lee	♂ 23	Ballistic injury	IMA pseudoaneurysm	Yes	Yes	Yes	-	-	CT, DSA	Endovascular	NGT	CR	PR	CR	4	
2009 Lucato	♂ 54	Vascular	ICA dissection	Yes	Yes	Yes	-	-	CTA	-	-	-	-	-	-	

(Continued)

Table 1 (Continued)

Study	Age, sex	Mechanism/disease	Causative lesion	CN deficits	X	XI	XII	Other	Diagnostic imaging	Treatment	Alimentation	CN outcome	XI	XII	GOS
2009 Opie	♀ 79	Tumor	Breast cancer metastasis	IX	Yes	Yes	Yes	-	MRI, PET	Radiotherapy	-	IX	X	XI	-
2009 Sibai	♂ 56	Infection	Occipitocervical osteomyelitis	Yes	Yes	Yes	Yes	-	CT, MRI	Surgery, antibiotics	Gastrostomy	PR	PR	PR	-
2010 Handley	♂ 32	Vascular	IJV thrombosis	Yes	Yes	-	Yes	-	MRIA	Blood thinners	NGT	PR	PR	PR	4
2011 Kwon	♂ 46	Trauma (fall)	C1 Jefferson fracture	Yes	Yes	-	Yes	-	CT	Surgery	NGT	PR	CR	-	4
2011 Petrović	♀ 57	Tumor	Fibrosarcoma	Yes	Yes	Yes	Yes	-	CTA	Surgery	-	-	-	-	-
2011 Villatoro	♂ 70	Tumor	Prostate carcinoma metastasis	Yes	Yes	Yes	Yes	-	CT, MRI	Medical treatment	-	CR	PR	NR	4
2013 Climans	♂ 67	Infection (NEO)	IJV thrombosis	Yes	Yes	Yes	Yes	-	CT	Blood thinners	-	PR	PR	PR	4
2013 Khalid	♀ 45	Tumor	Glomus paraganglioma	-	-	-	Yes	VII	CT	Radiotherapy	-	NR	NR	NR	4
2013 Smith	♂ 52	Vascular	ICA dissection	Yes	Yes	Yes	Yes	-	CT, MRI	Blood thinners	-	PR	PR	PR	4
2015 Domenicucci	♂ 58	Trauma (fall)	C1 Jefferson fracture	Yes	Yes	Yes	Yes	-	CT, MRI	Orthopaedic	-	NR	PR	PR	4
2015 Gutiérrez Rios	♀ 81	Tumor	Glomus paraganglioma	Yes	Yes	Yes	Yes	-	MRI	Radiotherapy	-	NR	NR	NR	5
2015 Schuster	♂ 52	Wegener disease	Granuloma	Yes	Yes	Yes	Yes	-	MRI	-	-	-	-	-	-
2016 Kang	♂ 70	Congenital bone conflict	Dysmorphic craniocervical junction	Yes	Yes	Yes	Yes	VII	CT, MRIA	-	-	-	-	-	-
2016 Mnari	♂ 21	Trauma	Styloid process fracture	Yes	Yes	Yes	Yes	-	CT, MRI	Conservative	Gastrostomy	CR	CR	CR	5
2017 Barbiero	♀ 44	Tumor	Glomus paraganglioma	Yes	Yes	Yes	Yes	-	CT, MRI, PET	Radiotherapy	-	NR	NR	NR	4
2018 Erben	♀ 43	Vascular (fibromuscular dysplasia)	ICA pseudoaneurysm	Yes	Yes	Yes	Yes	-	CTA, DSA	Endovascular	-	CR	CR	CR	5
2017 Lee	♀ 39	Tumor	XII schwannoma	Yes	-	Yes	Yes	-	MRI	Surgery	-	CR	NR	NR	4
2017 Maier	♂ 56	Vascular	ICA aneurysm	Yes	Yes	Yes	Yes	-	CTA, MRIA, DSA	-	-	-	-	-	-
2017 Neo	♂ 71	Vascular (iatrogenic CVC)	IJV thrombosis	Yes	Yes	Yes	Yes	-	CTA, MRIA	Blood thinners	NGT	CR	PR	CR	4
2018 Oushty	♀ 59	Tumor	Multiple myeloma	Yes	Yes	Yes	Yes	-	CT, MRI, PET	Biopsy, medical treatment	-	-	-	-	-
2017 Sánchez-larsen	♂ 90	Tumor	Lung cancer metastasis	Yes	Yes	Yes	Yes	-	CT, MRI	Conservative	-	-	-	-	1
2018 Low	♂ 82	Infection (NEO)	Skull base abscess	Yes	Yes	Yes	Yes	-	MRI	Biopsy, antibiotics	-	CR	CR	CR	5
2018 Saliou	♂ 61	Cerebral amyloid-related inflammation	ICA dissection	Yes	Yes	-	Yes	VII	CT, MRI, DSA, PET	Brain biopsy, steroids	-	CR	CR	-	5
2018 Simões	♂ 71	Congenital bone conflict	Eagle syndrome (elongated styloid process)	Yes	Yes	Yes	Yes	-	CT, MRI	Surgery	-	NR	NR	NR	4
2018 Subha	♀ 68	Tumor	Adenocarcinoma metastasis	Yes	Yes	-	Yes	VII	CT, MRI, PET	Surgery	-	-	-	-	-
2019 Dey	♀ 60	Tumor	Glomus paraganglioma	Yes	Yes	Yes	Yes	-	-	-	-	-	-	-	-
2019 Ganesh	♀ 56	Tumor	Glomus paraganglioma	Yes	Yes	Yes	Yes	-	CTA, MRI	Radiotherapy	-	-	-	-	5
2019 Krishnan	♂ 60	Tumor	Prostate carcinoma metastasis	Yes	Yes	Yes	Yes	-	MRI	Radiotherapy	NGT	-	-	-	5
2019 Mutlu	♀ 56	Tumor	Glomus paraganglioma	Yes	Yes	Yes	Yes	-	MRI	Radiotherapy	-	-	-	-	-

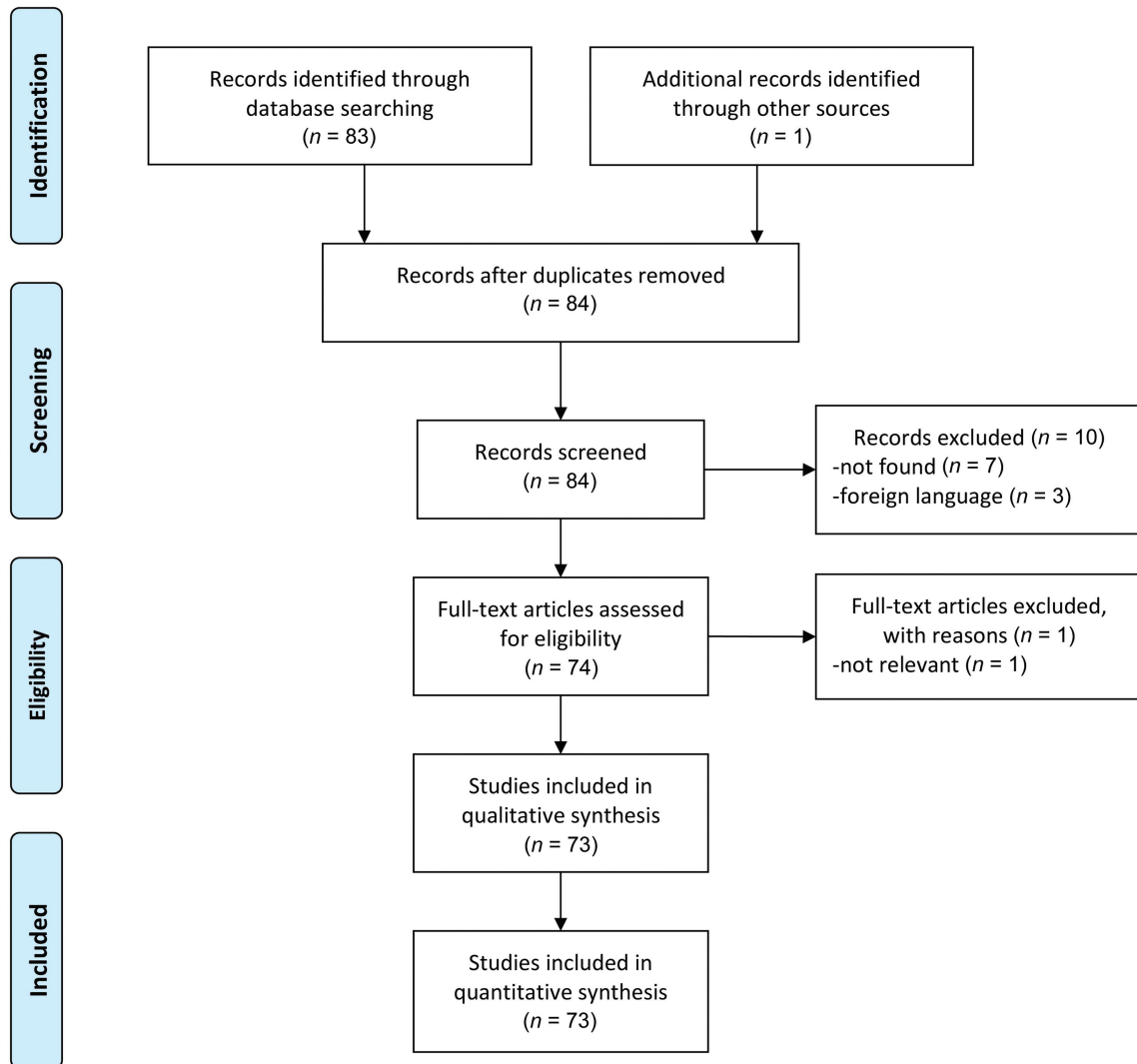
Table 1 (Continued)

Study	Age, sex	Mechanism/disease	Causative lesion	CN deficits	X	XI	XII	Other	Diagnostic imaging	Treatment	Alimentation	CN outcome	X	XI	XII	GOS
2019 Zamudio Moya	♂ 29	Infection (Smith-Lemli-Opitz syndrome)	Influenza A	Yes	Yes	Yes	–	Other	MRI, PCR	Antiviral treatment	–	CR	CR	CR	CR	5
2020 Beucler	♀ 30	Vascular (trauma)	IJV thrombosis	–	Yes	–	–	–	CTA	Blood thinners	–	–	CR	–	–	5
2020 Amar	♂ 51	Tumor	Paranglioma (pheochromocytoma)	Yes	Yes	Yes	–	–	MRI, full-body CT	–	–	–	–	–	–	–
2020 Arasawa	♀ 50	Tumor	Colorectal cancer metastasis	Yes	Yes	–	–	–	MRI	Radiotherapy	NGT	–	–	–	–	1
2020 Cabreira	♂ 57	Vascular (repetitive trauma)	ICA dissection	Yes	Yes	Yes	–	–	MRIA	–	–	–	–	–	–	5
2021 Al-Shabibi	♂ 56	Trauma (fall)	ICA dissection (C1 Jefferson)	Yes	Yes	–	–	–	CTA	Blood thinners	–	–	–	–	–	5
2021 Evan	♂ -	Vascular (infection)	ICA pseudoaneurysm	Yes	Yes	–	–	–	–	–	–	–	–	–	–	–
2021 Lian	♀ 35	Trauma (fall)	Condyle fracture	Yes	Yes	Yes	–	–	CT	Orthopaedic	NGT	–	–	–	–	5
2022 Shi	♂ 50	Vascular	ICA dissection	Yes	Yes	Yes	–	–	CT, MRIA	–	–	–	–	–	–	–
2021 Sokhi	♀ 57	Vascular (myeloma)	IJV thrombosis	Yes	Yes	Yes	–	–	MRI, DSA	Chemotherapy	–	PR	PR	PR	PR	4
2022 Bonda	♂ 63	Infection (NEO)	Skull base osteomyelitis	Yes	Yes	–	–	VII	CT, MRIA, PET	Antibiotic	Gastrostomy	CR	CR	–	CR	5
2022 Nowak	♂ 40	Vascular	ICA dissection	Yes	Yes	Yes	–	–	CTA, MRI, DSA	Endovascular	Gastrostomy	CR	PR	CR	PR	4
2022 Shahrivini	♀ 86	Trauma (fall)	C1 Jefferson fracture	Yes	Yes	Yes	–	–	CT	Orthopaedic	Gastrostomy	–	–	–	–	4
2023 Lin	♀ 49	Vascular	ICA aneurysm	Yes	Yes	Yes	–	–	MRIA	Endovascular	–	PR	PR	NR	NR	4

Abbreviations: CN, cranial nerve; CR, complete recovery; CT, computed tomography scan; CTA, computed tomography scan with angiography; CVC, central venous catheter; DSA, digital subtraction angiography; GOS, Glasgow Outcome Scale; ICA, internal carotid artery dissection; IJV, internal jugular vein; IMA, internal maxillary artery; MRI, magnetic resonance imaging; MRIA, magnetic resonance imaging with angiography; NEO, necrotizing external otitis; NGT, nasogastric tube; NR, no recovery; PCR, polymerase chain reaction; PET, positron emission tomography; PR, partial recovery.



PRISMA 2009 Flow Diagram



From: Moher D, Liberati A, Tetzlaff J, Altman DG, The PRISMA Group (2009). Preferred Reporting Items for Systematic Reviews and Meta-Analyses: The PRISMA Statement. PLoS Med 6(7): e1000097. doi:10.1371/journal.pmed1000097

For more information, visit www.prisma-statement.org.

Fig. 1 Medline-based systematic literature review of patients presenting with Collet-Sicard syndrome. Preferred Reporting Items for Systematic Reviews and Meta-Analyses (PRISMA) flowchart.

Treatment

Among the 18 patients suffering from ICA dissection or IJV thrombosis, 11 were treated with blood thinners. Four patients were treated with endovascular treatment, whether it was for posttraumatic pseudoaneurysm ($n = 2$), ICA dissection ($n = 1$), or ICA aneurysm ($n = 1$).

Among the patients with skull base tumors, 17.8% ($n = 13/73$) benefited from palliative radiotherapy among whom 11.0% ($8/73$) suffered from metastasis and 6.8% ($5/73$) suffered from glomus paraganglioma. Note that 6.8% ($5/73$) of the patients harboring skull base tumors were operated on.

Table 2 Causes of Collet-Sicard syndrome

Parameter	Number of patients	Percentage
Total	73	100
Mean age	53.7 ± 16	
Male-to-female ratio	47 / 26 (1.8/1)	
Cause		
Tumor	28	38.4
Metastasis	13	17.8
Paraganglioma	7	9.6
Multiple myeloma	3	4.1
XII schwannoma	2	2.7
Hemangiopericytoma	2	2.7
Fibrosarcoma	1	1.4
Vascular	21	28.8
ICA dissection	13	17.8
IJV thrombosis	5	6.8
Pseudoaneurysm	2	2.7
Aneurysm	1	1.4
Trauma	12	16.4
Fall	6	8.2
Traffic accident	5	6.8
Unspecified	1	1.4
Infection	5	6.8
Necrotizing otitis externa	3	4.1
Congenital immunodeficiency	1	1.4
Influenza A	1	1.4
Ballistic	2	2.7
Direct injury	1	1.4
Pseudoaneurysm	1	1.4
Congenital bone conflict	2	2.7
Cranio-cervical junction	1	1.4
Eagle syndrome	1	1.4
Systemic disease	2	2.7
Wegener disease	1	1.4
Cerebral amyloid-related inflammation	1	1.4
Postoperative	1	1.4

Abbreviations: ICA, internal carotid artery dissection; IJV, internal jugular vein.

Among trauma patients, 8.2% (6/73) benefited from orthopaedic treatment and 4.1% (3/73) of the patients were operated on.

Progressive Recovery of Cranial Nerves Deficit

CN IX was the most commonly involved in CSS (97.3%, $n = 71/73$), closely followed by CN X (95.9%, $n = 70/73$) and CN XII (93.2%, $n = 68/73$). CN XI was involved in 84.9% of the cases ($n = 62/73$). Temporary enteral nutrition was reported in 23.3% of the cases ($n = 17/73$), whether it was a nasogastric tube ($n = 9/73$) or a gastrostomy ($n = 8/73$). The four CN presented significant chances of CR or PR: 52.1% for CN IX ($n = 38/73$, $p < 0.001$), then 46.6% for CN X and CN XII ($n = 34/73$, $p < 0.001$), and finally 39.7% for CN XI ($n = 29/73$, $p = 0.002$) (► **Tables 3** and **4**).

Infectious etiologies harbored the highest rate of favorable CN functional recovery (60%, $n = 3/5$), closely followed by vascular causes (52.4%, $n = 11/21$) and trauma (41.7%, $n = 5/12$). At the opposite, patients suffering from tumors presented poor chances of CN recovery (7.1%, $n = 2/28$) ($p < 0.001$, ► **Table 5**). Age older than 53 years old was not associated with a lower rate of favorable CN functional recovery ($p = 0.763$, ► **Table 5**).

Functional Outcome

Most patients (71.2%, $n = 52/73$) presented a favorable outcome defined as a GOS score of 4 ($n = 29$) or 5 ($n = 23$). All the patients who died (6.8%, $n = 5/73$) suffered from skull base tumors, whether they were metastases ($n = 4$) or multiple myeloma ($n = 1$). Of note, the outcome according to the GOS score was not reported in 23.3% of the patients ($n = 17/73$).

Discussion

Historical Context

Wartime has always triggered important surgical progress for the care of the wounded,⁷⁵ such as the invention of the ambulance for the triage of war casualties by Dominique-Jean Larrey, chief military doctor in French emperor Napoleon's army.⁷⁶ At this time, and owing to the peculiar bone anatomy of the craniocervical junction and the precise course of the lower CN through the cranial base and along the jugulo-carotid gutter, a few authors have reported specific combinations of CN deficits:

-Vernet (1918) reported associated deficit of CN IX, X, and XI, indicating lesions located right at the jugular foramen, above the level of the hypoglossal canal and hypoglossal foramen.⁷⁷

-Then, for the first time, Collet (1915) described the combined deficit of the last four CNs (CN IX, X, and XI) in a soldier suffering from a ballistic injury in the mastoid region.⁷⁸

-The same clinical picture was reported by J. Sicard 2 years afterwards (1917).⁷⁹

-In the meantime, Villaret (1916) reported the association of CSS and deficit of the carotid sympathetic chain, thus

Table 3 Cranial nerve function upon admission and after treatment

Admission cranial nerve status		Number	Percentage	
IX		71	97.3	
X		70	95.9	
XI		62	84.9	
XII		68	93.2	
Other		11	15.1	
VII		10	13.7	
VIII		2	2.7	
Long-term cranial nerve status				
IX	CR	22	30.1	52.1%
	PR	16	21.9	
	NR	5	6.8	
	Not reported	30	41.1	
X	CR	18	24.7	46.6%
	PR	16	21.9	
	NR	8	11.0	
	Not reported	31	42.5	
XI	CR	15	20.5	39.7%
	PR	14	19.2	
	NR	10	13.7	
	Not reported	34	46.6	
XII	CR	15	20.5	46.6%
	PR	19	26.0	
	NR	8	11.0	
	Not reported	31	42.5	
Good CN recovery	≥ 4 PR + ≥ 2CR	22	30.1	
Vascular		11	15.1	
ICA dissection		6	8.2	
Artery pseudoaneurysm		2	2.7	
IJV thrombosis		2	2.7	
Trauma		5	6.8	
C1 Jefferson fracture		3	4.1	
Infection		3	4.1	
Skull base metastasis		2	2.7	
Postoperative emphysema		1	1.4	

Abbreviations: CN, cranial nerve; CR, complete recovery; ICA, internal carotid artery; IJV, internal jugular vein; NR, no recovery; PR, partial recovery.

adding Claude-Bernard-Horner syndrome to the clinical picture of CSS.⁸⁰

Relevant Anatomy

The pathophysiology of CSS is closely related to the course of the four lower CN through the jugular foramen and along the major blood vessels of the neck (→ Fig. 2).

The jugular foramen is located right above and lateral to the occipital condyle. This foramen is divided into three different compartments by a temporal intrajugular process

which continues with two thick intrajugular dura mater septa. The anteromedial part, historically known as the *pars nervosa*, is the pathway for CN IX along with the inferior petrous sinus. The middle part, comprised between the two dural septa, is coined the intrajugular compartment and contains CN X and CN XI, while the ascending pharyngeal artery passes in between to provide the posterior meningeal artery. This intrajugular compartment is anatomically included within the posterolateral sigmoid portion of the jugular foramen, which was historically known as *pars*

Table 4 Comparison of cranial nerve function upon admission and after treatment according to the chi-square test

	Upon admission	After treatment	Chi-square
CN IX palsy			$p < 0.001$
Yes	71 (97.3%)	33 (45.2%)	
No	2 (2.7%)	40 (54.8%)	
CN X palsy			$p < 0.001$
Yes	70 (95.9%)	36 (49.3%)	
No	3 (4.1%)	37 (50.7%)	
CN XI palsy			$p = 0.002$
Yes	62 (84.9%)	33 (45.2%)	
No	11 (15.1%)	40 (54.8%)	
CN XII palsy			$p < 0.001$
Yes	68 (93.2%)	34 (46.6%)	
No	5 (6.8%)	39 (53.4%)	

Abbreviation: CN, cranial nerve.

Table 5 Odds of cranial nerves recovery depending on clinical variables (etiology, age) according to the Fisher's exact test

Clinical variable	Significant CN recovery	Nonsignificant CN recovery	Missing data	Fisher's exact test
Etiology				$p < 0.001$
Infection	3 (60%)	2 (40%)	–	
Vascular	11 (52.4%)	10 (47.6%)	–	
Trauma	5 (41.7%)	7 (58.3%)	–	
Tumor	2 (7.1%)	26 (92.9%)	–	
Age				$p = 0.763$
≤ 53	11 (52.4%)	10 (47.6%)	11	
> 53	10 (43.5%)	13 (56.5%)	18	

Abbreviation: CN, cranial nerve.

vascularis and is the gateway for the jugular bulb, which constitutes the bulging angle between the sigmoid sinus and the IJV.^{81,82}

During its course outside the jugular foramen, CN IX is tethered to the major blood vessels of the neck by dense connective tissue and is thus particularly vulnerable to vessel injury.⁸¹ The cranial accessory nerve separates from the spinal accessory nerve to rejoin the middle ganglion of the vagus nerve, to finally further become the recurrent laryngeal nerve. Last, the hypoglossal canal runs through the occipital condyle. CN XII exits the hypoglossal canal medially to the jugular foramen and courses between the IJV and the ICA, before crossing the later laterally and heading forward. Hence, the four lower CN and the major blood vessels of the neck are closely intermingled.

Clinical Manifestations

CSS manifests with a recognizable constellation of clinical symptoms. Our aim is not to provide an exhaustive list of these symptoms, but rather to provide systematic and reliable clinical signs allowing proper recognition of the rare and peculiar CSS in the emergency room (→Fig. 3)⁸³:

- CN IX palsy results in soft palate anesthesia and loss of gag reflex.
- CN X palsy results in vocal cord paralysis, generally stuck in medial position.
- CN XI palsy manifests as a drooping shoulder indicating trapezius muscle palsy and difficulty in turning the head to the contralateral side indicating sternocleidomastoid muscle palsy.
- CN XII palsy is identified by ipsilateral tongue wasting (ipsilateral protraction).⁸⁴

Urgent Imaging

Upon clinical suspicion of CSS, the clinical must seek the most time- and cost-effective imaging exams allowing accurate diagnostic. Given the frequency of tumoral, vascular, and traumatic causes, the imaging can include computed tomography scan of the brain with or without angiography and/or magnetic resonance imaging of the brain with or without angiography. If these paraclinical explorations are unable to provide the diagnostic, digital subtraction angiography becomes mandatory.

In this review, 60.3% of the patients (44/73) were subjected to computed tomography, 57.5% of the patients

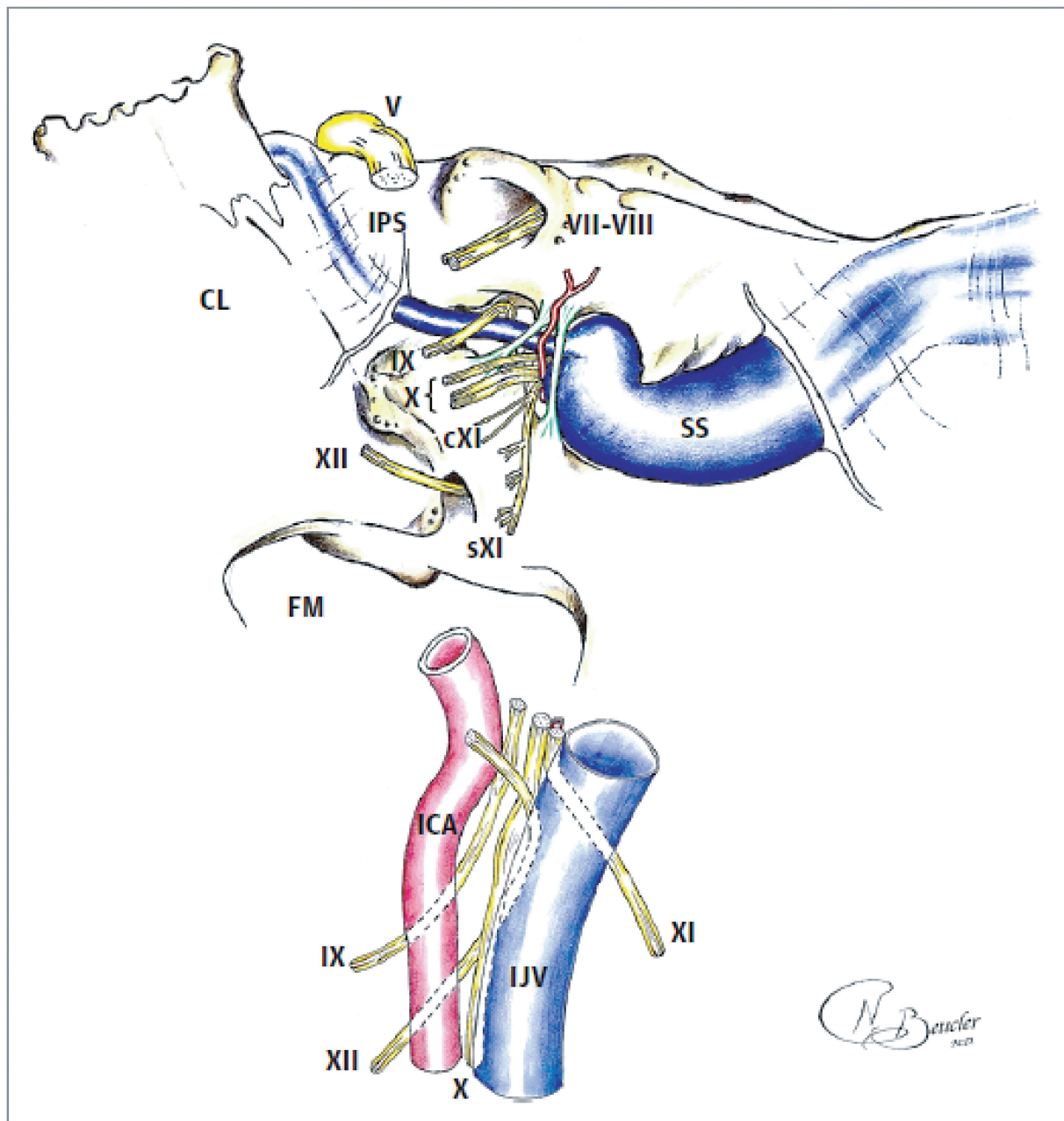


Fig. 2 Three-quarter backside artistic view of the course of the four lower cranial nerves course through the jugular foramen and along the major blood vessels of the neck. CL, clivus; FM, foramen magnum; IPS, inferior petrosal sinus; SS, sigmoid sinus. (Courtesy of Beucler et al. An unusual posttraumatic dysphagia with special reference to cerebellopontine angle. *JAMA Otolaryngol Head Neck Surg*; 2020).

(42/73) were subjected to magnetic resonance imaging, 15.1% of the patients (11/73) patients were subjected to digital subtraction angiography, and 9.6% of the patients (7/11) were subjected to positron emission tomography or scintigraphy.

Treatment

CSS is a very rare clinical condition arising from irritation or direct compression of the four lower CN during their course through the jugular foramen or along the major neck vessels. Whether it is caused by a skull base tumor, vascular injury, traumatic lesion, infectious disease, or more anecdotic causes, the management of patients harboring CSS requires

multidisciplinary approach regarding both the CN deficits and the patient's general status.

Skull Base Tumors

The care of patients with skull base tumors involves evaluation of the performance status.⁸⁵ In case of metastasis, the Graded Prognostic Assessment is a valuable preoperative screening tool allowing to determine the best candidates for surgical treatment.⁸⁶ Surgical removal of tumors located in the vicinity of the jugular bulb is a highly technical procedure which often requires partial drilling of the occipital condyle. Precise knowledge of this region's surgical anatomy is a prerequisite in order to perform functional sparing surgery,

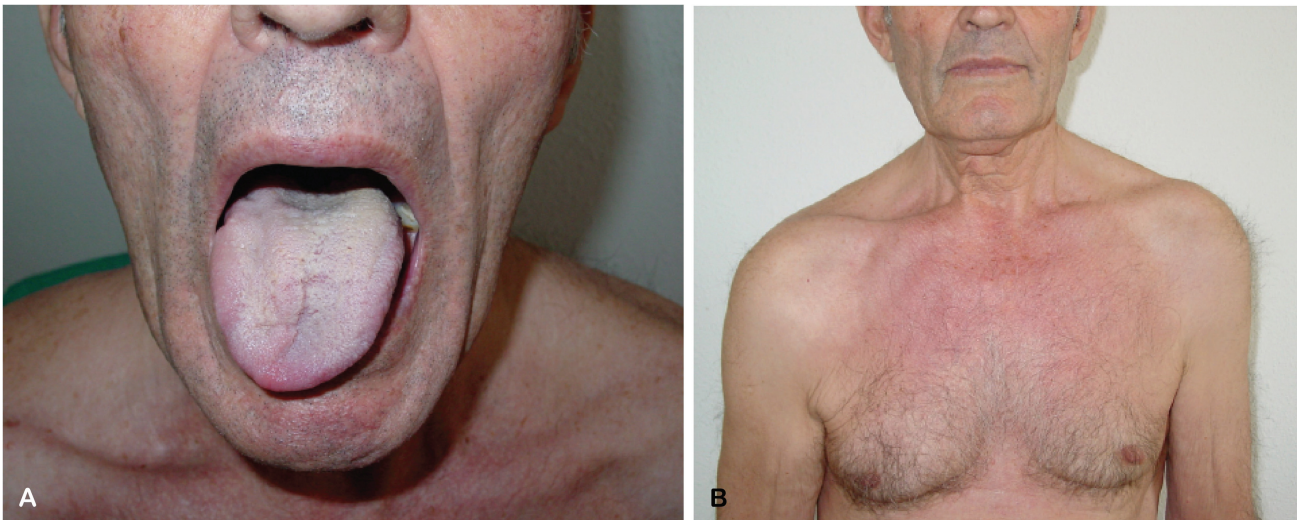

Fig. 3 Nonexhaustive display of clinical manifestations of Collet-Sicard syndrome. (A) Ipsilateral tongue wasting (deviation), indicating hypoglossal nerve palsy. (B) Ipsilateral shoulder drooping indicating accessory nerve palsy (Courtesy of Villatoro et al. Collet-Sicard syndrome as an initial presentation of prostate cancer: a case report. *J Med Case Rep*; 2011).

given the proximity of the bulbospinal junction, the presence of the vertebral artery, and the lower CNs.⁸⁷ Beyond its well-known complications such as intracranial infection and cerebrospinal fluid leak, the surgical procedure in itself may worsen the CN deficits.^{88–90} Given these considerations, palliative radiotherapy may appear as a valuable alternative, even more in case of very aggressive tumors or multimetastatic patients.⁹¹

Traumatic Lesions

Fractures of the occipital condyles⁹² as well as C1 Jefferson fractures most of the time require orthopaedic treatment. Nevertheless, both nonconsolidation and symptomatic displaced fractures (for example, when there are CN deficits) can indicate the need for surgical treatment.^{93,94}

Vascular Lesions

The management of ICA dissection,^{95,96} ICA aneurysm, and IJV thrombosis⁹⁷ is supported by widely accepted guidelines. Most of the times, patients suffering from these vascular diseases can be cured with modern management, which combine blood thinners and sometimes endovascular treatment.

Prognostic

From our point of view, the fact that “curable” medical affections such as infectious and vascular etiologies display the highest rates of favorable CN function improvement can be explained by two factors. First, part of the CN palsy can be caused by close contact inflammation which may resolve over time. Second, in such context, another part of CN palsy may be caused by the mass effect of the skull base abscess or the intravascular clot. The shrinking of the mass effect, thanks to proper treatment, may explain progressive symptomatic recovery.

At the opposite, surgical excision of tumors located in the vicinity of the jugular foramen is technically challenging. Most of

the time, patients undergo subtotal surgical excision followed by radiotherapy, and their very fragile status makes them particularly vulnerable to postoperative complications.⁹⁸

Limitations

This study presents limitations inherent to its retrospective nature. Considering that this work included only case reports, there is a reporting bias in favor of patients with a good functional outcome. There is a possible measurement bias during the collection of information. Last, the functional outcome was reported heterogeneously among the articles included, which inevitably leads to a supplementary measurement bias given our own interpretation of such information. Last, this study presents a clear lack of power ($n = 73$) which possibly increases the beta risk.

Nevertheless, to our knowledge this study is the largest concerning CSS. It has shed light on the most frequent causes and treatment options in face with CSS syndrome. It has also provided the odds of CN recovery depending on the most common causes, thus giving precious clues to clinicians facing this rare syndrome.

Conclusion

CSS characterizes combined deficit of the four lower CN. Therefore, it has a localizing value to the jugular and the hypoglossal foramina, or to the upper part of the major blood vessels of the neck. Tumor is the most frequent cause of CSS, followed by vascular and traumatic etiologies. Given the high chances of CN function improvement, treatment must be established on an individual basis, oftentimes with the support of a multidisciplinary team if necessary. Infectious and vascular causes present the highest rates of favorable CN functional recovery, followed by traumatic etiologies, whereas skull base tumors presenting with CSS suffer from dismal CN recovery as well as poor general outcome. Age does not influence CN functional recovery.

Funding

None.

Conflict of Interest

None declared.

Acknowledgments

We warmly thank Joffrey Marchi, biostatistician at the French Military Research Center for Epidemiology and Public Health, for carrying out the statistical analyses of this work on his personal time.

References

- Moher D, Liberati A, Tetzlaff J, Altman DGPRISMA Group. Preferred Reporting Items for Systematic Reviews and Meta-Analyses: the PRISMA statement. *PLoS Med* 2009;6(07):e1000097
- Al-Shabibi T, Hamdi H, Balaha A, Ghoraba Y, Kaya J-M. Delayed Collet-Sicard syndrome after internal carotid dissection and Jefferson fracture. Case report and review of literature. *Surg Neurol Int* 2021;12:374
- Amar JY, Ruta J, Bazer D, Bhattacharya A, Varadhachary AS. Collet-Sicard syndrome as the presentation of malignant pheochromocytoma. *Neurohospitalist* 2020;10(04):320–321
- Arasawa T, Miyauchi H, Fujita E, et al. A case of rectal cancer with Collet-Sicard syndrome [in Japanese]. *Gan To Kagaku Ryoho* 2020;47(13):2225–2226
- Barbiero FJ, Baehring JM, Fulbright RK, Becker KP. MRI findings in Collet-Sicard syndrome. *Neurology* 2017;88(08):811
- Basu S, Nair N. Relapse of cervical cancer presenting as symptoms of Collet-Sicard syndrome with metastatic subcutaneous and adrenal deposits. *Lancet Oncol* 2006;7(07):610
- Battaglia F, Martini L, Tannier C. Syndrome de Collet-Sicard après dissection carotidienne. *Rev Neurol (Paris)* 2009;165(6-7):588–590
- Beucler N, Morvan J-B, Dagain A. An unusual posttraumatic dysphagia with special reference to cerebellopontine angle. *JAMA Otolaryngol Head Neck Surg* 2020;146(01):73–74
- Bonda S, Tun KM, Asad S. A case of Collet-Sicard syndrome caused by otitis externa. *Cureus [Internet]* 2022. Accessed March 5, 2023 at: <https://www.cureus.com/articles/95102-a-case-of-collet-sicard-syndrome-caused-by-otitis-externa>
- Cabreira V, Lopes AC, Figueiredo R, Pinto MM. Collet-Sicard syndrome secondary to internal carotid artery dissection: a firing link. *Neurohospitalist* 2020;10(04):322–323
- Chacon G, Alexandraki I, Palacio C. Collet-Sicard syndrome: an uncommon manifestation of metastatic prostate cancer. *South Med J* 2006;99(08):898–899
- Climans SA, Melanson M, Desai JA. A case of Collet-Sicard syndrome caused by necrotizing otitis externa. *Can J Neurol Sci* 2013;40(02):268–270
- Comacchio F, D'Eredità R, Poletto E, Poletti A, Marchiori C. Hemangiopericytoma of the skull base and Collet-Sicard syndrome: a case report. *Ear Nose Throat J* 1995;74(12):845–847
- Connolly B, Turner C, DeVine J, Gerlinger T. Jefferson fracture resulting in Collet-Sicard syndrome. *Spine* 2000;25(03):395–398
- Dey JK, Carlson ML. Jugular paraganglioma presenting with Collet-Sicard syndrome. *Mayo Clin Proc* 2019;94(09):1832–1833
- Domenicucci M, Mancarella C, Dugoni ED, Ciappetta P, Paolo M. Post-traumatic Collet-Sicard syndrome: personal observation and review of the pertinent literature with clinical, radiologic and anatomic considerations. *Eur Spine J* 2015;24(04):663–670
- Erben Y, Ghare MI, Patel A, Mojibian H, Matouk C. Collet-Sicard syndrome secondary to internal carotid artery pseudoaneurysm. *J Vasc Surg* 2018;67(05):1596–1597
- Erol FS, Topsakal C, Kaplan M, Yildirim H, Ozveren MF. Collet-Sicard syndrome associated with occipital condyle fracture and epidural hematoma. *Yonsei Med J* 2007;48(01):120–123
- Evan J, Johansen M, Akst LM. Dysphagia, dysphonia and a deviated tongue: diagnosing Collet-Sicard syndrome. *BMJ Case Rep* 2021;14(05):e243154
- Ganesh A, Assis Z, Fok D, Cairncross JG, Bal SS, Furtado S. Teaching NeuroImages: Collet-Sicard syndrome and hearing loss with glomus jugulotympanicum. *Neurology* 2019;93(14):e1408–e1409
- Garcia-Escrivà A, Pampliega Pérez A, Martín-Estefania C, Botella C. Schwannoma of the hypoglossal nerve presenting as a syndrome of Collet-Sicard[in Spanish]. *Neurología* 2005;20(06):311–313
- Gutiérrez Ríos R, Castrillo Sanz A, Gil Polo C, Zamora García MI, Morollón Sánchez-Mateos N, Mendoza Rodríguez A. Collet-Sicard syndrome. *Neurología* 2015;30(02):130–132
- Handley TPB, Miah MS, Majumdar S, Hussain SSM. Collet-Sicard syndrome from thrombosis of the sigmoid-jugular complex: a case report and review of the literature. *Int J Otolaryngol* 2010;2010:1–5
- Hashimoto T, Watanabe O, Takase M, Koniya J, Kobota M. Collet-Sicard syndrome after minor head trauma. *Neurosurgery* 1988;23(03):367–370
- Heckmann JG, Tomandl B, Duhm C, Stefan H, Neundörfer B. Collet-Sicard syndrome due to coiling and dissection of the internal carotid artery. *Cerebrovasc Dis* 2000;10(06):487–488
- Hsu HP, Chen ST, Chen CJ, Ro LS. A case of Collet-Sicard syndrome associated with traumatic atlas fractures and congenital basilar invagination. *J Neurol Neurosurg Psychiatry* 2004;75(05):782–784
- Kang K, Moon BG. Developmental abnormalities of the craniocervical junction resulting in Collet-Sicard syndrome. *Spine J* 2016;16(09):e635–e639
- Khalid S, Zaheer S, Khalid M, Zaheer S, Raghuwanshi RK. Collet-Sicard syndrome secondary to a large glomus jugulotympanicum. *Ann Saudi Med* 2013;33(04):407–410
- Krishnan M, Balamurugan N, Thiruvartchelvan K, Sivakumar S. Prostate cancer presenting as Collet-Sicard syndrome. *J Assoc Physicians India* 2019;67(08):72
- Kwon HC, Cho DK, Jang YY, Lee SJ, Hyun JK, Kim TU. Collet-Sicard syndrome in a patient with Jefferson fracture. *Ann Rehabil Med* 2011;35(06):934–938
- Larson WL, Beydoun A, Albers JW, Wald JJ. Collet-Sicard syndrome mimicking neuralgic amyotrophy. *Muscle Nerve* 1997;20(09):1173–1177
- Lee J-S, Sy ED, Chang C-W, Chang S-S. Craniofacial gunshot injury resulting in pseudoaneurysm of the left internal maxillary artery and Collet-Sicard syndrome. *J Craniofac Surg* 2009;20(02):568–571
- Lee SH, Lee ES, Yoon CH, Shin H, Lee CH. Collet-Sicard syndrome with hypoglossal nerve schwannoma: a case report. *Ann Rehabil Med* 2017;41(06):1100–1104
- Lian C, Liu S, Li X, Du Z-H. The diagnosis process of Collet-Sicard syndrome caused by skull base fracture: a case report. *Neurología (Engl Ed)* 2021;36(08):649–651
- Lin J, Zhou L, Hong D. Internal carotid artery aneurysm presenting as lower cranial nerve palsies. *World Neurosurg* 2023;173:23–24
- Low W-K, Lhu H-L. Skull base osteomyelitis from otitis media presenting as the Collet-Sicard syndrome. *Case Rep Otolaryngol* 2018;2018:1407417
- Lucato LT, Passos RBD, Campos CR, Conforto AB, McKinney AM. Neurological picture. Multidetector-row computed tomography in the diagnosis of Collet-Sicard syndrome. *J Neurol Neurosurg Psychiatry* 2008;79(05):521–521
- Lucato LT, Passos RBD, Campos CR, Conforto AB, McKinney AM. Multidetector-row computed tomography in the diagnosis of Collet-Sicard syndrome. *BMJ Case Rep* 2009;2009:bcr2007120972

- 39 Maier S, Bajkó Z, Moțățăianu A, Rusu S, Bălașa R. Giant internal carotid artery aneurysm causing Collet-Sicard syndrome. *Acta Neurol Belg* 2017;117(01):295–297
- 40 Mnari W, Kilani M, Harrathi K, Maatouk M, Koubaa J, Golli M. An unusual etiology of posttraumatic Collet-Sicard Syndrome: a case report. *Pan Afr Med J* 2016;23:143
- 41 Mohanty SK, Barrios M, Fishbone H, Khatib R. Irreversible injury of cranial nerves 9 through 12 (Collet-Sicard syndrome). *Case report. J Neurosurg* 1973;38(01):86–88
- 42 Mohr A, Ebert S, Knauth M. Spontane Dissektion der Arteria carotis interna mit ipsilateralem Collet-Sicard-Syndrom. *Röfo Fortschr Geb Röntgenstr Neuen Bildgeb Verfahr* 2006;178(04):444–446
- 43 Mutlu V, Ogul H. Magnetic resonance imaging features of Collet-Sicard syndrome associated with glomus jugulare paraganglioma. *J Craniofac Surg* 2019;30(06):e574–e576
- 44 Nagata H, Sato S, Tanaka K, et al. Skull base metastasis of the breast cancer causing the Collet-Sicard syndrome—a case report (author's transl) [in Japanese]. *No To Shinkei* 1980;32(07):695–700
- 45 Neo S, Lee KE. Collet-Sicard syndrome: a rare but important presentation of internal jugular vein thrombosis. *Pract Neurol* 2017;17(01):63–65
- 46 Nowak DA, Linden R, Arnold P, et al. Case report: a complicated course of Collet-Sicard syndrome after internal carotid artery dissection and lenticulo-striatal artery infarction. *Front Neurol* 2022;13:939236
- 47 Opie NJ, Ur-Rehman K, James GJ. A case of Collet-Sicard syndrome presenting to the oral and maxillofacial surgery department and a review of the literature. *Br J Oral Maxillofac Surg* 2010;48(04):e9–e11
- 48 Otto M, Otto V, Göttinger R, Cordes P, Wessel K. Collet-Sicard's syndrome as a result of jugular vein thrombosis. *J Neurol* 2001;248(02):143–144
- 49 Oushy S, Graffeo CS, Perry A, Morris JM, Carlson ML, Van Gompel JJ. Collet-Sicard syndrome attributable to extramedullary plasmacytoma of the jugular foramen. *World Neurosurg* 2018;110:386–390
- 50 Paparounas K, Gotsi A, Apostolou F, Akritidis N. Collet-Sicard syndrome disclosing glomus tumor of the skull base. *Eur Neurol* 2003;49(02):103–105
- 51 Petrović S, Grozdanović D, Kovačević P, Višnjić M, Petrović D. Collet-Sicard syndrome as atypical presentation of neck fibrosarcoma: a case report. *Bosn J Basic Med Sci* 2011;11(02):137–140
- 52 Prashant R, Franks A. Collet-Sicard syndrome—a report and review. *Lancet Oncol* 2003;4(06):376–377
- 53 Prick MJ, Verhagen WI. The Collet-Sicard syndrome as a complication of cardiovascular surgery. *J Neurol Neurosurg Psychiatry* 1992;55(08):741
- 54 Rees JH, Valentine AR, Llewelyn JG. Spontaneous bilateral carotid and vertebral artery dissection presenting as a Collet-Sicard syndrome. *Br J Radiol* 1997;70(836):856–858
- 55 Saliou V, Ben Salem D, Ognard J, et al. A Collet-Sicard syndrome due to internal carotid artery dissection associated with cerebral amyloid angiopathy-related inflammation. *SAGE Open Med Case Rep* 2018;6:2050313 × 1877717
- 56 Sánchez-Larsen A, Feria-Vilar I, Collado R, Segura T. Síndrome de Collet-Sicard metastásico. *Neurología* 2017;32(06):399–401
- 57 Satoh H, Nishiyama T, Horiguchi A, Nakashima J, Saito S, Murai M. A case of Collet-Sicard syndrome caused by skull base metastasis of prostate carcinoma [in Japanese]. *Nippon Hinyokika Gakkai Zasshi* 2000;91(06):562–564
- 58 Schuster NM, Karnezis S, Restrepo L. Teaching NeuroImages: granulomatosis with polyangiitis causing Collet-Sicard syndrome and refractory headache. *Neurology* 2015;85(23):e179–e180
- 59 Sehitoglu MA, Uneri C, Celikoyar MM, Tutkun A, Küllü S. Heman-giopericytoma as the cause of Collet-Sicard syndrome. *ORL J Otorhinolaryngol Relat Spec* 1990;52(02):133–136
- 60 Shahrivini B, Crawford K, Vahabzadeh-Hagh AM. Collet-Sicard syndrome after Jefferson fracture. *Ear Nose Throat J* 2022;101(07):NP273–NP275
- 61 Sharma BS, Mahajan RK, Bhatia S, Khosla VK. Collet-Sicard syndrome after closed head injury. *Clin Neurol Neurosurg* 1994;96(02):197–198
- 62 Shi K, Zhang N, Li Y, et al. Be careful of Collet-Sicard syndrome: a rare result of carotid artery dissection. *Headache* 2022;62(03):389–394
- 63 Shine NP, O'Sullivan P. Collet-Sicard syndrome: a rare presentation of metastatic prostate adenocarcinoma. *Auris Nasus Larynx* 2005;32(03):315–318
- 64 Sibai TA, Ben-Galim PJ, Eicher SA, Reitman CA. Infectious Collet-Sicard syndrome in the differential diagnosis of cerebrovascular accident: a case of head-to-neck dissociation with skull-based osteomyelitis. *Spine J* 2009;9(04):e6–e10
- 65 Simões J, Paiva S, Miguéis J, Miguéis A. A long styloid process and Collet-Sicard syndrome. *Acta Otorrinolaringol Esp (Engl Ed)* 2019;70(05):310–311
- 66 Smith R, Tassone P, Saada J. Collet-Sicard syndrome as a result of unilateral carotid artery dissection. *BMJ Case Rep* 2013;2013:bcr2013200358–bcr2013200358
- 67 Sokhi DS, Mithi CW, Ebrahim FA, Salyani A, Waa S, Riyat MS. Collet-Sicard syndrome due to concurrent extramedullary intracranial plasmacytoma and jugular venous sinus thrombosis in multiple myeloma. *Clin Case Rep* 2021;9(07):e04457
- 68 Subha ST, Nordin A-J. Metastatic adenocarcinoma of temporal bone with Collet-Sicard syndrome. *Iran J Otorhinolaryngol* 2018;30(101):361–364
- 69 Tappin JA, Satchi G, Corless JA, Ashworth F. Multiple myeloma presenting as the Collet-Sicard syndrome. *J Neurol Neurosurg Psychiatry* 1996;60(01):14–14
- 70 Villatoro R, Romero C, Rueda A. Collet-Sicard syndrome as an initial presentation of prostate cancer: a case report. *J Med Case Rep* 2011;5:315
- 71 Walker S, McCarron MO, Flynn PA, Watt M. Left internal carotid artery dissection presenting with headache, Collet-Sicard syndrome and sustained hypertension. *Eur J Neurol* 2003;10(06):731–732
- 72 Wani MA, Tandon PN, Banerji AK, Bhatia R. Collet-Sicard syndrome resulting from closed head injury: case report. *J Trauma* 1991;31(10):1437–1439
- 73 Willy PJ, McArdle P, Peters WJ. Surgical emphysema and Collet-Sicard syndrome after cryoblockade of the inferior alveolar nerve. *Br J Oral Maxillofac Surg* 2003;41(03):190–192
- 74 Zamudio Moya FJ, Sagarra Mur D, Pereira de Vicente M. Síndrome de Collet-Sicard secundario a infección por virus de la influenza A (H1N1). *Neurología (Engl Ed)* 2019;34(06):418–419
- 75 Chauvin F, Fischer L-P, Ferrandis J-J, Chauvin E, Gunepin F-X. Progress in surgery of limb's wounds during the Great War [in French]. *Hist Sci Med* 2002;36(02):157–173
- 76 Koehler U, Conradt R. The inventor of the "Triage": Dominique-Jean Larrey (1766–1842), Napoleon's Chief Military Doctor [in German]. *Pneumologie* 2022;76(05):365–369
- 77 Vernet. RIMBAUD. Syndrome condylo-déchiré postérieur. *Société Med Chir*; 1918
- 78 Collet FJ. Sur un nouveau syndrome paralytique pharyngo-laryngé par blessure de guerre (hémiplegie glosso-laryngo-scapulo-pharyngée). *Lyon Med* 1915;•••:121–129
- 79 Sicard A. Syndrome du carrefour condylo-déchiré postérieur (type pur de paralysie des quatre derniers nerfs crâniens). *Mars Med* 1917;•••:385–397
- 80 Villaret. Le syndrome nerveux de l'espace rétro-parotidien postérieur. *Rev Neurol (Paris)*; 1916
- 81 Ayeni SA, Ohata K, Tanaka K, Hakuba A. The microsurgical anatomy of the jugular foramen. *J Neurosurg* 1995;83(05):903–909
- 82 Tummala RP, Coscarella E, Morcos JJ. Surgical anatomy of the jugular foramen. *Oper Techniq Neurosurg* 2005;8:2–5

- 83 Beucler N, Boissonneau S, Ruf A, Fuentes S, Carron R, Dufour H. Crossed brainstem syndrome revealing bleeding brainstem cavernous malformation: an illustrative case. *BMC Neurol* 2021;21(01):204
- 84 Jorquera Moya M, Merino Menéndez S, Porta Etessam J, Escribano Vera J, Yus Fuertes M. Cranial nerve disorders: clinical manifestations and topography. *Radiología (Engl Ed)* 2019;61(02):99–123
- 85 Karnofsky DA, Abelmann WH, Craver LF, Burchenal JH. The use of the nitrogen mustards in the palliative treatment of carcinoma. With particular reference to bronchogenic carcinoma. *Cancer* 1948;1:634–656
- 86 Sperduto PW, Kased N, Roberge D, et al. Summary report on the graded prognostic assessment: an accurate and facile diagnosis-specific tool to estimate survival for patients with brain metastases. *J Clin Oncol* 2012;30(04):419–425
- 87 Beucler N, Haikal C, Sellier A, May A, Meyer M, Fuentes S. Far-lateral approach for foramen magnum meningioma: an anatomical study with special reference to bulbopontine junction. *Asian J Neurosurg* 2022;17(04):656–660
- 88 Bruneau M, George B. Foramen magnum meningiomas: detailed surgical approaches and technical aspects at Lariboisière Hospital and review of the literature. *Neurosurg Rev* 2008;31(01):19–32, discussion 32–33
- 89 Chibbaro S, Mirone G, Makiese O, Bresson D, George B. Dumbbell-shaped jugular foramen schwannomas: surgical management, outcome and complications on a series of 16 patients. *Neurosurg Rev* 2009;32(02):151–159, discussion 159
- 90 Makiese O, Chibbaro S, Marsella M, Tran Ba Huy P, George B. Jugular foramen paragangliomas: management, outcome and avoidance of complications in a series of 75 cases. *Neurosurg Rev* 2012;35(02):185–194, discussion 194
- 91 Johnson J, Barani JJ. Radiotherapy for malignant tumors of the skull base. *Neurosurg Clin N Am* 2013;24(01):125–135
- 92 Anderson PA, Montesano PX. Morphology and treatment of occipital condyle fractures. *Spine* 1988;13(07):731–736
- 93 Hu Y, Yuan Z-S, Kepler CK, Dong W-X, Sun X-Y, Zhang J. Comparison of occipitocervical and atlantoaxial fusion in treatment of unstable Jefferson fractures. *Indian J Orthop* 2017;51(01):28–35
- 94 Noble ER, Smoker WR. The forgotten condyle: the appearance, morphology, and classification of occipital condyle fractures. *AJNR Am J Neuroradiol* 1996;17(03):507–513
- 95 Bontinis V, Antonopoulos CN, Bontinis A, et al. A systematic review and meta-analysis of carotid artery stenting for the treatment of cervical carotid artery dissection. *Eur J Vasc Endovasc Surg* 2022;64(04):299–308
- 96 Sultan S, Hynes N, Acharya Y, Kavanagh E, Jordan F. Systematic review of the effectiveness of carotid surgery and endovascular carotid stenting versus best medical treatment in managing symptomatic acute carotid artery dissection. *Ann Transl Med* 2021;9(14):1212
- 97 Nepal G, Kharel S, Bhagat R, et al. Safety and efficacy of Direct Oral Anticoagulants in cerebral venous thrombosis: a meta-analysis. *Acta Neurol Scand* 2022;145(01):10–23
- 98 Ramina R, Maniglia JJ, Fernandes YB, Paschoal JR, Pfeilsticker LN, Coelho Neto M. Tumors of the jugular foramen: diagnosis and management. *Neurosurgery* 2005;57(1, Suppl):59–68