

The technical success of expandable stent placement in the upper gastrointestinal tract (76–100%) [1] and in the colon (83–100%) [1,2] mainly depends on the ability to pass a hydrophilic-coated guide wire through the tumor [3,4]. In the standard technique, if it is not possible to pass the lesion with the endoscope, a hydrophilic biliary guide wire preloaded into a standard biliary catheter is used to traverse the stricture [1–4]. However, this type of catheter does not allow selective alteration of the angle of the guide wire. The present report describes stenting in one case of esophageal neoplasm with an esophagotracheal fistula, and in three cases of obstructive colonic adenocarcinoma, with the help of a rotatable sphincterotome (Autotome Rx, Boston Scientific, Natick, Massachusetts, USA) – a new use for this device that has not previously been described.

In the patient with an esophageal neoplasm, a guide wire preloaded into a standard catheter repeatedly passed into the bronchial branch of an esophagotracheal fistula. In the patients with obstructive colonic adenocarcinoma, the stenoses were located in an angle, so that it was not possible to position the endoscope and the standard catheter directly in front of the lesion (Figure 1). This made it impossible to pass the wire through the lumen of the tumor. Using a 0.035-inch hydrophilic guide wire (Terumo, Tokyo, Japan) preloaded into the Autotome Rx and changing the direction of the tip at the edge of the stenosis by bending and/or rotating the sphincterotome, it became possible to pass the guide wire through the stenoses in all four of these cases (Figure 2).

Rotation of a conventional sphincterotome was recently described as a method for selective intrahepatic cannulation during endoscopic retrograde cholangiopancreatography [5]. The modification of the standard technique for stenting malignant digestive tract stenoses described here, using a rotatable sphincterotome in-

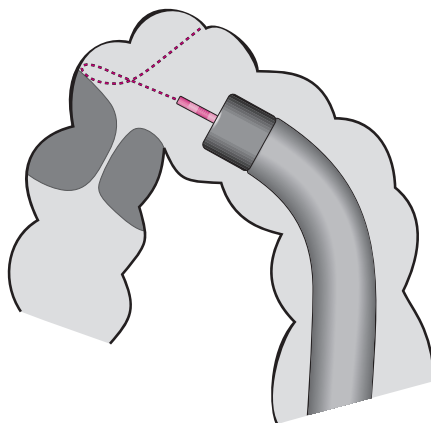


Figure 1 When a stenosis is located in an angle, it is not possible to position the endoscope and the standard catheter directly in front of the lesion.

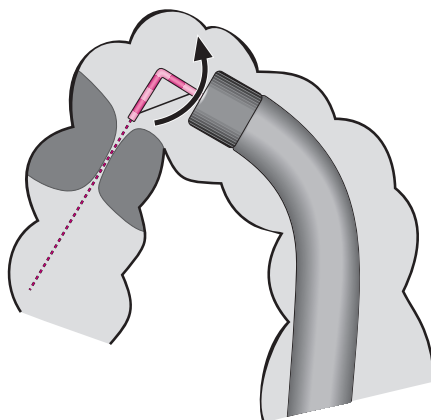


Figure 2 The lumen of the neoplasm can be successfully targeted by bending and/or turning the rotatable sphincterotome.

stead of a biliary catheter, has not previously been described, so far as we are aware. The technique may help achieve technical success with this procedure in selected difficult cases.

L. Rosés, A. González Ramírez, A. Lancho Seco, S. Soto Iglesias, E. Santos Blanco, S. Ávila

Digestive Disease Unit, Xeral Hospital, Lugo, Spain.

References

- 1 Baron TH, Harewood GC. Enteral self-expandable stents. *Gastrointest Endosc* 2003; 58: 421–433
- 2 Chevalier P, Baque P, Benchimol D et al. Treatment of colorectal obstruction with self-expanding metallic stents under fluoroscopic guidance. *J Radiol* 2002; 83: 473–477
- 3 Baron TH, Rey JF, Spinelli P. Expandable metal stent placement for malignant colorectal obstruction. *Endoscopy* 2002; 34: 823–830
- 4 Keymling M. Colorectal stenting. *Endoscopy* 2003; 35: 234–238
- 5 Moxon DR, Hong K, Brown RD, Venu RP. Selective intrahepatic ductal cannulation during ERCP with a sphincterotome. *Gastrointest Endosc* 2003; 57: 738–743

Corresponding Author

A. González Ramírez, M.D.

Digestive Disease Unit, Xeral Hospital
C/Campos Novos, no. 116 4º L
27002 Lugo
Spain
Fax: +34-982-296671
E-mail: seanlugo@hotmail.com