

# Henoch-Schönlein purpura in an elderly patient with unusual manifestation

# UCTN

An 81-year-old man was admitted to the hospital with hematochezia and ascites, but with no abdominal pain or skin rash. Colonoscopy revealed a circumferential ulcer with marked edema in the terminal ileum (Figure 1a). Duodenoscopy also showed multiple ulcers in the duodenum (Figure 1b). Histological examination of biopsy specimens indicated nonspecific inflammation. Paracentesis yielded hemorrhagic fluid, with no malignant cells and no growth of pathogens. A definite diagnosis could not be established initially, and the patient was treated conservatively.

On hospital day 8, palpable purpuric lesions abruptly developed at both extremities, hematochezia progressed, and renal function rapidly worsened. On the basis of these findings, Henoch-Schönlein purpura was diagnosed clinically, and was pathologically confirmed several days later (Figure 2). Despite intensive treatment, including methylprednisolone pulse therapy, the patient's condition progressively deteriorated and he died on day 13.

Autopsy revealed massive hemorrhagic ascites and coagulated blood in the gastrointestinal tract. The mucosa in both the duodenum and the ileum was extensively peeling, but interestingly, the jejunal and colonic mucosa was intact (Figure 3). Immunohistochemistry demonstrated IgA depositions on the small vessels of the bowel wall, including not only the duodenum and the ileum, with extensive ulcers, but also the jejunum, with a normal appearance.

The presence of characteristic purpura can facilitate the diagnosis of Henoch-Schönlein purpura, but the diagnosis is more difficult when other manifestations of the disease precede the purpura [1–4]. In the present patient, it was difficult to obtain a final diagnosis of Henoch-Schönlein purpura, as the case had the following unusual in characteristics: old age at onset, delayed appearance of characteristic

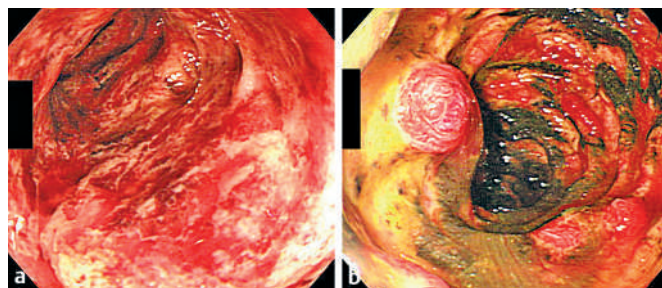


Figure 1 Endoscopic views. **a** Colonoscopy, showing a circumferential ulcer with marked edema in the terminal ileum. **b** Duodenoscopy, showing multiple ulcers in the second part of the duodenum.

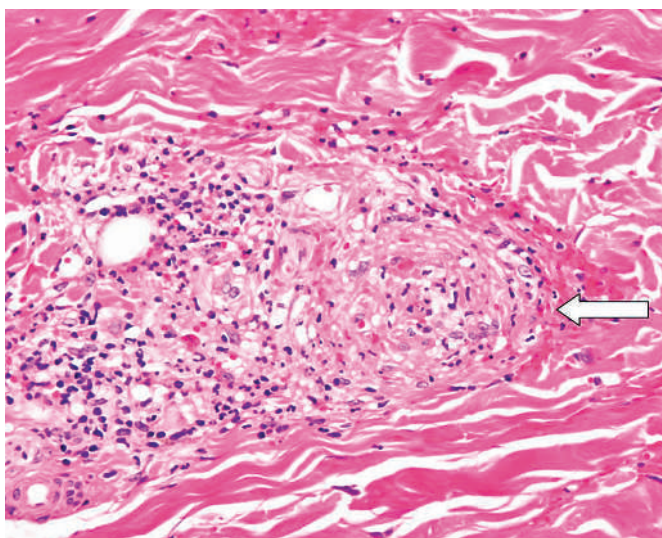


Figure 2 A microscopic view of the skin. Hematoxylin-eosin stain, showing leukocytoclastic vasculitis (arrow), which is representative of Henoch-Schönlein purpura.

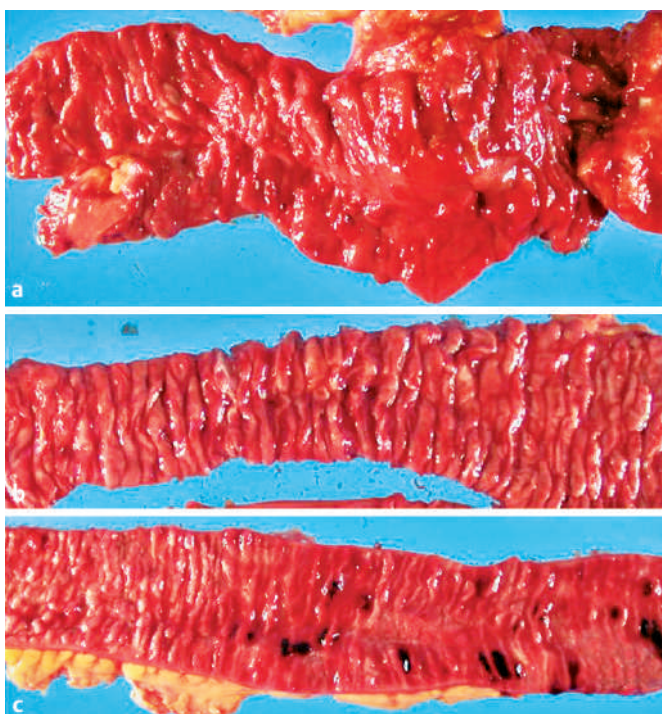


Figure 3 Macroscopic views of the gastrointestinal tract at autopsy. **a** Multiple ulcers were observed in the duodenum. **b** The jejunal mucosa was intact. **c** The mucosa in the ileum was extensively peeling, with pseudopolyps.

DOI: 10.1055/s-2006-945022

purpura, an absence of abdominal pain, and the presence of hemorrhagic ascites. The patient also had an unusual distribution of gastrointestinal lesions, with the jejunum being spared despite systemic vasculitis. However, the reason for the absence of the jejunal lesions is not clear.

Endoscopy\_UCTN\_Code\_CCL\_1AD\_2AF  
Endoscopy\_UCTN\_Code\_CCL\_1AB\_2AZ\_3AD

**N. Uza<sup>1</sup>, S. Yazumi<sup>1</sup>, K. Tanabe<sup>1</sup>, Y. Endo<sup>1</sup>,  
Y. Kodama<sup>1</sup>, Y. Matsumura<sup>2</sup>,  
H. Sakashita<sup>3</sup>, T. Chiba<sup>1</sup>**

<sup>1</sup> Dept. of Gastroenterology and Hepatology

<sup>2</sup> Dept. of Dermatology

<sup>3</sup> Dept. of Pathology, Graduate School of Medicine, Kyoto University, Kyoto, Japan.

## References

- <sup>1</sup> Saulsbury FT. Henoch-Schönlein purpura. *Curr Opin Rheumatol* 2001; 13: 35–40
- <sup>2</sup> Godkin A, Thompson M, Summerfield J. Abdominal pain and melaena: an unusual cause. *Lancet* 2000; 356: 562–563
- <sup>3</sup> Kim HS, Lee DK, Baik SK et al. Ileal vasculitis in Henoch-Schönlein purpura. *Gastrointest Endosc* 2001; 54: 493–494
- <sup>4</sup> Sasaki K, Nukuda Y, Masuda T et al. Endoscopically and histologically documented gastrointestinal lesions in an adult patient with Henoch-Schönlein purpura. *Endoscopy* 1994; 26: 629–630

## Corresponding author

**S. Yazumi, M.D., Ph.D.**

Dept. of Gastroenterology and Hepatology  
Kyoto University

Graduate School of Medicine  
Shogoin-Kawara-cho, Sakyo-ku  
Kyoto 606-8507

Japan

Fax: +81-75-751-4303

Email: yazoo@kuhp.kyoto-u.ac.jp