

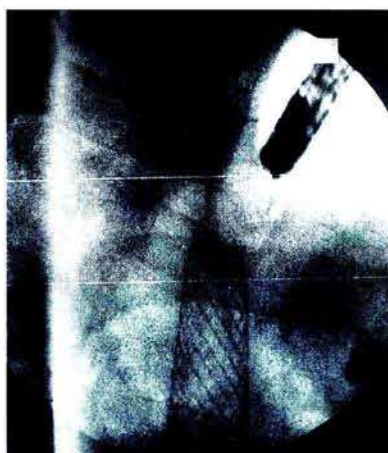
Proximal Closure of Esophageal Metal Stents

C. Steele, W. Dickey

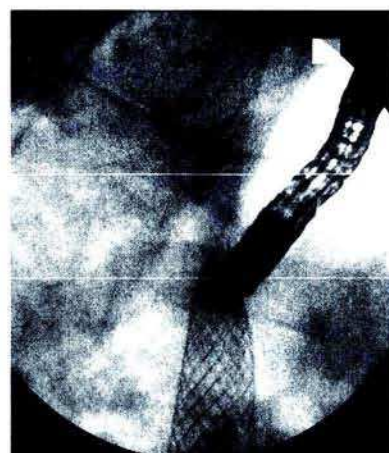
Department of Gastroenterology,
Altnagelvin Hospital, Londonderry,
Northern Ireland, UK

Corresponding Author

Dr. W. Dickey
Altnagelvin Hospital
Londonderry BT47 1SB
Northern Ireland
United Kingdom
Fax: +44-1504-611218



After a metal stent (Wallstent, Schneider [Europe] AG, Bulach, Switzerland) was placed across an esophageal adenocarcinoma, the patient's dysphagia initially improved but recurred 10 days later. Food had wedged between the stent's upper end and the esophagus. Because of esophageal angula-



tion, food approached the stent obliquely (Figure 1), with external impaction and luminal compression (Figure 2). Food removal and a second stent, proximally overlapping the first, solved the problem. We have seen two such cases. Esophageal angulation should be taken into consideration during stenting.