Published online: 2019-11-27

Review Article

Advanced skin, scar and wound care centre for children: A new era of care

Andrew Burd, Lin Huang

Department of Surgery, Division of Plastic, Reconstructive and Aesthetic Surgery, The Chinese University of Hong Kong, Prince of Wales Hospital, Hong Kong

Address for correspondence: Prof. Andrew Burd, Chief of Plastic, Reconstructive and Aesthetic Surgery, Department of Surgery, Prince of Wales Hospital, Hong Kong, E-mail: andrewburd@surgery.cuhk.edu.hk

ABSTRACT

Advanced wound care centres are now a well established response to the growing epidemic of chronic wounds in the adult population. Is the concept transferable to children? Whilst there is not the same prevalence of chronic wounds in children there are conditions affecting the integumentary system that do have a profound effect on the quality of life of both children and their families. We have identified conditions involving the skin, scars and wounds which contribute to a critical number of potential patients that can justify the setting up of an advanced skin, scar and wound care centre for children. The management of conditions such as giant naevi, extensive scarring and epidermolysis bullosa challenge medical professionals and lead to new and novel treatments to be developed. The variation between and within such conditions calls for a customizing of individual patient care that involves a close relationship between research scientists and clinicians. This is translational medicine of its best and we predict that this is the future of wound care particularly and specifically in children.

KEY WORDS

Children; scarring; wound care

BACKGROUND

The concept of advanced wound centres was popularized by Dr. Fin Gottrup from Denmark.[1] The traditional approach to wound care was that it was delivered by individual specialists and disciplines. Gottrup proposed to gather these specialists and disciplines together in a single team to deliver standardized protocol based treatment with optimal resource allocation. The team members would have specialized training. The centres would deliver a broad spectrum of wound care and through exposure to multiple cases develop expertise and credibility in advanced wound management. An important element of the treatment would be to demonstrate the cost-effective nature of interventions. Such an advanced wound care centre would have both inpatient and outpatient facilities. Finn Gottrup is from Denmark, a country of just over 5 million people. He estimates the prevalence of chronic wounds to be about 1% of the population; that is to say roughly 50,000-60,000 people in Denmark have chronic wounds and these can be managed in two wound healing centres.

The chronic wounds that Dr. Gottrup is talking about are those most often associated with degenerative or acquired diseases such as diabetes, venous hypertension or ischaemia. Notably a principle risk

Access this article online	
Quick Response Code:	Website: www.ijps.org
	DOI: 10.4103/0970-0358.101268

factor for developing chronic wounds is age! So where does this leave children? Do children get chronic wounds? Well yes they can and do and one of the most devastating inherited skin conditions affecting children is epidermolysis bullosa, particularly recessive dystrophic epidermolysis bullosa (RDEB). This is a rare condition and the prevalence is difficult to determine but has been calculated to be of the order of 1 in a million population. The contrast then, between chronic wounds in children and chronic wounds in adults is conspicuous when it come to numbers.

It is the number factor which is very relevant if considering whether the concept of an Advanced Wound Care Centre exclusively for children is economically viable. There can be few, if any, places in the world where such a model, as exemplified by the Adult Advanced Wound Care Centre, has been directly transferable to children. And yet there are conditions that severely affect the quality of life of children which could be treated in a similar setting of advanced specialist care. When such cases are grouped together they can reach a critical mass that renders such a concept cost-effective and economically viable. This then is the background to the concept of an Advanced Skin, Scar and Wound Care Centre specifically for children.

The concept is good but what about the funding? A Foundation was formed. The Hong Kong Children's Skin Foundation. A logo had to be quickly designed

Figure 1: The logo depicting a father, mother and baby in simple brush strokes

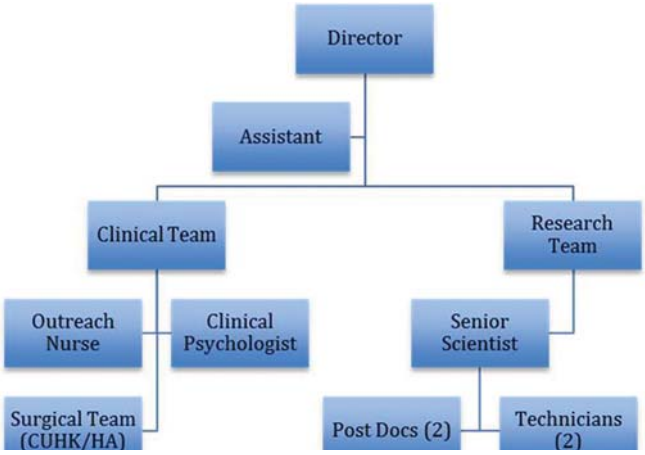

Figure 2 : The organizational structure of the centre

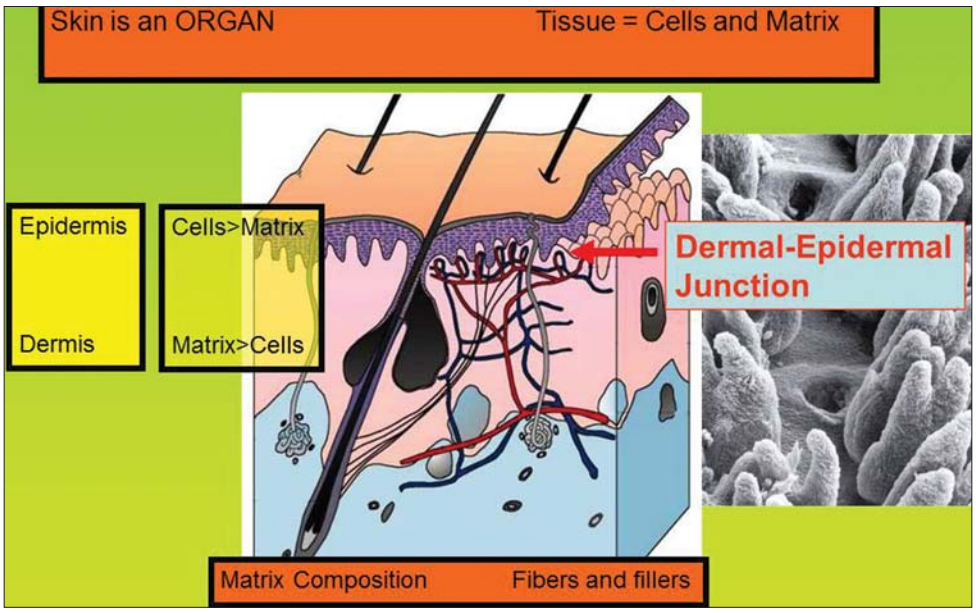

Figure 3: The conceptual simplicity of the skin belies a biological complexity

for invitation to a fund raising event [Figure 1]. And so the goal was announced publically and can be seen in Figure 2. What is important here is that the team is evenly balanced between clinical and laboratory based scientists delivering individualized, specialized care to children with rare or debilitating, physically or psychologically, skin conditions that severely impair the child's quality of life.

SKIN

Human skin is the most remarkable biomaterial in the universe. The conceptual simplicity, i.e. a two layer structure comprising epidermis and dermis belies the unfathomable biological complexity of the largest organ in the body. The ectodermally derived epithelial layer can be identified early in foetal development and the integrity of this layer, the epidermis, is essential for survival. It is obvious that as skin covers our bodies throughout intrauterine and post-natal life that it must be continually adapting and changing in response to growth, the environment and age. Skin is a multi-functional organ and key elements of protection are served by the stratum corneum, the layer of dead cells that sustain human life. The structural arrangement of the epidermis represents a gradient of metabolic activity with intracytoplasmic changes in the terminally differentiating keratinocyte arising from the transit amplifying cells lying on the basement membrane [Figure 3]. The epidermis is mechanically weak and the major contribution of the structural integrity and remarkable biomechanical properties of the skin are provided by the dermis. The dermis is comprised mainly of the fibrillar protein, collagen and elastin together

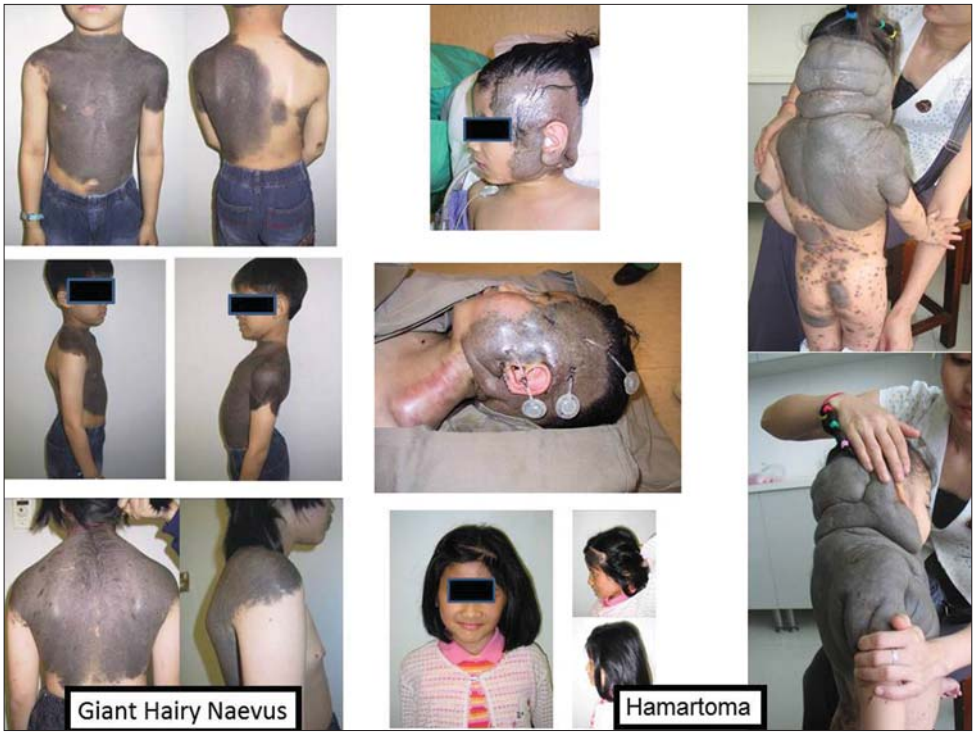

Figure 4: The two children on the left have grant hairy naevae; the two on the right have hamartomas

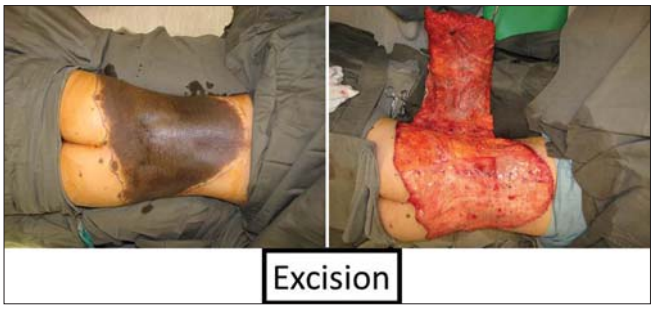

Figure 5: A giant hairy naevus involving 18% body surface area is excised

Figure 6: Needle point, hand held, cantery with suction tube attached (Ref 2)

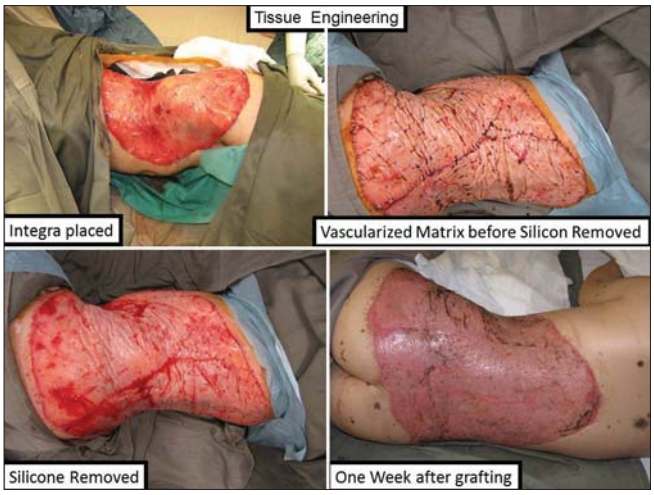

Figure 7: The stages of Integra application

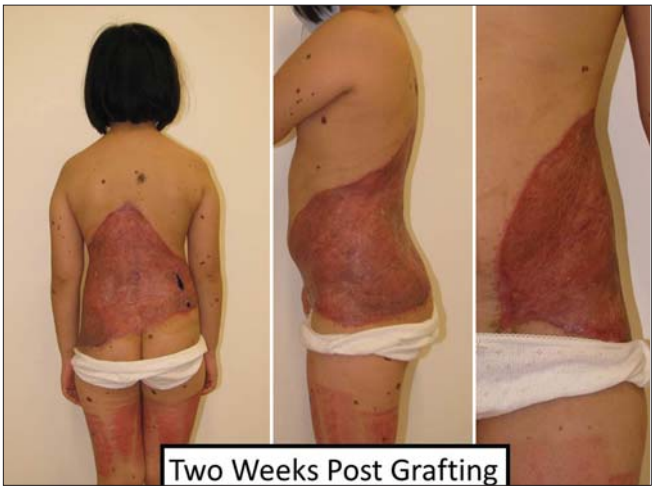

Figure 8: Early appearance of reconstructed skin

Figure 9: Late appearance of reconstructed skin

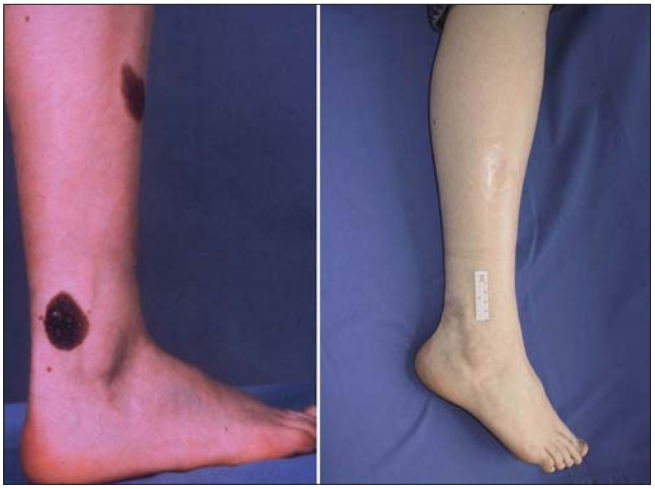

Figure 10: A six year follow up of the world's first case where Integra was used for a non-burn related application

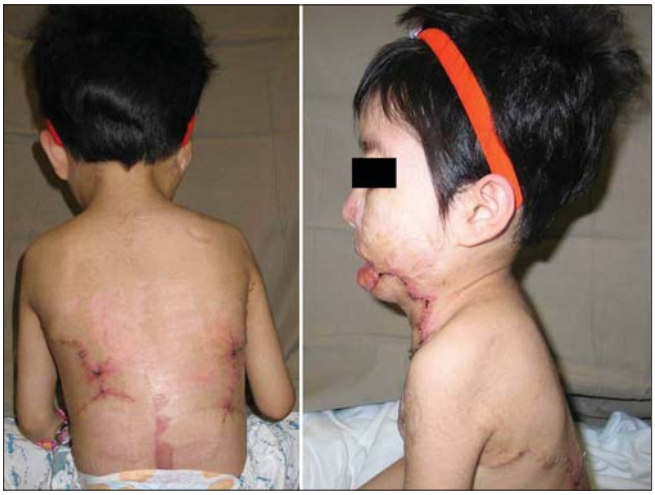

Figure 11: Bilateral pedicled LD flaps

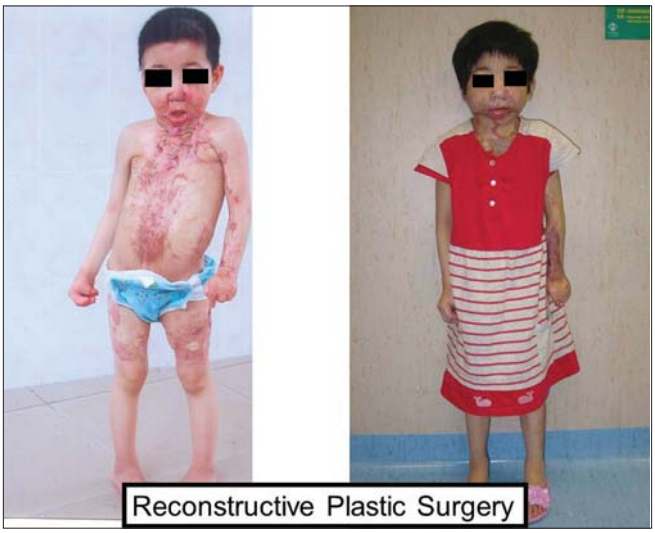

Figure 12: Deformity and disability

with a non-fibrillar extracellualr matrix of proteo-glycans and glycosamino-glycans. The morphological structure of the dermis allows for stretching and recoil which gives the skin remarkable elastic properties that can be appreciated by observing the skin on the hands as a fist is clenched and unclenched. There are cells within the dermis, mainly fibroblasts but in addition there are blood vessels and sensory endorgans. The epidermis also invades the dermis with ectodermally derived structures that contribute to the structure and function of the skin. Sweat glands play a role, albeit minor, in thermoregulation and also play some part in excretion and water and electrolyte balance. Sebaceous glands produce sebum, a predominantly triacylglycerol secretion that has lubricating and antibacterial actions. Hair follicles occur in skin from all parts of the body apart from the glaberous areas; palms, soles, lips and labia minora and glaun penis. Hair is a highly diverse biological feature again with multiple biological, functions and diverse cultural significance.

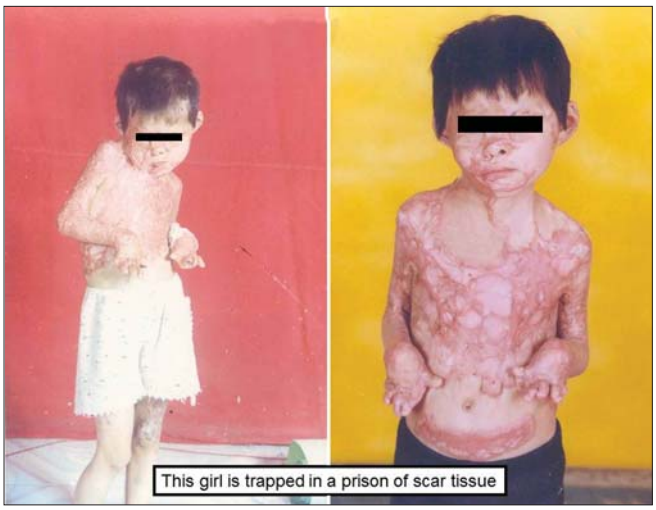

Figure 13: Standing tall and happy

And then we have this incredible molecular assembly that joins the epidermis to the dermis forming the dermal epidermal junction (DEJ).

When looking at the discipline of paediatric dermatology it is evident that a vast array of congenital and acquired anomalies arise which can seriously affect a child and indeed their families, quality of life. In the context of the centre proposed the majority of paediatric skin problems can be very effectively managed with creams, lotions, emollients and other non-surgical strategies. It is also evident that many surgically related congenital anomalies or pathology affecting the skin can be most adequately treated by paediatric and/or plastic surgeons. Figure 4 shows four children with extensive areas of darkly pigmented skin. In two of the children the skin only is involved and the diagnosis in each case is a giant

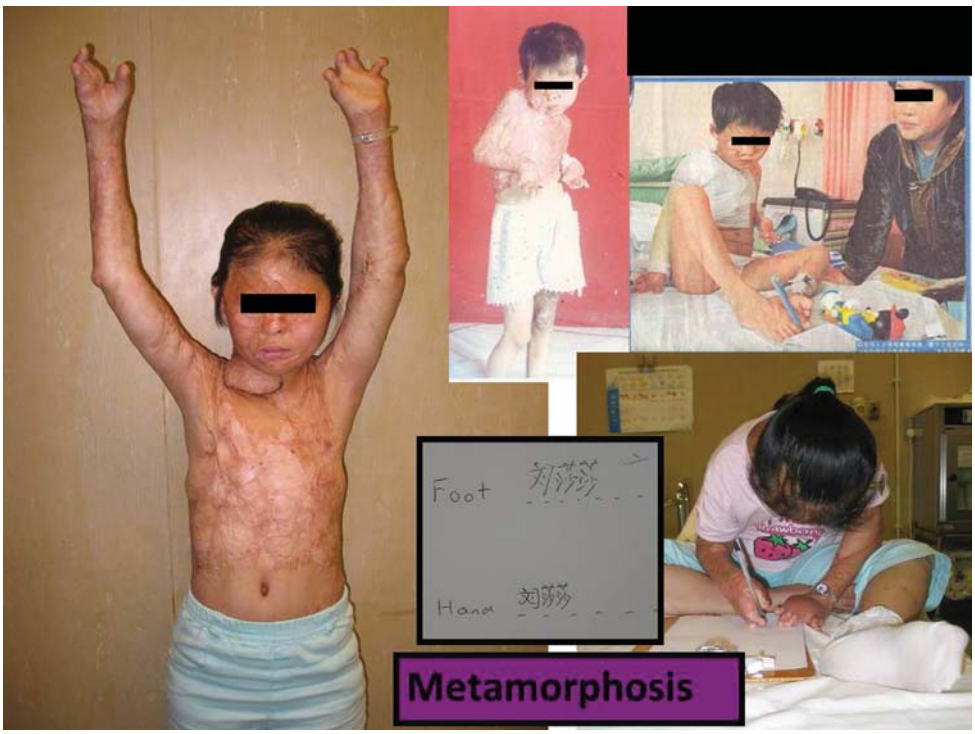

Figure 14: Metamorphosis combines surgery, tissue engineering tissue expansion and stem cell applications

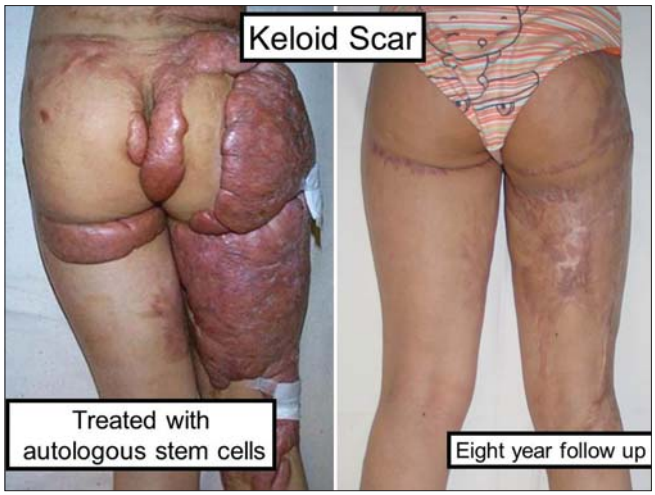

Figure 15: Keloid scar post burn

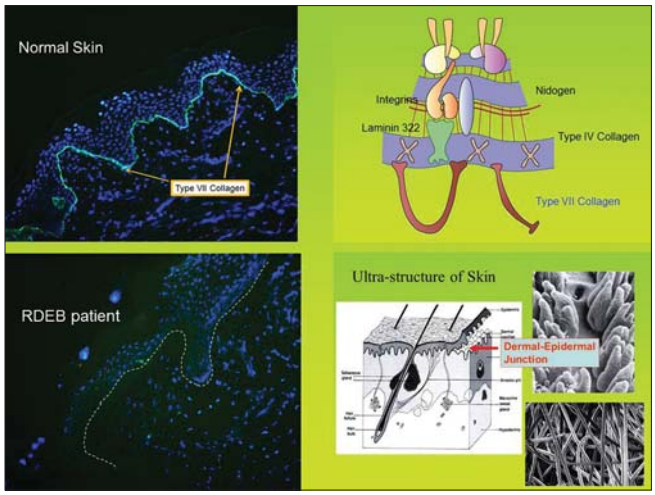

Figure 16: Type VII collagen-essential for healthy skin

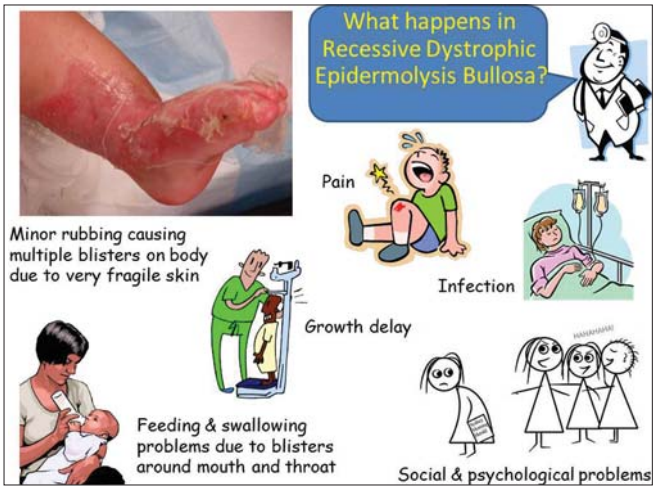

Figure 17: A medical student illustrates the clinical problems in RDEB

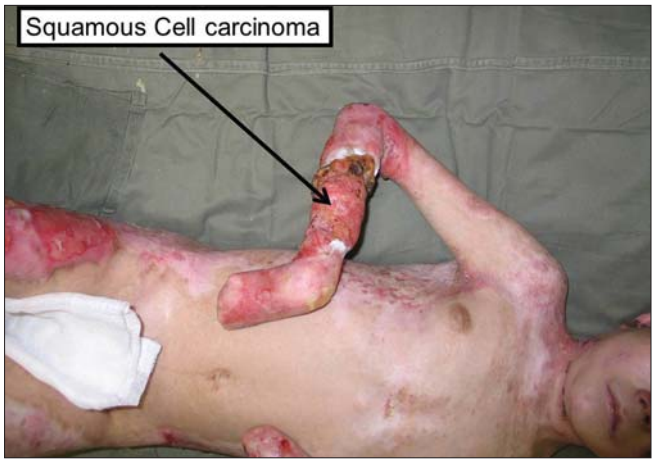

Figure 18: Squamous cell carcinoma

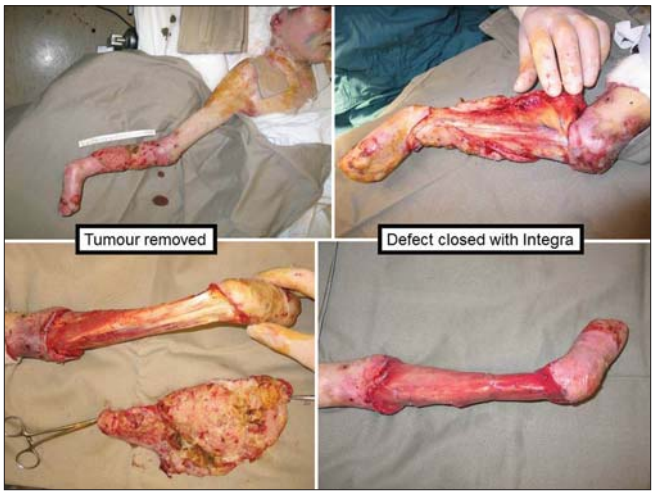

Figure 19: Excise and reconstruct with Integra

hairy naevus. In the other two cases deeper tissues and structures are also abnormal and the diagnosis is hamartoma. The girl with the hamartoma affecting her face has been treated with tissue expansion. This technique has been used in clinical plastic surgery for over a quarter of a century and yet the fundamental biology of tissue expansion remains a mystery. New tissue is generated but the stimulus and signalling process are unclear. This is just one example of where clinical plastic surgery is operating far in advance of scientific understanding.

Another example is in the clinical application of tissue engineered products. Figure 5 shows an extensive naevus affecting the back and left flank. Excision is performed using a needle tipped unipolar diathermy set on coagulation mode. Using a slow and meticulous technique that uses electrical arcing rather than physical contact a large bloodless field can be created with minimal deposits of charred tissue. The periphery has been infiltrated with lignocaine and adrenaline solution and the margin of the lesion incised with a knife

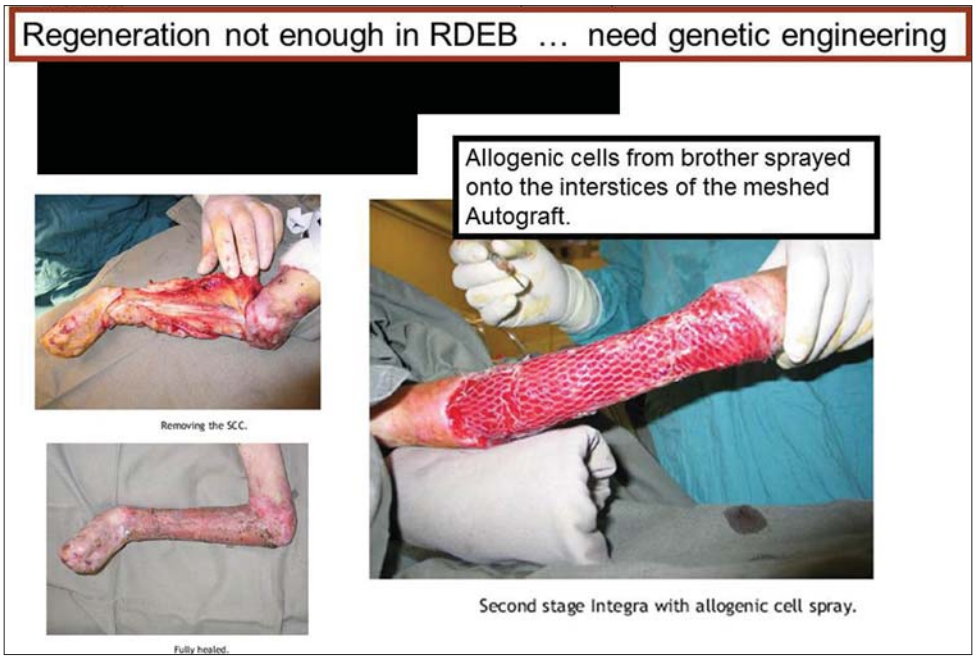

Figure 20: Allogenic cells and autogenous meshed skin produce disable new skin

Different strategies to replace the abnormal collagen VII in EB patient:

Gene therapy - That is to use a virus to carry the correct type VII collagen gene into sking cells of RDEB patients.

Protein therapy - That is to inject type VII collagen protein into the dermis to restore the function.

Cell therapy - Which the intradermal injection of allogenic fibroblasts has been first developed.

Figure 21: Strategies to treat RDEB

down to the deep dermal layer. Further excision has been performed by the diathermy to prevent bleeding. The diathermy has been described previously in the Indian Journal of Plastic Surgery[2] and incorporates suction to remove the carcinogenic smoke [Figure 6].

Again Plastic Surgery leads the surgical specialties in the clinical application of tissue engineered products. This patient is having the defect reconstructed with a dermal regeneration template, Integra [Figure 7]. This is a stage process with the application of the tissue engineered material, the biodegradation of the engineered matrix and its replacement with autologous collagen which is covered with a very thin autologous skin graft. Figure 8 shows the progress at two weeks. Figure 9 shows another patient who had a giant hairy naevus of the right lower leg removed one year before. The appearance of the reconstructed leg is very acceptable although there is still room for improvement. The new skin, for example does not contain appendageal structures and this again is a focus of laboratory research. There are great prospects

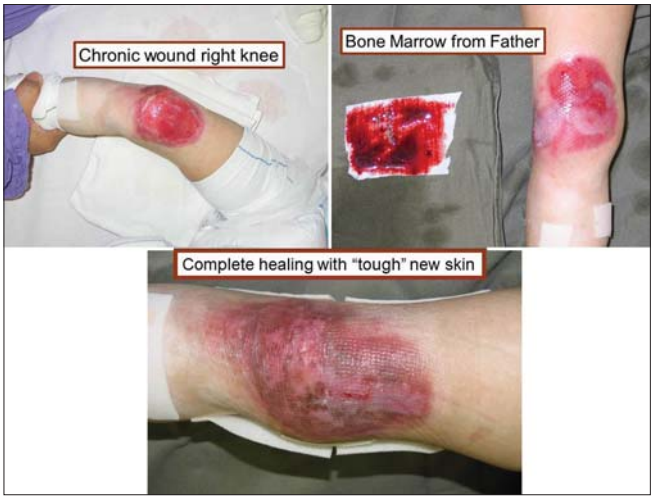

Figure 22: Using the father's bone marrow to aid healing of a wound in a patient with RDEB

for combing tissue engineering a stem cell product in the future. Of interest the first case where Integra was used in Reconstructive Plastic Surgery rather than Acute or Reconstructive Burns Surgery involved a child with a suspicious pigmented naevus on her right lower leg.[3] Figure 10 shows the six year follow up of that patient. It is evident that there will be new and exciting developments in the field of Cell and Tissue Engineering in the future.

SCAR

A scar is the result of natures attempt to repair a disruption in the extracellular matrix in an organ or tissue. Scarring is

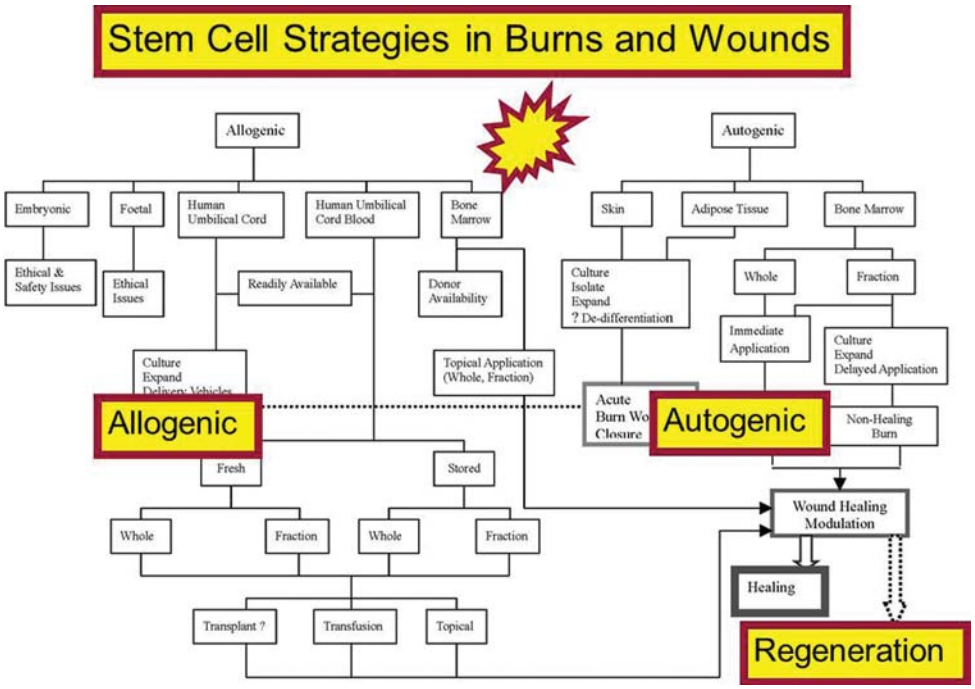

Figure 23: A strategy for stem cells

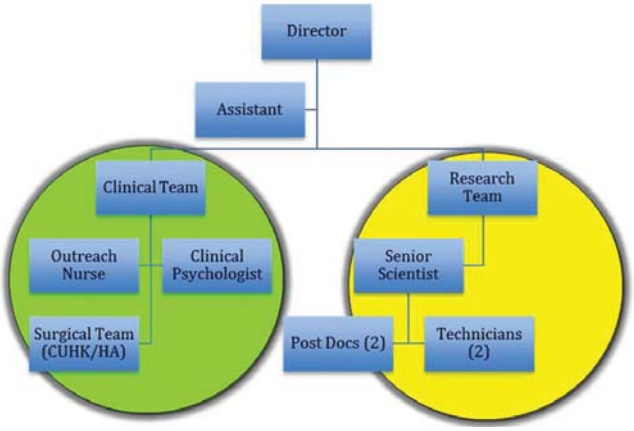

Figure 24: Translational medicine means individualized care. Clinical and Research teams' work together to achieve solutions

very evident in the skin and can cause significant functional disability as well as distressing deformity [Figure 11]. Reconstructive plastic surgery can do a great deal to help in restoring form and function [Figures 12 and 13]. However to achieve what we describe as metamorphosis for children whose lives are seriously affected, being prisoners within their walls of scar tissue, the route to freedom can be long and complex. The girl depicted in Figure 14 needed long term planning to create new tissue for reconstructive surgery[4] and illustrates the long term view of reconstruction and 'scar wars'. Other forms of scarring do occur and we have previously postulated that one day the approach to keloid scarring will be to undertake a biomolecular characterization of the scar and individualize the treatment.[5] Our experience of using stem cell rich cell culture to treat keloids have been previously reported[6] and Figure 15 shows the eight year follow up of our original case.

But why focus on scarring? On April 26th 1981 the first open human fetal surgical procedure was performed in San Francisco. An amazing observation from those early procedures was that human fetal surgical wounds heal without scarring. This opened up a whole new emphasis in biomedical research the pursuit of scarless healing or regeneration. Such research clearly falls within the scope of such a centre.

CHRONIC WOUNDS

The third category of patient we would aim to treat in this centre are children who do have chronic, recurring and disabling wounds. There is no condition that illustrates the devastation to the quality of life as much as recessive dystrophic epidermolysis bullosa. The key problem is the lack of normal collagen type VII which is an integral part of the dermo-epidermal junction [Figure 16]. Without this functioning component, the epidermis is not attached to the dermis in a robust manner and can easily be dislodged by shearing forces. Repeated blistering and wounds occur [Figure 17]. We treated one child with an

aggressive squamous cell carcinoma complicating his disease [Figure 18].[7] In the course of this treatment we used Integra [Figure 19] and a combination of meshed autograft and a spray of cultured allograft grown from the patient's younger brother. This case illustrates that the Holy Grail of the Plastic Surgeon 'regeneration' is not enough. We need to find ways to manipulate the patients cells which will ultimately involve genetic engineering[8] [Figure 20]. One year later we used the same strategy for an axillary recurrence and noted rapid and robust healing in the area treated with the allogenic cells. There was no evidence of prior immunological stimulation.

Of note there is currently no cure for recessive dystrophic epidermolysis bullosa and all that can be done is to manage the condition with advanced wound dressings, nutritional support and life style adaptation. There are experimental strategies to replace the abnormal collagen VII but these remain in the trial stages in various centres [Figure 21].

Another observation we can report is the use of allogenic bone marrow to aid the healing in an RDEB patient [Figure 22]. We have previously reviewed stem cell strategies in burn and wounds [Figure 23] and looking at allogenic sources we are most attracted to the intra-uterine 'life support system' – the amoniotic membranes, the placenta and the umbilical cord and cord blood.[9] These are abundant in supply, ethically acceptable and safe (after appropriate screening) and can provide both allogenic and autogenic cells. We have been looking at the stem cells derived from the human umbilical cord and the potential for epithelial reconstitution.[10] This the work in the laboratory is directed and driven by the clinical need. So the proposed Advanced Skin Scar and Wound Care Centre for children will be an example of the future trend in clinical medicine – translational medicine [Figure 24].

Our hope is that by delving deeply into the fundamental biology of a relatively small number of children we can learn for more about conditions that affect all age groups. So our immediate goal is to improve the quality of life of severely distressed children but ultimately we hope to make a significant contribution to improving the quality of life of the many millions of people (adults) who suffer particularly from chronic wounds. If Dr. Gottrup is correct that Figure should be in excess of 700 lakhs world wide.

REFERENCES

1. Gottrup F. A specialized wound-healing center concept: importance of a multidisciplinary department structure and surgical treatment facilities in the treatment of chronic wounds. Am J Surg 2004;187:38S-43S.
2. Wai SC, Hong RC, Burd A. Suction diathermy. Indian J Plast Surg 2007;40:239-40.
3. Burd A. The role of serendipity in the evolving indications for Integra™ dermal regeneration template. Plast Reconstr Surg 2002;109:1764-6.
4. Burd A, Pang PC, Ying SY, Ayyappan T. Microsurgical reconstruction in children's burns. J Plast Reconstr Aesthet Surg 2006;59:679-92.
5. Burd A, Huang L. Hypertrophic response and keloid diathesis: Two very different forms of scar. Plast Reconstr Surg 2005;116:150e-157e.
6. Burd A, Chan E. Keratinocyte-keloid interaction. Plast Reconstr Surg 2002;110:197-202.
7. Burd A. RDEB: Regeneration is not enough. J Plast Reconstr Aesthet Surg 2008;61:1421-2.
8. Huang L, Burd A. Reconstruction in RDEB patients. Ann Plast Surg 2009;63:693.
9. Burd A, Ahmed K, Lam S, Ayyappan T, Huang L. Stem cell strategies in burns care. Burns 2007;33:282-91.
10. Huang L, Wong YP, Gu H, Cai YJ, Ho Y, Wang CC, *et al.* Stem cell-like properties of human umbilical cord lining epithelial cells and the potential for epidermal reconstitution. Cytotherapy 2011;13:145-55.

How to cite this article: Burd A, Huang L. Advanced skin, scar and wound care centre for children:A new era of care. Indian J Plast Surg 2012;45:184-92.

Source of Support: Nil, **Conflict of Interest:** None declared.