

## Case Report

Access this article online
Quick Response Code:

Website: www.jlponline.org
DOI: 10.4103/0974-2727.199622

# Surgical management of chronic hyperplastic candidiasis refractory to systemic antifungal treatment

Neha Shah, Jay Gopal Ray<sup>1</sup>, Sanchita Kundu, Divesh Sardana<sup>2</sup>

## Abstract:

Chronic hyperplastic candidiasis (CHC), earlier known as candidal leukoplakia, is a variant of oral candidiasis that classically presents as a white patch on the commissures of the oral mucosa and it is mostly caused by *Candida albicans*. Clinically, the lesions are usually asymptomatic and regress after appropriate antifungal therapy and correction of the underlying cause. If the lesions are untreated, a small portion may develop dysplasia and later progress into carcinoma. The purpose of this article is to report a case of CHC in a 57-year-old male patient with a significant smoking habit, who presented with a thick, non-scrapable, brownish-white coating on the dorsum of the tongue for 9 years. This case is of particular importance and concern because of the high risk for malignant transformation in CHC. The role of biopsy and histopathology is also stressed through this case report in arriving at a definitive diagnosis and treatment planning. Further, this case is interesting because it was refractory to local and systemic antifungal treatment and so, surgery was chosen as an alternative treatment modality considering the side effects of the prolonged use of antifungal drugs.

## Keywords:

Chronic hyperplastic candidiasis, malignant transformation, oral candidiasis, smoking, tongue

## Introduction

Oral candidiasis (OC) is one of the common infections encountered by the clinicians in the oral cavity, mostly caused by *Candida albicans*, which is a normal commensal of the oral cavity, skin, gastrointestinal tract, and genitourinary tract.<sup>[1-3]</sup> Pseudomembranous, erythematous, and chronic hyperplastic are the three types of primary OC, out of which chronic hyperplastic candidiasis (CHC) is the least common.<sup>[2,4,5]</sup> Although *Candida* is more frequently isolated from women, the highest prevalence of CHC is seen in middle-aged men who are smokers.<sup>[6]</sup> CHC is of two types: Homogeneous/plaque and nodular/speckled type. Homogeneous type presents as white plaque that cannot be scraped off and is usually asymptomatic. Speckled type presents as multiple white nodules on an erythematous background and may be associated with pain and burning sensation.<sup>[3,7]</sup> The most commonly affected site is the buccal commissure followed by buccal mucosa, palate, and tongue.<sup>[7,8]</sup> CHC is of particular significance and concern because of its reported association with malignant transformation; hence, biopsy is

mandatory for accurate diagnosis.<sup>[3,7,9,10]</sup> Various treatment modalities have been suggested for its management ranging from topical and systemic antifungal agents to surgical methods.<sup>[7]</sup>

## Case Report

A 57-year-old male patient reported to the Department of Oral and Maxillofacial Pathology of Dr. R. Ahmed Dental College and Hospital, Kolkata, with a chief complaint of a thick coating on the tongue causing discomfort for the past 9 years. His past medical history and family history were noncontributory. He consulted a local physician for his ailment and received several courses of topical and systemic medications including antifungal drugs, without much relief of symptoms. Thereafter, he was referred to our hospital for further management. The patient belonged to poor socioeconomic strata and was a chronic smoker with a history of smoking 1–2 bundles of beedi/day for 15–20 years. Extraoral examination did not reveal any abnormality. Intraoral examination of the patient revealed poor oral hygiene and the presence of thick, brownish-white coating intermixed with erythematous areas, measuring about 4 cm × 2.5 cm on the dorsal surface of the

Department of Oral and Maxillofacial Pathology, Guru Nanak Institute of Dental Sciences and Research, <sup>1</sup>Department of Oral and Maxillofacial Pathology, Dr. R. Ahmed Dental College and Hospital, Kolkata, West Bengal, <sup>2</sup>Department of Pedodontics and Preventive Dentistry, Centre for Dental Education and Research, All India Institute of Medical Sciences, New Delhi, India

## Address for correspondence:

Dr. Neha Shah,  
EC-11 Saltlake City,  
Sector-I,  
Kolkata - 700 064,  
West Bengal, India.  
E-mail: docneha10@gmail.com

Submission: 02-02-2016

Accepted: 11-07-2016

This is an open access article distributed under the terms of the Creative Commons Attribution-NonCommercial-ShareAlike 3.0 License, which allows others to remix, tweak, and build upon the work non-commercially, as long as the author is credited and the new creations are licensed under the identical terms.

For reprints contact: reprints@medknow.com

**How to cite this article:** Shah N, Ray JG, Kundu S, Sardana D. Surgical management of chronic hyperplastic candidiasis refractory to systemic antifungal treatment. J Lab Physicians 2017;9:136-9.

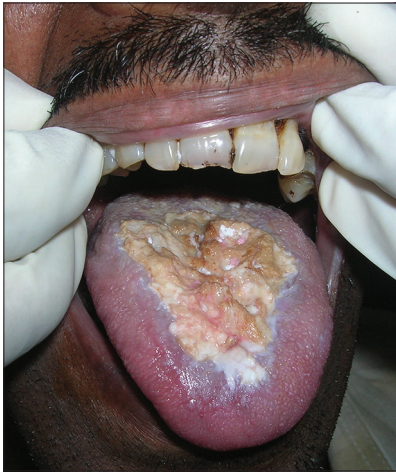tongue [Figure 1]. The lesion was raised, uneven, granular, and nodular at some places and homogeneous at other areas. The periphery of the lesion was white and merged with the normal mucosa of the dorsum of the tongue. It was nonscrapable, firm, and adherent to the underlying tissue. No similar lesion was present in other areas of the oral cavity including the palate. Based on the history and clinical examination, a provisional diagnosis of CHC was made. Differential diagnosis included oral leukoplakia, proliferative verrucous leukoplakia, oral hairy leukoplakia, hairy tongue, and malignancy. A complete hemogram was done, and all the values were found to be within the normal range. An incisional biopsy was performed and sent for histopathologic examination. Hematoxylin and eosin (H and E)-stained section showed the presence of hyperplastic stratified squamous epithelium with a thick layer of hyperparakeratinization on the surface [Figure 2]. Fungal hyphae were seen on the parakeratin layer [Figure 3]. There was an elongation of the epithelial rete ridges. The underlying connective tissue revealed a dense chronic inflammatory cell infiltrate chiefly comprising lymphocytes. Based on the histopathological examination, a final diagnosis of candidiasis

was concluded. Further, periodic acid-Schiff (PAS) staining was done to confirm the presence of candidal hyphae, which were stained magenta red [Figure 4].

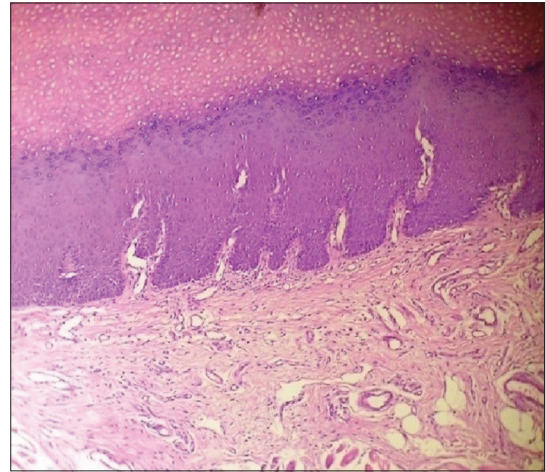
Subsequently, the patient was counseled to quit smoking habit and prescribed oral antifungal fluconazole 200 mg once daily along with topical antifungal clotrimazole five times daily for 2 weeks. Following the antifungal therapy, the lesion regressed substantially. However, nonscrapable, adherent, homogeneous white patches remained on the dorsum of the tongue [Figure 5]. Surgery was then done to excise the remaining adherent white patches from the dorsum of the tongue. No lesions were evident in the follow-up period of 6 months [Figure 6].

## Discussion

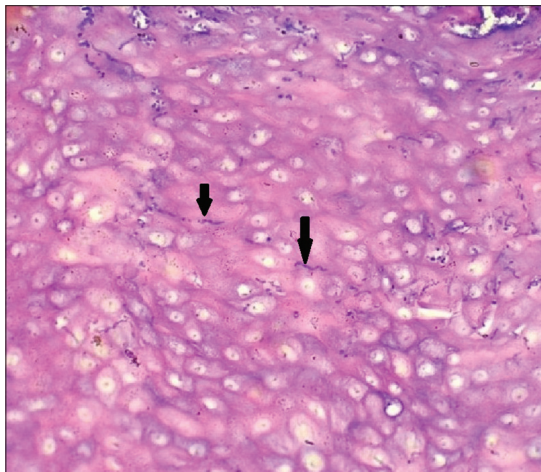
According to the proposed revised classification of OC by Axéll *et al.* in 1997, the important forms of primary OC are pseudomembranous, erythematous, and CHC.<sup>[2,5]</sup> CHC is the least common form of this opportunistic fungal infection.<sup>[2,4]</sup>



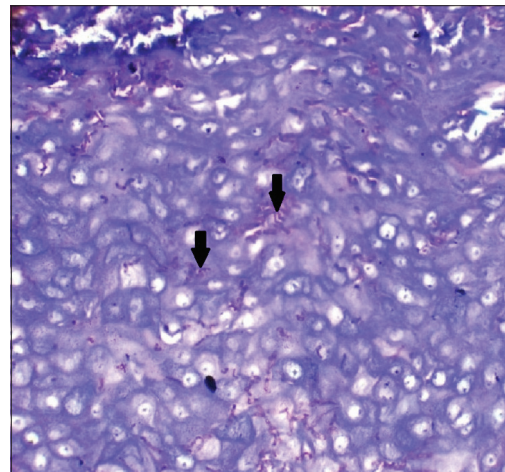
**Figure 1:** Intraoral photograph showing thick brownish-white coating on the dorsal surface of the tongue with bilateral involvement having uneven, raised, granular areas at some places and homogeneous white patches in the periphery



**Figure 2:** Low-power photomicrograph (H and E, ×10) showing hyperplastic epithelium with hyperparakeratosis and elongated rete ridges and chronic inflammation of the underlying connective tissue

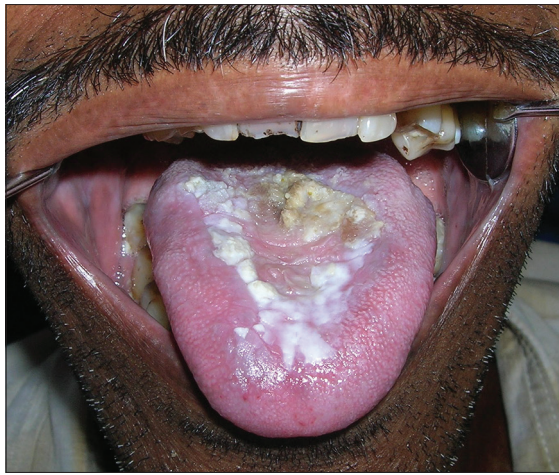

**Figure 3:** High-power photomicrograph (H and E, ×40) showing candidal hyphae (black arrows) in epithelium



**Figure 4:** High-power photomicrograph (PAS, ×40) showing candidal hyphae (black arrows) stained magenta red





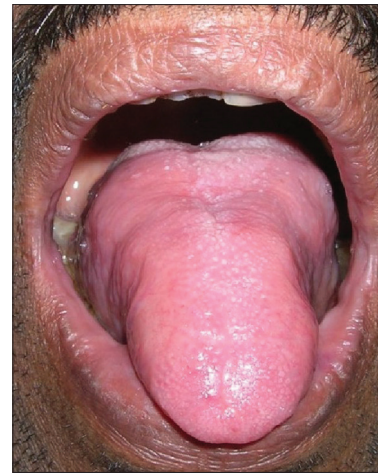**Figure 5:** Intraoral photograph showing partial resolution of the lesion 2 weeks after antifungal therapy

Cernea *et al.* and Jepsen and Winter in 1965 first reported that many oral leukoplakias were associated with *Candida* infection.<sup>[7,11,12]</sup> Mehta *et al.* reported 0.2–4.9% prevalence of oral leukoplakia in India.<sup>[13]</sup> Interestingly, 7–50% of the leukoplakias have been found to be associated with candidal hyphae.<sup>[7]</sup> Lehner first used the term “candidal leukoplakia” for leukoplakic lesions associated with chronic candidal infection. However, this term is no longer used; instead, it is designated as CHC.<sup>[7,10]</sup>

In the present case, a 57-year-old male patient with a significant smoking habit was diagnosed with CHC, which is in accordance with literature where it has been reported in age group from 31 years to 81 years, though most patients are above 50 years. Males are affected more frequently than females in a ratio of 2:1.<sup>[7]</sup> In our case, tongue was involved which is an unusual site for occurrence of CHC. The most common being buccal commissure followed by buccal mucosa and palate.<sup>[7,8]</sup>

Smoking has been recognized as the main risk factor associated with CHC.<sup>[2,14]</sup> Daftary *et al.* reported that 98% of the patients affected by CHC either smoked or chewed tobacco.<sup>[15]</sup> Shin *et al.* have reported a positive and direct association between smoking and candidal colonization.<sup>[16]</sup> It has been suggested that smoking favors candidal colonization by causing localized epithelial alterations such as increased epithelial keratinization and hydrophobicity. An alternative hypothesis states that smoking depresses the activity of polymorphonuclear leukocytes and reduces gingival exudate, thereby decreasing the number of leukocytes and salivary immunoglobulin A levels which, in turn, are important in inhibiting the candidal colonization in the oral cavity.<sup>[1,7]</sup>

Both homogeneous/plaque and nodular/speckled type of CHC can progress to moderate-to-severe dysplasia or even malignancy.<sup>[3,4,8-10,14]</sup> It has been reported that up to 15% of the CHC lesions may progress to dysplasia.<sup>[7]</sup> Although the role of *Candida* in oral carcinogenesis is not well established, *in vitro* studies have reported the production of carcinogenic nitrosamine, *N*-nitrosobenzylmethylamine, by *Candida* from precursors.<sup>[6,10]</sup> In 1989, Field *et al.* postulated that the



**Figure 6:** Intraoral photograph showing follow-up of the patient after 6 months

nitrosamine produced by *Candida* may directly or along with other carcinogens, activates specific proto-oncogenes responsible for carcinogenesis.<sup>[17]</sup> In addition, the expression of p53 tumor suppressor gene in cases of CHC has been studied, thereby linking the association of CHC with epithelial dysplasia or malignancy.<sup>[7]</sup>

Mere presence of *Candida* in the oral cavity is not indicative of infection, since it is a common inhabitant in this location being present in around 40–60% of the normal individuals.<sup>[1]</sup> Definitive diagnosis of OC requires the confirmation of tissue invasion by *Candida*. Hence, biopsy which is considered the gold standard for diagnosis is a must, since the nonscrapable white plaques of CHC are most often confused with leukoplakia clinically.<sup>[9]</sup> In our case too, biopsy guided in establishing the confirmatory diagnosis and treatment planning.

Histopathological examination of tissue sections stained with H and E reveals epithelial hyperplasia with hyperparakeratosis and candidal hyphae in parakeratin layer invading the deeper layers of epithelium, as was seen in the present case. An inflammatory cell infiltrate consisting of polymorphonuclear leukocytes and lymphocytes is present within the lamina propria and occasionally in the superficial layer of epithelium. The presence of fungal hyphae can be confirmed with PAS stain.<sup>[3,6]</sup> Nagai *et al.* have concluded that epithelial hyperplasia is a protective response of the host against *Candida*.<sup>[18]</sup>

Management of CHC involves the elimination of predisposing factors, chiefly smoking, antifungal therapy (both topical and systemic), and surgery in cases nonresponsive to medical treatment.<sup>[7]</sup> The patient had been complaining of thick coating on the tongue for 9 years and also had received several courses of antifungal drugs by a local physician, without much relief of symptoms. Hence, he was initially prescribed both oral and topical antifungal drugs for 2 weeks only, since the dose and duration of systemic treatment are reduced when a combination of both is used, but when the lesion did not regress completely following the antifungal treatment, surgery was performed to reduce the risk of malignant transformation associated with CHC.

## Conclusion

Although OC is a common infection in humans, yet it can pose a diagnostic challenge due to its varied clinical presentations. CHC is the least common form of OC and closely mimics many clinical conditions. Since there is a risk of malignant transformation associated with CHC, histopathological examination is essential to provide conclusive diagnosis and plan treatment.

## Financial support and sponsorship

Nil.

## Conflicts of interest

There are no conflicts of interest.

## References

- Pontes HA, Paiva HB, de Freitas Silva BS, Fonseca FP, da Silva FB, Pontes FS, et al. Oral candidiasis mimicking an oral squamous cell carcinoma: Report of a case. *Gerodontology* 2012;29:70-4.
- Sherman RG, Prusinski L, Ravenel MC, Joralmon RA. Oral candidiasis. *Quintessence Int* 2002;33:521-32.
- Krishnan PA. Fungal infections of the oral mucosa. *Indian J Dent Res* 2012;23:650-9.
- Neville BW, Damm DD, Allen CM, Bouquot JE. Oral and Maxillofacial Pathology. 3<sup>rd</sup> ed. India: Elsevier Publishers; 2009. p. 217-21.
- Axéll T, Samaranayake LP, Reichart PA, Olsen I. A proposal for reclassification of oral candidiasis. *Oral Surg Oral Med Oral Pathol Oral Radiol Endod* 1997;84:111-2.
- Williams D, Lewis M. Pathogenesis and treatment of oral candidosis. *J Oral Microbiol* 2011;3:5771-DOI: 10.3402/jom.v3i0.5771.
- Sitheequ MAM, Samaranayake LP. Chronic hyperplastic candidosis/candidiasis (candidal leukoplakia). *Crit Rev Oral Biol Med* 2003;14:253-67.
- Scardina GA, Ruggieri A, Messina P. Chronic hyperplastic candidiasis: A pilot study of the efficacy of 0.18% isotretinoin. *J Oral Sci* 2009;51:407-10.
- Coronado-Castellote L, Jiménez-Soriano Y. Clinical and microbiological diagnosis of oral candidiasis. *J Clin Exp Dent* 2013;5:e279-86.
- Greenberg MS, Glick M, Ship JA. *Burket's Oral Medicine*. 11<sup>th</sup> ed. India: CBS Publishers; 2012. p. 80-1.
- Cernea P, Crepy C, Kuffer R, Mascaro JM, Badillet G, Marie JL. Aspects peu connus de candidosis buccales. Les Candidases à foyers multiples de la cavité buccale. *Rev Stomatol (Paris)* 1965; 66:103-38.
- Jepsen A, Winther JE. Mycotic infection in oral leukoplakia. *Acta Odontol Scand* 1965;23:239-56.
- Mehta FS, Pindborg JJ, Gupta PC, Daftary DK. Epidemiologic and histologic study of oral cancer and leukoplakia among 50,915 villagers in India. *Cancer* 1969;24:832-49.
- Akpan A, Morgan R. Oral candidiasis. *Postgrad Med J* 2002;78:455-9.
- Daftary DK, Mehta FS, Gupta PC, Pindborg JJ. The presence of *Candida* in 723 oral leukoplakias among Indian villagers. *Scand J Dent Res* 1972;80:75-9.
- Shin ES, Chung SC, Kim YK, Lee SW, Kho HS. The relationship between oral *Candida* carriage and the secretor status of blood group antigens in saliva. *Oral Surg Oral Med Oral Pathol Oral Radiol Endod* 2003;96:48-53.
- Field EA, Field JK, Martin MV. Does *Candida* have a role in oral epithelial neoplasia? *J Med Vet Mycol* 1989;27:277-94.
- Nagai Y, Takeshita N, Saku T. Histopathologic and ultrastructural studies of oral mucosa with *Candida* infection. *J Oral Pathol Med* 1992;21:171-5.