

## Trigeminal Neuralgia Secondary to Vertebrobasilar Dolichoectasia Treated with Cyberknife Stereotactic Radiosurgery

### Abstract

Trigeminal neuralgia caused by vertebrobasilar dolichoectasia is a rare condition. It is characterized by paroxysmal hemifacial pain which is lancinating in type mostly refractory to medical management. This is a report of trigeminal neuralgia secondary to vertebral dolichoectasia refractory to medical management treated with cyber knife stereotactic radiosurgery to the dose of 66 Gy in single fraction to the proximal nerve root. Pain relief was achieved immediately after the treatment and with a follow up period of 2 years, patient is pain free. Cyberknife assisted radiosurgery is relatively safe in delivering high ablative doses with precise conformality to small target regions like proximal nerve root entry of trigeminal nerve with no major toxicities and achieving early pain relief. It is an outpatient and non-invasive procedure. It can be used as a definite treatment modality for trigeminal neuralgia induced by vertebrobasilar dolichoectasia.

**Keywords:** Cyberknife, trigeminal neuralgia, vertebrobasilar dolichoectasia

### Introduction

Trigeminal neuralgia is a chronic clinical condition secondary to multiple causes. Trigeminal neuralgia caused by vertebrobasilar dolichoectasia (VBD) is an extremely rare condition. The incidence is 0.05%.<sup>[1]</sup> Primarily, VBD is a vascular disorder characterized by a dilated, elongated, and tortuous vertebrobasilar system. It is characterized by paroxysmal hemifacial pain.

We are describing a patient who developed trigeminal neuralgia secondary to VBD and successfully treated with Cyberknife stereotactic radiosurgery.

### Case Report

A 66-year-old male presented to our outpatient department with the history of severe left-sided facial pain lancinating in type and associated with difficulty in chewing food on the left side. Pain distributed along the maxillary and mandibular components of the trigeminal nerve. He was diagnosed 7 years back clinically with trigeminal neuralgia and was started on tablet carbamazepine 100 mg thrice daily and the dose was increased to 200 mg thrice daily. He had no pain relief

This is an open access journal, and articles are distributed under the terms of the Creative Commons Attribution-NonCommercial-ShareAlike 4.0 License, which allows others to remix, tweak, and build upon the work non-commercially, as long as appropriate credit is given and the new creations are licensed under the identical terms.

For reprints contact: reprints@medknow.com

with medical management. Pain assessment was done using the Barrow Neurological Institute Pain Intensity Score. The initial assessment was a score of V (severe pain or no pain relief) before treatment.

A preliminary magnetic resonance imaging (MRI) of the brain with contrast was done which showed tortuous dilated right vertebral artery coursing in the prepontine cistern, extending to the left cerebellopontine angle, abutting and displacing the left trigeminal nerve (cisternal) to the lateral side. Mild altered morphology with flattening of the surface left trigeminal nerve was noted [Figure 1].

He was planned for Cyberknife stereotactic radiosurgery with single-fraction treatment using MRI and computed tomography (CT)-based planning. At the region of interest MRI Images with Constructive Interference in Steady state sequence of 0.6 mm slice thickness and CT scan with 1.25 mm slice thickness were acquired and fused using Cyberknife Data Management System (CDMS) [Figure 2]. Contouring was done using both CT and MRI scans [Figure 3]. Brainstem and vertebral arteries were organs at risk. Multiplan system version 4.6.1 was used for planning

**How to cite this article:** Lakshman VB, Aal M, Karumanchi PK, Jaleel A, Iyer AP. Trigeminal neuralgia secondary to vertebrobasilar dolichoectasia treated with cyberknife stereotactic radiosurgery. Asian J Neurosurg 2019;14:978-80.

**Vijay Bhaskar Lakshman, Mahalaxmi Aal, Pradeep Kumar Karumanchi, Ayesha Jaleel, Aarthi Pashupathy Iyer**

Department of Radiation Oncology, Health Care Global Enterprises Ltd., Bengaluru, Karnataka, India

### Address for correspondence:

Dr. Vijay Bhaskar Lakshman, Department of Radiation Oncology, Health Care Global Enterprises Ltd., 44-45/2, 2<sup>nd</sup> Cross, Raja Ram Mohan Roy Extension, Shanthi Nagar, Central Street, Bengaluru - 560 027, Karnataka, India.  
E-mail: vijaybhaskar9000@gmail.com

### Access this article online

Website: www.asianjns.org

DOI: 10.4103/ajns.AJNS\_53\_18

### Quick Response Code:



with sequential optimization. The dose to the target was 66 Gy in single fraction prescribed to the 83% isodose line [Figure 4].

The treatment was delivered with Cyberknife radiosurgery system which consists of 6MV, X band linear accelerator mounted on fully articulated robotic arm. It has precision of 0.3 mm with six degrees of freedom. Real-time imaging of bony anatomy with two orthogonally positioned X-ray detectors was done using 6D-skull tracking on CyberKnife VSI Radiosurgery System (Accuray Inc., Sunnyvale, CA, USA) 6D skull tracking mode was used to identify the skull and track the skull motion in six degrees of freedom based on the fixed relationship between the target volume and the skeletal features of the skull to correct the intrafraction movement errors.

After premedications, single-fraction radiation was delivered. Immediately after treatment, the patient noticed pain relief with improvement in chewing food. The Barrow

Neurological Institute Pain Intensity Score after treatment was I (no pain, no medications). Even though the patient had complete pain relief, empirically tablet carbamazepine was continued with tapering doses and stopped after 1 month. Follow-up was done at 3, 6, 12, and 18 months, respectively; he developed facial numbness posttreatment at the end of 6 months which was mild and not bothering (Barrow Neurological Institute Facial Numbness Scale).

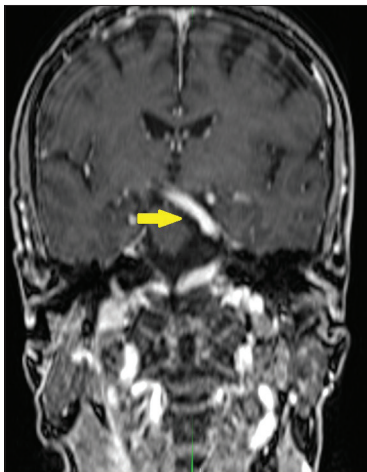


Figure 1: Coronal section of the magnetic resonance imaging of the brain showing the dilated vertebral artery due to vertebrobasilar dolichoectasia

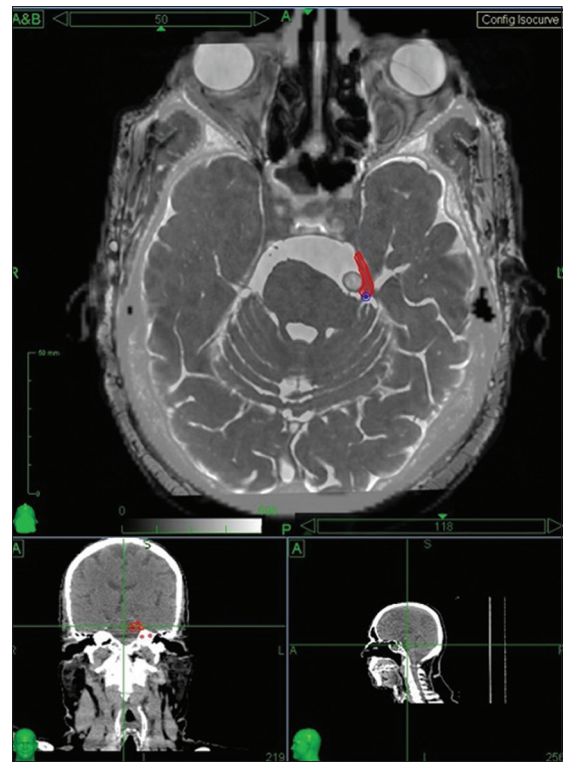


Figure 2: The above image is the fusion of the planning computed tomography scan and constructive interference in the steady-state sequence of magnetic resonance imaging, the red line is the target area that is the proximal nerve root entry zone

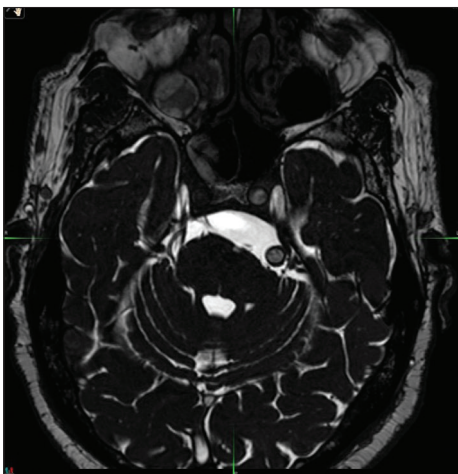


Figure 3: Axial section magnetic resonance imaging of the brain (constructive interference in steady-state series) showing the course of the trigeminal nerve

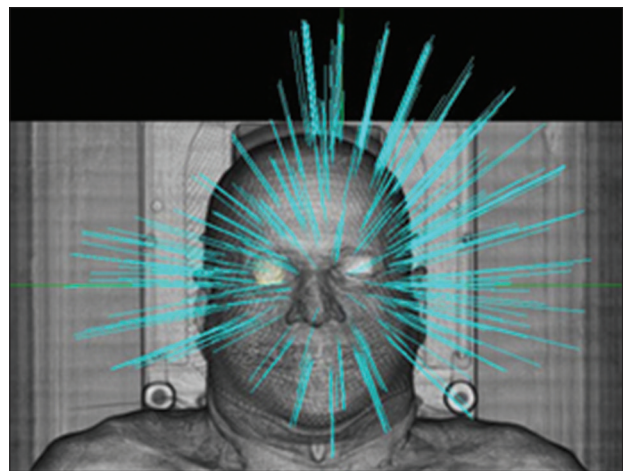


Figure 4: Three-dimensional beam planning with Cyberknife radiosurgery for trigeminal neuralgia (TN)

## Discussion

The term dolichoectasia means distension and elongation. The most common localization of dolichoectasia is the vertebrobasilar system in the brain.<sup>[2]</sup> The course of the Basilar Artery (BA) lies in the midline or paramedian but medial to the margin of the sphenoid clivus or dorsum sellae in 98% of the people. In the interpeduncular fossa, BA divides into both posterior cerebral arteries at the level of the superior aspect of dorsum sellae. The proposed mechanism for trigeminal neuralgia is vascular compression at a specific portion of the cisternal segment of the nerve known as the root entry zone (REZ). REZ is prone to continuous, pulsatile pressure resulting in “short circuit” of impulses and focal demyelination resulting in pain.

Trigeminal neuralgia is diagnosed clinically and VBD as etiology is confirmed with imaging. MRI with preferably CISS is useful in identifying the nerves. CISS sequence produces high-resolution isotropic images using strong T2-weighted three-dimensional gradient echo technique. CISS sequence is useful to delineate cranial nerves, as it provides good contrast between cerebrospinal fluid and cranial nerves.

The nerves appear dark gray in CISS sequence. Fast Imaging Employing Steady-state Acquisition (FIESTA) sequence is also used for better nerve delineation.

The most explored treatment for trigeminal neuralgia secondary to VBD is a surgical intervention in the form of microvascular decompression. The second-most common treatment option is the Gamma knife radio surgery (GKRS). Although both surgery- and Gamma knife-based treatments have resulted in good outcomes in terms of pain relief both being invasive techniques, require general anesthesia and have potential risks such as hearing loss, double vision, facial weakness, and stroke as post treatment complications,<sup>[3]</sup> whereas GKRS has unexpected headaches, edema, severe facial pain, and syncopal episodes after treatment.<sup>[4]</sup> Hence, both techniques require hospitalization to monitor postoperative complications.

Cyberknife radiosurgery (CKRS) is a linac-based robotic stereotactic radiosurgery, a new option for trigeminal neuralgia treatment, producing good pain relief and can be used as a definite treatment modality for medically refractory cases. In comparison to GKRS, CKRS being a frameless noninvasive technique makes it patient-friendly with no requirement for anesthesia. Gamma knife with a mounted frame needs imaging, planning, and treatment on the same day which is cumbersome compared to Cyberknife and offers flexibility in imaging and planning days before the treatment at the patient's comfort. GKRS can approach the lesion from 190 positions only, whereas

CKRS has 1300 positions to approach the lesion virtually from any angle with pinpoint precision to submillimeter accuracy. CKRS has real-time tracking of the lesion that can handle body and organ movement, whereas GKRS has no real-time update; it utilizes static images that are taken before treatment to fix the location of the lesion. CKRS thus aids in delivering high dose of radiation to the target volume of the nerve to produce ablation with accurate precision, eliminating the ability of the nerve to malfunction and cause pain. Due to the nerve root compression by VBD, the resulting treatment volume is more, favoring the use of CKRS. It is effective and safe as first line of treatment with no major adverse toxicities and improved dose homogeneity.<sup>[5]</sup>

In our patient, CKRS was done and the patient experienced immediate pain relief with no postprocedure complications. Patient is pain free with no requirement of adjuvant pain medication after two years of Cyberknife Stereotactic Radiosurgery.

### Declaration of patient consent

The authors certify that they have obtained all appropriate patient consent forms. In the form, the patient has given his consent for his images and other clinical information to be reported in the journal. The patient understands that name and initials will not be published and due efforts will be made to conceal identity, but anonymity cannot be guaranteed.

### Financial support and sponsorship

Nil.

### Conflicts of interest

There are no conflicts of interest.

### References

1. Flemming KD, Wiebers DO, Brown RD Jr, Link MJ, Huston J 3<sup>rd</sup>, McClelland RL, *et al.* The natural history of radiographically defined vertebrobasilar nonsaccular intracranial aneurysms. *Cerebrovasc Dis* 2005;20:270-9.
2. Ince B, Petty GW, Brown RD Jr, Chu CP, Sicks JD, Whisnant JP. Dolichoectasia of the intracranial arteries in patients with first ischemic stroke: A population-based study. *Neurology* 1998;50:1694-8.
3. Singh R, Davis J, Sharma S. Stereotactic radiosurgery for trigeminal neuralgia: A Retrospective multi-institutional examination of treatment outcomes. *Cureus* 2016;8:e554.
4. Elaimy AL, Hanson PW, Lamoreaux WT, Mackay AR, Demakas JJ, Fairbanks RK, *et al.* Clinical outcomes of gamma knife radiosurgery in the treatment of patients with trigeminal neuralgia. *Int J Otolaryngol* 2012;2012:919186.
5. Karam SD, Tai A, Snider JW, Bhatia S, Bedrick EJ, Rashid A, *et al.* Refractory trigeminal neuralgia treatment outcomes following CyberKnife radiosurgery. *Radiat Oncol* 2014;9:257.