

## Are rodlet cells reliable biomarkers in *Fundulus heteroclitus* (L.)?

KRAMER, C. R. \*, HONGACH, S. W., ANTONOV, K. and QAMA, E.

Department of Biology, College of Staten Island, City University of New York, 2800 Victory Boulevard,  
Staten Island, New York 10314, USA

\*E-mail: Charles.Kramer@csi.cuny.edu

### Abstract

Two populations of killifish, *Fundulus heteroclitus* (L.) were studied, one from a high environmentally impacted site (Saw Mill Creek) exposed to pollutants, heavy metals and infected with parasites, the other from a habitat that was far less affected (Lemon Creek), on Staten Island, New York. The rodlet cell counts in the gills of each population were compared and correlated with the number of gill parasites. A comparison of rodlet cell numbers was also made between mature males and females within each population. Although the parasite infestation was significantly higher in the Saw Mill Creek population, the rodlet cell counts did not differ between the two groups. There was no statistical correlation between the parasite number and number of rodlet cells or between standard length and rodlet cells in each population. Also, the number of rodlet cells did not differ between males and females in either group. Furthermore, EM observations showed no difference in the activity of these cells. Our findings suggest that in *F. heteroclitus*, rodlet cells are not dependable biomarkers for evaluating the fish's response to parasites and environmental stressors. In addition, the sexual status of the fish does not appear to affect the number of rodlet cells.

**Keywords:** *Fundulus heteroclitus*, rodlet cells, gills, parasite, biomarker.

### 1 Introduction

The rodlet cell (RC) has posed a conundrum for fish biologists since its identification over a century ago (THELOHAN, 1892). Found within viscera and epithelium of both freshwater and marine species (LEINO, 1974; BARBER, WESTERMANN and JENSEN, 1979; MAYBERRY, MARCHIONDO, UBELAKER et al., 1979; BIELEK and VIEHBERGER, 1983; FISHELSON, RUSSELL, GOLANI et al., 2011), two major hypotheses emerged as to the origin and function of these cells. According to the exogenous hypothesis, this cell is a parasite; most likely of the Apicomplexa order (MAYBERRY, MARCHIONDO, UBELAKER et al., 1979; AGULLEIRO, ZUASTI and LOZANO, 1986) whereas the tenet of the increasingly more prevalent view is that the RC is an endogenous element. Although several functions have been assigned to the RC over the years (see review by MANERA and DEZFULI, 2004), growing evidence suggests that this cell plays a role in the fish's innate immune response (LEINO, 1996; DEZFULI, CAPUANO and MANERA, 1998; DEZFULI, SIMONI, ROSSI et al., 2000; DEZFULI, GIARI, KONECNY et al., 2003a; DEZFULI, GIARI and SHINN, 2007; MANERA, SIMONI and DEZFULI, 2001; REITE, 2005; REITE and EVENSEN, 2006; KRAMER and QAMA, 2014), presumably as a member of the granulocytic line.

Studies on the role of RCs as immune effector cells have focused primarily on their mobilization and recruitment in response to parasite invasion (LEINO, 1996; DEZFULI, CAPUANO and MANERA, 1998; DEZFULI et al., 2003a; PALENZUELA, ALVAREZ-PELLITERO and SITJA-BOBADILLA, 1999; BERMUDEZ, LOSADA, VAZQUEZ et al., 2010; MATISZ, GOATER and BRAY, 2010), bacterial infection (SALINAS, MYKLEBUST, ESTEBAN et al., 2008; RINGO, LOVMO, KRISTIANSEN et al., 2010), stressors (IGER and ABRAHAM, 1997; ABRAHAM, IGER and ZHANG, 2001; POLTRONIERI,

LAURÀ, BERTOTTO et al., 2009), environmental toxicants (DEZFULI, GIARI, SIMONI et al., 2003b; SHIMADA BORGES, SALIMBENI VIVAI, BRANCO et al., 2013; PROCÓPIO, RIBEIRO, PEREIRA et al., 2014; SCHULTZ, JONES and TOOP, 2014) and pathological lesions (SMITH, CACECI and ROBERTSON, 1995a; SMITH, CACECI, MAREI et al., 1995b). Exposed tissues including gills (SHIMADA BORGES, SALIMBENI VIVAI, BRANCO et al., 2013; SCHULTZ, JONES and TOOP, 2014), intestine (DEZFULI, CAPUANO and MANERA, 1998), skin (IGER and ABRAHAM, 1997; ABRAHAM, IGER and ZHANG, 2001), liver (DEZFULI, SIMONI, ROSSI et al., 2000); kidney (LEINO, 1996; PALENZUELA, ALVAREZ-PELLITERO and SITJA-BOBADILLA, 1999) and brain (MATISZ, GOATER and BRAY, 2010) invariably showed a greater number of RCs than uninfected or unexposed fish of the same species. Thus, measurements of the response of RCs to various perturbations have come to serve as biomarkers for the potential negative impact of the environment on the health of the fish.

The gills of fish are often described along with skin, as the structures most often affected histologically by waterborne biological and physical contaminants (MALLATT, 1985; PANDEY, PARVEZ, ANSARI et al., 2008) because these elements have the most direct and continuous contact with the aquatic environment. The focus of this study was to evaluate the role of RCs as dependable biomarkers in two populations of the estuarine killifish, *Fundulus heteroclitus* on Staten Island, New York exposed to two different levels of contamination. The Saw Mill Creek population had been exposed to a major oil spill that took place in 1990 (PAULSON, SHARACK and ZDANOWICZ, 2003). Studies showed the presence of high levels of Cu, Hg, Pb and Zn as well as organic pollutants at this site (PAULSON, SHARACK and ZDANOWICZ, 2003;

PEREZ and WALLACE, 2004; GOTO and WALLACE, 2009, 2010). In addition to heavy metal exposure, the gills of these fish were heavily laden with trematode and myxosporean parasites. The Lemon Creek group was collected from a low impacted site located along the south shore of the island. Only an occasional myxosporean parasite was observed in the gills of these fish; trematode cercaria were never seen. The RC numbers were compared between males and females within each group and between groups. Correlations were made between parasite counts and the number of RCs within each population. We found that the RC numbers did not differ between males and females in either population and correlations between parasites and RCs were insignificant. Our results suggest that RCs are not influenced by sex hormones in mature fish. Furthermore, while RC recruitment serves as a good biomarker in the gills of other fishes exposed to hostile environments (DEZFULI, GIARI, KONECNY et al., 2003; MANERA and DEZFULI, 2004; SCHULTZ, JONES and TOOP, 2014), our results indicate that they are not reliable biomarkers in *F. heteroclitus*.

## 2 Materials and Methods

### 2.1 Fish

Adult *F. heteroclitus* were collected during July and August, 2013 using a common minnow trap from two collection sites, Saw Mill Creek and Lemon Creek, on Staten Island, NY. Spawning in this species commences in spring (March to May) and ends in late summer (July to September) (HARDY JUNIOR, 1978). The Saw Mill Creek collection (n= 13; four males, StL 64.1 + 2.02 mm and nine females, 70.2 + 4.26 mm) was from a highly contaminated site historically exposed to smelting activities (CARMODY, PEARCE and YASSO, 1973) and subjected to an earlier major oil spill (PAULSON, SHARACK and ZDANOWICZ, 2003). Previous studies showed high levels of heavy metals Cu, Hg, Pb and Zn as well as organic pollutants within the sediment (PEREZ and WALLACE, 2004; GOTO and WALLACE, 2009, 2010). The Lemon Creek population (n= 20; eight males, 44.4 + 2.7 mm, ten females 46.3 + 4.1 mm and two undetermined, 37.8 + 5.2 mm) was collected from an area that is one of the few undisturbed tidal marshes on the island (GOTO and WALLACE, 2010).

In the laboratory, each fish was sacrificed by over anesthetization in a solution of MS- 222 (tricaine methanesulphonate (Sigma)) and its standard length measured to the nearest 0.1 mm.

### 2.2 Tissue preparation

Under a dissection microscope, the opercular plates were carefully cut away and the individual gill hemibranchs were separated and placed into Bouin's fixative for 24 hours. The tissues were subsequently decalcified in a commercial 'decal' solution. In order to confirm the sexual status of the fish, the gonads were carefully removed via an anterior-posterior incision along the ventral midline followed by two vertical cuts at the anterior and posterior margins of the incision. The flap of tissue was peeled back to expose the viscera including the gonads which were carefully extracted and placed into Bouin's. Tissues were processed for paraffin in a routine manner. The gills were embedded so longitudinal sections could be cut ensuring the presence of the cartilaginous base support of the primary lamellae. Our previous work has shown the perichondrial area immediately beneath the afferent branchial artery to be a

robust site of rodlet cell recruitment in *F. heteroclitus* (QAMA, BLAIZE, L'AMOREAUX et al., 2009). Serial sections, 6 µm thick were cut with a rotary microtome, mounted on gelatin coated slides and stained with Masson's trichrome.

A small piece of each hemibranch was cut and processed for TEM according to the procedures previously described (KRAMER and POTTER, 2002). Sectioning was performed on a Leica Ultracut UCT microtome. Thick (1 µm) sections were stained with toluidine blue. Thin sections (80-100 nm) were collected on uncoated grids and stained with saturated aqueous uranyl acetate followed by lead citrate. Observations were made at 80kV on an FEI Tecnai Spirit transmission electron microscope.

### 2.3 Cell counting

Rodlet cell counts were made at the light level from ten randomly selected areas (151,976 µm<sup>2</sup>) in the hemibranchs of each fish according to the procedures of Manera, Simoni and Dezfuli (2001), stained with Masson's to accentuate cell identification. The total number of parasites was counted in every tenth section of the hemibranch of each fish. This precluded the possibility of counting the same parasite more than once.

### 2.4 Statistics

The mean rodlet cell counts of males v. females from SMC were compared using Student's T ( $P < 0.05$ ) while in the LC group a one-way ANOVA was performed. Comparisons between groups were made with ANOVA. The mean parasite counts within and between populations were similarly analyzed ( $P < 0.05$ ). Correlations between StL and RCs as well as parasite number and RC counts in both populations utilized Pearson's Correlation followed by least squares regression analysis ( $P < 0.05$ ) performed with Microsoft Excel.

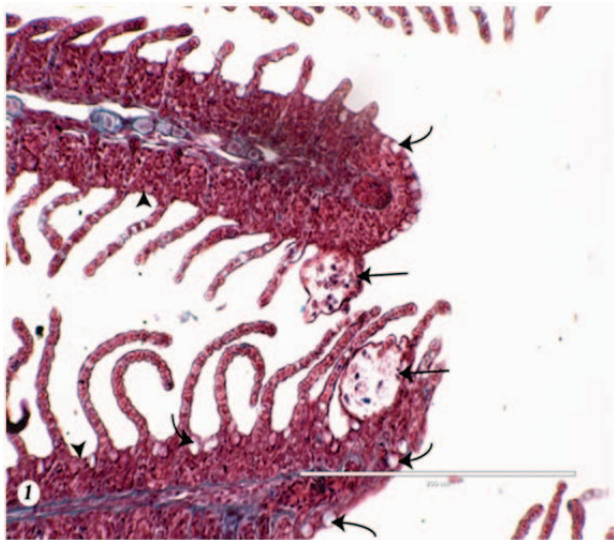
## 3 Results

The gills of fish from the heavily impacted SMC population invariably showed marked signs of histopathology including extensive hyperplasia of interlamellar epithelium leading to fusion of secondary lamellae, abundant mucous cells, epithelial detachment in the secondary lamellae causing intralamellar edema and an increase in melanocytes and melanin deposits. Myxosporean cysts and trematode metacercaria were abundant in this tissue (Figures 1-3). The males averaged  $19.7 \pm 5.9$  and the females  $17.6 \pm 3.37$  parasites/section (Table 1). In contrast, the gills of fish from the LC site were normal in appearance with well defined secondary lamellae and a modicum of melanocytes and mucus producing cells. Parasites were scarce (Figures 4 and 5). The males averaged  $0.21 \pm 0.12$ , females  $0.18 \pm 0.05$  and unknowns,  $0.27 \pm 0.2$  parasites/section (Table 1). RCs were observed in the gills of both populations where they were seen to occupy an area of the perichondrium beneath the cartilaginous knob that supports the base of the filament as part of the branchial skeleton. The majority of these cells were oriented so that the rodlets faced the lumen of the afferent branchial artery (Figure 5). We did not observe RCs associated with the parasites within either the 1<sup>o</sup> or 2<sup>o</sup> lamellae.

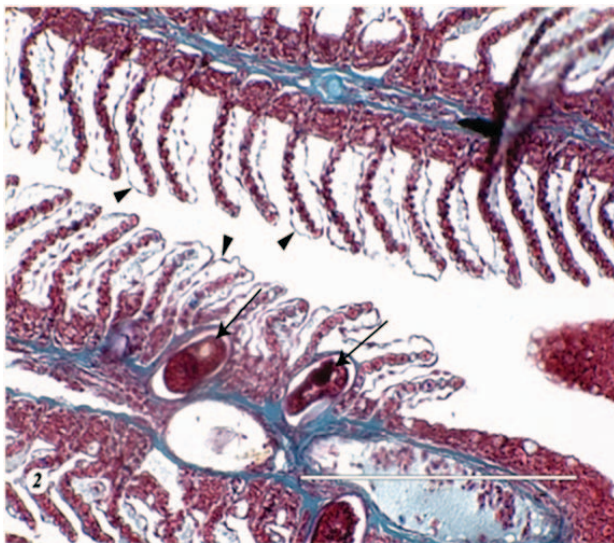
Surprisingly, even though the number of parasites/area in the SMC population differed significantly ( $P < 0.001$ ) from the LC population (Table 1), the mean number of RCs did not differ ( $P > 0.05$ ) between the two populations (Table 2). Furthermore, a correlation did not exist between parasite

numbers and RC counts in either population (Table 3); in the highly impacted SMC fish  $r=0.173$  ( $P>0.05$ ) compared to  $r=0.095$  ( $P>0.05$ ) in the LC fish from the non-impacted site (Table 4). Furthermore, there was no significant difference in the mean number of RCs/area between males ( $55.6 \pm 9.9$ ) and females ( $41.8 \pm 5.5$ ) of the SMC population and among the males ( $50.0 \pm 5.5$ ), females ( $46.6 \pm 4.6$ ) and unknowns ( $37.9 \pm 0.85$ ) of the LC population ( $P>0.05$ ) (Table 1). When we tested for a correlation between StL and RCs/area we obtained an  $r = 0.14$  for the SMC fish and  $r = 0.18$  for the LC population (Table 4), indicating that a positive correlation did not exist between these two parameters.

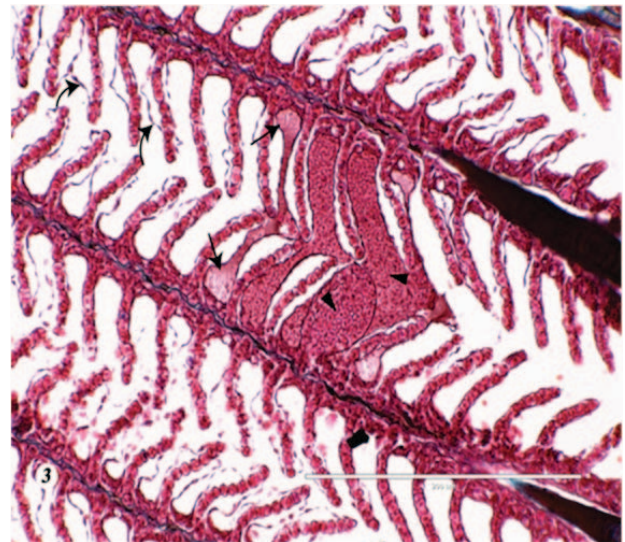
Ultrastructural observations on the gills of both populations showed that the distribution and activity of the rodlet cells was essentially the same. Mature RCs were most numerous. They were seen in the subendothelial layer of the afferent branchial artery where they were most often oriented perpendicular to the luminal space (Figures 5 and 6). Adhering junctions in the form of desmosomes and tight junctions could often be seen at the apices between the RCs and neighboring endothelial cells (Figure 7). On occasion, homocellular junctions in the form of desmosomes existed between adjacent RCs (Figure 8). The apices of the secreting RCs were observed to be protruding between the endothelial cells into the vascular space (Figures 6 and 7). Discharged rodlets were observed occasionally within the



**Figure 1.** A section through the gill of an SMC fish. Note the presence of myxoporean parasites (arrows), hyperplasia of the interlamellar zone (arrowheads) and mucous cells (curved arrows).



**Figure 2.** A section through the gill of an SMC fish infected with metacercaria cysts (arrows). Epithelial detachment of the secondary lamellae (arrowheads) is also apparent.



**Figure 3.** The gill of an SMC fish showing marked dilation of the blood vessels (telengectasia) (arrowheads) and epithelial detachment of the secondary lamellae (curved arrows) causing edema (arrows).



**Figure 4.** An uninfected gill from the LC population. Note the well defined secondary lamellae, lack of epithelial detachment, edema, vascular dilation and mucous cells.

**Table 1.** The mean number of parasites/section in SMC and LC populations of *Fundulus heteroclitus*<sup>1</sup>.

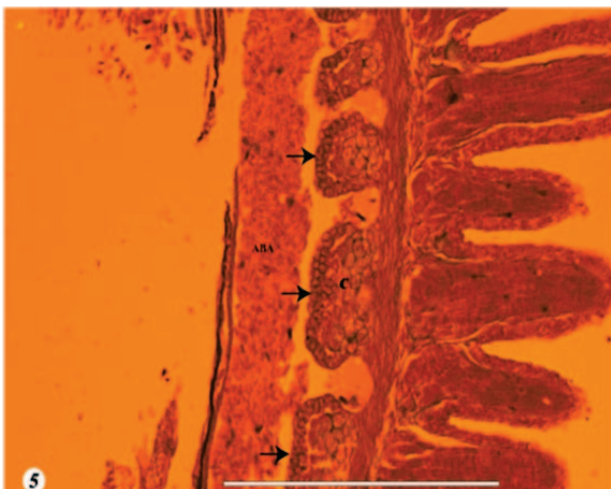
Saw Mill Creek <sup>2</sup>		Lemon Creek <sup>3</sup>		
Males	Females	Males	Females	Unknown
9.55	37.7	0.1	0.09	0.43
23.9	11.9	0.1	0.11	0.11
32.5	18.6	0.1	0.1	
31.4	32.7	0.13	0.2	
	7.53	0	0	
	8.33	0	0.21	
	18.0	1.6	0.11	
	5.8	0.08	0.18	
	18.1		0.5	
			0.1	
19.7 ± 5.9*		0.21 ± 0.12*		0.27 ± 0.2*

<sup>1</sup>One-way ANOVA between populations is significant (P<0.001). <sup>2</sup>T-test comparison between males and females is insignificant (P>0.05). <sup>3</sup>One-way ANOVA between males, females and unknowns is insignificant (P>0.05). \* Mean ± SEM.

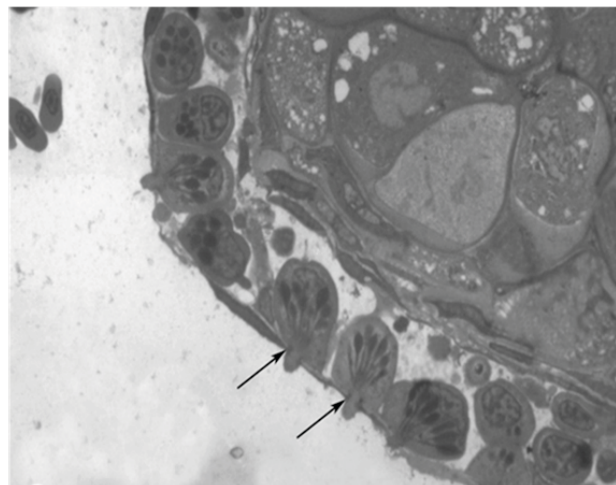
**Table 2.** The mean number of RCs/area in SMC and LC populations of *Fundulus heteroclitus*<sup>1</sup>.

Saw Mill Creek <sup>2</sup>		Lemon Creek <sup>3</sup>		
Males	Females	Males	Females	Unknown
57.7	60.3	56.7	28.6	38.8
39.5	60.3	41.5	40.7	37.1
34.2	33.3	33.8	53.4	
91.0	30.6	63.4	41.7	
	56.6	76.3	47.6	
	41.0	74.1	44.3	
	53.5	40.9	28.1	
	24.4	53.7	75.4	
	15.9		68.8	
			55.2	
55.6 ± 9.9*		50.0 ± 5.5*		37.9 ± 0.85*

<sup>1</sup>One-way ANOVA between populations is insignificant (P>0.05). <sup>2</sup>T-test comparison between males and females is insignificant (P>0.05). <sup>3</sup>One-way ANOVA between males, females and unknowns is insignificant (P>0.05). \*Mean ± SEM.



**Figure 5.** The base of the hemibranch of an LC fish. The rodlet cells (arrows) form clusters within the perichondrium beneath the cartilage (C) of the branchial skeleton and located un-neath the afferent branchial artery (ABA).



**Figure 6.** A TEM of the gill from an LC fish. The rodlet cells within the subendothelial layer of the afferent branchial artery are oriented perpendicular to the luminal space. Their apices can be seen protruding between the endothelium. Adhering junctions (arrows) between the rodlet cells and the endothelium are visible.

**Table 3.** A correlation between mean parasites/section and RCs/area in SMC and LC populations of *Fundulus heteroclitus*<sup>1</sup>.

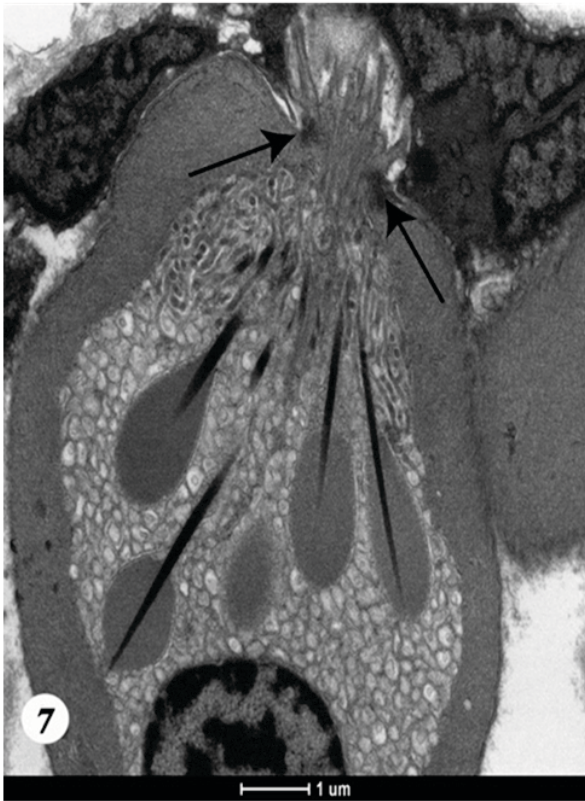Saw Mill Creek		Lemon Creek	
Parasites/Sec.	RCs/Area	Parasites/Sec.	RCs/Area
37.7	60.3	0.43	38.8
11.9	60.3	0.1	56.7
18.6	33.3	0.09	28.6
32.7	30.6	0.11	40.7
7.53	56.6	0.1	53.4
9.55	57.7	0.2	41.7
8.33	41.0	0.1	41.5
23.9	39.5	0.1	33.8
18.0	53.5	0	47.6
32.5	34.2	0.13	63.4
5.8	24.4	0.21	44.3
31.4	91.0	0	76.3
18.1	15.9	0.11	28.1
		0.11	37.1
19.7 ± 3.1*	46.02 ± 5.43*	0	74.1
		0.18	75.4
		0.5	68.8
		1.6	40.9
		0.08	53.7
		0.1	55.2
		0.21 ± 0.07*	48.3 ± 3.1*
	r= 0.1728		r= 0.095
	P>0.05		P>0.05

<sup>1</sup>Data was combined in each population as a statistical difference in RCs/area did not exist (P>0.05) between males and females (SMC) and males, females and unknowns (PB) (Table 2). \*Mean ± SEM.

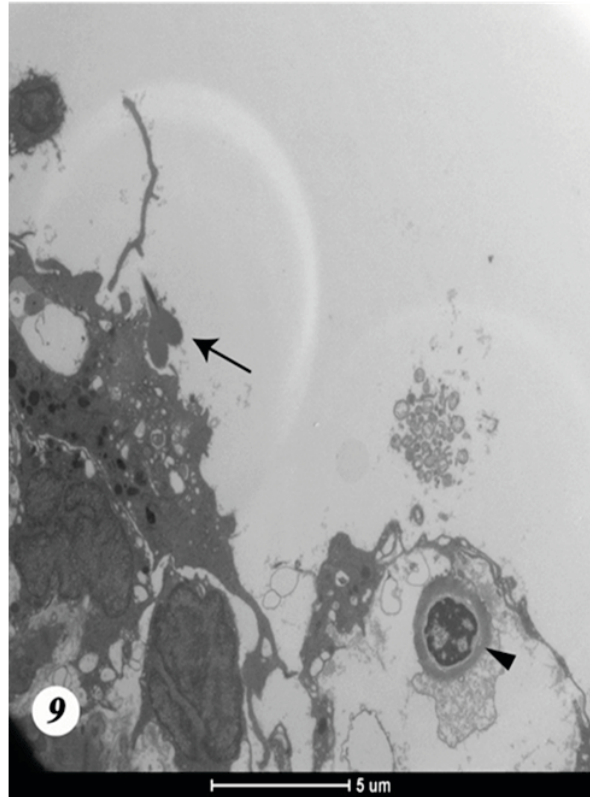
**Table 4.** A correlation between StL and Mean RCs/area in SMC and LC populations of *Fundulus heteroclitus*<sup>1</sup>.

Saw Mill Creek		Lemon Creek	
StL (mm)	RCs/area	StL (mm)	RCs/area
69.4	60.3	31.7	38.8
82.8	60.3	35.0	56.7
60.1	33.3	37.8	28.6
52.5	30.6	43.6	40.7
74.0	56.6	56.2	53.4
60.7	57.7	43.3	41.7
60.8	41.0	49.7	41.5
54.8	39.5	31.9	33.8
61.5	53.5	75.4	47.6
73.5	34.2	42.9	63.4
83.9	24.4	55.9	44.3
67.5	91.0	39.3	76.3
86.5	15.9	30.0	28.1
		29.8	37.1
		45.5	74.1
		34.0	75.4
		51.9	68.8
		32.5	40.9
		44.9	53.7
		34.9	55.2
68.3 ± 3.1*	46.02 ± 5.4*	42.3 ± 4.0*	46.2 ± 3.8*
	r= 0.14		r= 0.18
	P>0.05		P>0.05

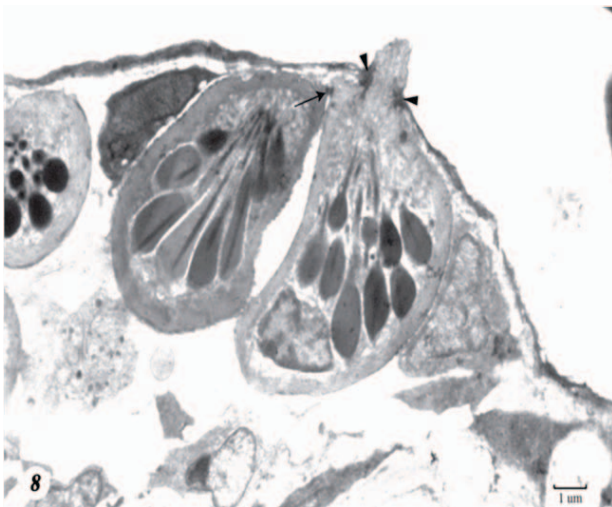
<sup>1</sup>Data was combined in each population as a statistical difference in RCs/area did not exist (P>0.05) between males and females (SMC) and males, females and unknowns (PB) (Table 2). \*Mean ± SEM.



**Figure 7.** A TEM of mature rodlet cell secreting into the afferent branchial artery of the gill of an SMC fish. Note the adhering junctions (arrows) between the rodlet cell and surrounding endothelial cells.



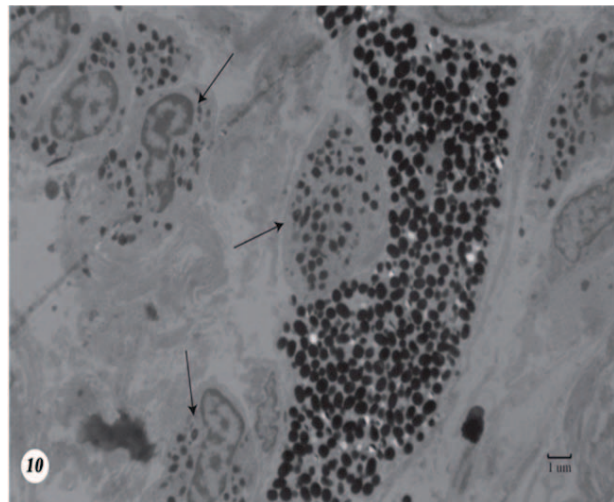
**Figure 8.** A TEM of the perichondrial region of the base of the gill filament underlying the afferent branchial artery of an LC fish. Adhering junctions in the form of desmosomes (arrows) and tight junctions (arrowheads) are seen between the rodlet cells and the rodlet cells and endothelium respectively.



**Figure 9.** A TEM of the basal portion of a hemibranch from an SMC fish showing discharged rodlets (arrow) and a spent rodlet cell (arrowhead). Note the retracted membrane.

vascular space (Figure 9). A small number of spent RCs that had become apoptotic were present within the elements of the perichondrium (Figure 9).

In addition to RCs, intact EGCs were on occasion, present within the sub-vascular tissue of the gills of fish from both populations (Figure 10). These purported analogs of the mammalian mast cell (REITE and EVENSEN, 2006) had not



**Figure 10.** A TEM showing EGCs (arrows) within the subvascular tissue in the gill of an LC fish.

degranulated, coinciding with a lack of tissue inflammation or necrosis.

#### 4 Discussion

Histopathological changes in the gills of fishes have often served as a monitor of environmental stress. The structural impact that we observed in the gills of the SMC fish from the highly

contaminated site were consistent with those of others who observed a negative effect of such factors as parasite infestation (DYKOVA and LOM, 1978; DEZFULI, GIARI and SHINN, 2007; SANTIAGO BASS; KHAN and WEIS, 2007), changes in water temperature (BOYD, DEVRIES, EASTMAN et al., 1980), salinity (AVELLA, BERHAUT and BORNANCIN, 1993) and pH (WILKIE and WOOD, 1994). Pathological changes in the gills have also been reported for fish exposed to petroleum effluents (GIARI, DEZFULI, LANZONI et al., 2012) while heavy metal exposure has been found to be especially damaging to gills (MALLATT, 1985; PANDEY, PARVEZ, ANSARI et al., 2008). Typical pathology that we observed included dilation of blood vessels (telangiectasia), epithelial lifting of the secondary lamellae, hyperplasia of the epithelium in the interlamellar zone between the secondary lamellae, secondary lamellae fusion, increased melanin deposition and mucous cells and the presence of rodlet cells.

An innumerable number of studies have come forth in recent years that support the recruitment of rodlet cells as effectors in the immune response of various tissues to the physical, chemical and parasite perturbations imposed by the environment (KOPONEN and MYERS, 2000; DEZFULI et al., 2003b; MANERA and DEZFULI, 2004; MATISZ, GOATER and BRAY, 2010; SHIMADA BORGES, SALIMBENI VIVAI, BRANCO et al., 2013). As a consequence, the rodlet cell has been viewed by many to serve as a biomarker for evaluating the potential negative impact of the environment on the life of the fish. Studies on the gills of fish exposed to environmental stressors have shown that rodlet cells were recruited and associated with specific histopathologies. Shimada Borges, Salimbeni Vivai, Branco et al. (2013) observed a statistically greater number of rodlet cells in affected gills of the Nile tilapia, *Oreochromis niloticus* collected from an urban lake contaminated with high levels of phosphate and chlorophyll compared to two other less contaminated sites where the tissue damage was less severe and the rodlet cells were fewer in number. Procópio, Ribeiro, Pereira et al. (2014) observed a greater number of rodlet cells in the gills of *Prochilodus argenteus* collected from a site that was highly contaminated with heavy metals compared to fish obtained from a low impacted site. The degree of tissue damage was greatest in the former group. Recently, Schultz, Jones and Toop (2014), investigating the gills of the Murray Cod, *Maccullochella peeli* suffering from chronic ulcerative dermatopathy, found that there was a greater number of rodlet cells in the damaged gill tissue than in unaffected fish. According to these investigators, the cause was of unknown origin, presumably a response to a water contaminant. Similar results have been reported in studies of fish exposed to other perturbations affecting gill structure including parasite infection (DEZFULI, GIARI, KONECNY et al., 2003a; DEZFULI, GIARI and SHINN, 2007; MAZON, HUISING, TAVERNE-THIELE et al., 2007), water-borne contaminants such as the herbicides Propanil (DEZFULI, GIARI, SIMONI et al., 2003b) and terbutylazine (DEZFULI, SIMONI, GIARI et al., 2006) and osmotic stress (GIARI, MANERA, SIMONI et al., 2006).

Our results show that in *F. heteroclitus* collected from a highly contaminated habitat (SMC) with high pollutants and having heavy gill infestation with parasites, although histopathological lesions existed in the gills, the number of rodlet cells did not differ compared to the gills of fish collected from a far less impacted site (LC). Furthermore, although the mean

number of parasites /section differed significantly between each population, there was no correlation between parasite counts and the number of rodlet cells in either collection. A similar observation was made by Densmore, Smith and Odenkirk (2007) who reported that no correlation could be made between the number of rodlet cells and the parasitized tissues of the snakehead, *Channa argus*.

Within each population, the number of rodlet cells did not differ between males and females nor was there a correlation between standard length and rodlet cells/area. Thus, the rodlet cell number was not a factor of the size of the fish, i.e., the larger fish would be expected to have a greater number of rodlet cells. The fact that we did not observe a difference in rodlet cell counts between the sexes answers a valid question asked by some who suggest that sex hormones could affect the rodlet cell population (JORDANOVA, MITEVA and ROCHA, 2007; PROCÓPIO, RIBEIRO, PEREIRA et al., 2014) and should be taken into account when making comparisons between the sexes when using rodlet cells as biomarkers. Jordanova, Miteva and Rocha (2007) reported that the number of rodlet cells in the liver of female trout, *Salmo letnica* increased from early to late stages of ovarian maturation, presumably the effect of ovarian sex steroids. Procópio, Ribeiro, Pereira et al. (2014) observed differences in rodlet cell counts in the gills of male and female curimba, *Prochilodus argenteus* collected from a site highly contaminated with heavy metals. In contrast, our observations show that gender was not a factor that affected rodlet cells, at least in *F. heteroclitus*. Our finding is consistent with that made by Koponen and Myers (2000) who observed that the sex of the fish had no apparent effect on the number of RCs in the bream, *Abramis brama* that were chronically exposed to PCBs.

The fact that the number of RCs/ area did not differ in the LC fish in comparison to the SMC fish poses an interesting conundrum. Even though the LC fish were exposed to a low impacted environment their RC numbers could have represented an immune mobilization of these cells against an as yet determined physical or chemical contaminant. This would explain why the number of RCs was statistically the same as those in the gills of the fish exposed to high contamination and parasite infestation where the RCs would be expected to be mobilized. One could suggest that even though the RC counts did not differ, the cells of the SMC fish could have been more active as the fish were more immunologically challenged than the LC fish. This was not the case, however. The RCs in both populations did not show any difference in the degree of recruitment and or secretory activity. We never observed RCs to be associated with the parasites in either the primary or secondary lamellae. Therefore, the possibility exists that in the gills of *F. heteroclitus*, RCs may not have been the primary immune effector cell. Instead, this task might have fallen on other effectors such as the EGCs (mast cell equivalent (REITE and EVENSEN, 2006; SFACTERIA, BRINES and BLANK, 2015)), macrophages, granulocytes and non-specific cytotoxic cells (KOPONEN and MYERS, 2000). Other than mucous cells, melanocytes and a modicum of EGCs, however, we did not observe any of the other effector cells in appreciable numbers within the gills of either fish. When describing gill histopathologies resulting from exposure to environmental contamination or parasite invasion, other investigators have made no mention of any changes in the RC population although they reported that other immune effector cells such as mucous cells,

lymphocytes and EGCs/mast cells had been mobilized (PAWERT, MULLER and TRIEBSKORN, 1998; RAMIREZ-DUARTE, RONDON-BARRAGAN and ESLAVA-MOCHA, 2008; ARAFA, EL-NAGGAR and EL-ABBASSY, 2009; VAN DYK, MARCHAND, PIETERSE et al., 2009; ANDREWS, BATTAGLENE, COBCROFT et al., 2010). Pawert, Muller and Triebskorn (1998) observed histopathological changes in the gills of brown trout, *Salmo trutta* and loach, *Barbatula barbatula* exposed to a heavily polluted stream. However, although the gills of each fish were significantly affected, RCs were present in all groups, the controls as well as fish exposed to pollution. The authors made no mention of quantitative differences in these cells between the fish.

Finally, the data reported herein strongly support our claim that RCs do not serve as a reliable biomarker, at least in the gills of *F. heteroclitus*. The presence of these cells in this tissue should be viewed more cautiously when evaluating the impact of the environment on the health of fishes.

## 5 Conclusion

The results of our study show that RCs, routinely, viewed as biomarkers in the tissues of fish exposed to environmental perturbations, must be viewed with some reservation, at least in *F. heteroclitus*. We found no statistical difference in the number of RCs/area in the gills between two populations exposed to two very different environments, one highly contaminated and with heavy parasite load and the other from an undisturbed tidal marsh. Furthermore, gender did not affect RC numbers as we observed no statistical difference between males and females in either population. The size of the fish was not a factor. There was no correlation between StL and RCs/area in either population. We found no correlation between the number of parasites and RCs/area. The fact that the number of RCs did not differ between the populations and if the RC is a major player in the immune reaction within the gill, then some undetectable factor in the low impacted site could have served to mobilize these cells. On the other hand, the absence of RCs in the immediate vicinity of parasites and the fact that we observed no difference in the activity of these cells at the ultrastructural level, suggests that these cells might not be the main immune effector cell. This is in need of further elucidation.

**Acknowledgements:** The authors are most grateful to Drs. Lisa Manne and Richard Veit of the Department of Biology, College of Staten Island, for their helpful suggestions regarding statistical analysis.

## References

ABRAHAM, M., IGER, Y. and ZHANG, L. Fine structure of the skin cells of stenohaline freshwater fish *Cyprinus carpio* exposed to diluted seawater. *Tissue & Cell*, 2001, vol. 33, n. 1, p. 46-54. PMID:11292170. <http://dx.doi.org/10.1054/tice.2000.0149>.

AGULLEIRO, B. ZUASTI, A and LOZANO, MT. Rodlet cells, gamonts and differentiating microgamonts of Apicomplexa in teleosts. *Acta Microscopica*, 1986, vol. 9, p. 23-30.

ANDREWS, M., BATTAGLENE, S., COBCROFT, J., ADAMS, M., NOGA, E. and NOWAK, B. Host response to the chondracanthid copepod *Chondracanthus goldsmidi*, a gill parasite of the striped trumpeter, *Laris lineata* (Forster), in Tasmania. *Journal of Fish Diseases*, 2010, vol. 33, n. 3, p. 211-220. PMID:19912458. <http://dx.doi.org/10.1111/j.1365-2761.2009.01107.x>.

ARAFA, SZ., EL-NAGGAR, MM. and EL-ABBASSY, SA. Mode of attachment and histopathological effects of *Macrogyrodactylus clarii*, a monogenean gill parasite of the catfish *Clarias gariepinus*, with a report on host response. *Acta Parasitologica*, 2009, vol. 54, n. 2, p. 103-112.

AVELLA, M., BERHAUT, J. and BORNANCIN, M. Salinity tolerance of two fishes, *Oreochromis aureus* and *O. niloticus*. I. Biochemical and morphological changes in the gill epithelium. *Journal of Fish Biology*, 1993, vol. 42, n. 2, p. 243-254. <http://dx.doi.org/10.1111/j.1095-8649.1993.tb00325.x>.

BARBER, DL., WESTERMANN, JEM. and JENSEN, DN. New observations on the rodlet cell (*Rhabdospora thelohani*) in the white sucker *Catostomas commersoni*: LM and EM studies. *Journal of Fish Biology*, 1979, vol. 14, n. 3, p. 277-284. <http://dx.doi.org/10.1111/j.1095-8649.1979.tb03519.x>.

BERMUDEZ, R., LOSADA, AP., VAZQUEZ, S., REDONDO, MJ., ALVAREZ-PELLITERO, P. and QUIROGA, MI. Light and electron microscopic studies on turbot *Psetta maxima* infected with *Enteromyxum scophthalmi*: histopathology of turbot enteromyxosis. *Diseases of Aquatic Organisms*, 2010, vol. 89, n. 3, p. 209-221. PMID:20481088. <http://dx.doi.org/10.3354/dao02202>.

BIELEK, E. and VIEHBERGER, G. New aspects on the "rodlet cell" in teleosts. *Journal of Submicroscopic Cytology and Pathology*, 1983, vol. 15, n. 3, p. 681-694. PMID:6876223.

BOYD, RB., DEVRIES, AL., EASTMAN, JT. and PIETRA, GG. The secondary lamellae of the gills of cold water (high latitude) teleosts. A comparative light and electron microscopic study. *Cell and tissue research*, 1980, vol. 213, n. 3, p. 361-367. PMID:7192603.

CARMODY, P., PEARCE, J. and YASSO, W. Trace elements in sediments of the New York Bight. *Marine Pollution Bulletin*, 1973, vol. 4, n. 9, p. 132-135. [http://dx.doi.org/10.1016/0025-326X\(73\)90006-4](http://dx.doi.org/10.1016/0025-326X(73)90006-4).

DENSMORE, CL. SMITH, SA. and ODENKIRK, J. Rodlet cells in tissues of the northern snakehead (*Channa argus*) from Potomac river tributaries. In *IAAAM Proceedings*, 2007. Cancun: IAAAM, 2007. 82 p.

DEZFULI, BS., CAPUANO, S. and MANERA, M. A description of rodlet cells from the alimentary canal of *Anguilla anguilla* and their relationship with parasitic helminthes. *Journal of Fish Biology*, 1998, vol. 53, n. 5, p. 1084-1095.

DEZFULI, BS., GIARI, L. and SHINN, AP. The role of rodlet cells in the inflammatory response in *Phoxinus phoxinus* brains infected with *Diplostomum*. *Fish & Shellfish Immunology*, 2007, vol. 23, n. 2, p. 300-304. PMID:17182257. <http://dx.doi.org/10.1016/j.fsi.2006.11.003>.

DEZFULI, BS., GIARI, L., KONECNY, R., JAEGER, P. and MANERA, M. Immunohistochemistry, ultrastructure and pathology of gills of *Abramis brama* from Lake Mondsee, Austria, infected with *Ergasilus sieboldi* (Copepoda). *Diseases of aquatic organisms*, 2003a, vol. 53, n. 3, p. 257-262. PMID:12691197.

DEZFULI, BS., GIARI, L., SIMONI, E., PALAZZI, D. and MANERA, M. Alteration of rodlet cells in chub caused by the herbicide StamR M-4 (Propanil). *Journal of Fish Biology*, 2003b, vol. 63, n. 1, p. 232-239. <http://dx.doi.org/10.1046/j.1095-8649.2003.00151.x>.

DEZFULI, BS., SIMONI, E., GIARI, L. and MANERA, M. Effects of experimental terbuthylazine exposure on the cells of *Dicentrarchus labrax* (L.). *Chemosphere*, 2006, vol. 64, n. 10, p. 1684-1694. PMID:16487568. <http://dx.doi.org/10.1016/j.chemosphere.2006.01.023>.

DEZFULI, BS., SIMONI, E., ROSSI, R. and MANERA, M. Rodlet cells and other inflammatory cells of *Phoxinus phoxinus* infected with *Raphidascaris acus* (Nematoda). *Diseases of Aquatic Organisms*, 2000, vol. 43, n. 1, p. 61-69. PMID:11129382.

DYKOVA, I. and LOM, J. Histopathological changes in fish gills infected with myxosporidian parasites of the genus *Henneguya*.



- Journal of Fish Biology*, 1978, vol. 12, n. 3, p. 197-202. <http://dx.doi.org/10.1111/j.1095-8649.1978.tb04165.x>.
- FISHELSON, L., RUSSELL, B., GOLANI, D. and GOREN, M. Rodlet cells in the alimentary tract of three genera of lizardfishes (Synodontidae, Aulopiformes): more on these enigmatic "gate-guards" of fishes. *Cybium*, 2011, vol. 35, n. 2, p. 121-129.
- GIARI, L., DEZFULI, BS., LANZONI, M. and CASTALDELLI, G. The impact of an oil spill on organs of bream *Abramis brama* in the Po river. *Ecotoxicology and Environmental Safety*, 2012, vol. 77, p. 18-27. PMID:22030380. <http://dx.doi.org/10.1016/j.ecoenv.2011.10.014>.
- GIARI, L., MANERA, M., SIMONI, E. and DEZFULI, BS. Changes to chloride and rodlet cells in gills, kidney and intestine of *Dicentrarchus labrax* (L.) exposed to reduced salinities. *Journal of Fish Biology*, 2006, vol. 69, n. 2, p. 590-600. <http://dx.doi.org/10.1111/j.1095-8649.2006.01130.x>.
- GOTO, D. and WALLACE, WG. Biodiversity loss in benthic macrofaunal communities and its consequence for organic mercury trophic availability to benthivorous predators in the lower Hudson River estuary, USA. *Marine Pollution Bulletin*, 2009, vol. 58, n. 12, p. 1909-1915. PMID:19857879. <http://dx.doi.org/10.1016/j.marpolbul.2009.09.032>.
- GOTO, D. and WALLACE, WG. Relative importance of multiple environmental variables in structuring benthic macroinfaunal assemblages in chronically metal-polluted salt marshes. *Marine Pollution Bulletin*, 2010, vol. 60, n. 3, p. 363-375. PMID:19954802. <http://dx.doi.org/10.1016/j.marpolbul.2009.11.002>.
- HARDY JUNIOR, JD. *Development of fishes of the Mid-Atlantic bight: an atlas of egg, larval and juvenile stages*. Washington: US Fish and Wildlife Service, Biological Service Program, 1978. 478 p. FWS/OBS-78/12. vol. 2: Anguillidae through Syngnathidae.
- IGER, Y. and ABRAHAM, M. Rodlet cells in the epidermis of fish exposed to stressors. *Tissue & Cell*, 1997, vol. 29, n. 4, p. 431-438. PMID:18627825. [http://dx.doi.org/10.1016/S0040-8166\(97\)80029-8](http://dx.doi.org/10.1016/S0040-8166(97)80029-8).
- JORDANOVA, M., MITEVA, N. and ROCHA, E. A quantitative study of the hepatic eosinophilic granule cells and rodlet cells during the breeding cycle of Ohrid trout, *Salmo letnica* Kar. (Teleostei, Salmonidae). *Fish & Shellfish Immunology*, 2007, vol. 23, n. 2, p. 473-478. PMID:17448686. <http://dx.doi.org/10.1016/j.fsi.2006.11.004>.
- KOPONEN, K. and MYERS, MS. Seasonal changes in intra- and interorgan occurrence of rodlet cells in freshwater bream. *Journal of Fish Biology*, 2000, vol. 56, n. 2, p. 250-263. <http://dx.doi.org/10.1111/j.1095-8649.2000.tb02104.x>.
- KRAMER, CR. and POTTER, H. Ultrastructural observations on rodlet cell development in the head kidney of the southern platyfish *Xiphophorus maculatus* (Teleostei: Poeciliidae). *Canadian Journal of Zoology*, 2002, vol. 80, n. 8, p. 1422-1436. <http://dx.doi.org/10.1139/z02-125>.
- KRAMER, CR. and QAMA, E. The effect of Neupogen® on rodlet cell activity and distribution in the heart of the goldfish, *Carassius auratus*. An LM and EM study. *In Vivo (Athens, Greece)*, 2014, vol. 36, n. 1, p. 11-17.
- LEINO, RL. Ultrastructure of immature, developing, and secretory rodlet cells in fish. *Cell and Tissue Research*, 1974, vol. 155, n. 3, p. 367-381. PMID:4458951. <http://dx.doi.org/10.1007/BF00222812>.
- LEINO, RL. Reaction of rodlet cells to a myxosporean infection in the kidney of the bluegill, *Lepomis macrochirus*. *Canadian Journal of Zoology*, 1996, vol. 74, n. 2, p. 217-225. <http://dx.doi.org/10.1139/z96-027>.
- MALLATT, J. Fish gill structural changes induced by toxicants and other irritants: a statistical review. *Canadian Journal of Fisheries and Aquatic Sciences*, 1985, vol. 42, n. 4, p. 630-648. <http://dx.doi.org/10.1139/f85-083>.
- MANERA, M. and DEZFULI, BS. Rodlet cells in teleosts: a new insight into their nature and functions. *Journal of Fish Biology*, 2004, vol. 65, n. 3, p. 597-619. <http://dx.doi.org/10.1111/j.0022-1112.2004.00511.x>.
- MANERA, M., SIMONI, E. and DEZFULI, BS. The effect of dexamethasone on the occurrence and ultrastructure of rodlet cells in goldfish. *Journal of Fish Biology*, 2001, vol. 59, n. 5, p. 1239-1248. <http://dx.doi.org/10.1111/j.1095-8649.2001.tb00188.x>.
- MATISZ, CE., GOATER, CP. and BRAY, D. Density and maturation of rodlet cells in brain tissue of fathead minnows (*Pimephales promelas*) exposed to trematode cercariae. *International Journal for Parasitology*, 2010, vol. 40, n. 3, p. 307-312. PMID:19748507. <http://dx.doi.org/10.1016/j.ijpara.2009.08.013>.
- MAYBERRY, LF., MARCHIONDO, AA., UBELAKER, JE. and KAZIĆ, D. *Rhabdospora thelohani* Laguesse, 1895 (Apicomplexa): new host and geographic records with taxonomic considerations. *The Journal of Protozoology*, 1979, vol. 26, n. 2, p. 168-178. PMID:490430. <http://dx.doi.org/10.1111/j.1550-7408.1979.tb02757.x>.
- MAZON, AF., HUISING, MO., TAVERNE-THIELE, AJ., BASTIAANS, J. and VERBURG-VAN KEMENADE, BM. The first appearance of rodlet cells in carp (*Cyprinus carpio* L.) ontogeny and their possible roles during stress and parasite infection. *Fish & Shellfish Immunology*, 2007, vol. 22, n. 1-2, p. 27-37. PMID:16843681. <http://dx.doi.org/10.1016/j.fsi.2006.03.012>.
- PALENZUELA, O., ALVAREZ-PELLITERO, P. and SITJÀ-BOBADILLA, A. Glomerular disease associated with *Polysoproplasma sparis* (myxozoa) infections in cultured seabream, *Sparus aurata* L. (Pisces: Teleostei). *Parasitology*, 1999, vol. 118, n. 3, p. 245-256. PMID:10205800. <http://dx.doi.org/10.1017/S0031182098003758>.
- PANDEY, S., PARVEZ, S., ANSARI, RA., ALI, M., KAUR, M., HAYAT, F., AHMAD, F. and RAISUDDIN, S. Effects of exposure to multiple trace metals on biochemical, histological and ultrastructural features of gills of a freshwater fish, *Channa punctata* Bloch. *Chemico-Biological Interactions*, 2008, vol. 174, n. 3, p. 183-192. PMID:18586230. <http://dx.doi.org/10.1016/j.cbi.2008.05.014>.
- PAULSON, AJ., SHARACK, B. and ZDANOWICZ, V. Trace metals in ribbed mussels from Arthur Kill, New York/New Jersey, USA. *Marine Pollution Bulletin*, 2003, vol. 46, n. 1, p. 139-152. PMID:12535980. [http://dx.doi.org/10.1016/S0025-326X\(02\)00312-0](http://dx.doi.org/10.1016/S0025-326X(02)00312-0).
- PAWERT, M., MULLER, E. and TRIEBSKORN, R. Ultrastructural changes in fish gills as biomarkers to assess small stream pollution. *Tissue & Cell*, 1998, vol. 30, n. 6, p. 617-626. PMID:10189321. [http://dx.doi.org/10.1016/S0040-8166\(98\)80080-3](http://dx.doi.org/10.1016/S0040-8166(98)80080-3).
- PEREZ, MH. and WALLACE, WG. Differences in prey capture in grass shrimp, *Palaemonetes pugio*, collected along an environmental impact gradient. *Archives of Environmental Contamination and Toxicology*, 2004, vol. 46, n. 1, p. 81-89. PMID:15025167. <http://dx.doi.org/10.1007/s00244-002-0249-9>.
- POLTRONIERI, C., LAURÀ, R., BERTOTTO, D., NEGRATO, E., SIMONTACCHI, C., GUERRERA, MC. and RADAELLI, G. Effects of exposure to overcrowding on rodlet cells of the teleost fish *Dicentrarchus labrax* (L.). *Veterinary Research Communications*, 2009, vol. 33, n. 7, p. 619-629. PMID:19205917. <http://dx.doi.org/10.1007/s11259-009-9211-x>.
- PROCÓPIO, MS., RIBEIRO, HJ., PEREIRA, LA., OLIVEIRA LOPES, GA., CASTRO, AC., RIZZO, E., SATO, Y., RUSSO, RC. and CORRÊA JUNIOR, JD. Sex response differences of immunological and histopathological biomarkers in gill of *Prochilodus argenteus* from a polluted river in southeast Brazil. *Fish & Shellfish Immunology*, 2014, vol. 39, n. 1, p. 108-117. PMID:24795082. <http://dx.doi.org/10.1016/j.fsi.2014.04.010>.
- QAMA, E., BLAIZE, J., L'AMOREAUX, WJ. and KRAMER, CR. Rodlet cell distribution and activity in the gills of laboratory-

- maintained and wild-caught *Fundulus heteroclitus*. *In Vivo*, 2009, vol. 31, n. 1, p. 1-7.
- RAMIREZ-DUARTE, WF., RONDON-BARRAGAN, IS. and ESLAVA-MOCHA, PR. Acute toxicity and histopathological alterations of Roundup® herbicide on “cachama blanca” (*Piaractus brachypomus*). *Pesquisa Veterinaria Brasileira*, 2008, vol. 28, n. 11, p. 547-554.
- REITE, OB. and EVENSEN, O. Inflammatory cells of teleostean fish: a review focusing on mast cells/eosinophilic granule cells and rodlet cells. *Fish & Shellfish Immunology*, 2006, vol. 20, n. 2, p. 192-208. PMID:15978838. <http://dx.doi.org/10.1016/j.fsi.2005.01.012>.
- REITE, OB. The rodlet cells of teleostean fish: their potential role in host defence in relation to the role of mast cells/eosinophilic granule cells. *Fish & Shellfish Immunology*, 2005, vol. 19, n. 3, p. 253-267. PMID:15820126. <http://dx.doi.org/10.1016/j.fsi.2005.01.002>.
- RINGO, E., LOVMO, L., KRISTIANSSEN, M., BAKKEN, Y., SALINAS, I., MYKLEBUST, R., OLSEN, RE. and MAYHEW, TM. OLSEN, RE and MAYHEW, TM. Lactic acid bacteria vs. pathogens in the gastrointestinal tract of fish: a review. *Aquaculture Research*, 2010, vol. 41, n. 4, p. 451-467. <http://dx.doi.org/10.1111/j.1365-2109.2009.02339.x>.
- SALINAS, I., MYKLEBUST, R., ESTEBAN, MA., OLSEN, RE., MESEGUER, J. and RINGØ, E. In vitro studies of *Lactobacillus delbrueckii* subsp. *lactis* in Atlantic salmon (*Salmo salar* L.) foregut: tissue responses and evidence of protection against *Aeromonas salmonicida* subsp. *salmonicida* epithelial damage. *Veterinary Microbiology*, 2008, vol. 128, n. 1, p. 167-177. PMID:18054448. <http://dx.doi.org/10.1016/j.vetmic.2007.10.011>.
- SANTIAGO BASS, C., KHAN, S. and WEIS, JS. Morphological changes to the gills of killifish associated with severe parasite infection. *Journal of Fish Biology*, 2007, vol. 71, n. 3, p. 920-925.
- SCHULTZ, AG., JONES, PL. and TOOP, T. Rodlet cells in Murray cod, *Maccullochella peelii peelii* (Mitchell), affected with chronic ulcerative dermatopathy. *Journal of fish diseases*, 2014, vol. 37, n. 3, p. 219-228. PMID:23496361. <http://dx.doi.org/10.1111/jfd.12099>.
- SFACTERIA, A., BRINES, M. and BLANK, U. The mast cell plays a central role in the immune system of teleost fish. *Molecular Immunology*, 2015, vol. 63, n. 1, p. 3-8. PMID:24613788. <http://dx.doi.org/10.1016/j.molimm.2014.02.007>.
- SHIMADA BORGES, JC., SALIMBENI VIVAI, ABB., BRANCO, PC., OLIVEIRA, MS. and SILVA, JRM. Effects of trophic levels (chlorophyll and phosphorous content) in three different water bodies (urban lake, reservoir and aquaculture facility) on gill morphology of Nile tilapia (*Oreochromis niloticus*). *Journal of Applied Ichthyology*, 2013, vol. 29, n. 3, p. 573-578. <http://dx.doi.org/10.1111/jai.12101>.
- SMITH, SA., CACECI, T., and ROBERTSON, JL. Occurrence of rodlet cells and associated lesions in the vasculature system of freshwater angelfish. *Journal of Aquatic Animal Health*, 1995a, vol. 7, n. 1, p. 63-69. [http://dx.doi.org/10.1577/1548-8667\(1995\)007<0063:OORCAA>2.3.CO;2](http://dx.doi.org/10.1577/1548-8667(1995)007<0063:OORCAA>2.3.CO;2).
- SMITH, SA., CACECI, T., MAREI, HE-S. and EL-HABBACK, HA. Observations on rodlet cells found in the vascular system and extravascular space of angelfish (*Pterophyllum scalare scalare*). *Journal of Fish Biology*, 1995b, vol. 46, n. 2, p. 241-254. <http://dx.doi.org/10.1111/j.1095-8649.1995.tb05965.x>.
- THELOHAN, P. Sur des spores indeterminees parasites des poissons. *Journal of Anatomy and Physiology Paris*, 1892, vol. 28, p. 163-171.
- VAN DYK, JC., MARCHAND, MJ., PIETERSE, GM., BARNHOORN, E. and BORNMAN, MS. Histological changes in the gills of *Clarias gariepinus* (Teleostei: Clariidae) from a polluted South African urban aquatic system. *African Journal of Aquatic Science*, 2009, vol. 34, n. 3, p. 283-291. <http://dx.doi.org/10.2989/AJAS.2009.34.3.10.986>.
- WILKIE, MP. and WOOD, CM. The effects of extremely alkaline water (9.5) on rainbow trout gill function and morphology. *Journal of Fish Biology*, 1994, vol. 45, n. 1, p. 87-98.

Received December 9, 2015  
Accepted November 5, 2016