

Traumatic chiasmal syndrome

Subramanya GS Datta M Ch, Harish C Pathak M Ch*

Departments of Neurosurgery, Command Hospital (Northern Command) Udhampur (J&K) and
*Army Hospital (Research & Referral), Delhi Cantt. New Delhi

Abstract : We present a case report of a young adult male who sustained severe head injury in a bomb blast. He was later detected to have traumatic chiasmal syndrome as well as cerebrospinal fluid rhinorrhoea. There were no other complications associated. He was managed conservatively. A review of the present literature and current understanding of the pathogenesis of this intriguing syndrome is presented. Traumatic chiasmal syndrome must be recognized in cases of head injury which can be associated with life threatening complications.

Keywords: bitemporal hemianopia, head injury, traumatic chiasmal syndrome

INTRODUCTION

Traumatic chiasmal syndrome is a rare cranial nerve injury syndrome seen following head injury, usually associated with anterior skull base fractures. The exact pathophysiology of this syndrome is still unclear though many hypotheses are put forward in literature including mechanical disruption or vascular insult to the chiasma being the most prominent of these. Though by itself not dangerous, this syndrome may be associated with life threatening associations in the form of pituitary function disturbances, CSF leak and intracranial carotid artery injuries. It is these severe sequelae that must be recognized and managed.

CASE REPORT

A 25-year-old man sustained closed head injury when the bus he was traveling in was targeted by a bomb. He was admitted with bleeding from his left nostril & right ear, and was seen to have bilateral black eye. Neurologically, he was in a Glasgow Coma Scale (GCS) of E1 M5 V2; pupils were equal but sluggishly reacting.

Initial Computed Tomography (CT) at a peripheral trauma center showed that left orbital roof fracture, with the fracture line running to the basi sphenoid, along with bifrontal patchy contusions and diffuse cerebral edema (Fig 1). He was managed conservatively. He showed slow

improvement over the next five days, following which he was transferred to neurosurgical center.

Evaluation at our center showed that he remained confused, and complained of reduced vision in both eyes. He had intermittent CSF rhinorrhoea. His GCS had improved to E4 M6 V4; pupils were equal but sluggishly reactive bilaterally. Detailed visual evaluation which was now possible in view of his improved neurological status revealed that he had bilateral relative afferent pupillary defect. Visual acuity was 6 / 12 in the right and 6/60 in the left. Visual field charting showed that he had bitemporal hemianopsia (Fig 2). There were no defects in extraocular movements. MRI brain showed edema of the chiasma with a sphenoid sinus traumatic herniation

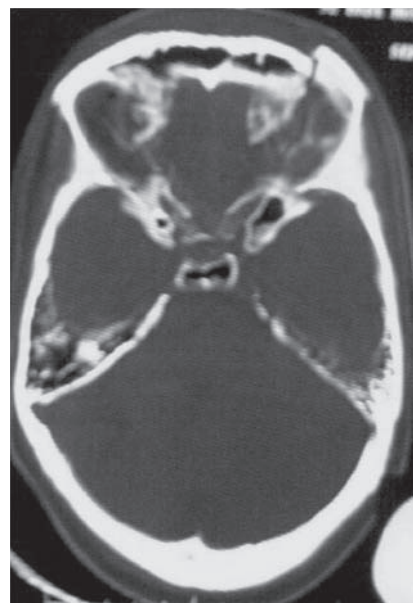


Fig 1: NCCT head bone windows showing the left orbital roof linear fracture extending back till the basisphenoid

Address for Correspondence:

Wg Cdr SGS Datta
Cl Spl (Surgery & Neurosurgery)
Command Hospital (Northern Command)
Udhampur, Jammu & Kashmir
India - 182101 Tele: Off - 01992271636 – 6525
Mob - 0-9906000580 E-mail: sgs1datta@rediffmail.com

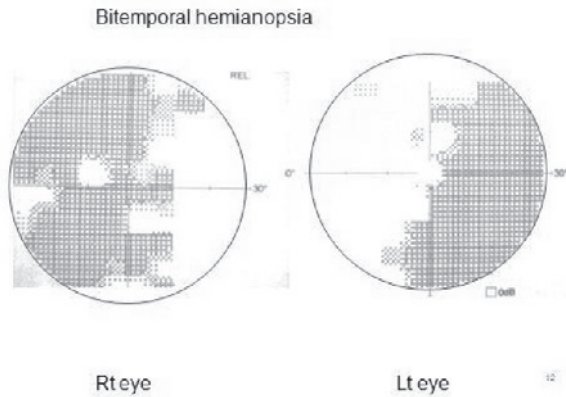


Fig 2: Visual field chart showing the bitemporal hemianopsia in this patient

of the gyrus rectus just anteroinferior to the chiasma (Figs 3a & b). Resolving contusions were also demonstrated in the basifrontal lobes.

He was managed conservatively with parenteral steroids, with which he showed gradually improved. He was closely evaluated for any dyselectrolytemias or diabetes insipidus. CSF leak stopped spontaneously. Visual improvement was marginal and he remains under close follow-up.

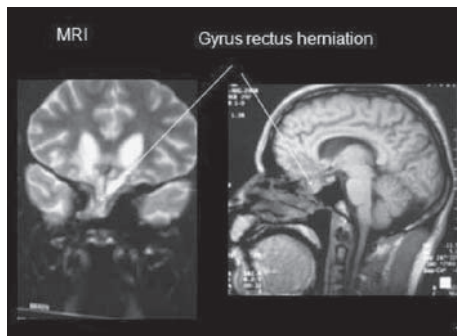


Fig 3a: MRI Brain Coronal T1 W& Sagittal T2 W images showing the herniation of the gyrus rectus in to the sphenoid sinus with drag on the chiasma

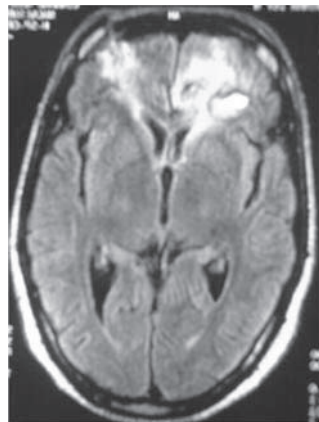


Fig 3b: MRI brain FLAIR images showing bifrontal patchy contusions

DISCUSSION

Bitemporal hemianopsia after closed head injury remains one of the important ophthalmological complications following closed head injury. Less than 1% of head injury survivors develop visual symptoms from injuries in the optic pathway. Chiasmal injury is even more rare, and in one study, only four of 90 patients with injuries in the optic pathway had chiasmal injury¹. Since it was first reported by Nieden in 1883, traumatic chiasmal syndrome was reported in 30 cases by 1935 and in 113 cases by 1975². Though still rare, traumatic chiasmal syndrome is being increasingly recognized and reported. In our centre with more than 600 cases of head injury seen over the last two years this case was the first with traumatic chiasmal syndrome.

A range of visual syndromes have been recognized following traumatic chiasmal injury. Traumatic chiasmal syndrome can present with either incomplete or complete bitemporal hemianopia, and also with macular splitting or sparing. Visual field defects vary from complete monocular blindness and contralateral temporal hemianopia to subtle bitemporal arcuate scotomas^{3,4}. Traumatic chiasmal syndrome usually follows severe frontal head trauma accompanied by multiple cranial fractures and prolonged loss of consciousness. In a clinical series of 19 patients with traumatic chiasmal syndrome, most of whom were young males involved in motor accidents, 65% had skull fractures^{5,6}. Patients have midline basilar skull fractures that traverse the mid clivus through the sella turcica floor, dorsum sella, and sphenoid sinus. Our patient had a fracture line in the orbital roof going into the basi sphenoid.

The resultant degree of visual loss does not necessarily reflect the severity of the craniocerebral trauma³. Although most patients with this syndrome have a severe impact to the frontal area, concomitant brain injury need not be necessarily severe. The visual field defect usually starts immediately after the insult².

It is believed that traumatic chiasmal syndrome results from tearing of the optic chiasm on a microscopic, if not macroscopic, scale^{6,7}. It is proposed that the great force of the injury may cause a sagittal tearing and stretching of the chiasmal crossing fibres. A shearing force that reaches the chiasm may cause contusion necrosis at the sub microscopic level. This is thought to be the most common mechanism responsible for traumatic chiasmal syndrome. The pathogenesis of how

these indirect injuries affect only the decussating fibres of the optic chiasm and spare the non decussating fibres however remains controversial.

Several other possible mechanisms of injury have also been suggested by various authors^{6,7}. It has been suggested that shearing of the internal carotid arteries and of their branches that supply the chiasm may induce ischemia and softening. It has been argued that rupture of fine vessels that supply the median chiasmal region could affect the crossing fibres. Also ascribed is the phenomenon of rupture of the *FranCiosû* chiasmal artery, a branch of the anterior communicating artery that supplies the median region of the chiasm. Another described mechanism is contusional necrosis of the chiasm caused by compression by herniated gyrus rectus. However, none of these explanations have been pathologically demonstrated.

Magnetic resonance imaging (MRI) is the best method for identifying chiasmal abnormalities^{3,8}. Although only a small number of reports of the syndrome have been presented with MRI, significant damage has been demonstrated in the midline structures of the base of the brain, even in patients without prolonged disturbance of consciousness or severe neurologic deficits. Contusion of the gyrus rectus and swelling of the chiasm are frequent findings². Magnetic resonance images have however not identified intra chiasmal haemorrhage as the cause of the visual field defect till date⁶. In our patient chiasmal swelling as well as herniation of the gyrus rectus into the sphenoid sinus was demonstrated on MRI. The breach in the roof of the sphenoid sinus was also probably responsible for the self limiting CSF rhinorrhoea in our patient.

Diabetes insipidus has been recognized to be present in half of these patients, but unlike the visual abnormalities, this complication usually is transient⁸. The incidence of diabetes insipidus in one study was 37%⁵. Other associated complications are panhypopituitarism, carotid cavernous fistula, deficits of cranial nerves II, III, IV, VI or VII, deafness, CSF rhinorrhoea and/or otorrhoea, carotid aneurysm, meningitis, pneumatocele, or intrasellar hematoma. Delayed onset seesaw nystagmus can also develop in cases of traumatic chiasmal syndrome³. Some of these complications could be fatal without early diagnosis and proper management^{2,9}. The clinical significance of posttraumatic bitemporal hemianopsia mainly remains as an early warning sign of such critical complications².

Bitemporal hemianopsia is permanent in most of cases and is not considered for surgical intervention except for cases of progressive deterioration presumably resulting from arachnoiditis around the chiasm. The prognosis for recovery of visual function remains incomplete. In one study, 75% of patients had a final visual acuity of 6/12 or better in at least one eye⁵. In other patients long-term follow-up disclosed persisting complete bitemporal hemianopsias⁶.

CONCLUSION

Traumatic chiasmal syndrome remains an intriguing phenomenon following closed head injury. The pathogenesis of traumatic chiasmal syndrome still remains uncertain. However, it is important to recognize bitemporal hemianopsia as a consequence of closed head trauma. This may permit the anticipation of hormonal deficiencies and other life threatening complications which require close monitoring for fluid and electrolyte balance.

REFERENCES

1. Hughes B. Indirect injury of the optic nerves and chiasma. *Bull Johns Hopkins Hosp* 1962; 111: 98-126.
2. Kawai K, Narita Y, Nagai A et al. Traumatic chiasmal syndrome presenting with bitemporal hemianopsia. *J Trauma* 1998; 44: 224-9.
3. Niphon Chirapapaisan, Alfredo A Sadun. A traumatic bitemporal hemianopia with macular sparing. *J Med Assoc Thai* 2005; 88: S126-30.
4. Peter J. Savino, Joel S. Glaser, Norman J. Schatz. Traumatic chiasmal syndrome. *Neurology* 1980; 30: 963.
5. Hassan A, Crompton JL, Sandhu A. Traumatic chiasmal syndrome: A series of 19 patients. *Clin Exp Ophthalmol* 2002; 30: 273-80.
6. Heinz GW, Nunery WR, Grossman CB. Traumatic chiasmal syndrome associated with midline basilar skull fractures. *Am J Ophthalmol* 1994; 117: 90-6.
7. McIlwaine GG, Carrim ZI, Lueck CJ, et al. A mechanical theory to account for bitemporal hemianopia from chiasmal compression. *J Neuroophthalmol* 2005; 25: 40-3.
8. Tang RA, Kramer LA, Schiffman J, Woon C, Hayman LA, Pardo G. Chiasmal trauma: clinical and imaging considerations. *Surv Ophthalmol* 1994; 38: 381-3.
9. Morris WJ. Traumatic bitemporal hemianopsia and diabetes insipidus. *Surg Neurol* 1978; 9: 246.