

## Backpack brachial plexus palsy

S Maurya MS, Manmohan Singh M Ch, PS Bhandari M Ch, TS Bhatti M Ch  
Dept of Plastic & Reconstructive Surgery, Armed Forces Medical College & Command Hospital (SC) Pune-40

### INTRODUCTION

Wearing of backpack amongst military recruits is a common mode of training. A significant consideration from a military perspective is how well soldiers are able to perform military tasks during load carriage. We report a case of panbrachial plexus palsy in a military recruit wearing such a pack.

### CASE REPORT

A 19-year-old military recruit presented with pain and weakness of left upper limb of 2 weeks duration. He had been well till about 2 weeks back, when he was on a routine cross country training exercise. During the exercise lasting four days, he was carrying a backpack continuously weighing 15.5 kg (Fig 1). He denied any history of fall or trauma to left shoulder. Examination revealed a well-built individual. General physical examination was essentially normal. Examination of left upper limb showed wasting of shoulder, arm, forearm and hand muscles. Wasting was more apparent in left



Fig 1 : Backpack worn by the soldier

deltoid, biceps, thenar and hypothenar muscles (Fig 2-3). Motor examination revealed grade 3+ power of shoulder abduction, elbow flexion and wrist flexion. There was weakness of interossei, lumbricals and abductor pollicis brevis. Thumb opposition was weak. Power was grade 4 in other muscles. There was no sensory loss. X-ray of left shoulder was normal. He was managed conservatively as a case of backpack brachial plexus palsy with weekly follow up. He started showing signs of recovery by 3rd week and had complete recovery at the end of 10 weeks. No neurophysiological studies were performed as he had shown signs of early recovery.

### DISCUSSION

Backpack brachial palsy is an uncommon injury presumably caused by constant pressure by shoulder

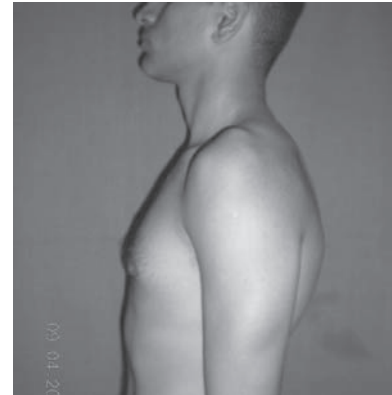

Fig 2 : Wasting of left deltoid

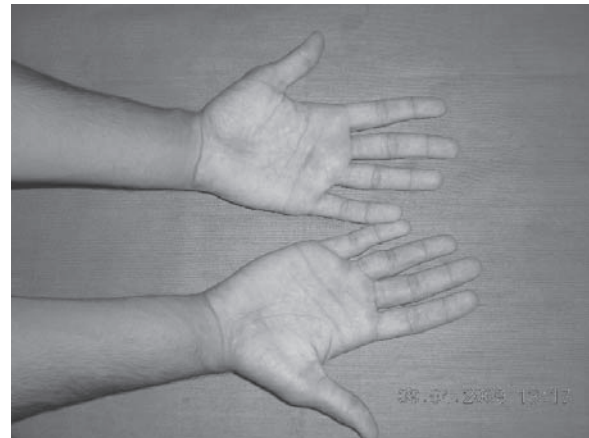


Fig 3 : Wasting of left hypothenar & thenar muscles

#### Address for correspondence:

Lt Col Sanjay Maurya  
Classified Specialist (Surgery), Command Hospital (SC)  
Pune- 411040  
E-mail: drsanjaymaurya@hotmail.com

straps of the pack. Actual incidence is unknown. However one study published by centre of Military Medicine, Finnish Defence Forces Finland, the incidence of neural compression after shoulder load carriage was 53.7 per 100000 recruits per year<sup>1</sup>.

Several factors favour the development of pack palsies, including heavy weights being carried, long period of use, considerable distance being traveled over irregular terrains (which require much upper limb movements at the shoulder to achieve stability). The presence of bony abnormalities about shoulder, especially remote clavicular fractures with resulting deformities also plays a role.

Clinically pack palsies present with unilateral lesions. They manifest as weakness, sometimes with atrophy, paraesthesias and sensory loss<sup>2,3</sup>. Pain is seldom present. Our patient had weakness, pain and atrophy of muscles of upper limb. It commonly involves the upper trunk of brachial plexus, but more extensive lesions can occur as in our case. Mononeuropathies including spinal accessory, axillary, long thoracic nerve neuropathies can also occur.

The underlying pathophysiology with majority of pack palsies is demyelinating conduction block (neuropraxia). However conduction failure caused by axon loss can occur occasionally. Thus recovery time can be quite variable. Patients with axon loss lesions have permanent disabilities

Neuroimaging studies are typically unhelpful with pack palsies (unless a bony lesion is present). Neurophysiological studies can differentiate neuropraxia from axonal block<sup>4</sup>. No specific treatment is available except refraining from pack use and physiotherapy.

Use of a frame and hip belt has been demonstrated to reduce the incidence of backpack palsy, presumably by reducing pressure on the shoulders<sup>5</sup>. Despite having this support our patient still developed the palsy indicating other factors, which might have caused this. Adjustable shoulder straps may help each soldier find the right amount of pull for his or her body build and posture. Horizontal sternum straps across the upper chest might help reduce the back and downward pull on the shoulders.

More studies are needed to find a better design for heavy backpacks carried by military personnel.

Improvement in pack design, awareness amongst recruits and training modifications can help prevent the palsy, which resulted in loss of training hours and transient disability in our patient.

## REFERENCES

1. Makela JP, Ramstad R, Mattila V, Philajamaki H. Brachial plexus lesions after backpack carriage in young adults. *Clin Orthop Relat Res* 2006;452: 205-9.
2. Rother AD, Wilbourn A, Mercer RD. Rucksack Palsy. *Pediatrics* 1975;56: 822-4.
3. De Luigi, Arhtur J, Pasquina P, Dahl E. Rucksack induced plexopathy mimicking a lateral antebrachial cutaneous neuropathy. *Am J Phy Med Rehabil* 2008; 87: 773-5.
4. Trojaborg W. Electrophysiological findings in pressure palsy of brachial plexus. *J Neurol Neurosurg Psychiat* 1977; 40: 1160-7.
5. Knapik JJ, Reynolds KL, Harman E. Soldier load carriage: historical, physiological, biomechanical and medical aspects. *Mil Med* 2004; 169: 45-56.