

Vertex epidural hematoma with pseudoencephalocele

Harjinder S Bhatoe M Ch

Department of Neurosurgery, Command Hospital (SC) and Armed Forces Medical College, Pune 411040

A 22-year-old male reported to the outpatient department with persistent scalp swelling over the right frontoparietal region and dull generalized headache. He had sustained closed head injury due to fall from a two-wheeler two weeks earlier. Clinical evaluation revealed fully conscious patient with no neurological deficit. There were no signs of raised intracranial pressure. He had soft scalp swelling with fluid consistency over the right frontoparietal region. There was no external swelling. CT Brain (Figs. 1a, 1b, 1c) showed a vertex epidural hematoma

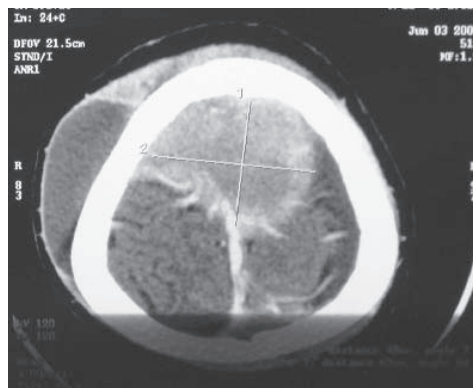
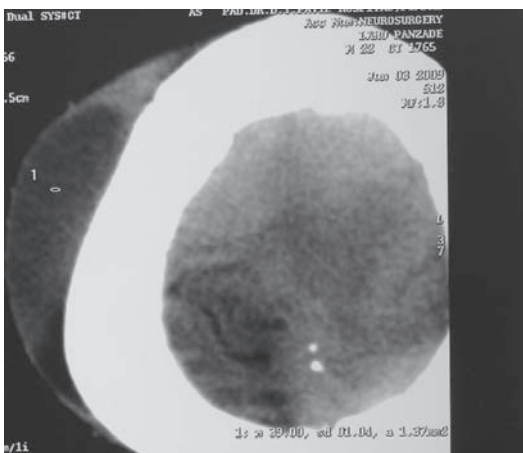
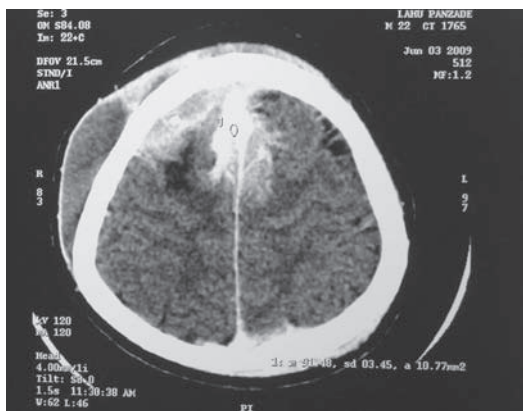


Fig. 1a b & c : NCCT showing EDH over the vertex and encephalocele

with subgaleal collection of cerebrospinal fluid (CSF). MRI brain done after another 48 hours showed midline vertex epidural hematoma with no changes in the brain, and a CSF filled pseudoencephalocele (Figs. 2a, 2b). He

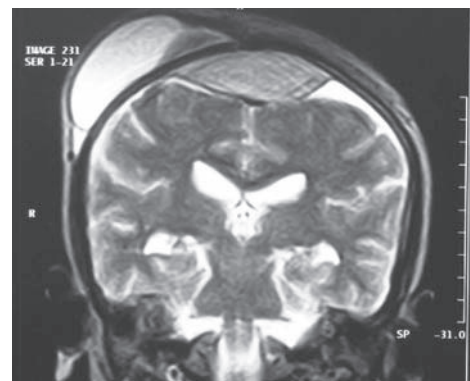
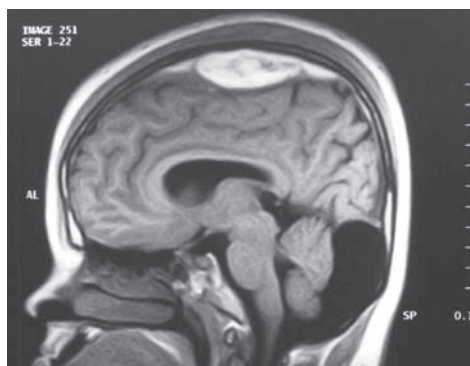


Fig. 2a & b : MRI showing EDH over the vertex and CSF-filled encephalocele

Address for correspondence:

Brig Harjinder S Bhatoe M Ch
Department of Neurosurgery,
Command Hospital (SC), Pune 411040, Maharashtra
Tel: 020-26306112, 26334509 Fax: 020-26334509
E-mail: hsbhatoe@gmail.com // harjinderbhatoe@yahoo.co.in

was managed conservatively, and showed near-complete resolution of encephalocele and epidural hematoma after four weeks (Figs. 3a, 3b).

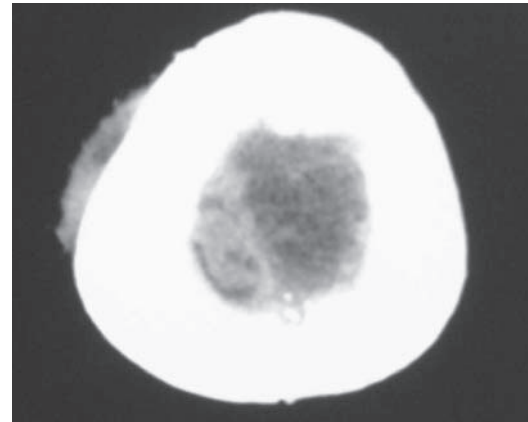
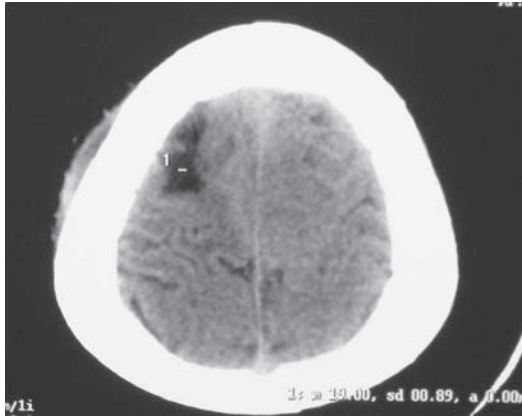


Fig 3a & b : Complete resolution of the hematoma and encephalocele