

High-voltage electrical burn of the head: Report of an unusual case

Mohammed Kaif MS, Deepak Singh Panwar MS, BK Ojha M Ch, Anil Chandra M Ch, Nagesh Chandra MS
Department of Neurosurgery, CSM (Earlier King George's) Medical University, Lucknow

Abstract: Deep burns of the scalp and skull can be caused by high-voltage electrical injuries. Electrocution can occur while working and illegal handling of the lines. Compared to conventional burns, these injuries are characterized by an increased morbidity and mortality. We encountered an unusual case of high-voltage electrical burn of the head causing charring of scalp, bone and dura with herniation of infected brain matter.

Keywords: duroplasty, head injury, high voltage electric burn

INTRODUCTION

Calvarial burns are extremely rare and pose a difficult challenge for both the burn and reconstructive surgeon¹ and the neurosurgeon. Compared to conventional burns, these injuries are characterized by an increased morbidity and mortality. We encountered an unusual case of high-voltage electrical burn of the head causing charring of scalp, bone and dura with herniation of infected brain matter without any neurological deficit.

CASE HISTORY

A 10-year-old girl presented to the trauma centre of CSM (formerly King George's) Medical University 15 days after accidental high-voltage electrical burn of the head while plucking branches from a tree. She had brief loss of consciousness followed by recovery, and a charred wound on the vertex for which he was being treated at home. Since the wound did not heal and foul smell emanated from it, she was brought to the hospital.

On examination she had 12 x 8 cm scalp loss with charred area on the vertex bone with foul smell and fungation of brain matter (Fig 1). There were no systemic signs and symptoms of meningitis or any other neurological deficit.

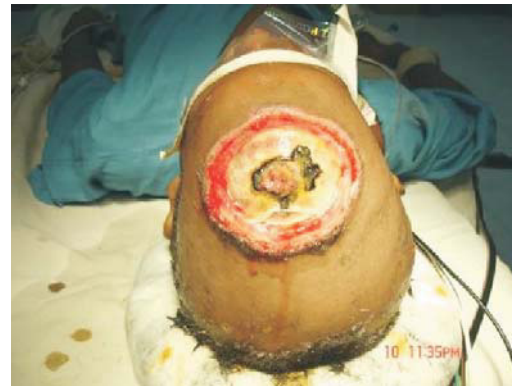

Fig 1: Clinical photograph showing the scalp wound

Plain CT scan was done which showed vertex bone defect (Fig 2).

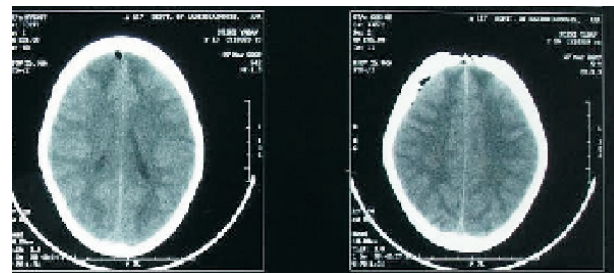


Fig 2: CT Head of patient showing bone defect in the frontal region

A MR Ventriculography was done which showed thrombosed anterior third of superior sagittal sinus (Fig 3)

The child was subjected to surgery for debridement of the wound and protruding necrotic brain matter with duraplasty and transposition scalp flap. After thorough cleaning of the wound the skin and bone defect was defined with visible charred margins of the skull bone

Address for correspondence:

Dr. Mohd. Kaif MS
Senior Resident
Department of Neurosurgery
CSM (Earlier King George's) Medical University
Lucknow, India- 226003
Tel: +91 522 2208256, Mobile: +91 9305561546
Fax: +91- 522- 2257606
E-mail: dr_kaifmohd@yahoo.co.in

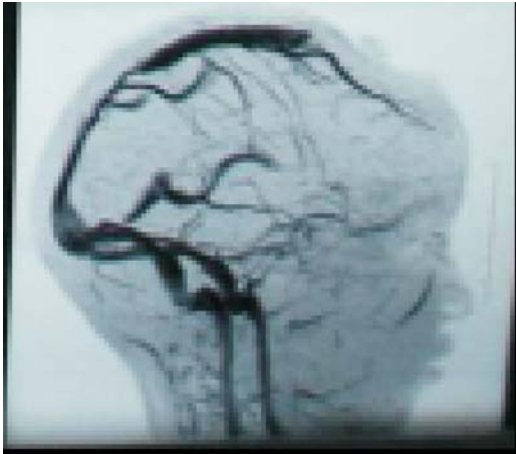

Fig 3: MR venograph of the patient showing thrombosed anterior third of superior sagittal sinus

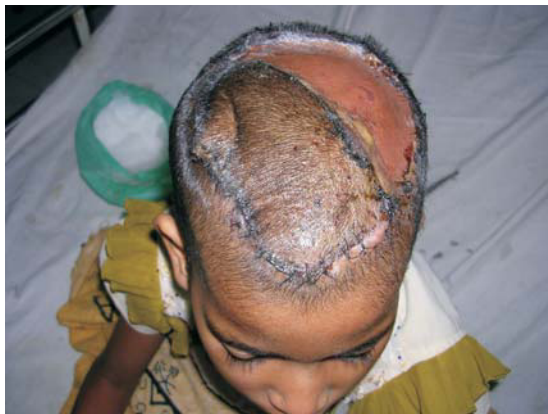

Fig 4: Postoperative photograph of the patient

and fungating brain matter visible. Debridement of the bone was done to define the dura. The infected portion of the dura was removed and stay sutures were applied. The fungated brain matter was excised followed by

hemostasis. Duraplasty was done using fascia lata. The skin defect was covered by transposition flap and the defect caused by the flap was covered by split skin graft. The postoperative period was uneventful and patient was discharged on seventh postoperative day.

DISCUSSION

Deep burns of the scalp and skull can be caused by high-voltage electrical injuries^{2,3}. Electrocutation can occur while working and illegal handling of the lines. Chances of accidentally coming in contact with high tension cables is there as these wires pass through the fields which are the place of work for most of our population. Children are prone to such injuries if left uncared. If such injuries occur they should be immediately attended and prompt intervention should be done which can significantly decrease the morbidity.

As a preventive measures installation of high voltage lines should be such that they should be away from the reach as in this case the line was mounted on a pillar, which was in a depth with a tree in the vicinity.

REFERENCES

1. Roehl K, Geoghegan J, Herndon DN, Patterson J, McCauley RL. Management of class IV skull burns using the bipediced superficial temporal artery scalp flap. *J Craniofac Surg* 2008;19:970-5.
2. Handschin AE, Jung FJ, Guggenheim M, et al. Surgical treatment of high-voltage electrical injuries. *Handchir Mikrochir Plast Chir* 2007;39:345-9.
3. Wright HR, Drake DB, Gear AJ, Wheeler JC, Edlich RF. Industrial high-voltage electrical burn of the skull, a preventable injury. *J Emerg Med* 1997;15:345-9.