Case Report

Indian Journal of Neurotrauma (IJNT)
2010, Vol. 7, No. 1, pp. 85-88

Facial nerve decompression via posterior tympanotomy approach in traumatic facial nerve palsy

P Paul MS, **Sabrigirish K** MS, **B Choudhury** MS, **K Upadhyay** MBBS, **S Raina** MBBS
Department of Otorhinolaryngology & Head-Neck Surgery
Command Hospital (SC) & Armed Forces Medical College, Pune 411040. Maharashtra

Abstract: We managed two cases of facial palsy following trauma, who were decompressed via posterior tympanotomy approach. Both cases improved following surgery. Investigations, surgery and post op management are discussed. We conclude that posterior tympanotomy approach can be used for facial nerve decompression till first genu.

Keywords: facial nerve decompression, post tympanotomy, traumatic facial nerve palsy

INTRODUCTION

Few decades ago, there was no treatment for paralysis of the facial nerve. A severed nerve was doomed never to function again; and in other cases of facial nerve damage, one had to be satisfied with treatments as galvanization of the facial musculature, salicylic acid and massage. The optimal timing for surgical exploration of traumatic facial paralysis to best preserve facial function is currently controversial. Surgical repair of facial nerves may be divided into three major categories: 1) decompression; 2) decompression and end-to end anastomosis; and 3) decompression and nerve grafting. Decompression alone should be performed in those facial nerve injuries which do not respond to higher stimulation and on exploration the nerve is found to be intact. We are presenting two cases of traumatic facial nerve palsy who were managed by decompression via posterior tympanotomy approach without removing incus.

CASE 1

A 28-year-old-male sustained injury to left side of head by falling from stairs on 02 Nov 09 and was diagnosed as a case of complete facial nerve palsy on left side by 04 Nov 09. He was referred to ENT OPD on 21 Nov 09. Clinically patient had complete lower motor neuron facial nerve palsy on the left side (Fig 1a). HRCT temporal bone showed longitudinal fracture line in temporal bone running in epitympanum, sparing labyrinth. In MRI no discontinuity of nerve could be seen and PTA showed normal hearing.

Patient was taken for facial nerve decompression on 27 Nov 09, by transmastoid and posterior tympanotomy approach. Peroperatively, fracture line (Fig. 3) was seen running in the epitympanum. Bony spicule from fracture line was found to be impinging on the nerve distal to first genu in horizontal segment with a fibrous constriction and colour change was seen distal to it. Constriction and bony spicule was removed and colour became normal. Perineurium was split over the exposed part of the nerve and there was no transaction or discontinuity of the nerve.

CASE 2

A 37-year-old-male met with road traffic accident on 27 Oct 09 and noticed facial weakness on left side in immediate post-trauma period. He was referred to ENT centre on 09 Dec 09. Clinically he had complete lower motor neuron facial nerve palsy on left side (Fig 2a). HRCT temporal bone revealed longitudinal fracture line in temporal bone extending upto epitympanum. Audiogram revealed normal hearing.

Patient was taken for facial nerve decompression on 11 Dec 09 by posterior tympanotomy approach. Peroperatively, there was no transaction /discontinuity of nerve however constriction band was seen in horizontal segment of nerve which was removed. Perineurium was split over the exposed part of the nerve.

RESULT

Both patients underwent active and passive facial muscle exercises after surgery and it has been six months since surgery. Facial palsy was graded on the basis of House Brackman scale. After six weeks, both patients have grade IV palsy and no hearing loss (Figs 1b & 2b).

DISCUSSION

Traumatic facial nerve palsy is a common cause of facial paralysis that the clinician is likely to encounter[1]. In a

This document was downloaded for personal use only. Unauthorized distribution is strictly prohibited.

Fig. 1a

Fig. 1b

Fig. 2a

Fig. 2b

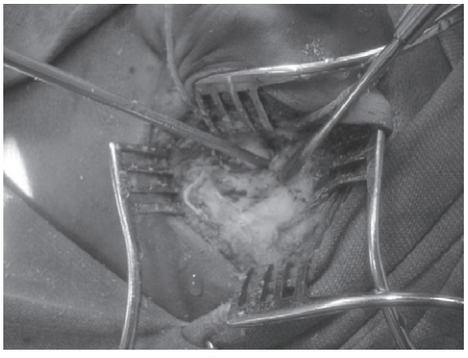

Fig. 3

large series reported by May, 17% of patients with facial paralysis had trauma as the cause[2].

The timing of surgery is still a matter of debate. Fisch[3] advocates immediate exploration only in patients with delayed palsy if ENoG shows more than 90% degeneration while delayed exploration (3 to 4 weeks) should be performed in patients with acute palsy if they meet the surgical criteria. Patients with acute palsy after trauma generally have other system injuries and the surgery should be delayed until the patient's neurological condition is stable.

According to Chang and Cass[4], decompression surgery provides beneficial effects if performed within 14 days of injury and delayed surgery should be done if the facial nerve function does not show any recovery. Many studies[5,6] have shown that late decompression also gives good outcome. Our 1st case was operated after 3 weeks of palsy and second was operated after 06 weeks of palsy. Both had complete facial nerve palsy and improved upto Grade IV after 06 weeks of follow up.

There are many approaches described – transmastoid, translabyrinthine and middle cranial fossa. The transmastoid approach for facial nerve decompression can be utilized when the trauma is clearly localized to the tympanic or mastoid segments of the facial nerve. The nerve should be decompressed for 180 degrees of its circumference. Important landmarks for this approach include the lateral semicircular canal, fossa incudis, and digastric ridge. The incus can be removed and then replaced as an interposition graft to achieve decompression of the tympanic segment of the facial nerve all the way to the geniculate ganglion.

We used transmastoid approach in both cases to expose the vertical segment and posterior tympanotomy approach was used for exploring the horizontal sement and first genu. Advantages of this approach are that canal wall could be preserved, hearing was normal as incus was not removed and post op morbidity of canal wall down techniques like open cavity and its disadvantages can be avoided. However, expertise is required to expose the nerve till first genu without taking out incus. We found that proper positioning is important for visualising the horizontal segment and first genu.

CONCLUSION

The duration of injury is probably not a limiting factor in the severed nerve. Experience with these cases suggests

This document was downloaded for personal use only. Unauthorized distribution is strictly prohibited.

that surgical exploration of the facial nerve is indicated at anytime, as it may be beneficial even in old injuries. Decompression of horizontal segment and first genu can be done by posterior tympanotomy approach which causes less morbidity and preservation of hearing.

REFERENCES

1. Lorenzini M, Mazza C, Scevola S, et al. Successful reconstruction of refractory posttraumatic skull base defects with the free radial forearm flap. *Plast Reconstr Surg* 1998;102:2097–9.
2. May M. The facial nerve. New York: Thieme 1986: 181-216.
3. Fisch U. Facial paralysis in fractures of the petrous bone. *Laryngoscope* 1974; 84: 2141-54.
4. Chang CY, Cass SP. Management of facial nerve injury due to temporal bone trauma. *Am J Otol* 1999; 20: 96-114.
5. Quaranta A, Campobasso G, Piazza F, et al. Facial nerve paralysis in temporal bone fractures: outcomes after late decompression surgery. *Acta Otolaryngol* 2001; 121: 652-5.
6. Ulug T, Ulubil SA. Management of facial paralysis in temporal bone fractures: a prospective study analyzing 11 operated fractures. *Am J Otol* 2005; 26: 230-8.

This document was downloaded for personal use only. Unauthorized distribution is strictly prohibited.