Indian Journal of Neurotrauma (IJNT)
2010, Vol. 7, No. 2, pp. 157-162

CSF rhinorrhea : An overview of endoscopic repair

DP Sharma M Ch, **D Singh** M Ch, **S Sinha** M Ch, **AK Srivastva** M Ch, **H Singh** M Ch, **A Jagetia** M Ch, **Monica Tandon** MD*, **P Ganjoo** MD*
Departments of Neurosurgery and *Neuroanaesthesia, G B Pant Hospital, New Delhi.

Abstract: CSF rhinorrhea can be diagnosed with more accurate localizations of the site of leak with the help of modern radiological methods. The repair involves surgical intervention, which has changed from open craniotomy to minimally invasive techniques. Endoscopic repair has gained popularity in last decade and is being practiced by many neurosurgeons either alone or with their ENT colleagues. The overall success rate of endoscopic repairs has triggered several centers to adopt endoscopic repair as first line of treatment of CSF rhinorrhea. However the inexperience of neurosurgeon to sinus anatomy may pose some difficulties with the young neurosurgeons. The article presents a review of the techniques for confirmation of a CSF leak as well as endocscopic repair of CSF fistula.

Keywords: CSF fistula, CSF rhinorrhea, endoscopic repair, endoscopic surgery

INTRODUCTION

Management of CSF rhinorrhea or otorrhea demands a clear understanding of the etiology and pathogenesis of such dural fistula. Most such leaks occur through the base of the skull, a fact undoubtedly related to the particular anatomy of the area and the inexorable force of gravity. The fundamental cause of CSF leakage is a meningeal fistula caused by a number of factors. The other critical factor is impaired tissue repair, which may be due to lack of proper closure, inadequate support of weak healing tissues, and poor healing of tissue owing to infection, metabolic disorders and other chronic disease.

Although traumatic leakage of CSF is overwhelmingly more common, the first published case of CSF rhinorrhea was a non traumatic high pressure type due to hydrocephalus reported by Miller in 1826[1], followed by reports by King in 1834[2] and Thomson in 1899[3]. Neurosurgical treatment of such dural fitulas began much later with the work of Grant[4] and Dandy[5]. Three cases of traumatic leakage treated surgically were reported in 1927 by Cushing[6]. The first series of cases treated by transcranial extradural repair using fascia lata was published by Cairns in 1937[7]. The transnasal approach to this problem was limited to cauterization until 1948, when Dohlman described a transnasal-transethamoid approach that could seal off leak through the cribriform plate with a septal and middle turbinate flap[8]. The intradural repair technique was first used by Taylor, and reported by Eden in 1941[9]. The etiologic classification of CSF leak was developed by Ommaya et al[10,11,12]. He classified CSF rhinorrhea into traumatic and nontraumatic, subdividing the latter into nontraumatic with normal pressure and nontraumatic with CSF hypertension.

Voena had described cases in which a congenital anomaly was found[13]. Nontraumatic leaks are much less common, are insidious in onset and may present for years. In most traumatic cases (>50%), rhinorrhea stops within one week and in most within 6 months. The flow of CSF is greater in the nontraumatic type, the side affected is not constant, aeroceles rarely develop intracranially and anosmia (found in 78% of traumatic cases), is rare; headache is common in nontraumatic cases. Traumatic CSF leaks bear no relationship to age or sex, whereas the nontraumatic variety affects adults mainly over 30 and female twice as common as male. Meningitis, the main danger in traumatic cases is much less common in the non traumatic variety[11].

DIAGNOSIS

Identification of CSF as the leaking fluid must precede demonstration of the cause as well as localization of the fistula itself. Fluid leaking from the nose or external auditory canal must first be positively identified as CSF. Drops of fluid from a CSF leak placed on absorbent filter paper may result in the double-ring sign, which is a central circle of blood and an outer ring of CSF. Beta-2 transferrin assay is more specific for CSF, but in case of associated orbital injuries this can be unreliable

Address for correspondence :
Dr Daljit Singh
529 Academic block G B Pant Hospital New Delhi India
Cell: 9718599353 Email: drdaljit@hotmail.com

due to the presence of beta-2 transferrin in vitreous humour[14]. Biochemical test on the collected fluid must show value for sugar of more than 30mg/dl to be conclusive, although a test with dextrstix reagent strip has a 45-75% chance of positive result with normal nasal secretions. A negative test is often very useful, particularly in traumatic cases with serosanguinous leaks[15]. Positive identification of CSF necessitate introduction of suitable tracer into the CSF cavities and their recovery into nasal discharge to localization of fistula[16]. The precise localization of the leakage is often a difficult and challenging problem. Possible leaking sites may be in anterior, middle and posterior fossa. Most often, CSF reaches the nasal cavity through the frontal sinus, lamina cribrosa, sphenoid roof or petrous bone via the middle ear and the Eustachian tube. Lateralization of the leak according to nostril side is not reliable, particularly in cases of dislocation of midline structures that act as a separating barriers(crista galli, vomer) or a meningocele obstructing the nostril on the affected side[17].

There are various methods to localization of fistula includes the use of dyes, fluorescent substance, radioactive tracers and radiographic techniques[18]. Dyes (methylene blue, phenolsulfonphthalein, indigo carmine) have been introduced before or during surgery within the subarachnoid spaces or intranasally for visual localization of the fistula. Most of these dyes and particularly methylene blue can cause significant morbidity like chemical meningitis[19]; these dyes are no longer in use.

Some neurosurgeons use a dilute solution of fluorescein to localize CSF fistulas both preoperatively and during surgery. Typically, 0.5 ml of a 10% fluorescein solution is injected into the lumbar subarachnoid space over more than one minute. Fluorescein-stained CSF is seen coming out of the defect as bright yellowish green fluid. There are risks of transverse myelitis and allergic reactions.

In 1956, Crow and colleagues reported three cotton pledge test they use radioactive sodium (Na^{+24}) injected into the cisterna magna and detected by cotton pledge distributed against the wall and roof of the nose and nasopharynx and the opening of the Eustachian tube[20]. Isotope cisternography introduced by Ommaya et al has been used successfully to visualize the fistula in many cases of traumatic and nontraumatic CSF rhinorrhea[11,21,22]. In 1972, Holmann and Devis review the use of isotope in the assessment of CSF pathway[23]. Plain roentgenogram and tomography may demonstrate a fluid level in the sphenoid sinus, an enlarge sella turcica and a suspicious bone defect.

Pneumoencephalography also has been used to show a dilated intrasellar subarachnoid pocket which by acting as a tense pulsating cyst, may be responsible for a rupture in the sellar floor[24,25]. Subdural pneumography may be useful in traumatic cases with leaks through the anterior cranial fossa. Various attempts have been made to localize a CSF fistula by pantopaque or metrizamide injected into the subarachnoid space[26] into the ventricular system, into pneumocephalic cavity or intranasally[27].

High resolution, thin section axial and coronal cranial and facial CT include all of the paranasal sinuses and petrous temporal bones in the scans is helpful in defect localization. CT Cisternography: the use of less irritating water soluble positive contrast media such as metrizamide combined with CT scanning and suitable image reconstruction can often be useful in pinpointing leak location. MR cisternography is helpful for detecting inactive fistulas, and brain and spinal MRI is helpful in demonstrating meningocele and meningoencephalocele when associated with CSF leak.

Gamma Scintigraphic display of the CSF fistula can provide useful information. A quantitative variant of this technique using chelated diethylene triamine pentaacetic acid (DTPA) has also been published[28]. The most commonly used radioisotope is 99mTc-DTPA. PET scanning with ethylene diamine tetra acetic acid (EDTA) has been used to demonstrate a leak in some cases in difficult cases where the side and site of the fistula are not obvious[29]. This is particularly useful in cases of CSF otorrhea where it is not clear whether the leak is via the middle fossa or posterior fossa. Positive contrast myeloencephalography and ventriculography are recommended to outline difficult to detect CSF fistulas[30].

Immunologic methods: Immunologic methods differentiate between proteins in CSF and those in nasopharyngeal secretions[31, 32]. Irjala and collegues have described the use of an immunofixation technique for the identification of microaliquots (100 µL) of CSF by demonstrating two electrophoretically characteristic bands of transferrin[33].

TREATMENT

Medical: Conservative management in CSF rhinorrhea consist of measures to reduce high intracranial pressure.

These include bed rest, head end elevation, avoiding lifting of heavy weights and acetazolamide. Stool softener or laxatives can be use to decrease the strain and increase in intracranial pressure associated with bowel movements.

Surgical: The surgical approach to traumatic leaks ranges from the vigorous one of Cairns[7,34] who recommended exploration and repair of all leaks as soon as the patient is fit for surgery, to the more moderate approach of waiting to see if spontaneous arrest will occur[35].

Prompt surgical intervention may be indicated under the following circumstances:

1) Acute traumatic or postoperative leaks that recur or persist after 10-13 days of conservative management, including external drainage.
2) Proven intermittent or delayed leaks.
3) High-pressure leaks acting as a "safety valve" for hydrocephalus.
4) Leaks associated with erosion, destruction, disruption, or severe combinations of skull base or of the paranasal sinuses.
5) Leaks associated with congenital dysplasias of the brain, skull base, orbit, or ear, particularly after a bout of meningitis
6) Leaks caused by high-energy missile wounds.
7) Postoperative rhinorrhea and otorrhea that cannot be controlled by position and drainage, specially when the air sinuses have been violated as part of the operative route.
8) High-volume leaks through the petrous bone and the sella are particularly recalcitrant to conservative management.

MICROSURGERY

Intracranial Procedure: Intracranial procedures have been adequately described by Dandy[5]. The critical factor in adequate surgical treatment is closure of meningeal defect. The intracranial intradural approach is recommended for most traumatic and nontraumatic cerebral fistulas, with careful patching of the fistula site, preferably using the patient's own fat with or without fascia lata as free graft. The main advantage of intracranial approach is that we can treat associated problems such as intracranial bleed, tumour and closing associated dural defects. The main disadvantages are anosmia, intracerebral hemorrhage, retraction related brain edema and a success rate of about 60% after the first attempt[36].

Extracranial Procedure: An extracranial approach to fistula through frontal and ethamoidal sinus has been recommended by Aboulker et al[37]. Leaks through the sella turcica and sphenoid sinus are best approach via the microneurosurgical trans-sphenoid route. The advantages of extracranial approaches are lower morbidity rates, higher success rates, and these seldom result in anosmia[38,39,40,41,42]. They provide the best exposure of the sphenoid, parasellar, and posterior ethmoidal regions and offer excellent visualization of fistulas in the posterior wall of frontal sinus, cribriform plate and the fovea ethamoidalis[38,42,43,44,45].

Endoscopic Surgery: The endoscopic approach is a subset of the extracranial, extradural approach to CSF fistula. Since 1981 when Wigand first used endoscopic treatment to treat CSF rhinorrhea[46], the technique has become popular worldwide due to its advantages of excellent visualization, precise graft placement, and shortened operating time[40,41,47]. Trasnasal endoscopic surgery minimizes intranasal trauma and preserves the bony framework supporting the frontal recess and other critical areas[48].

Technique: Endoscopic repair of CSF rhinorrhea essentially follows the same principle as that of microscope. It however has added advantage of panoramic view of the skull base and has more accurate localizing value than the other methods of repair. The transnasal repair with endoscope involves, packing the nose with xylocaine with adrenaline (1:100,000) to facilitate shrinkage of mucosa and turbinates and minimizing operative blood loss. Zero and 30 degree telescope are often used for the repair. The procedure can be done with or without the use of nasal speculum. Similarly one can be guided at the site of leak by the use of intra operative fluoroscopy. There are group of surgeons who believe that the middle turbinate should be excised whereas others do it by lateralizating middle turbinate. The site of leak requires definite confirmation before repair. The site of leak can be confirmed with Valsalva maneuver or by the use of fluorescent dye which is seen as yellowish stain CSF within the endoscope. The use of nasal speculum can obviate the need of middle turbinectomy. It also widens the nasal passage for easy placement of telescope and other instruments, and prevents accidental hit of telescope against the turbinate. Once the site of leak has been identified accurately the

repair involves three steps: *Firstly* the rent in the dura is plugged snugly with material like muscle, fascia intradurally. This can be augmented with surgical or biological glue. It is a common observation that most of the surgeons would instill biological glue from outside directly toward the side of leak. However it is our observation that surgicel soaked with biological glue can be placed at the site of leak more accurately and it results in better effective plugging (Fig 1). Second step involves extradural packing with fascia or muscle in a similar fashion as the first step (Fig 2). Thirdly, the repaired area is supported with fat, muscle or gelfoam in the affected air sinuses. The last step essentially prevents the dislodgement of tissue used to repair in step one and two, and to prevent falling off the tissue due to gravity. The nasal packing may be used as in pituitary surgery,

Fig 1 : Endoscopic view of defect at CrIbriform plate. White arrow shows soaked surgicel with glue.

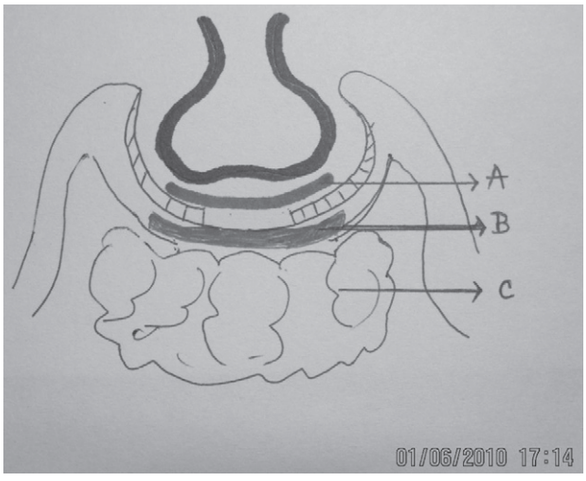

Fig 2 : Diagramatic repair of defects
A-Indradural patch, B-Extradural patch, C- Fat/Fascia in sinus

however some authors do not advocate it on routine basis. Postoperatively, lumbar drain for three days is recommended by some authors.

Familiarity with the nose and paranasal sinuses is an essential step in doing endoscopic repair. It is to be noted that the visible site of CSF leak in the nose may not be the actual site of dural rent at the base of skull. Many times, the leak at floor of sinus is mistaken as leak at the base of skull. Therefore, dura or the herniating brain should be identified at the base of skull before the repair is started. Whenever there is herniation of any brain substance into the sinuses it should be removed till the margins of dura are clearly defined. For most of the neurosurgeons the site of leak at the sphenoid sinus is easily identified because of the familiarity of this area to the neurosurgeons.

RESULTS

Between 2005 and 2009, 36 patients underwent endoscopic repair of CSF rhinorrhea at our institution. Age of the patients ranged from 16-56 yrs. Posttraumatic leak was present in 22 patients, spontaneous leak was seen in 6, and post-operative leak was observed in eight patients. Repair was successful in 32 (90%) patients, and four patients require second attempt making success rate to 97% (35 patients). One patient required craniotomy for failure of endoscopic repair. Mean follow-up was 13 months. Our results are comparable to that reported in literature (Table1).

Table1: Comparison of some published results of endoscopic repairs of CSF rhinorrhea

S No	Series	No of cases	1st attempt successful	2nd attempt successful	Craniotomy
1.	Papay et al[49]	04	04 (100%)	–	0
2.	Mattox et al[40]	07	6(86%)	7 (100%)	0
3.	Stan Kiewich[50]	06	6 (100%)	–	0
4.	Kelly et al[51]	08	7 (88%)	8 (100%)	0
5.	Burns et al[52]	42	35 (83%)	3,38 (90%)	Not mentioned
6.	Lanza et al[53]	36	34 (94%)	135 (97%)	1
7.	Mazhar Hussain et al[54]*	08	8 (100%)*	–	–
8.	Rohit Singh et al[55]	11	10 (90%)	111 (100%)	0
9.	Bhalodiya[17]	20	17 (85%)	219 (95%)	Not mentioned
10	Singh D Present series	36	32 (90%)	335(97%)	1

* One patient of post-traumatic rhinorrhea recurred a month later but responded to conservative treatment.

CONCLUSIONS

Endoscopic repair of CSF rhinorrhea provides a better field of vision with enhanced illumination, magnified angle of visualization and accurate positioning of the graft under direct visualization. The high success rate attached with this should make it the preferred approach in traumatic and nontraumatic CSF leaks, not associated with intracranial space occupying lesions.

REFERENCES

1. Mullar C. Case of hydrocephalus chronicus, with some unusual symptoms and appearances on dissection. *Trans Med Chir Soc Edinb* 1826; 2:243-8.
2. King D. Report to Westminster Medical Society. *Lond. Med Surg J* 1834; 4:823-5.
3. Thompson C. The cerebrospinal fluid: its spontaneous escape from the nose. London: Cassell. 1899.
4. Grant FC. Intracranial aerocele following fracture of the skull: report of a case with review of the literature. *Surg Gynecol Obstet* 1923; 36:251-5.
5. Dandy WE. Pneumocephalus (intracranial pneumatocele or aerocele). *Arch Surg* 1926; 12:949-82.
6. Cushing H. Experience with orbito-ethmoidale osteomata having intracranial complications. *Surg Gynecol Obstect* 1927; 44:721-2.
7. Cairns H. Injuries of the frontal and ethamoidal sinus withspecial reference to cerebrospinal fluid rhinorrhea aand aerocele. *J Laryngol Otol* 1937; 52:589-623.
8. Dohlman G. Spontaneus cerebrospinal fluid rhinorrhea. Case report by rhinologic methods. *Acta Otolaryngol (Stockh) [suppl]* 1948; 67:20-23.
9. Eden K. Traumatic cerebrospinal fluid rhinorrhea: repair of fistula by a transfrontal intradural operation. *Br J Surg* 1941; 29:299-303.
10. Oberader S. Primary nontraumatic spontaneous CSF rhinorrhea with normal CSF pressure. *Arch Neurol Neurochir Psychiatr* 1972; 111:369-76.
11. Ommaya AK, Di Chiro et al. Hydrocephalus and leaks. In Wager H (ed) Principles of nuclear medicine, 2nd edition Phildelphia Saunder 1995.
12. Spetzler RF, Wilson CB. Dural fistula and their repair. In Youman JR(ed) Neurological Surgery,2nd edition. Phildelphia: Saunder 1982PP 2209-27.
13. Voena G. Consideration sv un caso di grace cranio-rino liquorrea da persistanza del canale basi-occipitale. *Arch Ital Otol* 1959; 70:212-22.
14. Ryall RG, Peacock MK, Simpson DA. Usefulness of beta 2-transferrin assay in the detection of cerebrospinal fluid leaks following head injury. *J Neurosurg* 1992; 77:737-9.
15. Gadeholt H. The reaction of glucose oxidase test paper test in normal nasal secretion. *Acta Otolaryngol (Stockh)* 1964; 58:271-2.
16. Mc Kusick KA,Malmud IS, et al. Radionuclide cisternography: normal value for nasal secretion of intrathecally injected 111In-DTPA. *J Nucl Med* 1973; 14:933-4.
17. Neena H Bhalodiya, Shawn T Joseph. Cerebrospinal fluid rhinorrhea: Endoscopic repair based on a combined diagnostic approach. *Indian J Otolaryngol Head Neck Surg* 2009; 61:120-6.
18. Allen MB Jr., El Gammal T, et al. Fistula detection in cerebrospinal fluid leakage. *J Neurol Neurosurg Psychiat* 1972; 35:664-8.
19. Wolman L. The neuropathologic effects resulting from the intrathecal injection of chemical substance. *Paraplegia* 1966; 4:97-115.
20. Crow HJ , Keogh C, Northfield DWC. The localization of cerebrospinal fluid fistula. *Lancet* 1956; 2:325-7.
21. Di Chiro G, Grone AS Jr. Evaluation of surgical and spontaneous cerebrospinal fluid shunts by isotop scanning. *J Neurosurg* 1966; 24:743-8.
22. Di Chiro G, Reams PM, Grove AS Jr. RISA Ventriculography and RISA cisternography. *Neurology (Minneap*) 1964; 14:185-91.
23. Holman BL, Davis DO. Radio isotope assessment of cerebrospinal fluid pathway. *Prog Nucl Med*. 1972; 1:359-75.
24. Busch W, Die. Morphologic der sella turcica und ihre Beziehungen Zur Hypophyse *Verchows Arch Pathol Anat* 1951; 320:437-58.
25. Engels E P. Roentgenographic demonstration of a hypophyseal subarachnoid space. *Am J Roentgenol* 1958; 80:1001-4.
26. Rocket FX, Wittenborg M, Shilleto J Jr., Matson DD. Pantopaque visualization of a congenital dural defect of the internal auditory meatus causing rhinorrhea: Report of a case. *Am J Roentgenol* l964; 91:640-6.
27. Teng P, Edalatpour N. Crebrospinal fluid rhinorrhea with demonstration of cranionasal fistula with pantopaque. *Radiology* 1963; 81:802-6.
28. Oberson R. Radioisotope diagnosis of rhinorrhea. *Radiol Clin Biol* 1972; 41:28-35.
29. Berg Strand G, Berg Strand M. PET with 68 Ga-EDTA in the diagnosis and localization of CSF fistula. *J Comput Assist Tomogr* 1982; 6:320-4.

30. Doron Y, Simon J, Peyser E. Positive contrast myelo-encephalography for visualization of cerebrospinal fluid fistula. *Neuroradiology* 1972; 3:228-30.

31. Ricchetti A, Burkhard PR, Rodrigo N, et al. Skull base cerebrospinal fluid fistula: A novel detection method based on 2-dimentional electrophoresis. *Head and Neck* 2004; 26: 464-9.

32. Oberascher G, Arrer E. First clinical experience with beta2-transferrin in cerebrospinal fluid oto-andrhinoliquorrhea. *HNO* 1986; 34: 151-5.

33. Irjala K, Suonpaa J,Le Beau J,Sterkers JM,Elbaz P. Identification of CSF leakage by immunofixation. *Arch Otolaryngol* 1979; 105:447-8.

34. Cairns H. Injuries of the frontal and ethmoidal sinus with special reference to CSF rhinorrhea and aerocele. *J Laryngol Otol* 1937; 52:589-623.

35. Lewin W. CSF rhinorrhea in nonmissile head injuries. *Clin Neurosurg* 1966; 12:237-52.

36. Sethi DS, Chau C, Pillay PK. Endoscopic manegment of cerebrospinal fluid and traumatic encephalocele. *Am Acad Med Singapore* 1996; 25:724-7.

37. Aboulker, Le Bean J, Sterkers JM, et al. Treatment des fistula meningees ethamoidal- frontalis a propos de 15 cas operesarea, success pr voie exocrancenne. *Ann Otolarayngol Chir Cervicofac* 1966; 83:27-32.

38. Calcaterra TC. Extracranial surgical repair of cerebrospinal fluid rhinorrhea. *Ann Otol Rhinol* 1980; 89:108-16.

39. Park JI, Strelzow VV, Friedman WH. Current management of cerebrospinal fluid rhinorrhea. *Laryngoscope* 1983; 93:1294-1300.

40. Mattox DE, Kennedy DW. Endoscopic management of cerebrospinal fluid leaks and cephalocele. *Laryngoscope* 1990; 100:857-62.

41. Dodson EE, Gross CW, Swerdloff JL, Gustafson LM. Transnasal endoscopic repair of cerebrospinal fluid rhinorrhea and skull base defect: A review of 29 cases. *Otolaryngol Head Neck Surg* 1994; 111:600-605.

42. McCormack B, Cooper PR, Persky M, Rothstein S. Extracranial repair of cerebrospinal fluid fistulas: Technique and results in 37 patients. *Neurosurgery* 1990; 27:412-7.

43. Briant TDR, Snell E. Diagnosis of cerebrospinal fluid rhinorrhea and the rhinologic approach to its repair. *Laryngoscope* 1976; 77:1390-409.

44. McCabe BF. The osteo-mucoperiosteal flap in repair of cerebrospinal fluid rhinorrhea. *Laryngoscope* 1976; 86;537-9.

45. Montgomery WW. Surgery of cerebrospinal fluid rhinorrhea and otorrhea. *Arch Otolaryngol* 1966;84:92-104.

46. Wigand WE. Transnasal ethamoidectomy under endoscopic control. *Rhinology* 1981;19:7-15.

47. Stankiewicz JA. Cerebrospinal fluid fistula and endoscopic sinus surgery. *Laryngoscope* 1991; 101:250-6.

48. Schaefer SD, Manning S, Close LG. Endoscopic paranasal sinus surgery: indications and considerations. *Laryngoscope*. 1989; 99:1-5.

49. Papay FA, Benninger MS, LevineHL. Transnasal transseptal endoscopic repair of sphenoidal cerebrospinal fluid fistula. *Otolaryngol Head Neak Surg* 1989; 101:595-7.

50. Stankiewicz JA. Cerebrospinal fluid fistula and endoscopic sinus surgery. *Laryngoscope* 1991; 101:250-6.

51. Kelly RH, Hirsch BE, Tass SP, Skedros DG. Source of error in use of beta-2 transferrin analysis for diagnosing perilymphatic and cerebrospinal fluid leak. *Otolaryngology Head & Neck Surgery*1993; 109:861-4.

52. Burn JA, Dodson EE, Gross CW. Transnasal endoscopic repair of cranionasal fistula: a refined technique with long term follow up. *Laryngoscope* 1996; 106:1080-3.

53. Lanza DC, O'Brien DA, Kennedy DW. Endoscopic repair of cerebrospinal fluid fistula and encephalocele. *Laryngoscope* 1996; 106:1119-25.

54. Mazhar Hussain, Deepak Jha, Devender K Chhabra, et al. Neuroendoscopic transnasal repair of CSF fluid rhinorrhea. *Skull Base* 2003; 13:73-8.

55. Rohit Singh, Produl Hazarika, D R Nayak, R Balakrishanan, Manali Hazarika, Ansul Singh. Endoscopic repair of cerebrospinal fluid rhinorrhea-Manipal Experience. *Ind J Otolaryngol Head &Neck Surg* 2009; 61(1):14-8.