

Role of Computed Tomography in Minor Head Injury

NR Udgiri M S, M K Tewari M Ch, S Dwarakanath M Ch*, N Khandelwal M D#, BS Sharma M Ch*

Departments of Neurosurgery PGIMER, Chandigarh, AIIMS New Delhi* and Radiodiagnosis & Imaging PGIMER, Chandigarh#

Abstract: Minor Head Injuries (mHI), by their vast numbers, burden the already scarce hospital services by consuming man power and other resources which can be utilized for more deserving HI cases if a scanning protocol can be devised for managing these mHI. One hundred consecutive patients with Glasgow Coma Score of 15 (mHI) underwent a thorough neurological examination, x-rays of skull, cervical spine (AP and lateral views), and chest followed by computerized tomographic (CT) scan of brain. Results were analyzed and intervention was made in abnormal findings. Average age was 26.8 years. Seventy three percent of these patients were males, and 23% of them were children (<12 years). Road side accidents (76%), fall from height (18%) and assaults (6%) were the common causes. Three of the five skull fractures seen were depressed fractures. 23% x-ray films were of poor quality. Risk factors (nausea, vomiting, ear, nose or throat bleeding, headache and giddiness) were present in 54 patients. One or more of these risk factors was present in 16 of 20 patients with abnormal CT scans. Intracranial bleed was seen in 11 cases. Extradural hematoma was seen in five, subdural Patients with normal CT head were released after 24 hours of hospitalization. hematoma, intracerebral bleed and traumatic subarachnoid hemorrhage in two cases each. CT in patients with risk factors not only fetches abnormal CT scans, but also reduces incidence of unnecessary scan by 46%. Early CT in minor HI patients without risk factor and normal neurological examination and mental status with normal findings facilitates early discharge from hospital.

Keywords: Computed Tomography (CT), head injury, minor head injury

Introduction

Acute head trauma or head injury (HI) is increasing every day because of rapid mechanization and rapid increase in motorized vehicular traffic. It is an ever increasing burden on the already stressed accident and emergency services of the hospitals. Mild HI (mHI) which are the commonest of all HI pose an additional, and often avoidable burden over the trauma personnel and patients who require active intervention may get unknowingly neglected¹. Traditionally, patients with HI were subjected to skull x-rays. Advent of computerized tomographic (CT) scan facilities has revolutionized management of HI and limited the role of skull x-rays to medicolegal formalities. Management protocol of moderate and severe head injury is fixed *i.e.* urgent CT scan and management as dictated by the CT appearances. Management protocol of mHI however, remains controversial². Initial protocol of these patients has ranged from CT of head for all patients to admission for observation without head CT. Hence screening of patients using CT scans is helpful to determine which patients require further investigations and intervention and which can be discharged. In this study, we set out to determine whether patients with minor HI would benefit more from CT or clinical observation, or both.

Materials & methods

One hundred patients presenting to emergency surgical outpatient department with blunt trauma head and with the history of loss of consciousness/amnesia and an admission GCS score of 15 were studied prospectively. Identification data and clinical feature were noted. Thorough neurological examination was done. As per our institution protocol, X-rays skull, Cervical spine X-rays (AP and lateral views) and chest were done in all patients in the emergency department on ordinary table. All patients underwent non-contrast CT of head using a standard protocol (5mm cut for posterior fossa with 10 degrees tilt and 10 mm cuts for supratentorial region. Results were read by attending neurosurgeon and were reviewed by radiologist. Abnormal findings were intervened accordingly. All patients with normal CT head were admitted for minimum of 24 hours for observation and those who deteriorated were managed accordingly. Patient with normal CT scans were discharged after 24 hours.

Results

Age ranged between two to 70 years with average age being 26.8 years. Majority of them were males (73%), 23% of them were of pediatric age group (<12 years). Most of the injuries were sustained in roadside accidents (76%), fall from height accounted for 18% and assault for 6% (Fig.1). Fourteen children had history of RSA, 8 had fall and 1 had history of assault. Ten patients presented with history of

Address for correspondence: Dr. M.K.Tewari M Ch, Associate Professor, Department of Neurosurgery, PGIMER, Chandigarh, 160 012., e-mail : manojktewari@hotmail.com

amnesia, rest had history of loss of consciousness (LOC). Only 8 patients remembered exact time of LOC. Fifty four patients had history of one or more of the risk factors, *i.e.* nausea, vomiting, ear, nose or throat bleeding, headache and giddiness. Skull fracture was detected in 15% of patients: 3 of these were depressed fractures. 23% of the films were not of good quality and were either underexposed, overexposed or had improper positioning or rotation.

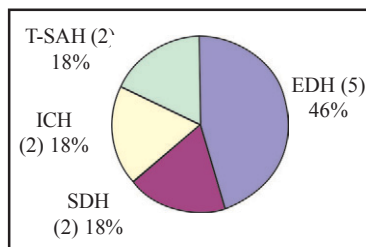


FIGURE 1. Pie diagram showing distribution of intracranial hematomas (N=11)

Abbrev.: EDH - extradural hematoma, ICH - intracerebral hematoma, SAH - subarachnoid hemorrhage, SDH - subdural hematoma

Only 20 patients (20%) had abnormal CT scan results. One of the risk factors was present in 16 out of 20 (80%) patients who had abnormal CT scan. Most of the abnormal CTs showed intracranial bleed (11/20). Contusion was seen in 6 patients, linear skull fracture in 5, depressed fracture in 2 and pneumocephalus was seen in 1 patient. Of the 11 patients who had intracranial bleed, five had extradural hematoma, while significant subdural hematoma, intracerebral bleed and traumatic subarachnoid hemorrhage was seen in two cases each (Table-1).

Table1: CT finding in Minor Head Injury patients

CT scan findings	No. of patients (N=20)
Extra dural hematoma	5
Subdural hematoma	2
Intracerebral hematoma	2
Traumatic subarachnoid hemorrhage	2
Brain contusions	6
Pneumocephalus	1
Fracture skull	5
Depressed fracture	2

Thirteen of these 20 patients with abnormal CT scan needed a change in their management in view of their head CT findings. Two patients with extradural hematoma required urgent surgery to evacuate the hematoma and control bleeding. Remaining patients with abnormal CT scan findings were closely monitored and treated according

to CT findings and discharged 24 hours later in majority of cases. Only 5 patients were observed for 48 hours before discharging them. Rest of the patients with normal CT were observed for 24 hours and there was no neurological worsening in any of them.

DISCUSSION

Skull x-rays had been the mainstay of radiodiagnostic investigation till the middle of eight decade, but at present their role is now debatable and presently are mainly done for medicolegal purposes³. Rosenorn et al³ found no significant difference in the incidence of intracranial complications in patients with or without fracture, and approximately 25% of all acute skull x-ray films were of unsatisfactory quality. Fifteen skull x-rays had abnormal findings which were all confirmed on CT. This again proves that the use of skull x-rays, apart from their current medicolegal value, does not have a significant bearing in diagnosis (as all can be confirmed on CT scan) and subsequent management. In the present study, 23% of skull x-rays were not of ideal quality and proper observation could not be made after studying them. Thus, their role in the overall management and decision making is questionable.

Dacey et al⁴, after studying skull x-rays of 610 head injured patients reported 10.8% incidence of skull fracture; we found this incidence to be 15%(Table-2). Thirteen of their patients with abnormal skull findings required surgery but only one patient in this study, with abnormal skull x-ray, merited surgery. In this study 15 patients had skull fractures demonstrable on skull x-rays and of these 8 patients (53.33%) had an abnormal CT scan. On correlating these figures (Table-3) the p value was significant (<0.01), as was value of Chi square test with 1° of freedom (9.9265). It suggests that there is definitely more chance of abnormal CT scan with abnormal skull x-rays and that it may ask for change in management in a patient with abnormal skull x-ray. Of the eight patients with abnormal CT scans, only five patients required change in management, of which one was operated for EDH had right temporal bone fracture demonstrable on both CT and x-ray while in the other patient no fracture was detected on both x-ray and CT. Thus radiological findings altered the management in 5% of patients of our study. In contrast deCampo and Petty⁵ found in their study that treatment was influenced by radiological findings only in 0.6% cases. They concluded that skull x-ray examination is indicated if a depressed fracture, compound fracture or radio opaque foreign body is suspected. In this study 60% of patients (3/15) with abnormal x-rays were detected to have depressed fractures. Films were of good quality in only 77% cases. The possible

reasons for poor quality could be non-availability of routine skull table and that injured patients could not cooperate fully because of pain and apprehension. Masters et al⁶ found a multidisciplinary panel for studying role of skull x-ray examination after head injury have recommended use of x-rays in moderate risk group and CT in high risk group. Their view is that skull x-rays may (rarely) be helpful, if positive, but do not exclude intracranial injury if normal.

The present study indicates that CT is a useful diagnostic tool. Early head CT is very useful in screening patients with mHI. It can accurately identify the patients at risk for subsequent neurological deterioration. We share the view with other authors⁷ that a normal CT scan with unremarkable neurological examination and no risk factor make an ideal situation for discharge of patient from hospital within 24 hours thus allowing better utilization of limited physician, nursing and hospital resources^{8,9}. In our study 20% patients had abnormal CT scan, only 2% required surgery and no patient with normal CT deteriorated. Stein and Ross⁹ observed that in patient with mHI (GCS 13-15 with LOC or amnesia), 18% had abnormal CT scan and only 5% required surgery. The difference between our and their study could be because of a bigger sample size and consideration of patients with GCS 13-15 in their study. In contrast to findings of Stein and Ross⁹, Mohanty et al¹⁰ reported an incidence of 3.45% abnormal scans in their study.

CT definitely has an edge over clinical examination in detecting an operable lesion. Feuerman et al¹¹ recommended that patients with normal neurological status and normal mental status can be discharged even without subjecting them to CT head and reported only 2 cases with neurological deficit required operative intervention. However, Stein et al¹² and Vilke et al¹³ disagreeing with Feuerman et al¹¹ assert that a normal or near normal neurological status does not exclude an operable lesion. Likewise, in our study, both the patients who had to be operated had a normal neurological status and normal mental status.

Miller et al¹⁴ studying the clinical significance of risk factors like severe headache, nausea, vomiting and depressed skull fracture found that significant number of patients with CT abnormality had these risk factors. They concluded that if CT in minor head injury was done only on patients with these risk factors there would be 61% reduction in number of CT scan done, and still identifying all patients who require neurosurgical intervention or will have abnormal CT scan. In our study we found that 54% patients had these risk factors. Twenty patients had abnormal CT scans, of which 16 had one of these

symptoms. Rest 38 patients had normal CT scans. Comparing these variables, p values is <0.05 is significant (according table 2 value of chi square with 1DF is 5.5581), meaning thereby, that this correlation between risk factors and abnormality on CT scan is significant. Thus in our study if we would have followed this criteria it would have resulted in reduction of 46% of CT scans done, still identifying all patients who required neurosurgical intervention and majority of abnormal CT scans.

Stein and Ross⁷ have emphasized on role of CT in head injury and feel that observation of patients without CT scan using skull x-rays alone is potentially dangerous as one cannot rule out operable lesion. Patients having LOC/ amnesia with normal CT can be discharged. Even if CT is costlier investigation than x-ray it should be done considering its diagnostic value. Similarly the cost-effectiveness of routine early CT scan after minor head injury was confirmed by Ingebrigsten and Romner¹⁵. In our study we found that the patients with normal CT scan findings had no deterioration in their neurological status during the observation period.

Taheri et al² suggested some criteria of discharge for patients with minor head injury presenting to emergency department. These were- GCS 15/15, no deficit loss of consciousness except amnesia, no signs of intoxication, no evidence of basilar fracture on clinical examination or linear fracture on screening skull X-ray. They found that

Table 2: Comparison between abnormal skull x-ray and CT scan

Observed Frequency Table is:

	Abnormal CT	Normal CT	Total
Abnormal skull x-ray	8 (40%)	7 (8.75%)	15(15%)
Normal skull x-ray	12 (60%)	73 (91.25%)	85 (85%)
Total	20	80	100

Value of Chi square with 1 Df is 9.9265

Table 3: Comparison of risk factors with abnormal CT scan

Observed Frequency Table is:

	Abnormal CT	Normal CT	Total
With risk factors	16 (80%)	38 (47.5%)	54 (54%)
Without risk factors	4 (20%)	42 (52.5%)	46(46%)
Total	20	80	100

Value of Chi square with 1 Df is 5.5581

safe discharge without universal CT evaluation is possible and cost efficient. Disagreeing with this view however, Stein et al¹² and Livingstone et al⁸ recommend use of CT in all

patients with mHI, so that an operable intracranial lesion is not missed. Scandinavian neurotrauma committee¹⁶ after reviewing forty two studies regarding management guidelines of head injury proposed that patients with minimal injuries (no LOC, GCS-15) can be safely discharged. Routine early CT scan is recommended in cases with mHI (history of LOC, GCS 14-15) and patients with normal scans may be discharged. CT scan and admission is mandatory is moderate injuries (GCS-13).

CONCLUSION

X-rays have debatable in minor HI as almost all of the x-ray findings can be seen on CT scan. Use of CT scan in patients with risk factors leads to better yield of lesions and reduces incidence of unnecessary CT scan by 46%. Patients with minor HI without risk factor(s) and normal neurological examination and mental status and normal CT scan can be safely discharged from hospital.

REFERENCES

1. Steill IG, Wells GA, Vandemheen K. et al. Variation in ED use of computed tomography for patients with minor head injury. *Ann Emer Med* 1997; 30 : 14-22.
2. Taheri PA, Karamanoukian H, Gibbons K, Waldman N, Doerr RJ, Hoover EI. Can patients with minor head injuries be safely discharged from home ? *Arch Surg* 1993 ; 128 : 229-92.
3. Rosenorn J, Duus B, Nielsen K, Kruse K, Boesen T. Is a skull X-ray necessary after milder head trauma. *Br J Neurosurg* 1991; 5 : 135-9.
4. Dacey RG Jr, Alves WM, Rimmel RW , Winn HR, Jane JA :Neurosurgical complication after apparently minor head injury: an assessment of risk in a series of 610 patients. *J Trauma* 1991;31: 801-4.
5. de Campo J, Petty PG. How useful is skull X-ray examination in trauma ? *Med J Aus* 1980; 2 : 553-5.
6. Masters SJ, McClean PM, Arcarese JS, et al. Skull X-ray examinations after head trauma. *N Engl J Med* 1987; 316 : 84-91.
7. Stein SC, Ross SE. Mild head injury : a plea for routine early CT scanning. *J Trauma* 1992; 33 : 11-3.
8. Livingstone DH, Loder PA, Koziol J,Hunt CD. The use of CT scanning to triage patients requiring admission following minimal head injury. *J Trauma* 1991; 31 : 483-7.
9. Stein SC, Ross SE. The value of computed tomographic scans in patients with low risk head injuries. *Neurosurgery* 1990; 26 : 638-40.
10. Mohanty SK, Thompson W, Rakower S. Are CT scans for head injury patients always necessary? *J Trauma* 1991;31: 801-7
11. Feuerman T, Wackym PA, Gade GF, Becker DP. Value of skull radiography, head computed tomographic scanning and admission for observation in cases of minor head injury. *Neurosurgery* 1988; 22 : 449-53.
12. Stein SC, Spettell C, Young G, Ross SE. Limitations of neurological assessment in mild head injury. *Brain Inj* 1993; 7: 425-30.
13. Vilke GM, Chan TC, Guss DA. Use of complete neurological examination to screen for significant head injury. *Am J Emer Med* 2000 ; 18: 159-63.
14. Miller EC, Holmes JF, Derlet RW. Utilising clinical factor to reduce head CT scan ordering for minor head trauma patients. *Am J Emer Med* 1997; 15: 453-7.
15. Ingebrigtsen T, Rommer B. Routine early CT scan is cost saving after minor head injury. *Acta Neurol Scand* 1996; 93: 207-10.
16. Ingebrigtsen T, Rommer B, Kock-Jensen C. Scandinavian guidelines for initial management of minimal, mild and moderate head injuries. *J Trauma* 2000; 48 : 760-6.