

# Traumatic Posterior Inferior Cerebellar Artery Infarction

Lt Col H S Bhatoo M Ch, S S Bakshi MD

Department of Neurosurgery Army Hospital (Research & Referral), Delhi Cantt. 10010. India  
& Department of Radiodiagnosis, Christian Medical College, Ludhiana (Punjab)

**Abstract :** Trauma is the commonest cause of intracranial ischemia in the young. A young soldier who developed features of posterior inferior cerebellar artery following acute flexion-torsional strain to the cervical spine who presented with cerebellar features is reported. There was no evidence of raised intracranial pressure. MRI was diagnostic. He improved with conservative management.

**Keywords:** cerebellar infarction, cerebellum, head injury, posterior inferior

## Introduction

Post-traumatic posterior inferior cerebellar artery (PICA) territory infarction generally follows lateral mass fracture of atlas with stretching or compression of the vertebral artery (VA) in closed cervical trauma<sup>1,2</sup>. PICA territory cerebellar infarction following cervical spine injury without any fracture or dislocation is distinctly rare. We report one such case, who developed features of cerebellar dysfunction following closed cervical spinal trauma, and was detected to have cerebellar infarction involving the medial PICA territory. Relevant literature is briefly reviewed.

## Case Report

A 25-year-old-army soldier sustained sudden twisting and hyperflexion trauma to his neck during a game of *kabaddi* (a rough contact sport popular in the rural Indian subcontinent), when he was tackled by the opponents. He suddenly felt electric shock-like sensation in his body and collapsed, and had to be lifted on a stretcher. At the time of admission, he was seen to be conscious, breathing spontaneously and had normal pulse and blood pressure. Neurological examination revealed coarse nystagmus and grade 5/5 power in all four limbs. Cervical spine radiographs were normal and there was no craniovertebral junction anomaly. He was given intravenous dexamethasone, and was closely observed for neurological deterioration. Ten hours later, he complained of headache and vomited once. Sensorium remained unchanged. In addition to nystagmus, he had developed past pointing and intention tremor on the left and truncal and gait ataxia. CT brain showed low attenuating non-enhancing region in the left cerebellar hemisphere (Fig 1).

Address for correspondence : Harjinder S Bhatoo M S, M Ch  
Department of Neurosurgery Army Hospital (R & R), Delhi Cantt 110010. India, Tel: 91-11-25668095, 25668096, Fax: 91-11-25681893  
E-mail: hsbhatoo@indiatimes.com, bhatoo@rediffmail.com:

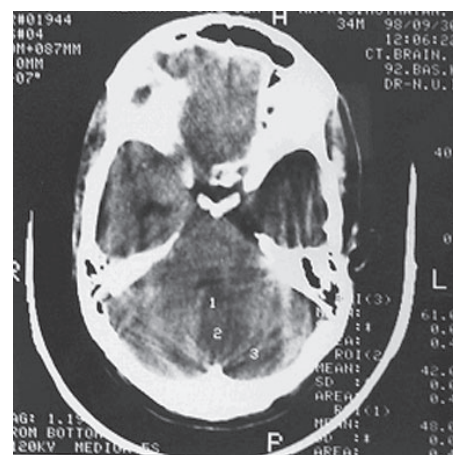


FIGURE 1. NCCT brain showing low attenuation area in cerebellum

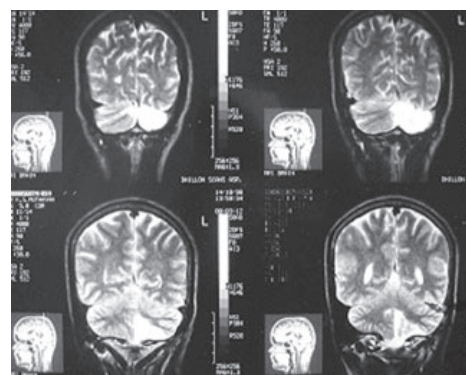
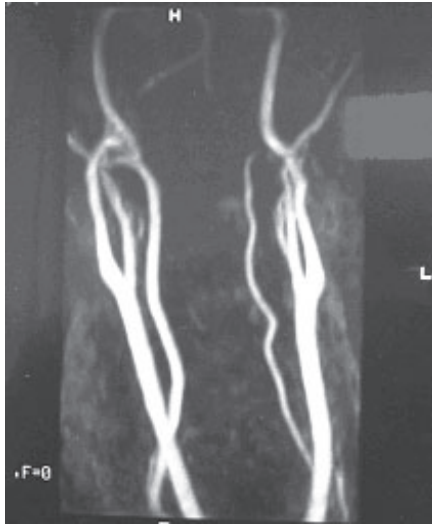

FIGURE 2. MRI (T2-weighted, coronal) showing PICA territory infarct

MRI of the brain could be done five days later. The study done at 0.5T revealed isointensity in the tonsillar region of the cerebellum on T1-weighted imaging (T1WI) and well defined wedge shaped hyperintensity of the caudal and medial regions of the cerebellum on T2-weighted imaging (T2WI) (Fig 2) indicating PICA territory



**FIGURE 3.** MR angiography showing normal caliber neck vessels

infarction. There was no involvement of brainstem. MR angiography of the neck vessels was normal (Fig 3).

He was managed conservatively, and showed gradual improvement over the next two weeks. He was discharged from the hospital three weeks after the injury and was asymptomatic when reviewed six months later.

### DISCUSSION

Reports of vertebrobasilar arterial trauma prior to 1950 dealt with almost exclusively with penetrating injuries, and potential for arterial injury following blunt trauma to the neck remained largely ignored. In 1955, Suechting & French<sup>3</sup> reported the first case of vertebral artery injury secondary to blunt trauma. They described a patient with an acute cervical fracture dislocation injury who developed a PICA syndrome. The underlying pathology was thought to be stretching of VA from the use of cervical traction. Their diagnosis was made clinically and there was no angiographic confirmation. The first autopsy confirmation of VA injury and cerebellar infarction was given by Murray<sup>4</sup>, while Aronson<sup>5</sup> first angiographically demonstrated vertebral artery injury after blunt neck trauma. Although there have been a number of case reports of injury to vertebrobasilar arteries<sup>2</sup>, reports of PICA region infarction following closed injury are rarely reported<sup>6,7,8,9</sup>.

**Mechanism of traumatic PICA occlusion :** While occlusion of PICA after injury generally results from vertebral artery thrombosis or intimal tear, it is also probable that stretching in its course injures the artery. The tonsillomedullary segment begins where the artery passes posterior to glossopharyngeal, vagus and accessory nerves, and extends medially across the posterior aspect of medulla

near the caudal half of the tonsil<sup>10</sup>. It may pass through, above or below the rootlets of hypoglossal nerves, and may be involved in a complex loop that stretches or distorts these nerves<sup>11</sup>. It is probable that in cases of PICA territory infarction involving the cerebellum only, this segment may have been stretched in acute flexion-distraction or rotatory trauma or subluxation of cervical spine, leading to intimal tear or thrombosis.

PICA territory infarction may lead to the classical lateral medullary syndrome (Wallenberg syndrome)<sup>8</sup>. Patients typically present with headache, dizziness, nausea and vomiting and staggering gait. The symptoms may develop suddenly but a gradual development over 24 to 48 hours is more common<sup>12</sup>. However, majority of the patients with PICA territory cerebellar infarcts do not have lateral medullary infarcts ; in an autopsy study by Sybert & Alvord<sup>13</sup> only 21 percent of PICA occlusion had an associated lateral medullary infarct. The infarct affects the flocculonodular lobe of the cerebellum which is closely connected with the vestibular nuclei. Some patients with PICA infarcts, especially infarcts affecting the cerebellar vermis (supplied by medial branches of PICA) present solely with pseudolabyrinthine symptoms that may have a positional character and be mistaken for acute labyrinthitis<sup>6,7</sup>. Gait ataxia is a prominent finding<sup>14</sup>. These infarcts involving the medial branch of the PICA are usually benign and have better prognosis<sup>6</sup>. Large infarcts however may swell and lead to fresh neurological deficits, including features of brainstem compression, decerebrate quadriparesis, respiratory difficulties and later apnea<sup>14</sup>. Infarcts are usually evident on CT. Special attention should be directed to the detection of early hydrocephalus and compression of the fourth ventricle. Recent developments in MRI, particularly spin-echo, gradient refocusing acquisition and magnetic resonance angiography (MRA) allow accurate and non-invasive evaluation of post-traumatic ischaemic sequelae. In addition to direct anatomical visualization of the vessels involved, MRI can show infarcts involving the cerebellum and brainstem as early as 6 to 12 hours after the injury<sup>15</sup>. The sagittal and coronal T2WI is particularly helpful in delineating the territory involved.

There are no definite guidelines for the management of these injuries because of limited data on the natural history of these lesions and their potential to produce symptoms. It is likely that spontaneous improvement in neurologic deficits occur in most of the patients. In comatose patients, Heros<sup>16</sup> advocated prompt surgical intervention for cerebellar swelling to prevent fatal outcome. Tyagi et al<sup>9</sup> achieved good result with ventricular drainage in one eighteen-year boy who had post-traumatic cerebellar

infarction. Hyperventilation and osmotic diuretics may also be beneficial<sup>14</sup>. However, the manifestations may be mild and patient may make an uneventful recovery without any such definitive treatment, especially with infarction limited to the medial branch of PICA<sup>6</sup>.

### CONCLUSION

Traumatic cerebellar infarction involving the PICA territory is rare after close neck injury without cervical fracture or dislocation. Patients may present with pseudolabyrinthine features and cerebellar signs. Such injury must be suspected in patients with unexplained deficits following head or neck injuries. MRI is diagnostic of the condition. Management is essentially conservative although surgical decompression and ventricular drainage have been described. Outcome is good with no or minimal residual neurological sequelae.

### REFERENCES

1. Rosman N P, Wu J K, Caplan L R. Cerebellar infarction in the young. *Stroke*, 1992; 23:763-6.
2. Willis B K (1995) Vertebral and basilar artery injuries. In, Carter L P, Spetzler R F, Hamilton M G (eds). *Neurovascular Surgery* McGraw-Hill, Inc. New York ; pp 1313-1336.
3. Suechting R L, French L A. Posterior inferior cerebellar artery syndrome following a fracture of the cervical vertebrae. *J Neurosurg*, 1955; 12:187- 9.
4. Murray D S. Post-traumatic thrombosis of the internal and carotid arteries after non-penetrating injuries of the neck. *Br J Surg*, 1957; 44:556 - 61.
5. Aronson N I (1961). Traumatic arteriovenous fistula of the vertebral vessels. *Neurology*, 1961; 11: 817- 20.
6. Amarenco P, Roullet E, Hommel M, Chaine P, Marteau R. Infarction in the region of the medial branch of the posterior inferior cerebellar artery. *J Neurol Neurosurg Psychiat* 1990; 53:731-5.
7. Duncan G, Parker S, Fisher C M. Acute cerebellar infarction in the PICA territory. *Arch Neurol* 1975; 32:364-8.
8. Levy R L, Dugan T M, Bernat J L, Keating J. Lateral medullary syndrome after neck injury. *Neurology*, 1980; 30:788-90.
9. Tyagi A K, Kirolos R W, Marks P V (1995). Post-traumatic cerebellar infarction. *Br J Neurosurg*, 1995; 9:683-6.
10. Lister J R, Rhoton Jr A L, Matsushima T, Peace D A. Microsurgical anatomy of the posterior inferior cerebellar artery. *Neurosurgery*, 1982; 10:170-99.
11. Oliviera Evandro de, Tedeschi H, Rhoton Jr A L, Peace D A (1995). Microsurgical anatomy of the posterior circulation: Vertebral and basilar arteries. In, Carter L P, Spetzler R F, Hamilton M G (eds). *Neurovascular Surgery* McGraw-Hill, Inc. New York; pp 25-34.
12. Norrving B, Cronqvist S (1991). Lateral medullary infarction. Prognosis in an unselected series. *Neurology*, 1991; 41:244-8.
13. Sybert G, Alvord E. Cerebellar infarction: A clinicopathologic study. *Arch Neurol* 1975; 32:357-63.
14. Wityk R J, Caplan L R (1995). Vertebrobasilar occlusive disease. In, Carter L P, Spetzler R F, Hamilton M G (eds). *Neurovascular Surgery* McGraw-Hill, Inc. New York; pp 359 – 82.
15. Drayer B P (1995). The diagnosis of brain infarction: Imaging approaches. In, Carter L P, Spetzler R F, Hamilton M G (eds). *Neurovascular Surgery* McGraw-Hill, Inc. New York; pp 113-26.
16. Heros C R. Cerebellar infarction resulting from traumatic occlusion of a vertebral artery. Case report. *J Neurosurg*, 1979; 51:111-3.